

Assessment of extravasation on ruptured uterine artery pseudoaneurysm using contrast-enhanced ultrasonography during uterine balloon tamponade

Journal of International Medical Research

48(4) 1–6

© The Author(s) 2019

Article reuse guidelines:

sagepub.com/journals-permissions

DOI: 10.1177/0300060519893166

journals.sagepub.com/home/imr



Jun Takeda , Shintaro Makino, Chihiro Hirai,
Yota Shimanuki, Tetsunori Inagaki,
Atsuo Itakura and Satoru Takeda

Abstract

Objective: Contrast-enhanced ultrasonography (CEU) has been used in critical trauma situations to visualize extravasation; however, its use is limited in the field of obstetrics. Cases of ruptured uterine artery pseudoaneurysm (UAP) were analyzed to clarify the efficacy to CEU during uterine balloon tamponade.

Methods: Cases of ruptured UAP diagnosed at a teaching university hospital from January 2015 to December 2017 were retrospectively analyzed. UAP was diagnosed using color Doppler ultrasonography. Extravasation was identified using computed tomography and double checked using CEU with an intravenously administered contrast agent (Sonazoid; Daiichi Sankyo Company, Ltd., Tokyo, Japan) and an ultrasound instrument (HI VISION Preirus; Hitachi Aloka Medical, Ltd., Tokyo, Japan). A balloon was then inserted into the uterine cavity and inflated at the point of bleeding until extravasation ceased.

Results: Three patients exhibited ruptured UAP during the study period. Bleeding points were successfully identified using CEU in all cases, and hemostasis was achieved using uterine balloon tamponade. Obliteration of UAP was confirmed using magnetic resonance imaging, and no patients developed recurrent UAP or any complications.

Conclusion: CEU can be used at the bedside to promptly diagnose ruptured UAP. Moreover, it precisely facilitates balloon compression at the point of bleeding.

Department of Obstetrics and Gynecology, Juntendo University Faculty of Medicine, Tokyo, Japan

Corresponding author:

Jun Takeda, Department of Obstetrics and Gynecology, Juntendo University Faculty of Medicine, 2-1-1 Hongo, Bunkyo-ku, Tokyo 113-8421, Japan.
Email: jtakeda@juntendo.ac.jp



Keywords

Contrast-enhanced ultrasonography, extravasation, postpartum hemorrhage, uterine balloon tamponade, uterine artery pseudoaneurysm, rupture

Date received: 21 August 2019; accepted: 13 November 2019

Introduction

Uterine balloon tamponade (UBT) is a highly effective technique for controlling postpartum hemorrhage.¹⁻⁵ Several recent guidelines have recommended performing UBT for first-line mechanical hemostasis because of its simplicity and cost-effectiveness.⁶⁻¹⁰ However, the success rate of UBT reportedly ranges from 78.1% to 97.1%.^{1-3,11} One reasonable explanation for failed UBT is that the balloon sloughs off or prolapses from the original fundal cavity and cannot directly compress the bleeding point.¹²⁻¹⁴ Thus, precise assessment of the bleeding point/area is necessary for reliable hemostasis in patients undergoing UBT.

We previously reported the efficacy of contrast-enhanced ultrasonography (CEU) using Sonazoid (Daiichi-Sankyo, Tokyo, Japan) to assess postpartum hemorrhage.¹⁵ CEU provides a clear view during the vascular and post-vascular phases and was originally used to diagnose hepatocellular carcinoma.¹⁶⁻¹⁸ The Japanese Ministry of Health, Labour and Welfare has expanded the indications for the use of Sonazoid to diagnosis of breast tumors. Sonazoid has also been used to visualize extravasation in patients with other critical conditions, such as liver trauma and gall bladder perforation.¹⁹⁻²¹ However, its application is limited in the field of obstetrics. Thus, in the present study, we evaluated the efficacy of CEU in UBT procedures to treat patients with a ruptured uterine artery pseudoaneurysm (UAP).

Patients and methods

This retrospective study was conducted at Juntendo University Hospital, a tertiary university hospital located in Tokyo, Japan. Patients who were diagnosed with UAP, examined using CEU, and treated with UBT from January 2015 to December 2017 were eligible for inclusion. UAP was diagnosed according to the “to-and-fro pattern”²² or “swirl pattern”²³ on color Doppler ultrasonography. Extravasation was diagnosed using computed tomography (CT) and double checked using CEU. Sonazoid was used as the contrast agent during ultrasonography and was intravenously administered at a dose calculated according to the patient’s body weight. Bleeding points were assessed a few minutes after administering Sonazoid. A Fuji-Metro balloon (Fuji Latex, Tokyo, Japan),²⁴ originally designed for cervical ripening before inducing labor, was then inserted at the bleeding point in the uterine cavity and inflated until extravasation ceased. The off-label use of the Fuji-Metro balloon was approved by the Juntendo University Hospital Ethics Committee (#18-040). The HI VISION Preirus (Hitachi Aloka Medical, Ltd.) was used for CEU. The contrast mode, which calculates noise levels to facilitate a clear view, was used in the assessment. Although the use of Sonazoid is not contraindicated in lactating women, lactation was prohibited for 24 hours after injecting Sonazoid because the adverse effects of this contrast agent on infants have not been established. The off-label use of Sonazoid

was approved by the Juntendo University Hospital Ethics Committee (#25-576), and written informed consent was obtained from all patients who participated in this study. The primary endpoint was the success rate of UBT. Complications related to CEU or UBT were assessed as secondary outcomes.

Results

Three patients exhibited a ruptured UAP during the study period, and all patients developed genital bleeding from the uterus that could not be controlled with uterotonic agents. Extravasation of the ruptured UAP was diagnosed using CT (Figure 1) and was also observed using color Doppler and CEU. The balloon was inserted into the uterine cavity and inflated at the point of bleeding using 30 to 200 mL of saline.²⁵ Bleeding was successfully stopped in all cases. In two of three patients, extravasation ceased using UBT on the first attempt; however, UAP recurred after 7 and 11 days, respectively. The patients were informed about the possibility of the need for repeat UBT or for hysterectomy or uterine artery embolization. UBT was attempted again for both patients, and the balloons were inserted into the uterine cavity again. Gross bleeding

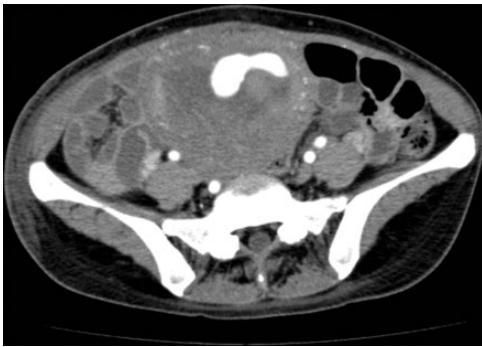


Figure 1. Computed tomography image of a ruptured uterine artery pseudoaneurysm. Contrast agent was extravasated toward the uterine cavity.

ceased in one patient; however, slight extravasation was observed using CEU. Therefore, an extra 20 mL of saline was added to the balloon (Video 1 (available as online supplementary materials)). The balloons were deflated and removed at least 2 days after insertion, and obliteration of UAP was confirmed using magnetic resonance imaging (MRI) (Figure 2). No complications were observed in any cases. All patients were followed up in the outpatient clinic, and none of them developed recurrent UAP.

Discussion

To our knowledge, this is the first report to describe the use of UBT to control ruptured UAP using CEU. The moment when hemostasis was achieved was captured using video imaging. Compared with CT or MRI, CEU can be used at the bedside for prompt diagnosis of UAP. The use of contrast agent during ultrasonography has an obvious advantage given that the latter two patients did not undergo CT before balloon tamponade because the extravasations were obvious with CEU, and CT would have taken more time with an increase in the amount of bleeding. (However, MRI was performed to confirm obliteration of the ruptured pseudoaneurysm [imaging data not shown]).

The mechanism of hemostasis in UBT is believed to involve direct compression of the pseudoaneurysm by the balloon at the bleeding point, leading to coagulation at the rupture point. A ruptured UAP usually exhibits extravasation at a single rupture point with massive arterial bleeding. The conventional UBT method involves blind insertion of the balloon into the uterine cavity without direct confirmation of the balloon actually contacting the bleeding point. As such, UBT performed with CEU guidance can address these time-consuming problems.

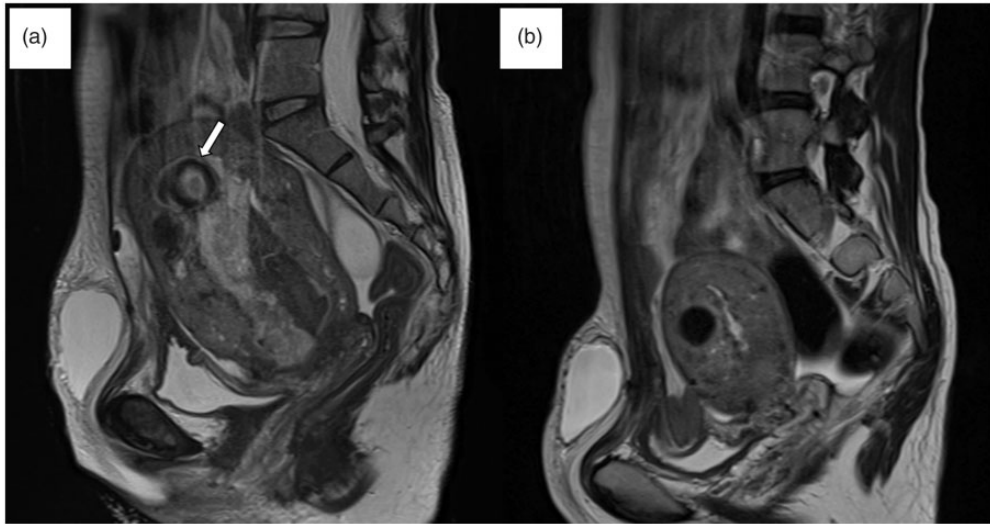


Figure 2. Magnetic resonance (MR) image of a uterine artery pseudoaneurysm (UAP). (a) MR image captured 2 days before UAP (arrow) rupture. (b) MR image captured 9 days after UAP rupture. No pseudoaneurysm is apparent. A uterine myoma is evident at the anterior wall of the uterus.

This study had several limitations, the first of which was the small number of patients. Second, contrast agents are difficult to observe in detail unless a dedicated contrast mode is used in a dedicated ultrasound device. One limitation of color Doppler is its low sensitivity to detect extravasation compared with CEU. Color Doppler loses track of slow-flowing blood; thus, the sensitivity of the color Doppler mode is limited to approximately 5 to 10 cm/s for slow-flow measurement. CEU can detect slow blood flow that is otherwise imperceptible on gross examination without CEU. Moreover, detectability is very low for blood flowing in a direction perpendicular to the probe. Although CT, MRI, and angiography have higher detection capability than color Doppler, they are difficult to perform in all facilities, especially during night shifts and/or off-peak hours. Moreover, these imaging modalities are time-consuming. Conversely, contrast

agents are clearly visualized with slow blood flow in any direction; thus, it is easier to identify the rupture point than when using any other method.

In conclusion, CEU can be used to locate the bleeding site of a ruptured UAP at the bedside, and hemostasis can be confirmed using UBT.

Acknowledgment

The authors thank Hitachi Aloka Medical, Ltd., Japan for calibrating the HI VISION Preirus ultrasound device.

Declaration of conflicting interest

The authors declare that there is no conflict of interest.

Funding

This research received no specific grant from any funding agency in the public, commercial, or not-for-profit sectors.

ORCID iD

Jun Takeda  <https://orcid.org/0000-0002-6195-8971>

Supplemental material

Supplemental material for this article is available online.

References

1. Goldrath MH. Uterine tamponade for the control of acute uterine bleeding. *Am J Obstet Gynecol* 1983; 147: 869–872.
2. Tindell K, Garfinkel R, Abu-Haydar E, et al. Uterine balloon tamponade for the treatment of postpartum haemorrhage in resource-poor settings: a systematic review. *BJOG* 2013; 120: 5–14.
3. Doumouchtsis SK, Papageorghiou AT and Arulkumaran S. Systematic review of conservative management of postpartum hemorrhage: what to do when medical treatment fails. *Obstet Gynecol Surv* 2007; 62: 540–547.
4. Georgiou C. Balloon tamponade in the management of postpartum haemorrhage: a review. *BJOG* 2009; 116: 748–757.
5. Georgiou C. A review of current practice in using balloon tamponade technology in the management of postpartum haemorrhage. *Hypertens Res Pregnancy* 2014; 2: 1–10.
6. World Health Organization. *WHO recommendations for the prevention and treatment of postpartum haemorrhage*. 2012, https://apps.who.int/iris/bitstream/handle/10665/75411/9789241548502_eng.pdf?sequence=1 (accessed 13 December 2019).
7. Committee on Practice Bulletins-Obstetrics. Practice Bulletin No. 183: Postpartum Hemorrhage. *Obstet Gynecol* 2017; 130: e168–e186.
8. RCOG Green-top Guideline. Prevention and Management of Postpartum Haemorrhage: Green-top Guideline No. 52. *BJOG* 2017; 124: e106–e149.
9. Lalonde A. International Federation of Gynecology and Obstetrics. Prevention and treatment of postpartum hemorrhage in low-resource settings. *Int J Gynaecol Obstet* 2012; 117: 108–118.
10. Leduc D, Senikas V, Lalonde AB, et al.; Clinical Practice Obstetrics Committee; Society of Obstetricians and Gynaecologists of Canada. Active management of the third stage of labour: prevention and treatment of postpartum hemorrhage. *J Obstet Gynaecol Can* 2009; 31: 980–993.
11. Son M, Einerson BD, Schneider P, et al. Is there an association between indication for intrauterine balloon tamponade and balloon failure? *Am J Perinatol* 2017; 34: 164–168.
12. Matsubara S, Baba Y and Takahashi H. Preventing a Bakri balloon from sliding out during “holding the cervix”: “fishing for the balloon shaft” technique (Matsubara). *Acta Obstet Gynecol Scand* 2015; 94: 910–911.
13. Matsubara S, Kuwata T, Usui R, et al. ‘Holding the cervix’ technique for postpartum hemorrhage for achieving hemostasis as well as preventing prolapse of an intrauterine balloon. *J Obstet Gynaecol Res* 2013; 39: 1116–1117.
14. Kawamura A, Kondoh E, Hamanishi J, et al. Cervical clamp with ring forceps to prevent prolapse of an intrauterine balloon in the management of postpartum hemorrhage. *J Obstet Gynaecol Res* 2013; 39: 733–737.
15. Makino S, Hirai C, Itakura A, et al. Evaluation of uterine blood flow: a new method using contrast-enhanced ultrasound. *Eur J Obstet Gynecol Reprod Biol* 2015; 191: 143–144.
16. Trillaud H, Bruel JM, Valette PJ, et al. Characterization of focal liver lesions with SonoVue-enhanced sonography: international multicenter-study in comparison to CT and MRI. *World J Gastroenterol* 2009; 15: 3748–3756.
17. Strobel D, Bernatik T, Blank W, et al. Diagnostic accuracy of CEUS in the differential diagnosis of small (≤ 20 mm) and subcentimetric (≤ 10 mm) focal liver lesions in comparison with histology: results of the DEGUM multicenter trial. *Ultraschall Med* 2011; 32: 593–597.
18. Sporea I, Badea R, Popescu A, et al. Contrast-enhanced ultrasound (CEUS) for the evaluation of focal liver lesions: a prospective multicenter study of its usefulness in clinical practice. *Ultraschall Med* 2014; 35: 259–266.

19. Calabrese E, Catalano O, Nunziata A, et al. Bedside contrast enhanced sonography of critically ill patients. *J Ultrasound Med* 2014; 33: 1685–1693.
20. Tang S, Wang Y and Wang Y. Contrast-enhanced ultrasonography to diagnose gallbladder perforation. *Am J Emerg Med* 2013; 31: 1240–1243.
21. You JS, Chung YE, Lee HJ, et al. Liver trauma diagnosis with contrast-enhanced ultrasound: interobserver variability between radiologist and emergency physician in an animal study. *Am J Emerg Med* 2012; 30: 1229–1234.
22. Satija B, Kumar S, Duggal RK, et al. Deep circumflex iliac artery pseudoaneurysm as a complication of paracentesis. *J Clin Imaging Sci* 2012; 2: 10.
23. Mou Y, Xu Y, Hu Y, et al. Giant uterine artery pseudoaneurysm after a missed miscarriage termination in a cesarean scar pregnancy. *BMC Womens Health* 2014; 14: 89.
24. Yorifuji T, Takeda J, Makino S, et al. Evaluation of the effectiveness of metreurynters for balloon tamponade. *Hypertens Res Pregnancy* 2018; 6: 26–29.
25. Takeda J, Makino S, Hirai C, et al. Long-term uterine balloon tamponade for treatment and obliteration of ruptured uterine pseudoaneurysm. *Taiwan J Obstet Gynecol* 2018; 57: 329–331.