

# Image quality-based dose optimization in pediatric cone-beam computed tomography: A pilot methodological study

Hak-Sun Kim<sup>1,2</sup>, Yoon Joo Choi<sup>1</sup>, Kug Jin Jeon<sup>1</sup>, Sang-Sun Han<sup>1</sup>, Chena Lee<sup>1,\*</sup>

<sup>1</sup>Department of Oral and Maxillofacial Radiology, Yonsei University College of Dentistry, Seoul, Korea

<sup>2</sup>Department of Oral and Maxillofacial Radiology, Kyung Hee University Dental Hospital, Seoul, Korea

## ABSTRACT

**Purpose:** This study aimed to propose a methodological approach for reducing the radiation dose in pediatric cone-beam computed tomography (CBCT), focusing exclusively on balancing image quality with dose optimization.

**Materials and Methods:** The dose-area product (DAP) for exposure was reduced using copper-plate attenuation of an X-ray source. The thickness of copper (Cu) was increased from 0 to 2.2 mm, and 10 different DAP levels were used. The QUART DVT\_AP phantom and pediatric radiologic dentiform were scanned under the respective DAP levels. The contrast-to-noise ratio (CNR), image homogeneity, and modulation transfer function (MTF) were analyzed using the QUART DVT\_AP phantom. An expert evaluation (overall image grade, appropriateness of field of view, artifacts, noise, and resolution) was conducted using pediatric dentiform images. The critical DAP level was determined based on phantom and dentiform analysis results.

**Results:** CNR and image homogeneity decreased as the DAP was reduced; however, there was an inflection point of image homogeneity at Cu 1.6 mm (DAP = 138.00 mGy · cm<sup>2</sup>), where the value started increasing. The MTF showed constant values as the DAP decreased. The expert evaluation of overall image grades showed “no diagnostic value” for dentiform images with Cu 1.9-2.2 mm (DAP = 78.00-103.33 mGy · cm<sup>2</sup>). The images with Cu 0-1.6 mm (DAP = 138.00-1697.67 mGy · cm<sup>2</sup>) had a “good,” “moderate,” or “poor but interpretable” grade.

**Conclusion:** Reducing DAP beyond a 1.6-mm Cu thickness degraded CBCT image quality. Image homogeneity and clinical image grades indicated crucial decision points for DAP reduction in pediatric CBCT scans. (*Imaging Sci Dent* 2024; 54: 264-70)

**KEY WORDS:** Radiation Protection; Radiation Dosage; Cone-Beam Computed Tomography; Dose Reduction

## Introduction

Cone-beam computed tomography (CBCT) was first developed in the late 1990s.<sup>1,2</sup> Compared to conventional multi-detector computed tomography (MDCT), CBCT offers a smaller voxel size and a lower effective dose. These features make it ideal for high-definition visualization of the 3-dimensional aspects of the oral and maxillofacial regions.<sup>3-11</sup> Applications of this technique include root canal visualization;<sup>3</sup> the localization of normal anatomical struc-

tures,<sup>4</sup> jaw lesions,<sup>5,6</sup> and impacted teeth;<sup>7,8</sup> temporomandibular joint evaluations,<sup>9</sup> and other clinical purposes.<sup>10,11</sup>

CBCT is preferred over MDCT for evaluating hard tissue in the oral and maxillofacial region due to the need to adhere to the as low as reasonably achievable (ALARA) principle in radiation protection, because CBCT delivers a significantly lower effective dose than MDCT for the same field of view.<sup>12-14</sup> This benefit is especially important for pediatric patients, who are more vulnerable to radiation due to their ongoing development.<sup>15,16</sup> Typically, pediatric patients undergo CBCT examinations to localize impacted teeth and assess conditions such as cleft palate or complex skeletal abnormalities that require surgical intervention.<sup>17</sup> Some studies have reported that restricting the field of view (FOV) to closely match the region of interest may actually increase the radiation dose.<sup>14,18</sup> Therefore, instead of reducing the

This research was supported by the 2023 Yonsei University College of Dentistry student research grant.

Received February 19, 2024; April 16, 2024, 2023; Accepted April 26, 2024

Published online July 2, 2024

\*Correspondence to : Prof. Chena Lee

Department of Oral and Maxillofacial Radiology, Yonsei University, College of Dentistry, 50-1 Yonsei-ro, Seodaemun-gu, Seoul 03722, Korea  
Tel) 82-2-2228-3124, E-mail) chenalee@yuhs.ac

Copyright © 2024 by Korean Academy of Oral and Maxillofacial Radiology

This is an Open Access article distributed under the terms of the Creative Commons Attribution Non-Commercial License (<http://creativecommons.org/licenses/by-nc/3.0>) which permits unrestricted non-commercial use, distribution, and reproduction in any medium, provided the original work is properly cited.

Imaging Science in Dentistry · pISSN 2233-7822 eISSN 2233-7830

FOV, efforts should focus on minimizing the radiation dose to a level that still yields acceptable and accurate CBCT images.

Studies have been conducted to reduce the radiation dose in CBCT without compromising image quality. Some approaches have involved directly adjusting the unit's parameters<sup>19-21</sup> or applying a mathematically calculated minimum level of current.<sup>22</sup> Other studies have increased filtration for dose reduction.<sup>23-25</sup> However, manipulating the parameters or structure of the CBCT unit is not feasible in real clinical settings. Furthermore, no study has yet described a methodological approach for reducing the radiation dose of CBCT without manipulating its parameters.


This study was conducted to propose a methodological approach aimed at reducing the radiation dose in pediatric CBCT, with a specific focus on balancing image quality and dose optimization.

## Materials and Methods


Copper (Cu) plates in 10 different thicknesses, ranging from 0-2.2 mm, were attached to the X-ray source of a CBCT

system (Rayscan Alpha Plus, Ray Co., Seongnam, Korea) to investigate their effect on radiation dose (Fig. 1). The manufacturer's recommended exposure settings were used for the jaw mode: 90 kVp, 12 mA, and a 10 × 10 cm FOV. This imaging mode is commonly used for pediatric patients, as noted in a previous study and at the authors' affiliated institution.<sup>26</sup> The Cu plate was used to attenuate the radiation dose, rather than adjusting the tube voltage, tube current, or exposure time, because CBCT units do not permit users to freely control the exposure conditions in a clinical setting. As each Cu plate was attached to the X-ray source, the dose-area-product (DAP) was measured 3 times using the VacuDAP standard (VacuTec Meßtechnik GmbH, Dresden, Germany), and the mean value was recorded (Table 1).

For quantitative analysis, 3 sets of CBCT images were acquired at varying thicknesses of Cu plates using the QUART DVT\_AP phantom (QUART, Zorneding, Germany). This phantom is specifically designed to conform to a standard dedicated to dental CBCT<sup>27</sup> and is utilized for CBCT quality control (Fig. 2A). The images were analyzed with QUART DVT\_TEC software (QUART, Zorneding, Germany) by 2 observers. They assessed image homogeneity,



**Fig. 1.** The tube of the cone-beam computed tomography unit used in this study. A. The tube without any copper attenuation. B. The tube with a copper plate attached.



**Fig. 2.** The QUART DVT\_AP phantom (QUART, Zorneding, Germany) and cone-beam computed tomography image analysis. A. Top view of the phantom. B. Image homogeneity. C. Contrast-to-noise ratio. D. Modulation transfer function analysis by QUART DVT\_TEC software (QUART, Zorneding, Germany).

the contrast-to-noise ratio (CNR), and modulation transfer function (MTF) for each attenuation set, and the mean values were recorded as representative (Fig. 2B-D). Image homogeneity refers to the variation between basic contrast and background changes in a specified ROI, with an ideal homogeneity value for a homogeneous slice being 0.

CBCT images of a pediatric radiologic dentiform (Columbia Dentoform; Lancaster, PA, USA) were acquired for all attenuations (Fig. 3). Three experts, each with over 5 years of experience, assessed the images using the clinical image evaluation chart (Table 2), and the mean scores were used to determine the acceptable CBCT images. The evaluation chart was adapted from previous literature to address differ-

ences in study objectives.<sup>28,29</sup> It includes 5 criteria: FOV, artifacts, noise, resolution, and overall image grade. The first 4 criteria were scored on a 3-point scale: 1-disagree, 2-neutral, and 3-agree. The overall image grade was rated on a 4-point scale: 1-no diagnostic value, 2-poor but interpretable, 3-moderate, and 4-good.

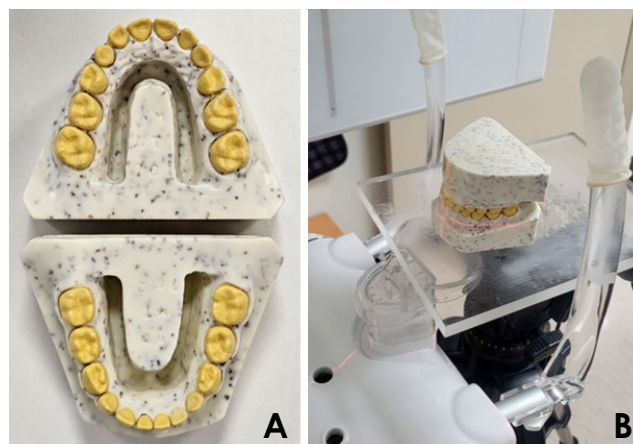
The results of all evaluations were descriptively analyzed to identify the CBCT image that was interpretable with the lowest radiation dose.

### Results

Image homogeneity initially decreased with lower DAP values (corresponding to decreasing copper plate thickness)

**Table 1.** Selected thicknesses of copper attenuation and their mean dose-area-product (DAP) values for image quality evaluation

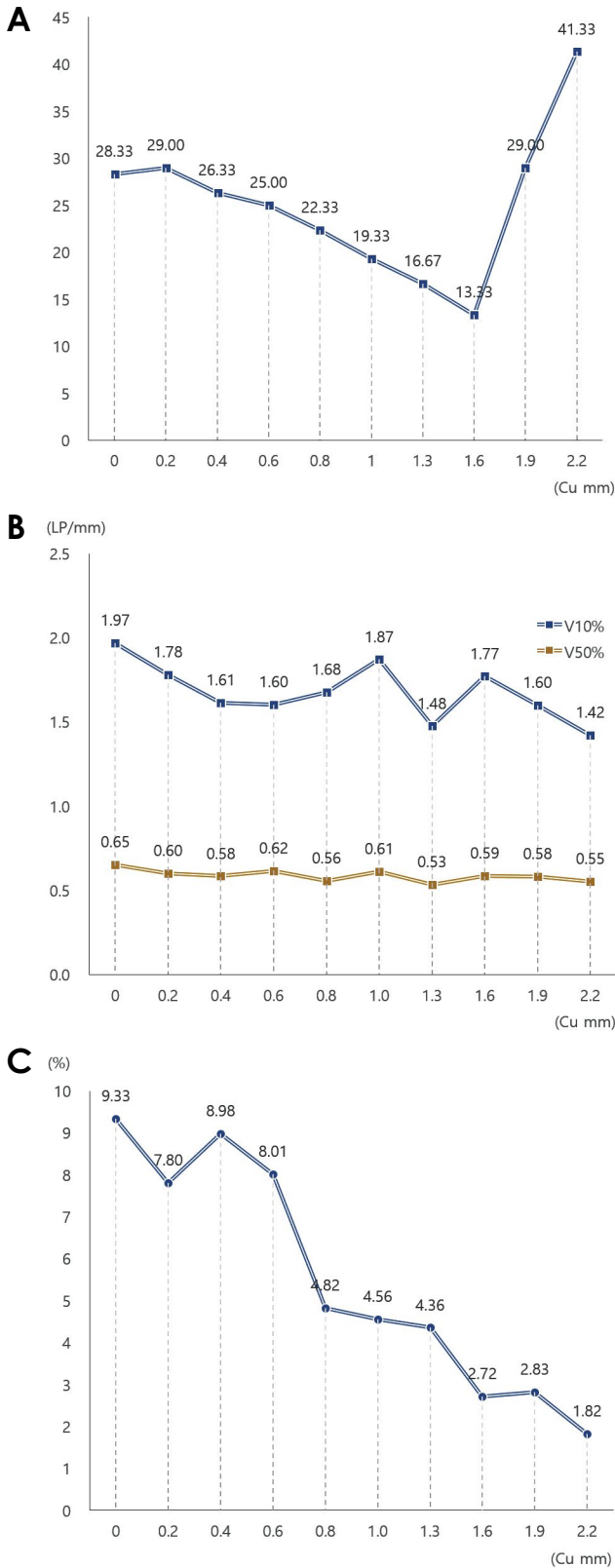
	Copper thickness (mm)	Mean DAP (mGy · cm <sup>2</sup> )	Dose percentage to the standard (%)
Standard	0.0	1697.67	100
1	0.2	1093.00	64
2	0.4	745.00	44
3	0.6	540.33	32
4	0.8	409.00	24
5	1.0	267.67	16
6	1.3	188.67	11
7	1.6	138.00	8
8	1.9	103.33	6
9	2.2	78.00	5



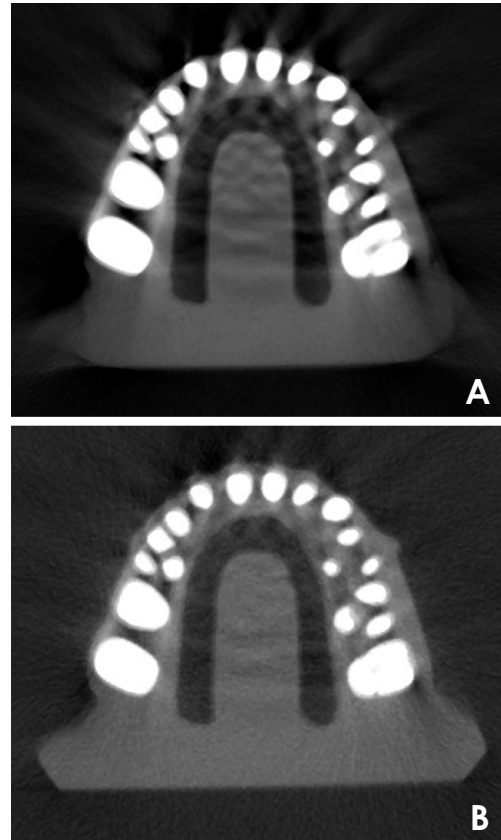
**Fig. 3.** A. The pediatric radiologic dentiform. B. Positioning the dentiform in the cone-beam computed tomography unit.

**Table 2.** Clinical cone-beam computed tomographic image evaluation chart

Criteria	Disagree (1)	Neutral (2)	Agree (3)
Field of view			
– The region of interest is completely included within the field of view			
Artifacts			
– Streak artifact is not significant			
– Ring artifact is not visible			
– Motion artifact is not significant			
Noise			
– Noise is not significant			
Resolution			
– Density and contrast are acceptable			
– Teeth and alveolar bone are clearly distinguishable			
	No diagnostic value (1)	Poor but interpretable (2)	Moderate (3)
			Good (4)
Overall image grade			



**Fig. 4.** Quantitative evaluation results from the QUART DVT\_AP phantom. A. Homogeneity decreases until a copper (Cu) thickness of 1.6 mm, and then increases. B. Modulation transfer function shows almost constant values. C. The contrast-to-noise ratio shows decreasing tendency.



**Fig. 5.** Cone-beam computed tomography images of the dentiform with a copper thickness of A. 0 mm and B. 1.6 mm. More image noise is observed due to added copper attenuation.

until it reached a minimum at a Cu thickness of 1.6 mm ( $DAP = 138.00 \text{ mGy} \cdot \text{cm}^2$ ), after which it began to increase (Fig. 4A). The 10% and 50% modulation transfer ratios in the MTF remained nearly constant (Fig. 4B). The CNR exhibited a decreasing trend as the DAP values decreased with increasing thickness of the Cu plate (Fig. 4C).

The mean overall grades for copper thicknesses ranging from 0 to 1.6 mm were categorized as “poor but interpretable” or better (Table 3). Specifically, the average scores for the FOV were consistently 3.00 across all copper thicknesses. The scores for noise and resolution fell within the “neutral” range or higher for copper thicknesses of 0-1.6 mm and 0-1.9 mm, respectively. Artifacts were observed in all CBCT images across all examined levels. Figure 5 displays examples of CBCT images of the dentiform with copper thicknesses of 0 and 1.6 mm.

### Discussion

This study aimed to propose a methodological approach for reducing the radiation dose in pediatric CBCT. It partic-

**Table 3.** The mean scores of clinical image evaluation of cone-beam computed tomography images at all copper thicknesses (dose-area-product reduction levels). The highest score for the field of view, artifacts, noise, and resolution was 3, and that of the overall image grade was 4

Copper thickness (mm)	Field of view	Artifacts	Noise	Resolution	Overall image grade
0.00	3.00	1.33	3.00	2.67	3.00
0.20	3.00	1.33	3.00	2.67	3.00
0.40	3.00	1.33	2.67	2.67	3.00
0.60	3.00	1.33	2.33	2.33	2.33
0.80	3.00	1.33	2.33	2.00	2.00
1.00	3.00	1.33	2.33	2.00	2.00
1.30	3.00	1.33	2.00	2.33	2.00
1.60	3.00	1.33	1.67	1.67	1.67
1.90	3.00	1.33	1.33	1.67	1.33
2.20	3.00	1.67	1.33	1.33	1.33

ularly focused on finding a balance between image quality and radiation dose to optimize pediatric CBCT doses. Since the dose cannot be reduced indefinitely, the study sought to identify the threshold at which the DAP could no longer be decreased without compromising image quality. A major strength of this study is its identification of critical factors that should be considered in the dose optimization process. Evaluation factors such as image homogeneity and expert assessments of image quality were crucial in determining the points at which further reductions in radiation dose could be made. Based on the image homogeneity and expert clinical image evaluation scores, a significant reduction in the DAP is achievable in pediatric CBCT. Based on the analysis of the pediatric radiologic dentiform, the current study proposes that DAP reduction could be achieved with a Cu thickness of 1.6 mm and a DAP of  $138.00 \text{ mGy} \cdot \text{cm}^2$ .

An intriguing finding was that image homogeneity alone offered a clear criterion for selecting the optimal DAP level during dose reduction, whereas other factors such as CNR and MTF had little impact on this decision. The CNR exhibited a general downward trend as attenuation increased, making it challenging to specify an appropriate Cu thickness. However, the CNR significantly dropped when the DAP level reached 24–32% of the standard, corresponding with a decline in the resolution score from expert evaluations. More detailed and objective studies are needed to explore the relationships between DAP, CNR, and image quality.

Contrary to the initial expectations that decreasing DAP and increasing noise would alter the results, the MTF—a detector specification that reflects its spatial resolution—remained remarkably constant for both 10% and 50% modulation transfer ratios throughout the experiment. This stability likely stems from the inherent characteristics of

the detector, which remained unchanged during the experiment.

Image homogeneity, which is a factor in image quality assurance, initially showed a decreasing trend similar to the CNR. However, after reaching a certain DAP level, it began to increase, leading to the establishment of a dose reduction threshold at this DAP level. Initially, it was anticipated that image homogeneity would continue to decrease, akin to the CNR. Yet, the outcomes were different, and several reasons for this can be inferred from the dose-reduction techniques employed in this study. Unlike previous studies that adjusted exposure parameters,<sup>20–22</sup> this study implemented the use of Cu plates to reduce dosage, effectively blocking scattered low-energy radiation at a specific Cu thickness. Consequently, for pediatric CBCT dose optimization, varying the thickness of Cu filtration could be considered as an alternative to directly altering exposure parameters. Collaboration with the CBCT manufacturer is crucial for developing a convertible Cu filtration device suitable for pediatric patients in real clinical settings.

Some studies on dose reduction of CBCT have focused on adjusting the exposure parameters (kVp, mAs), and 2 studies decreased the dose to less than 20%<sup>20</sup> or approximately 40%<sup>21</sup> of the standard CBCT protocols without significantly affecting image quality. To reduce the current (mAs), a study modulated the tube current to calculate the optimal current for each location of the tube and lowered the dose by 31%.<sup>22</sup> Because ethical considerations preclude direct dose reduction experiments in humans, another study attempted to simulate ultra-low-dose CBCT images by adding noise to existing low-dose patient scans, achieving a significant dose reduction. However, while this approach successfully lowered the dose, to the best of the authors'



knowledge, no research has yet employed quality control phantoms for comprehensive image quality evaluation in such scenarios. In most studies, evaluations were conducted either using subjective scoring, similar to the clinical image evaluation in this study,<sup>19,21</sup> or other quantitative evaluations.<sup>22</sup> One study also conducted subjective and quantitative image evaluations, somewhat similar to this study, but it differed in that a quality control phantom was used, and the analysis software was specifically developed for that phantom.<sup>30</sup> Furthermore, direct adjustments of exposure parameters for specific circumstances are not permitted in real clinical settings.

Some studies have added Cu filtration, similar to this study.<sup>23-25</sup> However, one such study utilized only a contrast phantom and limited its image quality evaluation to CNR assessment.<sup>23</sup> Another study also employed Cu filtration but did not measure the actual radiation dose nor use a standardized phantom.<sup>24</sup> Furthermore, the range of Cu thicknesses employed in these studies was narrower than that used in this study.<sup>23-25</sup>

This study has several limitations, primarily because it was conducted as a pilot study aimed at demonstrating a methodological approach for balancing dose reduction with image quality. Firstly, the pediatric phantom used for clinical image evaluation did not include facial bones or soft tissue structures. While the pediatric dentiform was designed for radiological assessments, the lack of comprehensive facial structures could significantly affect X-ray attenuation and image quality. Consequently, the actual reduction in DAP might be less than what was observed in this study. Future studies should evaluate CBCT images of anthropomorphic phantoms that fully replicate soft tissue and cranial bones at various DAP levels. Additionally, the proposed DAP reduction level only supports the lowest quality image sufficient to distinguish between teeth and alveolar bones; thus, the minimal DAP might need to be increased depending on the specific objectives of the CBCT examination.

In conclusion, this study demonstrates that in pediatric CBCT, the radiation dose can be significantly reduced below typical clinical levels. For radiologic evaluations of dental form, Cu plate thicknesses of up to 1.6 mm can be used while still maintaining interpretable image quality, as determined by key indicators such as image homogeneity and clinical image grade. When adjusting exposure conditions to reduce the dose, image homogeneity and expert evaluation should be considered critical factors to ensure the images remain readable.

**Conflicts of Interest:** None

## Acknowledgments

The authors would like to thank Hoyoung Seo, Yong Hyun Lee, Jiwoo An, and Youjin Jung for assisting with the experiment as part of a student research grant from the Yonsei University College of Dentistry.

## References

1. Mozzo P, Procacci C, Tacconi A, Martini PT, Andreis IA. A new volumetric CT machine for dental imaging based on the cone-beam technique: preliminary results. *Eur Radiol* 1998; 8: 1558-64.
2. Arai Y, Tammissalo E, Iwai K, Hashimoto K, Shinoda K. Development of a compact computed tomographic apparatus for dental use. *Dentomaxillofac Radiol* 1999; 28: 245-8.
3. Lamira A, Mazzi-Chaves JF, Nicolielo LF, Leoni GB, Silva-Sousa AC, Silva-Sousa YT, et al. CBCT-based assessment of root canal treatment using micro-CT reference images. *Imaging Sci Dent* 2022; 52: 245-58.
4. Jain S, Choudhary K, Nagi R, Shukla S, Kaur N, Grover D. New evolution of cone-beam computed tomography in dentistry: combining digital technologies. *Imaging Sci Dent* 2019; 49: 179-90.
5. Loureiro RM, Sumi DV, Tames HL, Ribeiro SP, Soares CR, Gomes RL, et al. Cross-sectional imaging of third molar-related abnormalities. *AJNR Am J Neuroradiol* 2020; 41: 1966-74.
6. Cuschieri LA, Schembri-Higgans R, Bezzina N, Betts A, Cortes AR. Importance of 3-dimensional imaging in the early diagnosis of chondroblastic osteosarcoma. *Imaging Sci Dent* 2023; 53: 247-56.
7. Pakbaznejad Esmaeili E, Ilo AM, Waltimo-Sirén J, Ekholm M. Minimum size and positioning of imaging field for CBCT scans of impacted maxillary canines. *Clin Oral Investig* 2020; 24: 897-905.
8. Ilo AM, Ekholm M, Pakbaznejad Esmaeili E, Waltimo-Sirén J. Minimum size and positioning of imaging field for CBCT-scans of impacted lower third molars: a retrospective study. *BMC Oral Health* 2021; 21: 670.
9. Augdal TA, Angenete OW, Shi XQ, Säll M, Fischer JM, Nordal E, et al. Cone beam computed tomography in the assessment of TMJ deformity in children with JIA: repeatability of a novel scoring system. *BMC Oral Health* 2023; 23: 12.
10. Tyndall DA, Price JB, Tetradis S, Ganz SD, Hildebolt C, Scarfe WC, et al. Position statement of the American Academy of Oral and Maxillofacial Radiology on selection criteria for the use of radiology in dental implantology with emphasis on cone beam computed tomography. *Oral Surg Oral Med Oral Pathol Oral Radiol* 2012; 113: 817-26.
11. Schulze RK, Drage NA. Cone-beam computed tomography and its applications in dental and maxillofacial radiology. *Clin Radiol* 2020; 75: 647-57.
12. Nardi C, Talamonti C, Pallotta S, Saletti P, Calistri L, Cordopatri C, et al. Head and neck effective dose and quantitative

- assessment of image quality: a study to compare cone beam CT and multislice spiral CT. *Dentomaxillofac Radiol* 2017; 46: 20170030.
13. Han M, Kim HJ, Choi JW, Park DY, Han JG. Diagnostic usefulness of cone-beam computed tomography versus multi-detector computed tomography for sinonasal structure evaluation. *Laryngoscope Investig Otolaryngol* 2022; 7: 662-70.
  14. Ludlow JB, Ivanovic M. Comparative dosimetry of dental CBCT devices and 64-slice CT for oral and maxillofacial radiology. *Oral Surg Oral Med Oral Pathol Oral Radiol Endod* 2008; 106: 106-14.
  15. Seibold P, Auvinen A, Averbek D, Bourguignon M, Hartikainen JM, Hoeschen C, et al. Clinical and epidemiological observations on individual radiation sensitivity and susceptibility. *Int J Radiat Biol* 2020; 96: 324-39.
  16. Pierce DA, Shimizu Y, Preston DL, Vaeth M, Mabuchi K. Studies of the mortality of atomic bomb survivors. Report 12, Part I. Cancer: 1950-1990. *Radiat Res* 1996; 146: 1-27.
  17. Yiğit T, Yüksel HT, Evirgen Ş, Kaçmaz I, Türkmenoğlu A. Evaluation of use of cone beam computed tomography in paediatric patients: a cross-sectional study. *Int J Paediatr Dent* 2023; 33: 468-76.
  18. Pauwels R, Beinsberger J, Collaert B, Theodorakou C, Rogers J, Walker A, et al. Effective dose range for dental cone beam computed tomography scanners. *Eur J Radiol* 2012; 81: 267-71.
  19. Bryce-Atkinson A, de Jong R, Bel A, Aznar MC, Whitfield G, van Herk M. Evaluation of ultra-low-dose paediatric cone-beam computed tomography for image-guided radiotherapy. *Clin Oncol (R Coll Radiol)* 2020; 32: 835-44.
  20. Olch AJ, Alaei P. How low can you go? A CBCT dose reduction study. *J Appl Clin Med Phys* 2021; 22: 85-9.
  21. Oenning AC, Pauwels R, Stratis A, De Faria Vasconcelos K, Tijssens E, de Grauwe A, et al. Halve the dose while maintaining image quality in paediatric cone beam CT. *Sci Rep* 2019; 9: 5521.
  22. Son K, Chang J, Lee H, Kim C, Lee T, Cho S, et al. Optimal dose reduction algorithm using an attenuation-based tube current modulation method for cone-beam CT imaging. *PLoS One* 2018; 13: e0192933.
  23. Kuramoto T, Takarabe S, Shiotsuki K, Shibayama Y, Hamasaki H, Akamine H, et al. X-ray dose reduction using additional copper filtration for dental cone beam CT. *Phys Med* 2021; 81: 302-7.
  24. Houffrar J, Ludwig B, Bister D, Nienkemper M, Abkai C, Venugopal A. The effects of additional filtration on image quality and radiation dose in cone beam CT: an in vivo preliminary investigation. *Biomed Res Int* 2022; 2022: 7031269.
  25. Ludlow JB. A manufacturer's role in reducing the dose of cone beam computed tomography examinations: effect of beam filtration. *Dentomaxillofac Radiol* 2011; 40: 115-22.
  26. Ismanyılov R, Özgür B. Indications and use of cone beam computed tomography in children and young individuals in a university-based dental hospital. *BMC Oral Health* 2023; 23: 1033.
  27. de Las Heras Gala H, Torresin A, Dasu A, Rampado O, Delis H, Hernández Girón I, et al. Quality control in cone-beam computed tomography (CBCT) EFOMP-ESTRO-IAEA protocol (summary report). *Phys Med* 2017; 39: 67-72.
  28. Choi H, Yun JP, Lee A, Han SS, Kim SW, Lee C. Deep learning synthesis of cone-beam computed tomography from zero echo time magnetic resonance imaging. *Sci Rep* 2023; 13: 6031.
  29. Ryu K, Lee C, Han Y, Pang S, Kim YH, Choi C, et al. Multi-planar 2.5D U-Net for image quality enhancement of dental cone-beam CT. *PLoS One* 2023; 18: e0285608.
  30. Hidalgo Rivas JA, Horner K, Thiruvengkatachari B, Davies J, Theodorakou C. Development of a low-dose protocol for cone beam CT examinations of the anterior maxilla in children. *Br J Radiol* 2015; 88: 20150559.