



Pre-shaped Allograft for Glenoid Reconstruction in Anterior Shoulder Instability

Mia Smucny, M.D., and Anthony Miniaci, M.D., F.R.C.S.C.

Abstract: Anteroinferior glenoid bone loss plays a significant role in recurrent glenohumeral instability. Current surgical strategies to reconstruct the glenoid include coracoid transfer (Bristow-Latarjet procedure), iliac crest autograft, and allograft (osteochondral and iliac crest). These may carry drawbacks of technical difficulty, increased surgical time, neurovascular injury, and nonanatomic reconstruction. We report a technique to manage glenoid bone loss using a pre-shaped, predrilled allograft (Glenojet; Arthrosurface) that matches the native contour of the glenoid. The surgical technique and outcomes are described with an accompanying video and figures.

Anteroinferior glenoid bone loss plays a significant role in recurrent glenohumeral instability. Loss of greater than 25% of the inferior glenoid diameter contributes to an instability recurrence rate of 67% after arthroscopic capsulolabral reconstruction, versus just 4% in patients without significant bone loss.¹ Anteroinferior glenoid rim deficiency has been reported in up to 90% of cases of recurrent instability.² Thus, it has become the standard of care to perform glenoid reconstruction in patients with bone loss greater than 25% or in certain revision scenarios.³ The amount of bone loss can be determined from preoperative imaging such as magnetic resonance imaging or computed tomography, and a variety of methods for calculation of bone loss have been described. Physical examination may also be helpful in determining significant osseous deficiency because the patient may experience apprehension at less than 90° of abduction

and external rotation.⁴ Once it has been determined that bone loss should be addressed, glenoid reconstruction can be performed through coracoid transfer (Bristow-Latarjet procedure), iliac crest autograft, and allograft (osteochondral and iliac crest). These procedures all successfully restore stability of the glenohumeral joint. However, they may have drawbacks of increased operative time and surgical complexity, risk of neurovascular damage, or nonanatomic reconstruction and subsequent instability arthropathy.

We introduce a technique that uses a pre-shaped, predrilled allograft (Glenojet; Arthrosurface) to match the contour of the glenoid defect. The graft is simple to insert and can reduce the operative time. We present details on the graft, surgical technique for the graft, and outcomes based on our experience. We have reported our outcomes previously,⁵ but there are no other published data on the allograft at this time.

Surgical Technique

Video 1 shows the steps for graft preparation and insertion.

Graft Preparation

The Glenojet graft is a shaped human tissue cortical bone allograft, prepared from the proximal or distal tibia or femur. It is shaped and standardized by the manufacturer; thus, the graft preparation time required with other allograft techniques is reduced. There is no cartilage on the graft, but it is shaped to match the contour of the glenoid. The graft has a flat surface that will abut the glenoid and a concave surface that will be repaired to the capsule. It has predrilled holes for cortical screw placement and smaller holes for

From the Sports Health Center, Cleveland Clinic Foundation, Garfield Heights, Ohio, U.S.A.

The authors report the following potential conflict of interest or source of funding: M.S. receives support from Cleveland Clinic Foundation. Orthopaedic fellow in sports medicine. A.M. receives support from Arthrosurface, Trice Medical, Cleveland Clinic, Zimmer, Cleveland Clinic Innovations. Full ICMJE author disclosure forms are available for this article online, as [supplementary material](#).

Received April 3, 2017; accepted October 7, 2017.

Address correspondence to Anthony Miniaci, M.D., F.R.C.S.C., Sports Health Center, Cleveland Clinic Foundation, 5555 Transportation Blvd, Garfield Heights, OH 44125, U.S.A. E-mail: miniaca@ccf.org

© 2017 by the Arthroscopy Association of North America. Published by Elsevier. This is an open access article under the CC BY-NC-ND license (<http://creativecommons.org/licenses/by-nc-nd/4.0/>).

2212-6287/17506

<https://doi.org/10.1016/j.eats.2017.10.007>

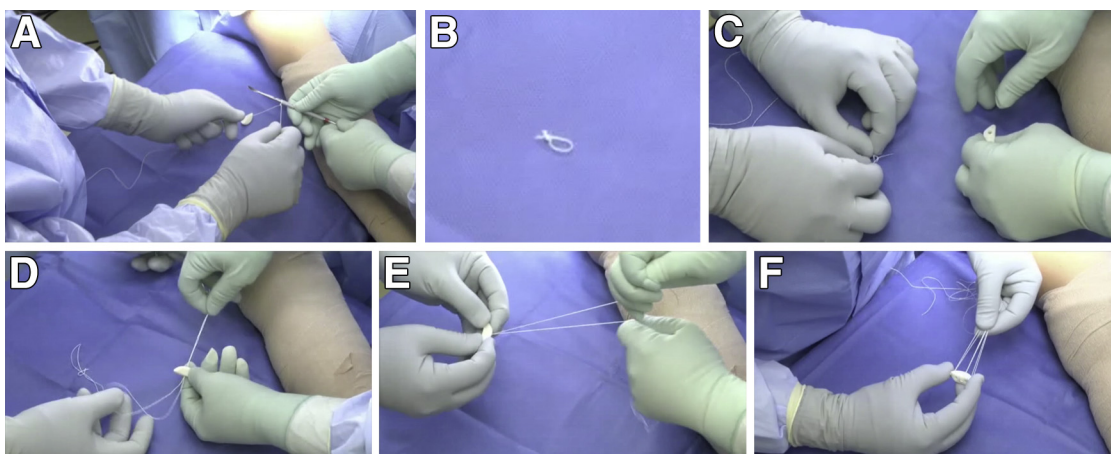


Fig 1. (A) To prepare the graft, a No. 2 FiberWire or equivalent suture is tied over a small object such as a freer elevator. (B) The freer is removed, and the tails of the knot are trimmed. (C) Another suture is threaded through the loop that has been created and is pulled so that its 2 long tails are even. (D) These tails are then threaded through 1 of the small holes of the graft, going from the flat side to the concave side. (E) The suture tails are pulled all the way through, including the loop of the prior knotted loop. The knot of the loop will prevent it from pulling through. The suture tails will then be able to slide as if they were attached to an anchor. (F) These steps are repeated for the remaining 2 small holes, such that there are 3 total sutures (6 suture tails) exiting the graft.

threading suture for capsule repair. It can be ordered in 2 different sizes according to the amount of bone loss: 10×29 mm or 13×34 mm. The smaller graft is more commonly used and reconstructs defects of 20% to 30% of the glenoid.

The sutures through the Glenojet graft can be prepared on the back table while the rest of the equipment is being set up (as shown in the first section of [Video 1](#), as well as [Fig 1](#)). A No. 2 FiberWire (Arthrex) or equivalent is tied over a small thin object such as a freer elevator. The freer is removed, and the tails of the knot are trimmed. Another suture is threaded through the loop that has been created and is pulled so that its 2 long tails are even. Then, these tails are threaded through 1 of the small holes of the graft, going from the flat side to the concave side; alternatively, the suture can be passed in the opposite direction if one prefers the capsule to be tied to the flat portion of the graft that abuts the glenoid defect. The suture tails are pulled all the way through, including the loop of the prior knotted loop. The knot of the loop will prevent it from pulling through. The suture tails will then be able to slide as if they were attached to an anchor. These steps are repeated for the remaining 2 small holes, such that there are 3 total sutures (6 suture tails) exiting the graft.

Preoperative Patient Positioning

The patient is placed in the beach-chair position at approximately 30° of elevation. A small folded towel may be placed behind the scapula as a bump to improve exposure. The entire arm is prepared and draped free. An arm holder may be used; however, we prefer to use a padded and sterilely draped rolling Mayo stand to support the arm.

Surgical Approach

A standard deltopectoral approach is used to expose the anterior glenoid. The subscapularis either can be split in line with its fibers or can be tenotomized with 1 to 2 cm attached to the tuberosity for later repair ([Fig 2](#)). The chosen approach will change postoperative care (as discussed later). In either instance, the muscle should be separated from the underlying capsule layer because the capsule will be directly repaired to the graft.

The capsule is carefully taken off the anterior glenoid ([Fig 3](#)). A Fukuda or similar retractor may be used on

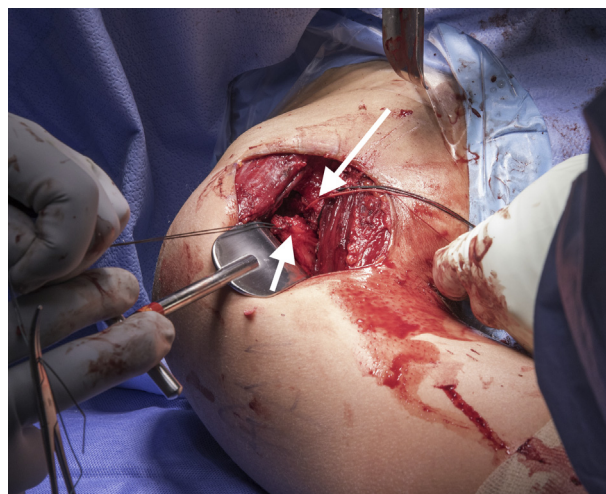


Fig 2. Exposure. Through a deltopectoral approach in a right shoulder (with the patient's head at the top of the image), the interval between the deltoid and pectoralis major muscle is developed. The subscapularis (long arrow) is taken off the humeral head and is separated from the capsular layer (short arrow).

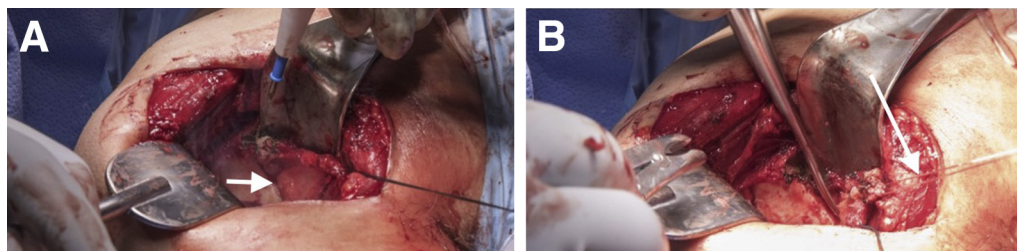


Fig 3. Removal of capsule and labrum. (A) The capsule (arrow) is carefully removed from the anterior glenoid, all the way to the anteroinferior glenoid. This can be achieved with a knife, electrocautery, or Cobb elevator. (B) Traction sutures (arrow) help maintain control of the capsule. A right shoulder is shown, with the patient's head at the top of the images.

the humerus, and a glenoid retractor should be placed on the anterior glenoid (under the capsule and subscapularis) for optimal exposure (Fig 4). Aggressive glenoid retraction and inferior dissection should be avoided to protect the musculocutaneous and axillary nerves (Table 1). A knife, electrocautery, or Cobb elevator is used to remove residual labrum or displaced bone fragments from the anterior glenoid. The entire anterior to anteroinferior glenoid must be exposed.

Recipient Site Preparation

Once the anterior glenoid surface has been exposed, the Glenojet drill guide is placed flush against the surface of the glenoid. The laser mark on the guide should be positioned in line with the anterior glenoid fracture plane, and the round portion of the guide should fit behind the humeral head (Fig 5). It is very important to confirm that the guide is flush and appropriately aligned because this ensures correct positioning, angulation, and alignment of the graft. The guide should be held securely while the 2 guide pins are being drilled (Fig 5). The pins are inserted until they are just past the posterior cortex of the glenoid (Fig 6).

The guide is removed, and a cannulated reamer is inserted over 1 of the guide pins. Reaming is performed until the pin's end appears in the viewing window of the reamer and hits the stop—this approximates the correct amount of bone to remove (Fig 7). This step is repeated for the second guide pin. Reaming flattens the anterior glenoid and allows for maximal stable apposition of the graft to the glenoid. Once reaming is complete, the anterior glenoid should be checked to ensure that it is smooth and even.

Graft Insertion, Capsule Repair, and Wound Closure

The Glenojet graft is inserted onto the pins in the correct orientation to match the surface of the native glenoid (Fig 8). The length of the superior guide pin is measured with the provided pin depth-gauge device. This pin is then removed, and a 3.5-mm cortical bone screw is inserted. Alternatively, the guide pin can be removed, and a standard depth gauge can be used to measure the appropriate screw length (Figs 9 and 10).

Once secure, this process is repeated for the inferior guide pin. The screws should have excellent bicortical fixation (Fig 11). The pins are an appropriate diameter to allow screw insertion without predrilling.

Once the graft is secure, the capsule is attached by use of a free needle on the preinserted suture of the graft. The capsule may be advanced as necessary for appropriate anterior soft-tissue tensioning (Fig 12). We prefer to work with the sutures from inferior to superior. After capsular repair, the subscapularis is repaired as necessary. The remainder of the wound is closed according to surgeon preference.

Postoperative Care

Postoperatively, the patient is placed in a shoulder immobilizer for 3 weeks at all times except when performing physical therapy and then it may be worn as needed. When subscapularis takedown and repair are performed, there is no limit on active-assisted forward

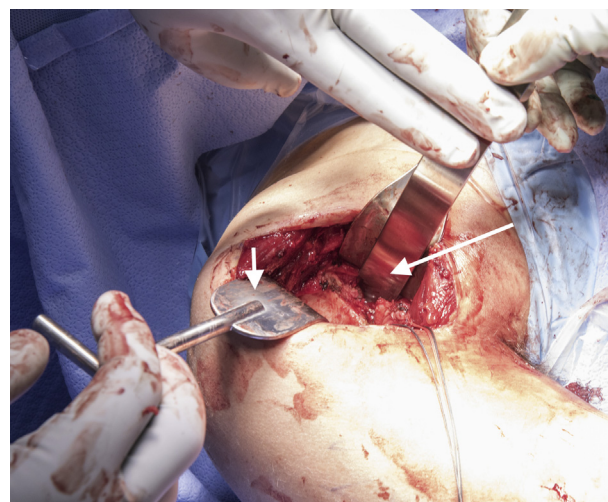


Fig 4. Retractor placement for glenoid exposure. A Fukuda retractor (short arrow) is placed on the humeral head. A 1- or 2-toed glenoid retractor (long arrow) is used on the glenoid neck to hold back the capsular tissue and subscapularis. A right shoulder is shown, with the patient's head at the top of the image.

Table 1. Pearls and Pitfalls of Glenojet Technique

Pearls	Pitfalls
Adequate exposure should be obtained by exposing the entire anteroinferior glenoid. This is most easily achieved by taking down the subscapularis, but in experienced hands, it can also be achieved through a subscapularis split.	Aggressive retraction of the glenoid should be avoided so as not to damage the musculocutaneous and axillary nerves. The surgeon should avoid aggressive dissection of the inferior glenoid to avoid damage to the axillary nerve.
Extra time should be taken to ensure correct placement of the drill guide: It should be flush with the articular surface, and the laser line should be in line with the anterior bone defect.	If the drill guide is positioned incorrectly, the guidewires may penetrate the joint or the anterior edge of the glenoid will be inappropriately reamed for graft fit.
The capsule can be advanced as it is repaired to the graft to add soft-tissue restraint to the anterior shoulder.	Over-tightening of the screws could potentially result in graft fracture or stress risers.

elevation but external rotation is limited to 20° to protect the repair. Terminal stretching, external rotation past 20°, and strengthening are allowed after 6 weeks postoperatively. When a subscapularis split is performed, range of motion is allowed as tolerated, with terminal stretching and strengthening after 6 weeks postoperatively.

Discussion

Coracoid bone transfer, or the Bristow-Latarjet technique, has historically been an important technique to guard against failure of soft-tissue repair for anterior instability with bone loss. However, a review of 45 studies using this technique showed a high complication rate of 30% and a reoperation rate of 7%.⁶ Given the potential complications of coracoid transfer, allograft reconstruction of the anteroinferior glenoid has gained increased popularity. It aims to provide a more anatomic reconstruction with possibly less long-term graft resorption and arthritis.^{6,7} With 45 months' follow-up after fresh distal tibial allograft reconstruction, Provencher et al.⁸ found that there were no cases of recurrent instability, patient-reported outcomes were significantly improved, and radiographic union was

achieved in 89% of cases, with average lysis of 3%. Mascarenhas et al.⁹ investigated results after iliac crest allograft reconstruction in 10 patients with average 4-year follow-up and found radiographic union in 80% at 6 months, with significantly improved patient-reported outcomes and no recurrent shoulder instability.

The advantage of the Glenojet graft over previously described allograft techniques is that it is pre-shaped and predrilled, thus eliminating the time and effort required by the surgeon for graft preparation in the operating room. Graft preparation is simple and only involves suture placement. We have found that the 2 available sizes accommodate the spectrum of bone loss seen in glenoid deficiency cases and the contour of the graft fits the native glenoid very well (Table 2). Indications and contraindications for this graft are displayed in Table 3.

The potential disadvantages of the Glenojet procedure are similar to those seen with other allograft reconstruction procedures. Care must be taken with retractor placement to avoid damage to the axillary and musculocutaneous nerves. There are concerns over graft union or subsequent resorption—particularly because

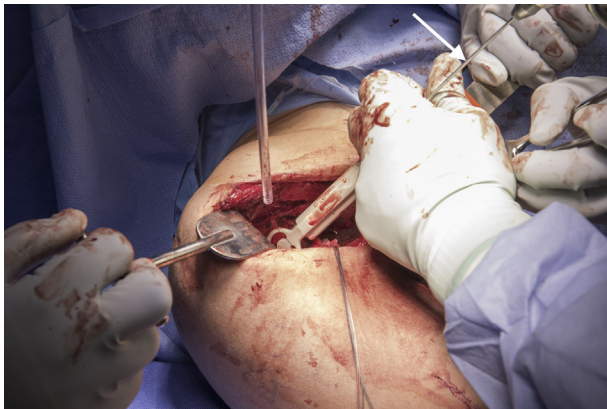


Fig 5. Once exposure has been obtained, the Glenojet drill guide is placed flush against the surface of the glenoid. One should note how the laser line matches the anterior edge of the glenoid defect. While the guide is being held in place, the 2 guide pins (arrow) are drilled. A right shoulder is shown, with the patient's head at the top of the image.

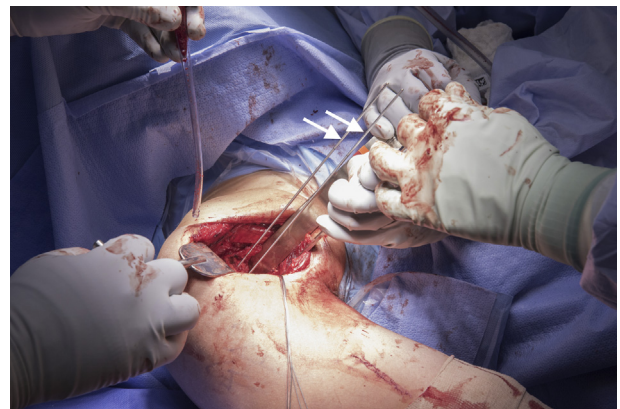


Fig 6. Appearance of the glenoid with the guide pins (arrows) in place after drill guide removal. The guide pins have been inserted just past the posterior cortex of the glenoid. A right shoulder is shown, with the patient's head at the top of the image.

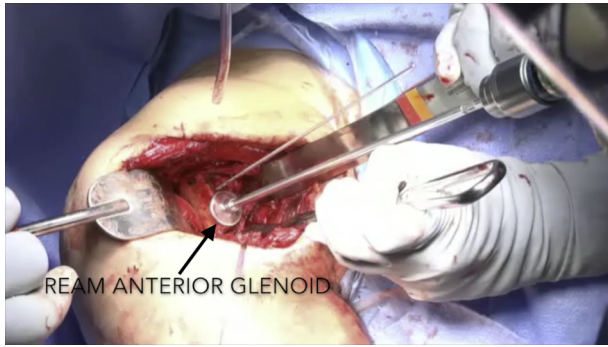


Fig 7. Once the guide pins are in place, a cannulated reamer is inserted over each pin sequentially and reamed until the pin hits the stop. The goal is to create a flat, even surface for graft placement. A right shoulder is shown, with the patient's head at the top of the image.

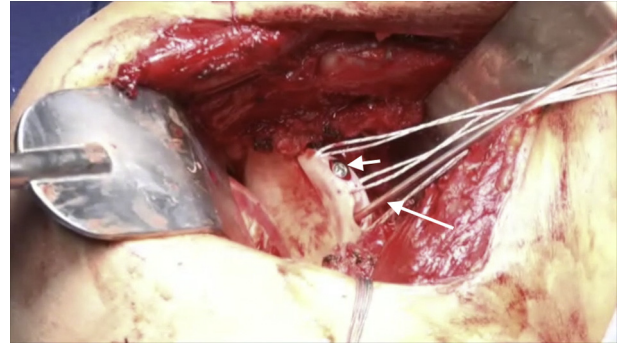


Fig 10. Appearance of the allograft after insertion of the first 3.5-mm cortical screw (short arrow). The inferior guide pin (long arrow) is subsequently removed, and the length is measured with the guide pin in preparation for the second screw. The guide pins are an appropriate diameter to allow screw insertion without predrilling. A right shoulder is shown, with the patient's head at the top of the image.

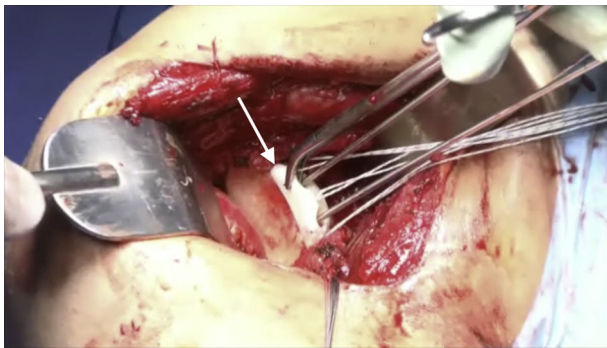


Fig 8. After the glenoid has been reamed, the prepared Glenojet graft (arrow) is placed onto the pins and oriented to match the surface of the native glenoid. A right shoulder is shown, with the patient's head at the top of the image.

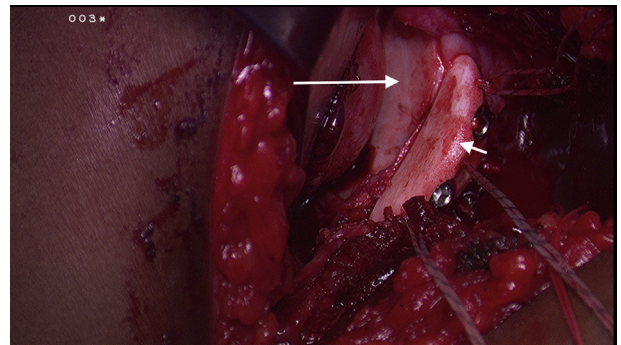


Fig 11. Appearance of the allograft (short arrow) after insertion of the inferior 3.5-mm cortical screw. There should be excellent bicortical fixation against the native glenoid (long arrow). A right shoulder is shown, with the patient's head at the top of the image.

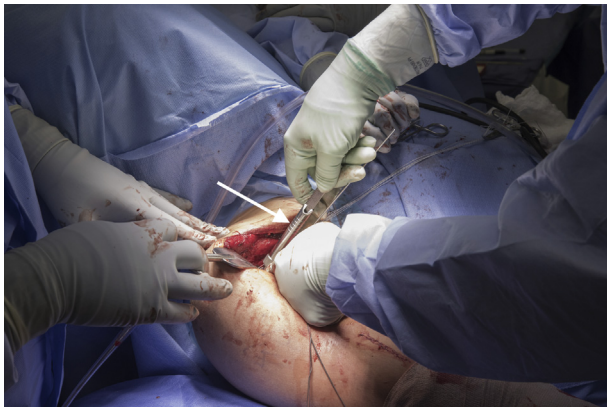

Fig 9. The superior pin is removed while the graft is held in place. A depth gauge (arrow) is used to determine the appropriate length for a 3.5-mm cortical bone screw with bicortical fixation. We have found that this length is typically around 26 to 32 mm. A right shoulder is shown, with the patient's head at the top of the image.

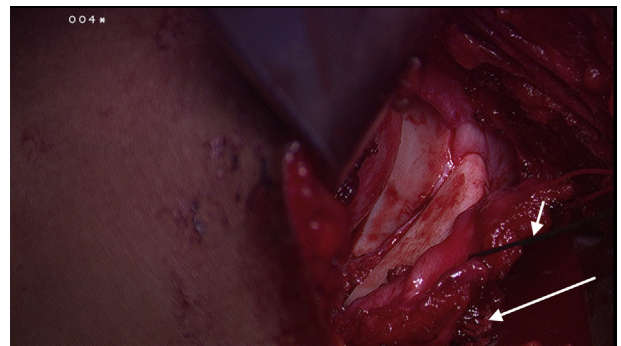


Fig 12. The sutures of the allograft have been brought through the capsule for capsulorrhaphy and trimmed (long arrow). A free needle has been threaded over the sutures of the allograft, starting with the most inferior suture and working in an inferior to superior direction, with mattress suture fixation. Additional sutures are used for traction (short arrow). After this, the subscapularis is repaired as per surgeon preference (suture fixation or suture anchors). A right shoulder is shown, with the patient's head at the top of the image.

Table 2. Advantages and Disadvantages of Glenojet Technique

Advantages
The graft saves time because the sutures are easy to prepare on the back table by a surgical assistant. The graft is predrilled and pre-shaped.
Use of allograft avoids (1) donor-site irritation for autograft bone block and (2) extensive dissection and risk of neurovascular injury from coracoid transfer.
The graft is precontoured to anatomically match the articular surface of the glenoid.
Disadvantages
The graft lacks articular cartilage—although the soft-tissue repair will cover much of the graft, so this may not be an issue.
The graft is not fresh frozen and thus may be slower to heal to the native glenoid.

this is not a fresh allograft or autograft—but we have not experienced this in our cohort to date. We have had 1 case of fracture at the superior corner of the graft at 9-month follow-up; we believe this was due to over-tightening of the screws in the graft, which created a stress concentration. Although the graft does not have an articular surface, the capsular repair covers much of the articular side of the graft, and given this soft-tissue coverage, we do not anticipate that the lack of articular cartilage would contribute to glenohumeral arthritis. However, we do not have long-term follow-up on these grafts at this time to substantiate this claim.

In conclusion, the Glenojet allograft is a technically simple option for glenoid reconstruction that creates an anatomic buttress with less surgical dissection than

Table 3. Indications and Contraindications of Glenojet Technique

Indications
Anterior glenohumeral instability in setting of glenoid bone loss >20%-25%
Revision anterior glenohumeral instability with any prior soft-tissue or bone treatment
Contraindications
Voluntary anterior instability
Multidirectional instability or instability without bone loss
Comorbidities that may prohibit healing of allograft to native bone
Active infection

traditional coracoid transfer. The ease of this procedure makes it an attractive option for reconstruction of a bony Bankart lesion or for failed previous bone reconstruction. Short-term outcomes are reassuring, but more research is needed to study long-term graft union, graft resorption, glenohumeral arthritis, and patient outcomes including recurrent shoulder instability.

References

- Burkhart S, De Beer J. Traumatic glenohumeral bone defects and their relationship to failure of arthroscopic Bankart repairs: Significance of the inverted-pear glenoid and the humeral engaging Hill-Sachs lesion. *Arthroscopy* 2000;16:677-694.
- Piasecki D, Verma N, Romeo A, Levine W, Bach BJ, Provencher MT. Glenoid bone deficiency in recurrent anterior shoulder instability: Diagnosis and management. *J Am Acad Orthop Surg* 2009;17:482-493.
- Sayegh ET, Mascarenhas R, Chalmers PN, Cole BJ, Verma NN, Romeo A. Allograft reconstruction for glenoid bone loss in glenohumeral instability: A systematic review. *Arthroscopy* 2014;30:1642-1649.
- Walia P, Patel RM, Gottschalk L, et al. The reduction instability from combined humeral head and glenoid bony defects is influenced by arm position. *Am J Sports Med* 2016;44:715-722.
- Smucny M, Miniaci A. A new option for glenoid reconstruction in recurrent anterior shoulder instability. *Am J Orthop (Belle Mead NJ)* 2017;46:199-202.
- Griesser MJ, Harris JD, McCoy BW, et al. Complications and re-operations after Bristow-Latarjet shoulder stabilization: A systematic review. *J Shoulder Elbow Surg* 2013;22:286-292.
- Young D, Rockwood CJ. Complications of a failed Bristow procedure and their management. *J Bone Joint Surg Am* 1991;73:969-981.
- Provencher MT, Frank RM, Golijanin P, et al. Distal tibia allograft glenoid reconstruction in recurrent anterior shoulder instability: Clinical and radiographic outcomes. *Arthroscopy* 2017;33:891-897.
- Mascarenhas R, Raleigh E, McRae S, Leiter J, Saltzman B, MacDonald PB. Iliac crest allograft glenoid reconstruction for recurrent anterior shoulder instability in athletes: Surgical technique and results. *Int J Shoulder Surg* 2014;8:127-132.