

## Case Report

## A successful off-pump cardiac repair following blunt cardiac rupture – A case report

Awaneesh Katiyar\*, Ajay Kumar, Neeraj Kumar, Ruby Kataria, Bhaskar Sarkar

Department of Trauma Surgery and Critical Care, All India Institute of Medical Sciences, Rishikesh, India

## ARTICLE INFO

## Keywords:

Cardiac rupture  
Emergency thoracotomy  
Cardiac repair  
Atrial rupture

## ABSTRACT

A 25-year-old male truck driver presented to Emergency Department following unrestrained heavy motor vehicle crash (MVC), when the high-speed truck collided to a wall. He sustained blunt chest trauma from steering wheel and open fracture of right tibia with compartment syndrome. On primary survey, patient was in shock with patent airway. Focused assessment sonography for trauma (FAST) suggested cardiac tamponade for which ultrasound-guided pericardial catheter was placed. After resuscitation patient was taken to the operation theatre. Clamshell thoracotomy revealed rents in left atrial appendages which were repaired. Fasciotomy of leg was performed and external fixator was applied for open tibia fracture. The patient developed surgical site infection that was treated with local antibiotic and regular dressings. After two weeks, fasciotomy wound was closed with split-skin grafting. At nine-month follow-up, patient was able to resume his occupation as a heavy motor vehicle driver.

### Background

Historically survival rate is abysmal in cardiac rupture victims as most of them die during transport or at the scene [1,2]. Post-operative, in-hospital mortality remains high due to pneumonia and sepsis, associated poly-trauma further worsens the prognosis [2,3]. Rehn reported the first successful cardiac repair in 1897 for penetrating cardiac injury, and Desforges and associates in 1955 reported similar technique for non-penetrating cardiac rupture. As per a review of 4169 victims of road traffic injuries between 1972 and 1985, chest trauma was the leading cause of death in 1121 patients. 75 out of 1121 patients were found to have a cardiac rupture in the post-mortem report [4]. Frontal collisions like a crushing force against the steering wheel appear to be the leading cause of cardiac rupture [4,5]. Besides blunt cardiac rupture has high mortality with a variable presentation in the emergency department, thus making diagnosis of this entity more arduous [5]. Ours is a case of blunt cardiac rupture with open tibia fracture and compartment syndrome of leg, which was successfully managed by the trauma team.

### Case presentation

A 25 years-old male unrestrained truck driver, presented in the emergency department, after 1 h of a motor vehicle crash. On primary survey, the airway was clear with reduced air-entry in left side of chest, SpO<sub>2</sub> was 99% on room-air, pulse rate was 164/min, blood pressure was 84/42 mm of Hg, and respiratory rate was 28/min. Further examination revealed open right tibia fracture,

\* Corresponding author at: Department of Trauma Surgery and Critical Care, Trauma Center, All India Institute of Medical Sciences, Rishikesh, India.

E-mail address: [awaneesh.traumasurg@aiimsrishikesh.edu.in](mailto:awaneesh.traumasurg@aiimsrishikesh.edu.in) (A. Katiyar).

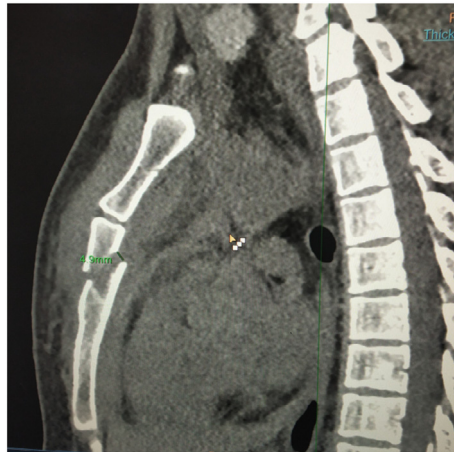
<https://doi.org/10.1016/j.tcr.2020.100344>

Accepted 27 July 2020

Available online 30 July 2020

2352-6440/ © 2020 Published by Elsevier Ltd. This is an open access article under the CC BY-NC-ND license

(<http://creativecommons.org/licenses/by-nc-nd/4.0/>).



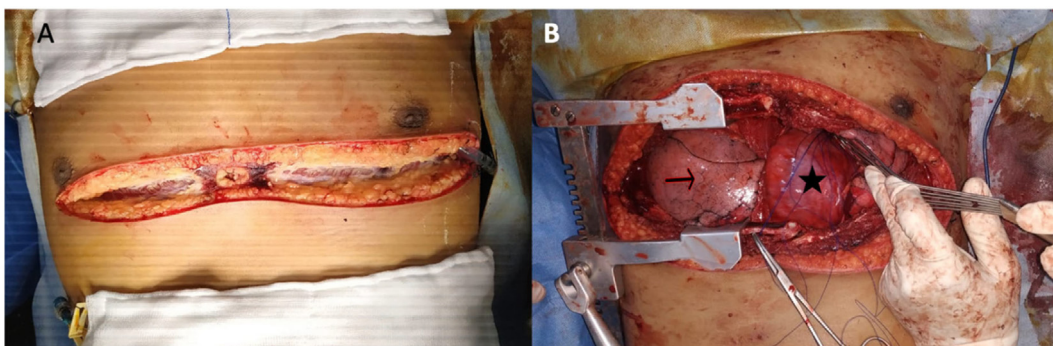
**Fig. 1.** CT image showing sternum fracture that is a sign of severe impact on chest.

Gustillo-Anderson Grade 3b, with compartment syndrome. Patient was resuscitated as per Advanced Trauma Life Support® (ATLS®) protocol. The bolus of Ringer's lactate was given and blood pressure was raised to 100/62 mm of Hg, though with persistent tachycardia (pulse rate 154/min) and engorged neck veins. Focused Assessment Sonography for Trauma (FAST) showed pericardial fluid causing cardiac tamponade and left-sided haemothorax. Left sided intercostal drain (ICD) and, under Ultrasonography (USG) guidance, pericardial catheter (16Fr) was placed. 200 ml of blood from left ICD and 100 ml of blood from pericardium were drained in over 10 min. Blood pressure was raised to 112/70, and pulse rate came down to 130/min. Once stabilized haemodynamically, he was shifted for contrast-enhanced computed tomography that was suggestive of small fluid and a catheter in the pericardial cavity with no active contrast leak (Fig. 1).

The patient was taken to the operation theatre and emergency clamshell thoracotomy was performed (Fig. 2). About 500 ml of clot was removed from the pericardial cavity and two defects were noted, of  $1 \times 2$  cm and  $1 \times 1$  cm size, over left atrial appendages. Both the defects were repaired with Prolene® 3-0 suture. Intraoperatively, the patient sustained cardiac arrest on three occasions due to bleeding and was successfully revived via internal cardiac massage and defibrillation. For open tibia fracture, an external fixator was applied, and fasciotomy was done for compartment syndrome. In the postoperative period, patient developed superficial surgical site infection (Fig. 3), which was treated by local antibiotics and serial changes in dressings. On fifth postoperative day (POD), chest X-rays were suggestive of lung atelectasis which was managed by vigorous chest physiotherapy and incentive spirometry. Split-skin grafting was done for fasciotomy wound after 15 days of initial surgery, once healthy granulation tissue had appeared (Fig. 4). He was discharged after seven days of second surgery in satisfactory condition.

### Outcome and follow-up

Patient was initially called weekly for follow-up for one month, then fortnightly for the next two months and then monthly for eight months. He was having usual recovery of the wound and is healthy now. At follow-up of nine months (Fig. 5), he was able to do all his routine activities and had also resumed his occupation as a truck driver.



**Fig. 2.** A: Incision of clamshell thoracotomy.

B: Internal view showing right lung (black arrow) with heart after taking control on defect (black star).

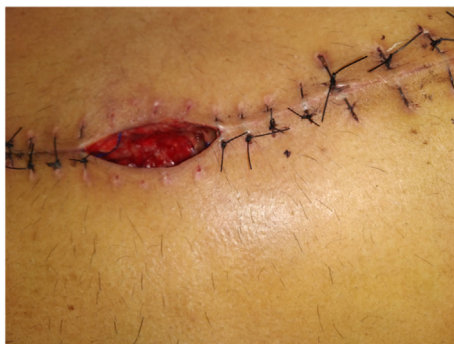

Fig. 3. Showing superficial surgical site infection on POD7.

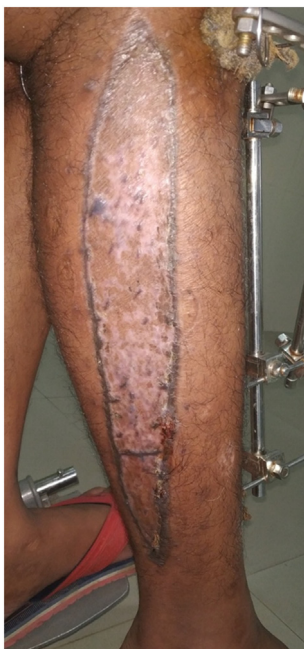

Fig. 4. Split skin grafting over fasciotomy wound on 2nd follow-up.

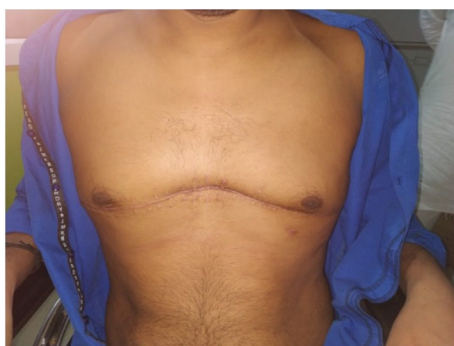

Fig. 5. After 8 months of follow-up.

## Discussion

The most common cause of cardiac rupture is road traffic injuries- especially with a frontal collision in high-speed motor vehicle [6]. The presentation of cardiac injuries after blunt chest trauma varies from a clinically insignificant myocardial contusion to full-

thickness cardiac rupture [5]. Most of the patients with cardiac rupture die because of cardiac tamponade or severe bleeding [5]. According to Mayfield, acute cardiac rupture may lead to death at the site of the accident or within a few hours of trauma unless intervened surgically [2]. Most frequent site of cardiac rupture is atrial appendage because of being the thinnest and weakest area of heart [2,7,8]. Also, the junction of atria and great veins is a common site for blunt cardiac ruptures [2,7]. In blunt cardiac rupture, associated pericardial tear is found in up to 30% of cases due to increased intra-abdominal pressure or rapid deceleration [9]. It is not uncommon to diagnose pericardial rupture during thoracotomy without pre-emption [5]. The first repair of a blunt right atrial rupture was reported by Desforges et al. in 1955 [10]. In 1676, Borch described the rupture of the heart following a non-penetrating chest injury for the first time. In 1649, Riolan suggested pericardiocentesis for the treatment of cardiac wounds. On suspicion of cardiac rupture or penetrating cardiac injury, clamshell thoracotomy is used to provide better and easy access to the heart in the emergency department for non-cardiothoracic surgeons [11]. Traditionally in case of cardiac rupture, median sternotomy is the approach utilized as it provides adequate exposure of the heart & great vessels, and also facilitates cardio-pulmonary bypass [3,7]. Furthermore, extension of the same incision suffices for exploratory laparotomy, if needed [7].

As per Shorr et al., 515 out of 5378 trauma patients, sustained blunt chest trauma, and out of 5378 cases 14 cases (0.3%) had cardiac lacerations [5]. Observation at autopsy indicates that blunt cardiac rupture indeed is not rare [4,12]. The most common clinical presentation of cardiac rupture is cardiac tamponade with shock and raised central venous pressure [7]. These patients usually have multiple associated injuries that may change the clinical presentation. Hypotension out of proportion to apparent blood loss with visible signs of blunt injury to chest should raise the suspicion of cardiac tamponade [8]. Elevation of central venous pressure, as indicated by distended jugular veins, and equalization of cardiac filling pressures may also suggest the diagnosis. Hematoma causes compression of superior vena cava within the pericardium or great vessels of the upper mediastinum. Seventy-six percent of patients surviving blunt cardiac rupture have been found to have a significant upper torso, head, and neck cyanosis [1,8]. Survival is also reported with emergency thoracotomy in a patient who succumbed to cardiac arrest due to cardiac tamponade [11]. Blunt cardiac rupture has four times higher mortality than penetrating cardiac injury [1]. Sophisticated prehospital care and transport facilities can be able to save more of these patients [7]. The high index of suspicion, focused clinical examination-oriented towards the diagnosis and prompt surgical intervention can increase the survival rate [8].

## Conclusion

Blunt cardiac rupture, though a rare clinical entity, should be suspected in high-velocity motor vehicle crash with sudden decelerating impact over chest. Establishing the diagnosis in the emergency room is indeed challenging. In patients with an aforesaid high-velocity mechanism, or with unexplained hypotension associated with engorged neck veins and presence of breath sounds, the diagnostic suspicion should be high. The most common cause of death is cardiac tamponade or severe haemorrhage. The most commonly reported sites are atrial appendages or the junction of the atrium and great veins. For successful clinical outcome, establishing the diagnosis of cardiac rupture in blunt chest trauma is most important, followed by the earliest possible intervention. Atelectasis and pneumonia are major malefactors leading to deaths in post-cardiac-repair patients and must be meticulously addressed.

## Key messages

1. High-velocity motor vehicle crash, direct impact over chest with rapid deceleration – may be associated with cardiac trauma with or without great vessels injury.
2. Unexplained hypotension, engorged neck veins, distant heart sound and presence of breath sound – suspect cardiac tamponade.
3. Pericardiocentesis in the emergency department – buys time for thoracotomy till operation theatre.
4. In Blunt chest trauma – making a diagnosis of cardiac rupture is albeit difficult, but with timely and judicious management by an efficient trauma team outcome may not be always gruesome.

## Funding resources and sponsors

None.

## Acknowledgement

I am very thankful to Dr Bhaskar Sarkar for his guidance in writing and reviewing article. Very thankful to our nursing team Mr. Sarthi Arora for helping in pericardiocentesis Mr. Vinod Pant in emergency thoracotomy. I am very thankful to whole Anesthesia team who involved in the patient care especially Dr Shailesh Lohani (Senior Resident Anesthesia) at AIIMS Rishikesh.

## References

- [1] M.J. Wall, P. Tsai, K.L. Mattox, *Heart and thoracic vascular injuries*, Trauma, McGraw Hill Medical, New York, NY, 2017, pp. 493–521.
- [2] A.N. Dalvi, R.A. Gondhalekar, R.G. Shirhatti, S.V. Joshi, R.U. Sukthankar, S.K. Mathur, Atrial rupture following blunt chest trauma (a case report), *J. Postgrad. Med.* 33 (3) (Jul 1, 1987) 152.
- [3] A. Ingraham, J. Sperry, Operative management of cardiac injuries: diagnosis, technique, and postoperative complications, *Curr. Trauma Rep.* 1 (4) (Dec 1, 2015)

- 225–231.
- [4] S.E. Santavirta, E.E. Arajärvi, Ruptures of the heart in seatbelt wearers, *J. Trauma* 32 (3) (Mar 1992) 275–279.
  - [5] D. Baldwin, K.L. Chow, H. Mashbari, E. Omi, J.K. Lee, Case reports of atrial and pericardial rupture from blunt cardiac trauma, *J. Cardiothorac. Surg.* 13 (1) (Dec 2018) 71.
  - [6] S. Pinni, V. Kumar, S.B. Dharap, Blunt cardiac rupture: a diagnostic challenge, *J. Clin. Diagn. Res.* 10 (11) (Nov 2016) PD27.
  - [7] B.J. Leavitt, J.A. Meyer, J.R. Morton, D.E. Clark, W.E. Herbert, C.A. Hiebert, Survival following nonpenetrating traumatic rupture of cardiac chambers, *Ann. Thorac. Surg.* 44 (5) (Nov 1, 1987) 532–535.
  - [8] C.E. Brathwaite, A.U. Rodríguez, S.Z. Turney, C.M. Dunham, R. Cowley, Blunt traumatic cardiac rupture. A 5-year experience, *Ann. Surg.* 212 (6) (Dec 1990) 701.
  - [9] H. Oizumi, K. Suzuki, H. Hoshino, T. Tatsumori, H. Ichinokawa, A case report: hemothorax caused by rupture of the left atrial appendage, *Surg. Case Rep.* 2 (1) (Dec 2016) 142.
  - [10] G. Desforges, W.P. Ridder, R.J. Lenoci, Successful suture of ruptured myocardium after nonpenetrating injury, *N. Engl. J. Med.* 252 (14) (Apr 7, 1955) 567–569.
  - [11] D. Wise, G. Davies, T. Coats, D. Lockey, J. Hyde, A. Good, Emergency thoracotomy: “how to do it”, *Emerg. Med. J.* 22 (1) (Jan 2005) 22.
  - [12] P. Kulshrestha, B. Das, K.S. Iyer, K.A. Sampath, M.L. Sharma, I.M. Rao, et al., Cardiac injuries-a clinical and autopsy profile, *J. Trauma* 30 (1990) 203–207.