

Treatment of giant congenital cysts of the midline in adults: Report of two cases and review of the literature

Liverana Lauretti, Pier Paolo Mattogno, Federico Bianchi, Roberto Pallini, Eduardo Fernandez, Francesco Doglietto¹

Institute of Neurosurgery, Catholic University School of Medicine, Rome, ¹Department of Neurosurgery, University of Brescia, Brescia, Italy

E-mail: Liverana Lauretti - llauretti@rm.unicatt.it; *Pier Paolo Mattogno - pierpaolo.mattogno@gmail.com; Federico Bianchi - fede0786@hotmail.it; Roberto Pallini - pallini@rm.unicatt.it; Eduardo Fernandez - efernandez@rm.unicatt.it; Francesco Doglietto - francdogl@gmail.com

*Corresponding author

Received: 24 March 15 Accepted: 20 May 15 Published: 20 August 15

This article may be cited as:

Lauretti L, Mattogno PP, Bianchi F, Pallini R, Fernandez E, Doglietto F. Treatment of giant congenital cysts of the midline in adults: Report of two cases and review of the literature. *Surg Neurol Int* 2015;6:S371-4.

<http://surgicalneurologyint.com/Treatment-of-giant-congenital-cysts-of-the-midline-in-adults-Report-of-two-cases-and-review-of-the-literature/>

Copyright: © 2015 Lauretti L. This is an open-access article distributed under the terms of the Creative Commons Attribution License, which permits unrestricted use, distribution, and reproduction in any medium, provided the original author and source are credited.

Abstract

Background: Giant cysts of the midline, not associated to a tumor, are exceptional finding in the brain of adults. Here we present two cases of symptomatic giant cerebral cysts of the midline occurred in an elderly and in a young adult patients both treated with mini-invasive unilateral neuroendoscopic procedure. In the recent literature (since 1999) similar cases have not been reported. Beside the clinical report, review of literature and major anatomical features of the region are described.

Case Description: These two adults (82 and 41 years old respectively) had a slow progressive development of headache, gait disturbances, memory impairment and urinary incontinence. Magnetic resonance imaging showed giant cyst of the midline and hydrocephalus. Surgery with the endoscopic procedure, through a right frontal burr hole, was followed by clinical and radiological improvement.

Conclusion: Giant cerebral cysts of the midline in adults can be successfully treated through a neuroendoscopic monolateral approach that comprehends multiple openings, diffuse coagulation of the capsule, and careful releasing of capsule-ependyma adherences. Knowledge of major anatomical and developmental details of the septal region is necessary to avoid complication in a mini-invasive surgical procedure.

Key Words: Cyst, midline, neuroendoscopy, septum pellucidum

Access this article online

Website:

www.surgicalneurologyint.com

DOI:

10.4103/2152-7806.163317

Quick Response Code:



INTRODUCTION

Cavum septi pellucidi (CSP), cavum vergae (CV) as well as cavum veli interpositi (CVI) are midline cerebrospinal fluid (CSF) collections that do not communicate with ventricles or subarachnoid spaces and usually do not necessitate of any treatment. Reported as incidental findings at autopsy and during neuro-radiological exams, their incidence decreases from premature birth to adult age. When such CSF collections are larger than 1 cm,

they are called “cysts” of CSP, CV, CVI. Given that there are not further classifications, in this study we reasonably considered as giant a cyst with a diameter bigger than 4 cm at least in two out of three directions (cranio-caudal, latero-lateral or antero-posterior). Symptomatic cysts cause different disorders that vary from humor changes to signs of chronic hydrocephalus as well as vomit or loss of consciousness. Shunting, craniotomy, stereotactic or endoscopic approaches have been used to treat these cysts.

Giant cysts of the midline are exceptional, especially in adults. Here we report on two cases of giant, cerebral cysts of the midline, remarkable like dimensions and age of appearance, which were treated with the endoscopic procedure. To our knowledge, these are the only two cases reported in adults since 1999.

CASE REPORT

Patients

These two female patients, 82 (case 1) and 41 (case 2) years old, had a slow history of progressive short-term memory deficits and gait instability with frequent falls; urinary incontinence had lately appeared. The older patient was taking medications for arterial hypertension. In each, computed tomography (CT) scan and magnetic resonance imaging (MRI) showed a giant (diameters in the three-dimensions over 4 cm, the biggest of them over 7 cm), supratentorial cyst of the midline determining biventricular hydrocephalus: In case 1 the third ventricle and brain-stem were downward displaced [Figure 1a]; in case 2 [Figure 2a] the cyst extended to the infratentorial compartment compressing the brain-stem posteriorly. Neurological exam at admission confirmed gait ataxia and the signs of chronic hydrocephalus. At surgery, through a right precoronal burr hole, the frontal horn of the ventricle was entered with a Storz-Decq rigid endoscope (30° angled): Fenestration of the cyst was made and the shrinkage was facilitated by monopolar coagulation of the capsule [Figure 3a and b].

RESULTS

The postoperative period was uneventful. The preoperative symptoms progressively improved. 12 months later they had recovered normal gait, urinary continence, and neuropsychological testing showed only minor difficulties. MRI confirmed the reduction of the cyst [Figure 1b and 2b].

Reviewed literature has been summarized in Table 1.

DISCUSSION

Cerebrospinal fluid cysts of the cerebral midline are rare and hardly ever they necessitate of any treatment. The septum region is part of the medial surface of the cerebral hemispheres, is well developed also in humans and plays an important role in pleasure and rewarding sensations. Its development is rather complex since it is made up by at least four telencephalic structures.^[7] The dorsal part of the septum is the “septum pellucidum,” whereas the ventral one is the “septum verum.”^[7]

The “septum pellucidum” (two layers, each one of gray and white matter), is placed between the genu of the

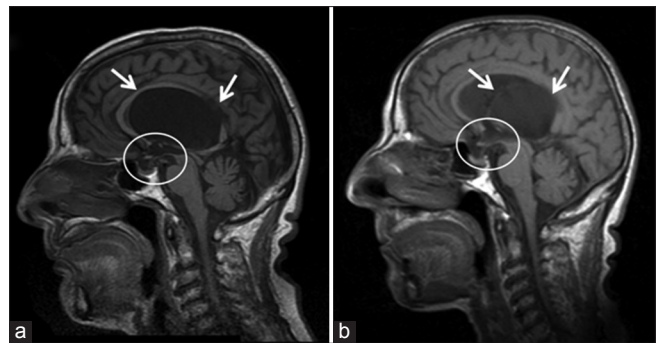


Figure 1: Case 1. (a) Preoperative T1-weighted, sagittal plane image: The cyst (arrows) determines biventricular hydrocephalus developing over the third ventricle that is downward displaced (circle); note also the compression of both pituitary gland and its stalk (circle). (b) The postoperative corresponding magnetic resonance image shows the shrinkage of the cyst (arrows), re-expansion of the third ventricle, patency of the foramen of Monro as well as the decompression of pituitary complex (circle)

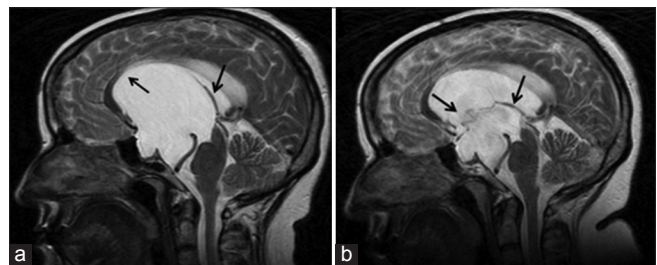


Figure 2: Case 2. (a) Preoperative magnetic resonance imaging (MRI): The sagittal plane T2-weighted image shows the enormous cyst (arrows) displacing the corpus callosum (CC) and the brain-stem. (b) The corresponding postoperative MRI: After treatment the deflated cyst wall is visible (arrows) and the CC with internal cerebral veins as well as the brain-stem appear decompressed

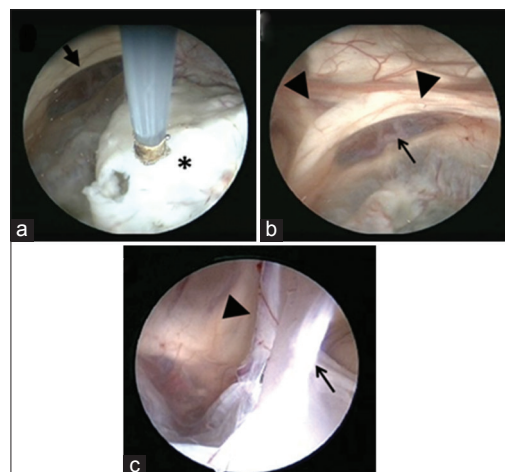


Figure 3: Endoscopic images during surgery. (a) Step by step the thick capsule (asterisk) is coagulated and fenestrated. (b and c) At the end of the procedure the cyst is clearly reduced and the surrounding anatomical structures, altered by the chronic compression, are visualized: The anterior cerebral and communicating arteries (black arrow), the absence of the septum pellucidum and the fornix of each side (bold arrows). The opened cyst wall and its adhesences to the surrounding ependyma (arrows) are visible: Some of them hide dangerous veins (bold arrow)

Table 1: Symptomatic midline cysts operated on and reported since 1999

Authors	N° cases	Age (years)	Treatment
Lancon <i>et al.</i> , 1999 ^[5]	2	6; 42	Endoscope
Gangemi <i>et al.</i> , 2002 ^[4]	3	8; 7; 21	Endoscope
Donati <i>et al.</i> , 2003 ^[2]	1 (giant)	1	Endoscope
Fratzoglou <i>et al.</i> , 2003 ^[3]	4	47.5 median age	Endoscope
Tirakotai <i>et al.</i> , 2004 ^[9]	3	Adults, not specified	Endoscope
Chiu <i>et al.</i> , 2005 ^[1]	2	14; 37	Endoscope
Meng <i>et al.</i> , 2006 ^[6]	10	3-60 range	Endoscope
Present series, 2015	2 (giant)	41; 82	Endoscope

corpus callosum (CC) anteriorly, the body of the CC dorsally, the fornix postero-ventrally, and the lateral ventricles laterally. The cavities between the layers of the “septum pellucidum,” formed during the first stages of fetal development, disappear during the first semester after birth except in 10% of the adult population with an incidence of 0.73% in the CT exams. When the anterior cavity persists, it is called “CSP.” This can be isolated but more frequently is associated to the persistence of the posterior cavity, named “CV,” which extends beyond the anterior columns of the fornix up to the splenium of CC.^[7]

The “septum verum” contains the lateral and medial nuclei of the limbic system and is bounded anteriorly by the rostrum of the CC, ventrally by the anterior commissure and the preoptic region, and laterally by the nucleus accumbens.^[7]

The “velum interpositum” is a double fold triangle of pia mater, enclosing subarachnoid trabeculae, between the fornix and hippocampal commissure dorsally and the ependymal roof of the third ventricle, the thalami and the superior surface of the pineal body ventrally; at each lateral margin there is a vascular fringe projecting into the choroidal fissure of the lateral ventricle. The apex of the triangle points anteriorly reaching the plane of foramina of Monro. Usually, the “velum interpositum” contains the internal cerebral veins with tributaries and the medial posterior choroidal arteries.^[7] When filled by CSF, it is named CVI and “cyst of CVI” when it is larger than 1 cm.

The mechanisms underlying the growth of the CSF cysts of the cerebral midline are not clearly understood. Histology of the cyst wall has revealed tissue derived from “septum pellucidum” rather than arachnoid or choroid plexus.^[3] In their growth, instead of a primary production of fluid, a valve mechanism with ventricular cavities seems to be most likely implied. Both the amount of trapped CSF and the rapidity of its accumulation are probably determinant for the onset of neurological disturbances: In adults, as the cases here reported, the cyst’s growth is so slow that causes

a progressive anatomical distortion that neutralizes for years the subtle increase of pressure. Only belatedly, even decades after, when encephalic structures had been quietly changed and in some grade spoiled, neurological disturbances appear. This could explain the indolent course of this pathology. The anatomical basis that favors the formation of large midline cysts in adults should be congenital. Like many other intracranial pathologies having big volumes, the growth velocity, more than the volume, is the key factor determining the appearance of symptoms. We can say that in our two reported cases the final volume of the cysts was formed very slowly permitting the intervention of all the mechanisms of intracranial compliance, but till a certain point when such mechanisms were spent, and patients became symptomatic.

Common to the three different kinds of cysts are the clinical symptoms of hydrocephalus from obstruction of Monro’s foramina or Sylvius’s aqueduct. Then, headache, gait disturbances, urinary incontinence, cognitive deterioration, vomiting and loss of consciousness are the symptoms. The anterior cysts can also compress optic and fronto-temporal structures causing visual disturbances, neuropsychiatric disorders, and memory deficit. Sometimes, because of the slow growth, large cysts can be asymptomatic and can be found incidentally.

Currently, the treatment of choice of symptomatic CSP, CV, CVI cysts is endoscopic fenestration through frontal or, seldom, posterior approach. Other options, mostly used formerly, include craniotomy, shunting, and stereotactic drainage.

Reviewing the 25 symptomatic midline cysts operated on and reported since 1999 [Table 1], we found only one giant cyst that affected a pediatric patient (1 year old); none operated giant cyst in adult/elderly patients has been reported. Regarding the patients’ age in the adult population in which non-giant CSP, CV, CVI cysts were treated, because of missing data in the published papers, appears quite difficult to establish the oldness: Anyway, when the age has been specified, the oldest patient was 60 years old.^[6] Therefore, the present two cases are peculiar because they are giant cysts, with a diameter of about 7 cm, affecting elderly-middle age adults (82–41 years old, mean age 60.5).

Regarding surgery, endoscopic treatment with flexible as well as rigid endoscope has been widely described, as well as different surgical approaches: Anterior (frontal) monolateral or bilateral, posterior (carrefour).^[1-6,8,9] Reached the cyst, simple fenestration using Fogarty balloon besides enlarged fenestration using a biopsy forceps have both been reported.^[1-6,8,9] Nevertheless, in the published papers, there is not any specific description about endoscopic treatment and tricks when

dealing with big or giant cyst.^[9] We think that some distinctive considerations should be made for the surgical treatment of such big cysts. What is particularly evident during endoscopic surgery of these cysts is the difficult orientation inside and outside the cyst due to the tremendous alteration of normal anatomy that persists also after surgery; the “steadiness” of the deformed anatomical structures complicates also the correct interpretation of postoperative radiological images.

During surgery, in both cases we used a monolateral, right frontal approach (precoronary burr hole, 2 cm from the midline) and a rigid Storz-Decq endoscope: The cyst was reached at the depth of 3–4 cm and the capsule appeared white, tense, sulked by small vessels. Multiple openings were made by monopolar coagulation [Figure 3a] and scissors and were enlarged by removing small pieces of the capsule. After egress of the inside CSF-like fluid, the capsule started to pulse. We also noticed that many adherences between the cyst wall and the ventricular ependyma [Figure 3c] could hinder a real reduction, a collapse, of the cyst. Therefore, to facilitate narrowing of cysts, besides multiple fenestrations, diffuse monopolar coagulation of the cyst wall and coagulation and cut of thick attachments to the ventricular ependyma were performed. Nonetheless, in the postoperative radiological images, as explained above, no so big were the changes in dimension of cysts and ventricles but their loss of tension was evident [Figures 1b and 2b]. Anyway, such “shrinkage” of the cyst wall as well as such reduction of ventriculomegaly were sufficient for clinical improvement.

CONCLUSION

Giant cysts of CSP, CV and CVI in adults can be successfully treated through a monolateral endoscopic approach. Bilateral ventriculostomy is not required

and adds an unnecessary risk of bifrontal damage. Differently from the newborn, to obtain an evident reduction of the cyst, multiple openings and diffuse coagulation of the capsule as well as a careful releasing of capsule-ependyma adherences can determine a better and lasting cure.

ACKNOWLEDGMENTS

Daniele Petricca (technical support for images).

REFERENCES

1. Chiu CD, Huang WC, Huang MC, Wang SJ, Shih YH, Lee LS. Navigator system-assisted endoscopic fenestration of a symptomatic cyst in the septum pellucidum – Technique and cases report. *Clin Neurol Neurosurg* 2005;45:105-8.
2. Donati P, Sardo L, Sanzo M. Giant cyst of the cavum septi pellucidi, cavum vergae and veli interpositi. *Minim Invasive Neurosurg* 2003;46:177-81.
3. Fratzoglou M, Grunert P, Leite dos Santos A, Hwang P, Fries G. Symptomatic cysts of the cavum septi pellucidi and cavum vergae: The role of endoscopic neurosurgery in the treatment of four consecutive cases. *Minim Invasive Neurosurg* 2003;46:243-9.
4. Gangemi M, Maiuri F, Cappabianca P, Alafaci C, de Divitiis O, Tomasello F, et al. Endoscopic fenestration of symptomatic septum pellucidum cysts: Three case reports with discussion on the approaches and technique. *Minim Invasive Neurosurg* 2002;107:337-41.
5. Lancon JA, Haines DE, Lewis AI, Parent AD. Endoscopic treatment of symptomatic septum pellucidum cysts: With some preliminary observations on the ultrastructure of the cyst wall: Two technical case reports. *Neurosurgery* 1999;45:1251-7.
6. Meng H, Feng H, Le F, Lu JY. Neuroendoscopic management of symptomatic septum pellucidum cysts. *Neurosurgery* 2006;59:278-83.
7. Nieuwenhuys R, Voogd J, van Huijzen C. *The Human Central Nervous System*. 4th ed. Berlin/Heidelberg/New York: Springer-Verlag; 2007.
8. Nishijima Y, Fujimura M, Nagamatsu K, Kohama M, Tominaga T. Neuroendoscopic management of symptomatic septum pellucidum cavum vergae cyst using a high-definition flexible endoscopic system. Case report. *Neurol Med Chir (Tokyo)* 2009;49:549-52.
9. Tirakotai W, Schulte DM, Bauer BL, Bertalanffy H, Hellwig D. Neuroendoscopic surgery of intracranial cysts in adults. *Childs Nerv Syst* 2004;20:842-51.