

Received: 2012.10.10
Accepted: 2013.02.08
Published: 2013.04.10

Co-incident *Plasmodium Knowlesi* and Mucormycosis infections presenting with acute kidney injury and lower gastrointestinal bleeding

Authors' Contribution:
Study Design A
Data Collection B
Statistical Analysis C
Data Interpretation D
Manuscript Preparation E
Literature Search F
Funds Collection G

EF 1 **Arunachalam Ramaswami**
EFG 1 **Jayakrishnan K. Pisharam**
E 1 **Hla Aung**
E 2 **Kafeel Ghazala**
E 1 **Khalil Maboud**
EF 3 **Vui Heng Chong**
ADEF 1 **Jackson Tan**

1 Department of Renal Medicine, RIPAS Hospital, Brunei-Muara, Brunei
2 Department of Histopathology, RIPAS Hospital, Brunei-Muara, Brunei
3 Department of Gastroenterology, RIPAS Hospital, Brunei-Muara, Brunei

Corresponding Author: Jackson Tan, e-mail: drjacksontan@yahoo.co.uk

Background: *Plasmodium knowlesi* is frequently reported in Southeast Asian countries and is now widely regarded as the fifth malarial parasite. Mucormycosis is a rare fungal infection that can occur in patients with a weakened immune system.

Case Report: We report a case of acute kidney injury secondary to *Plasmodium knowlesi* malaria infection and mucormycosis fungal infection. In addition, the patient also had lower gastrointestinal bleeding from invasive gastrointestinal mucormycosis. *P. knowlesi* infection was diagnosed by blood film and mucormycosis was diagnosed by histopathological examination of biopsy specimen of the colon. The patient recovered with antimalarial treatment (Quinine), antifungal treatment (Lipophilic Amphotericin), and supportive hemodialysis treatment.

Conclusions: We hypothesize that *P. knowlesi* malarial infection can lower the immunologic threshold and predisposes vulnerable individuals to rare disseminated fungal infections. To the best of our knowledge, this is the first *P. Knowlesi* malaria-associated invasive fungal infection reported in the literature.

Key words: *Plasmodium knowlesi* • malaria • mucormycosis • gastro-intestinal bleeding • acute kidney injury

Full-text PDF: <http://www.amjcaserep.com/download/index/idArt/883879>



971



—



2



15

Background

Plasmodium knowlesi (*P. Knowlesi*) is a malarial parasite of monkeys, transmitted by mosquitoes of the *Anopheles leucosphyrus* group [1]. Previously, *P. knowlesi* infections were thought to be rare in humans, but following a number of reports from Southeast Asian countries, it is now widely regarded as the fifth malaria parasite [2]. Naturally occurring *P. knowlesi* infections, misdiagnosed microscopically as *Plasmodium malariae* (*P. malariae*), accounted for over half of all malaria cases in a study conducted in Sarawak [3]. However, *P. knowlesi* infections usually have greater parasitemia and therefore have a more severe clinical presentation and course than *P. malariae* infections [2]. Patients with uncomplicated disease can be treated by chloroquine, quinine or artemether-lumefantrine, and those with severe disease can be treated with intravenous quinine or artesunate. [4].

Gastrointestinal mucormycosis is rare and accounts for only 7% of all mucormycosis [5]. In a study [6] of 87 patients with gastrointestinal mucormycosis, the most commonly affected sites were the stomach 57.5%, colon 32.2%, small bowel 10.4%, and oesophagus 7%. The hallmark of mucormycosis is vascular invasion leading to endarteritis thrombosis, resulting in tissue ischemia and infarction. Therefore, an ischemic colitis-like presentation is a common in colonic mucormycosis. However, the clinical presentation of colonic mucormycosis can be nonspecific, ranging from nonspecific abdominal pain to diarrhea and perforation [6].

Case Report

A 59-year-old Malay man was admitted to a medical intensive care unit with a 1-week history of fever and reduced urine output. Apart from being hepatitis B-positive and a previous history of cholecystitis, he had no other significant medical problems. Due to an acute hemodynamic compromise from septicemia, he was put on ventilatory support 1 day after admission. He was also started on broad spectrum empirical antibiotics (Ceftazidime and Co-amoxiclav). Renal replacement support was initiated due to acute kidney injury (urea 51.3 mmol/L, creatinine 558 micromol/L, potassium 4.9 mmol/L) and acidosis. Ultrasound of kidneys was normal and there was no proteinuria. His liver function test was normal. Blood film investigations showed red blood cells heavily infected with trophozoites and schizont-form *Plasmodium knowlesi* (Figure 1) and he was started on Quinine. Twelve days into his admission, he developed melena, with a significant drop in hemoglobin level. Esophago-gastro-duodenoscopy did not reveal a source of bleeding, but colonoscopy a day later showed a circumferential ulcer with irregular edges at 40 cms in the sigmoid colon and another superficial ulcer at the proximal

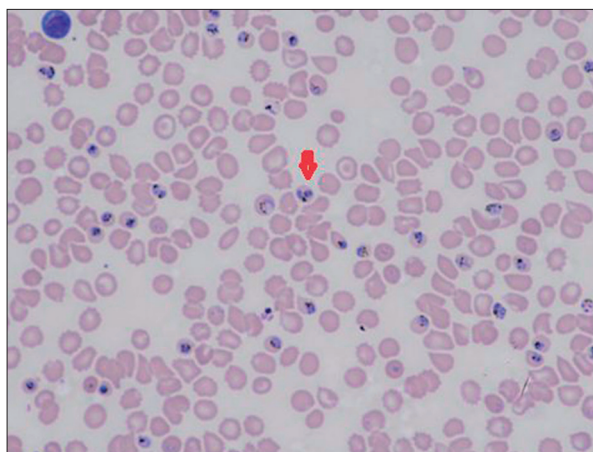

Figure 1. Peripheral blood film.

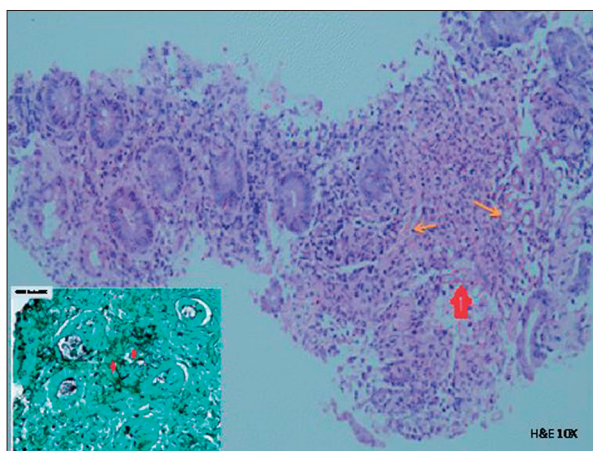


Figure 2. Colonic Biopsy: Broad aseptate fungal hyphae in lamina propria. Inset shows black fungal hyphae stained by Gomori Methemamine Silver Stain (GMS Stain).

ascending colon. Biopsies of the ulcers showed broad fungal hyphae aseptate with right angled branching in the lamina propria and vessels consistent with mucormycosis infection (Figure 2). The patient was treated with liposomal amphotericin for 6 weeks at a dose of 1mg/kg/day and he made an uneventful recovery. He was able to cease renal replacement therapy 20 days after commencement and was successfully discharged 57 days after admission. His serum creatinine upon discharge was 116 micromol/L.

Discussion

Literature reports of *P. knowlesi*-associated kidney injuries are rare. A recent case series from Sabah, Malaysia [4] revealed that 12 out of the 22 patients with WHO classified 'severe' *P. knowlesi* malaria developed acute kidney injury; 11 of the 12 patients required dialytic support, with median duration of

dialysis 3 days (range 1–6 days). Cyrus Daneshvar et al. [7] reported 3 cases of acute kidney injuries (serum creatinine >265 micromol/l, despite fluid resuscitation) from a case series of 8 severe *P. knowlesi* infections. Cox-Singh et al., [8] reported a case of acute kidney injury in a patient with *P. knowlesi* infection, with post-mortem evidence of acute tubular necrosis. Studies in monkeys have shown that the infections reduce glomerular filtration rate and increased glomerular permeability to albumin [9]. Another study showed that *P. knowlesi* significantly reduced renal blood flow in monkeys [10].

There are also very few reported cases of lower gastrointestinal bleeding due to mucormycosis. One was caused by a mixed infection of mucormycosis with cytomegalovirus in a renal transplant patient [11]. Anand et al., [6] reported a similar case of bleeding from colonic mucormycosis from our institution. Diagnoses of both cases were only made after histopathological examination. Invasive gastrointestinal mucormycosis carries a high mortality of over 90%. Mucormycosis can also frequently occur in patients with renal disease [12]. This is probably related to the innate immunosuppressive state of most renal patients and there appear to be no direct causative link between mucormycosis infections and intrinsic renal disease. Most kidney injuries are related to tubular damage from septicemia rather than direct toxic damage to glomeruli, vessels, or interstitium.

Our patient had simultaneous *P. knowlesi* and mucormycosis infections and made a complete recovery from both acute

infections with aggressive medical and supportive treatment. Judging by the chronology of events, it is likely that the acute malarial infection may have dampened his natural immune state and predisposed him to invasive mucormycosis gastrointestinal infection leading to acute lower gastrointestinal bleeding. This hypothesis is supported by a case report from Wilson et al. [13] who reported disseminated opportunistic fungal infections (*Aspergillus flavus* and *Absidia corymbifera*) secondary to presumed immune suppression from co-existing falciparum malaria. Severe falciparum malaria infections had also been linked to disseminated hyalohyphomycosis [14] and invasive pulmonary aspergillosis [15] in previously immune-competent patients. It is also possible that he may already have had chronic mucormycosis colonization in his gastrointestinal tract and this septic malarial episode may have lowered his coagulopathic threshold, leading to the bleeding incident. His renal presentation was in keeping with acute tubular necrosis, which is often seen in septicemic patients with multi-organ failure.

Conclusions

We conclude that *P. knowlesi* and mucormycosis infections can occur simultaneously, especially in a patient population with endemic *P. knowlesi* and when patients are immunocompromised. To the best of our knowledge, this is the first case of *P. knowlesi* malaria-associated invasive fungal infection reported in the literature. Prompt aggressive treatment with antibiotics and supportive therapy can lead to a favorable outcome.

Reference:

1. Tan CH et al: Bionomics of *Anopheles latens* in Kapit, Sarawak, Malaysian Borneo in relation to the transmission of zoonotic simian malaria parasite *Plasmodium knowlesi*. *Malar J*, 2008; 7: 52
2. Sabbatani S, Fiorino S, Manfredi R: The emerging of the fifth malaria parasite (*Plasmodium knowlesi*): a public health concern? *Braz J Infect Dis*, 2010; 14(3): 299–309
3. Singh B, Daneshvar C: *Plasmodium knowlesi* malaria in Malaysia. *Med J Malaysia*, 2010; 65(3): 166–72
4. William T et al: Severe *Plasmodium knowlesi* malaria in a tertiary care hospital, Sabah, Malaysia. *Emerg Infect Dis*, 2011; 17(7): 1248–55
5. Agha FP, Lee HH, Boland CR, Bradley SF: Mucormycoma of the colon: early diagnosis and successful management. *AJR Am J Roentgenol*, 1985; 145: 739–41
6. Anand J, Ghazala K, Chong VH: Massive lower gastrointestinal bleeding secondary to colonic mucormycosis. *Med J Malaysia*, 2011; 66(3): 266–67
7. Cyrus Daneshvar et al: Clinical and Laboratory Features of Human *Plasmodium knowlesi* Infection. *Clin Infect Dis*, 2009; 49(6): 852–60
8. Cox-Singh J et al: Severe malaria – a case of fatal *Plasmodium knowlesi* infection with post-mortem findings: a case report. *Malaria J*, 2010; 9: 10
9. Areekul S: Renal clearance, tubular reabsorption and urinary excretion of albumin in monkeys infected with *Plasmodium knowlesi*. *Southeast Asian J Trop Med Public Health*, 1987; 18(1): 59–65
10. Areekul S: Renal plasma flow in rhesus monkeys infected with *Plasmodium knowlesi*. *Southeast Asian J Trop Med Public Health*. 1987 Jun;18(2): 186-92.
11. Ju JH et al: Successful treatment of massive lower gastrointestinal bleeding caused by mixed infection of cytomegalovirus and mucormycosis in a renal transplant recipient. *Am J Nephrol*, 2001; 21(3): 232–36
12. Boelaert JR et al: Deferoxamine therapy and mucormycosis in dialysis patients: report of an international registry. *Am J Kidney Dis*, 1991; 18(6): 660–67
13. Wilson AP, Wright S, Bellingan G: Disseminated fungal infection following falciparum malaria. *J Infect*, 2000; 40(2): 202–4
14. Däbritz J, Schneider M, Just-Nuebling G, Groll AH: Minireview: Invasive fungal infection complicating acute *Plasmodium falciparum* malaria. *Mycoses*, 2011; 54(4): 311–17
15. Eckerle I, Ebinger D, Gotthardt D et al: Invasive *Aspergillus fumigatus* infection after *Plasmodium falciparum* malaria in an immuno-competent host: case report and review of literature. *Malar J*, 2009; 8: 167