

Laparoscopic-assisted mini percutaneous nephrolithotomy for treatment of large calculi in pelvic ectopic kidney

Ketan P. Vartak, Prashant H. Salvi

Department of Urology, Pramodini Urology Foundation, Pune, Maharashtra, India

Abstract We report two cases of male patients with pelvic ectopic kidney with large stones cleared with laparoscopic-assisted minimally invasive percutaneous nephrolithotomy (Mini-PERC) and holmium laser. These are the first cases of Mini-PERC done for pelvic ectopic kidney reported thus far.

Key Words: Ectopic kidney, laparoscopic minimally invasive percutaneous nephrolithotomy, RIRS, pyelolithotomy

Address for correspondence:

Dr. Ketan P. Vartak, Pramodini Urology Foundation, 917/20 A, F.C. Road, Opposite Hotel Vaishali, Pune - 411 004, Maharashtra, India.
E-mail: kpvartak@gmail.com

Received: 31.12.2015, Accepted: 08.04.2016

INTRODUCTION

Although the treatment modalities for stones in anatomically normal kidneys are well established, there are no clear guidelines for ectopic or malrotated kidneys as the anatomy is variable and hence decisions have to be taken on a case by case basis. This depends on the size and location of stones, location and anatomy of the renal unit, and age and anatomical problems in the patient.

The incidence of pelvic ectopic kidneys is 1 in 2200 to 1 in 3000.^[1] The various modalities that can be offered to the stones in pelvic ectopic kidneys are extracorporeal shock wave lithotripsy (ESWL), open surgery, laparoscopic pyelolithotomy, retrograde intrarenal surgery (RIRS), or laparoscopic-assisted percutaneous nephrolithotomy (PCNL).

Although the ESWL is a good modality, it has a success rate of 54%^[1] due to hindrance of bowel gas and poor clearance

due to anatomical constraints. Open surgery is a good modality for renal pelvic stones but is difficult for intrarenal or calyceal stones due to limited exposures of pelvi-calyceal system (PCS) in ectopic kidneys. Further, there is a lot of morbidities as compared to other modalities. RIRS is a good modality for stones less than 1.5 Cm. in size; however as the stone size increases, the difficulty of surgery & the stone clearance rate worsens. However, it is the best option if we consider the morbidity or postoperative pain and recovery.

These are the first documented cases.

CASE REPORT

A 60-year-old male patient presented with complaints of pain in abdomen for 15 days, sudden onset, spasmodic type of pain, localized to umbilical and left iliac fossa, radiating to back. The patient gave history of two to three episodes of vomiting.

This is an open access article distributed under the terms of the Creative Commons Attribution-NonCommercial-ShareAlike 3.0 License, which allows others to remix, tweak, and build upon the work non-commercially, as long as the author is credited and the new creations are licensed under the identical terms.

For reprints contact: reprints@medknow.com

How to cite this article: Vartak KP, Salvi PH. Laparoscopic-assisted mini percutaneous nephrolithotomy for treatment of large calculi in pelvic ectopic kidney. Urol Ann 2017;9:174-6.

Access this article online

Quick Response Code:



Website:

www.urologyannals.com

DOI:

10.4103/0974-7796.204189

Clinical examination did not reveal any abnormality.

Radiological investigations

Ultrasonography (USG) of the abdomen and pelvis was suggestive of left kidney not visualized in left renal fossa, seen in the pelvis suggestive of the left pelvic kidney. Calculus (20 mm) seen in the left renal pelvis caused moderate left hydronephrosis. A few (3–4) small (3–6 mm) size calyceal calculi were also seen. Right kidney normal size and echotexture. The rest was normal.

Xray KUB and IVU was done which shows Left pelvic ectopic kidney with stones and normal right kidney [Figure 1].

Management

Based on history, clinical examination, and radiological investigations, it was diagnosed with left pelvic kidney with 20 mm calculus at renal pelvis. Hence, the decision for laparoscopic minimally invasive PCNL (Mini-PERC) was taken.

Laparoscopy was performed in a supine position through two ports, namely, umbilical (10 mm) and left iliac fossa (5 mm). Bowel loops were mobilized and hydronephrotic left kidney visualized in the left pelvic region. Initial puncture was done from left iliac fossa under C-arm control. Dilatation was done till 16 French (Fr) using the Mini PCNL dilator, and Mini PCNL sheath was introduced. The Mini PCNL scope was inserted and calculi were seen. Approximately 2 cm brown calculi were fragmented using holmium laser. Fragmented calculi pieces were removed using 4 Fr forceps. A 16 cm 4 Fr double J (DJ) stent was placed antegradely and confirmed on the C-arm. Infant feeding tube No. 10 was kept as a nephrostomy. As the puncture in ectopic kidney was done through the upper calyx, it was easy to enter the mid and lower pole to clear all the stones. Pelvic drain was kept through the right port (14 Fr Ryle's tube) to drain peri-nephrostomy urinary leak into the peritoneum. After 48 h, nephrostomy tube was removed. Pelvic drain was removed after nephrostomy drain to check the nephrostomy site leak. The patient got discharged on postoperative day

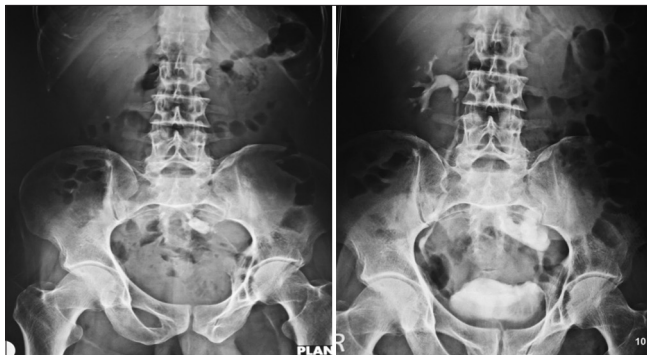

Figure 1: Kidney, ureter, bladder X-ray and intravenous pyelogram

5. Postoperative X-ray of KUB was done which showed no evidence of residual calculi.

Another patient was a 48-year-old man presenting with left flank pain. His USG suggested gross left hydronephrosis due to 19.2 mm and 14.7 mm calculi at pelvi-ureteric junction (PUJ) with papery thin parenchyma with ectopic right kidney with 20.2 mm stone at PUJ.

His clinical examination revealed palpable, tender left kidney. The rest was normal. His creatinine was 1.7 mg/dL and rest of the laboratory investigations was normal.

Computed tomography urography was performed. It showed a grossly enlarged, hydronephrotic left kidney with a dumbbell-shaped stone at PUJ and right pelvic ectopic kidney with 18 mm × 21 mm × 12 mm stone with 1075 HU with renal pelvis facing anteromedially [Figure 2].

He was treated with PCNL on the left side with placement of an integrated DJ stent. After 2 days, his creatinine dropped to 1.3 mg/dL. He was posted for laparoscopic-assisted Mini-PERC on the 4th postoperative day after left PCNL.

As the stone size in both cases was exceeding 20 mm, retrograde intrarenal surgery was not preferred. Furthermore, the clearance of residual stones and gravel is poor in malrotated ectopic kidney. The morbidity of laparoscopic pyelolithotomy and the risk of urinary leak would have been higher. Hence, Mini PCNL was preferred.

DISCUSSION

There are very few case reports of an ectopic kidney with calculi. Regular PCNL was contradicted as there is a chance to damage to bowel loops.

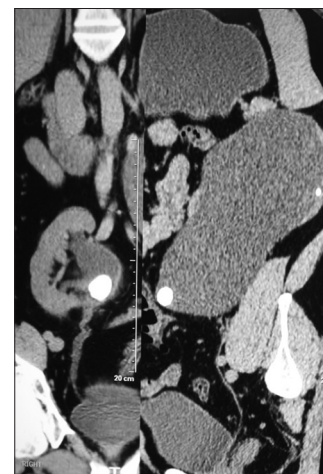


Figure 2: Computed tomography scan

Laparoscopic pyelolithotomy is a good option for renal pelvic large stones.^[2] It might have limitations in calyceal or infundibular stones. Because of the location and configuration of renal PCS of ectopic kidneys can vary, each case requires a unique approach for surgical management of stones. In the situation of an ectopic kidney with laterally or anteriorly directed pelvis, a skilled laparoscopic surgeon can perform a good laparoscopic pyelolithotomy.^[3] However, it is difficult in ectopic kidneys without that kind of anatomy. In addition, a small incision is required to deliver the stone, adding to the morbidity. Laparoscopy-assisted PCNL is an established procedure with all the advantages of PCNL. There are reports of micro Mini-PERC done without the assistance of laparoscopy,^[4] but there is a risk of puncturing bowel and adjacent structures. Hence, laparoscopic assistance is safer. The risk of bleeding and parenchymal injury is more in PCNL as compared to Mini PCNL.^[5] Due to the smaller size of Mini PCNL, it is easier to enter into different calyces and thereby improves stone clearance; hence, laparoscopic-assisted Mini PCNL should be a preferred modality.

RIRS has its own limitations in clearing larger than 1.5 cm stones and a total clearance of residual stones. The risk of sepsis is also much higher as compared to percutaneous procedures.^[6,7] The chances of requiring a multistage approach are also higher in RIRS. It is difficult to clear large stones (>1.5 cm), is more time-consuming, and may require the second procedure and the stone-free rate are inferior to PCNL techniques. It is more so in ectopically located kidneys which have problems with clearing the residual fragments due to high insertion of ureter and abnormal pyeloureteral motility. Furthermore, insertion of flexible ureteroscope is difficult due to abnormal and tortuous course of ureters in pelvic kidneys.^[8] Overall, the stone-free rates of PCNL (94%) techniques are better than RIRS (75%) in stones larger than 2 cm.^[9]

CONCLUSION

Laparoscopic-assisted Mini PCNL is a safe modality to clear large stones in pelvic ectopic kidney with good stone clearance.

Financial support and sponsorship

Nil.

Conflicts of interest

There are no conflicts of interest.

REFERENCES

1. Mehmet RM, Rustu YF, Hanefi B, Mursel D, Fusun A, Mehmet I. Direct pelvic access percutaneous nephrolithotomy in management of ectopic kidney stone: A case report and literature review. *Ren Fail* 2013;35:1440-4.
2. Troxel SA, Low RK, Das S. Extraperitoneal laparoscopy-assisted percutaneous nephrolithotomy in a left pelvic kidney. *J Endourol* 2002;16:655-7.
3. Gupta NP, Yadav R, Singh A. Laparoscopic transmesocolic pyelolithotomy in an ectopic pelvic kidney. *JLS* 2007;11:258-60.
4. Ganesamoni R, Sabnis RB, Mishra S, Desai MR. Microperc for the management of renal calculi in pelvic ectopic kidneys. *Indian J Urol* 2013;29:257-9.
5. Jackman SV, Docimo SG, Cadeddu JA, Bishoff JT, Kavoussi LR, Jarrett TW. The "Mini-PERC" technique: A less invasive alternative to percutaneous nephrolithotomy. *World J Urol* 1998;16:371-4.
6. Zhang W, Zhou T, Wu T, Gao X, Peng Y, Xu C, *et al.* Retrograde intrarenal surgery versus percutaneous nephrolithotomy versus extracorporeal shockwave lithotripsy for treatment of lower pole renal stones: A meta-analysis and systematic review. *J Endourol* 2015;29:745-59.
7. Rehman J, Monga M, Landman J, Lee DI, Felfela T, Conradie MC, *et al.* Characterization of intrapelvic pressure during ureteropyeloscopy with ureteral access sheaths. *Urology* 2003;61:713-8.
8. Cinman NM, Okeke Z, Smith AD. Pelvic kidney: Associated diseases and treatment. *J Endourol* 2007;21:836-42.
9. Bryniarski P, Paradysz A, Zyczkowski M, Kupilas A, Nowakowski K, Bogacki R. A randomized controlled study to analyze the safety and efficacy of percutaneous nephrolithotripsy and retrograde intrarenal surgery in the management of renal stones more than 2 cm in diameter. *J Endourol* 2012;26:52-7.