



Fate of Asymptomatic Limb after Kissing Stents in Aortoiliac Occlusive Disease

Faheem Asem Ahmad, Martin Michael Hennessy, and Alexander Fredrik Nath

Department of Interventional Radiology, Queen Elizabeth University Hospital, Glasgow, United Kingdom

Purpose: Kissing stent angioplasty is an established endovascular treatment strategy for stenosis at the aortic bifurcation but not without its detractors. This study aimed to analyze the outcomes of kissing stents with regard to stent occlusion and complications in which an asymptomatic limb was treated.

Materials and Methods: A total of 106 patients undergoing aortic bifurcation intervention from January 2015 to November 2020 were retrospectively reviewed. Only patients with at least one common iliac artery (CIA) ostium and undergoing bilateral CIA intervention were included in the study.

Results: Patients were followed up for a median period of 26 months (interquartile range, 21–51 months). The TransAtlantic InterSociety Consensus (TASC)-II classification of lesions was as follows: A, 49%; B, 41%; C, 6%; and D, 5%. The treatment indication was limited to one side in 53% of patients. Technical and procedural success rates were 99% and 90%, respectively. Ischemic events in an asymptomatic limb occurred in 6% of cases, 3% due to late stent thrombosis >30 days, and 3% due to progression of downstream infrainguinal disease. Primary and secondary patency rates at 1, 3, and 5 years were 98%, 87%, and 85%, and 99%, 94%, and 94%, respectively. Periprocedural mortality developed in two patients with no amputation.

Conclusion: Kissing stent deployment is a safe and effective strategy for the treatment of aortoiliac bifurcation disease. Unfavorable outcomes due to stenting in the asymptomatic iliac artery are very rare. Long-term surveillance is necessary due to the risk of late thrombosis or downstream disease progression.

Key Words: Interventional radiology, Peripheral arterial disease, Atherosclerosis, Stent, Iliac artery

Received November 2, 2021

Revised December 19, 2021

Accepted March 5, 2022

Published on March 31, 2022

Corresponding author: Faheem Asem Ahmad

Department of Interventional Radiology,
Queen Elizabeth University Hospital,
1345 Govan Rd, Glasgow G51 4TF, United
Kingdom

Tel: 44-0141-201-1100

Fax: 44-0141-201-2217

E-mail: Faheem.ahmad2@ggc.scot.nhs.uk

<https://orcid.org/0000-0003-3886-2936>

Copyright © 2022 The Korean Society for Vascular Surgery

This is an Open Access article distributed under the terms of the Creative Commons Attribution Non-Commercial License (<http://creativecommons.org/licenses/by-nc/4.0>) which permits unrestricted non-commercial use, distribution, and reproduction in any medium, provided the original work is properly cited.

Cite this article; Vasc Specialist Int 2022. <https://doi.org/10.5758/vsi.210074>

INTRODUCTION

Endovascular treatment has gained an increasing preference for the treatment of complex aortoiliac vascular diseases [1]. Aortobifemoral (ABF) bypass may yield better long-term patency rates but is associated with significant postoperative morbidity (8%–13%; including hemorrhage, sepsis, and heart failure) and mortality (up to 5%) [2–5].

Percutaneous approaches allow for faster patient recovery and shorter inpatient stay. Endovascular intervention is recommended for less complex lesions graded TASC-II class A and B, with comparable short- and medium-term outcomes now being shown for classes C and D [1,6].

Küffer et al. [7] pioneered the kissing stent technique for reconstruction of the aortic bifurcation. During this procedure, stents are placed across both limbs of the common

iliac artery (CIA) and inflated simultaneously. This approach minimizes plaque shift, preserves the native ostia, and reduces distal embolization down the contralateral unaffected limb [8,9]. Concerns remain regarding vessel dissection and thrombosis, particularly in asymptomatic or undiseased limbs [9-12]. The data remains sparse, with many studies hampered by small patient numbers and limited follow up periods [13]. Dated studies have also failed to reflect improvements in outcomes using contemporary stent technology and procedural techniques.

Substantive demand has arisen for viable endovascular alternatives, where surgery is no longer a viable option, such as advanced age and comorbidities. We aimed to review our practice of kissing stents in a tertiary vascular referral center and analyze the outcomes of kissing stents focusing on stent occlusion and complications in which an asymptomatic limb was treated.

This study was reviewed by the West of Scotland NHS Research Ethics Service and a formal ethical review was waived (West of Scotland REC 1 IRB 00002179). The written informed consent was waived by the ethics committee.

MATERIALS AND METHODS

The local radiology information system was manually reviewed to identify all aortoiliac intervention cases from January 2015 to November 2020 at our tertiary center. Case records were analyzed to determine whether patients met the inclusion criteria. Patient inclusion was limited to true aortoiliac disease at the bifurcation with involvement of at least one CIA ostium up to 1 cm from the bifurcation, and bilateral kissing intervention (either balloon angioplasty or stent) was performed. All patients underwent endovascular intervention through a multidisciplinary team (MDT) review comprising vascular surgeons and interventional radiologists. The practical criteria for choosing a kissing versus single-stent approach were left to the discretion of the individual teams. In general, a kissing stent approach was selected for complex aortoiliac bifurcation lesions involving the distal aorta and bilateral ostia of CIAs, and asymmetric aortoiliac lesions involving the unilateral CIA ostium, as per the currently accepted best practice.

Fluoroscopic angiographic images were examined by an interventional radiologist to determine the TransAtlantic InterSociety Consensus (TASC) classification. Operative records were reviewed to acquire baseline demographic variables, categorize pre-interventional symptoms according to the Fontaine classification system, and determine if symptoms were unilaterally distributed [14]. Each case record was reviewed longitudinally to determine procedural success, in-hospital complications, and the incidence of late

ischemic vascular events defined as recurrent intermittent claudication, stent occlusion, unplanned major amputation, and vascular re-intervention either at the CIA level or more distally. For cases in which intervention was performed on an asymptomatic leg, any subsequent complications to that leg were explored in more qualitative detail.

Vascular access was achieved through bilateral femoral artery punctures, either percutaneously or directly, if the patient underwent concurrent endarterectomy. Lesions were crossed using various methods, either luminal or sub-intimal, but in all cases, luminal re-entry was confirmed prior to treatment, and the lesion was treated from lumen to lumen. The selection of stent type and size was left to the discretion of the interventionalist. Stents were deployed simultaneously to ensure that the vessel flow and ostial integrity were not compromised during contralateral vessel treatment. All patients received maintenance antiplatelet therapy (aspirin 75 mg once daily) for at least one week before the intervention and intra-arterial heparin (50-100 IU/kg) during the procedure. Patients who were already taking clopidogrel before the intervention continued this afterward. All procedures were performed under local anesthesia using vascular closure devices at the end of the procedure. Completion angiography was performed in all cases. Technical success was defined as residual stenosis of $\leq 30\%$.

The patients underwent standard clinical follow-up at 3 to 6 months with ankle-brachial pressure index and duplex scan assessments. Further imaging, such as computed tomography angiography, magnetic resonance angiography, or invasive angiography, was performed only if clinical assessment raised suspicion of vessel restenosis or re-occlusion.

Patency was classified as per Society of Vascular Surgery - International Society for Cardiovascular Surgery (SVS-ISCS) Guidelines [15].

RESULTS

1) Patient demographics

A total of 106 patients were followed for a median period of 26 months (interquartile range [IQR], 21-51 months). None of the patients was lost to follow-up. The mean age was 66 ± 10 years, with a balanced sex distribution (51% male, 49% female). Cardiovascular comorbidities and risk factors are described in Table 1. Unilateral symptoms were observed in 56 patients (53%). The chief complaints were claudication (60%) and chronic limb-threatening ischemia (CLTI, 40%). Most lesions were classified as either TASC A (49%) or TASC B (41%). In 34 cases (32%), at least one CIA was occluded.

2) Procedural outcomes

Technical success was achieved in 99% of the cases, except in one where a heavily calcified occlusion could not be safely crossed. The procedural mortality rate was 2% due to thoracic aortic dissection and abdominal aortic rupture, and the periprocedural in-hospital complication rate was 9% (Table 2). The 30-day all-cause mortality rate was 3%. Major complications included aortic rupture (two

Table 1. Clinical characteristics of kissing stent angioplasty (n=106)

Clinical characteristic	Number	Ratio (%)
Sex, male	54	51
Risk factors		
Hypertension	54	51
Diabetes mellitus	34	32
Chronic kidney disease	12	11
Smoker/ex-smoker	100	94
Pre-interventional Fontaine classification		
II	64	60
III	19	18
IV	23	22
Symptom distribution		
Unilateral	56	53
Bilateral	50	47
Occlusion		
Complete occlusion	34	32
Stenosis	72	68
TASC-II classification		
A	52	49
B	43	41
C	6	6
D	5	5

TASC, Trans Atlantic Inter-Society Consensus.

Table 2. In-hospital outcomes

Variable	n (%)	Description
Technical success	105 (99)	-
Cumulative complications	9 (9)	-
Intra-procedural complication	5 (5)	-
Death	2	Thoracic aortic dissection, abdominal aortic rupture
Vessel dissection	2	Occlusion of external iliac artery requiring additional stenting
Distal embolization	1	Thrombus in tibioperoneal trunk
Post-procedural complication	4 (4)	-
Femoral pseudo-aneurysm	2	Requiring thrombin injection
Hematoma	1	Delayed discharge
Groin infection	1	Prolonged in-patient stay and antibiotics

cases) and groin pseudoaneurysm (two cases managed with thrombin injection). A kissing stent strategy was employed in 89 patients (84%), with the remainder being treated with simultaneous balloon angioplasty. The stent diameter ranged from 6 to 10 mm. Balloon-expandable stents were most commonly used in 61 patients (58%), followed by self-expanding stents in 11 patients (10%) for tortuous vessels and covered stents in 17 patients (16%) for more calcified arteries (Table 3). Most patients (73%) were treated with stainless steel stents, and 33 patients (31%) were discharged on the same day of the procedure. None of the patients required conversion to an open surgery.

3) Follow-up outcomes

During the study period, 21 patients (20%) died of cardiovascular and non-cardiovascular causes, with a median period free from recurrent events of 22 months (IQR, 9.6–38). The number of patients free of recurrence-defined peripheral vascular events at 1, 3, and 5 years was 88%, 70%, and 59%, respectively (Fig. 1). Kaplan–Meier analyses of primary and secondary patency rates were 98% and 99%

Table 3. Devices utilized

Device	Number
Balloon expandable stent	
Visipro (Medtronic, Minneapolis, MN, USA)	61
Self expandable stent	
Smart (Cordis, Miami Lakes, FL, USA)	9
Zilver (Cook Medical, Bloomington, IN, USA)	2
Covered stent	
Advanta (Atrium Medical, Charlotte, NC, USA)	15
Viabahn (Gore Medical, Flagstaff, AZ, USA)	1
VBX (Gore Medical)	1
Balloon only	17

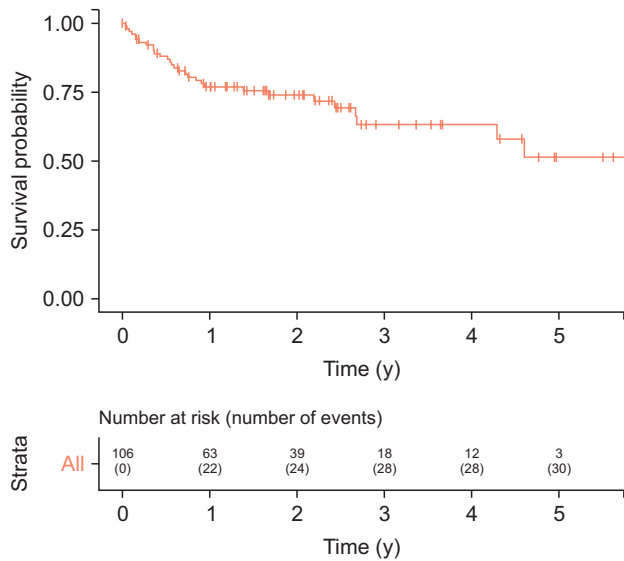


Fig. 1. Kaplan–Meier survival curves showed freedom from recurrent events (recurrent intermittent claudication, stent occlusion, vascular re-intervention to either common iliac artery or leg, and major amputation).

at 1 year, 87% and 94% at 3 years, and 85% and 94% at 5 years, respectively (Fig. 1, 2). Six ischemic events occurred in patients with an asymptomatic limb. Review of primary care notes and prescription data did not reveal any lack of compliance with secondary-prevention pharmacotherapy. Three cases were due to late (>30 days) stent thrombosis resulting from aortoiliac intervention (Table 4). One patient presented with unilateral occlusion and underwent ABF grafting at 6 weeks. Two patients presented with bilateral stent occlusion at 4 and 10 months. The former underwent surgical bypass, while the latter was managed conservatively due to comorbidities. The other three ischemic events in the asymptomatic limb were not related to aortoiliac intervention. All patients presented with worsening recurrent claudication due to downstream disease progression in the infrainguinal arteries, requiring surgical or endovascular intervention. Two patients underwent femoropopliteal bypass grafting at 12 and 24 months, and one patient underwent tibial angioplasty. Only one major amputation developed because of the progression of distal infrainguinal disease (Table 5).

DISCUSSION

Endovascular therapy is a viable alternative to open surgery for the treatment of aortic bifurcation atherosclerosis. Surgical approaches with ABF grafts continue to carry burdensome in-hospital mortality and morbidity (3%–5% and 8%–13%, respectively) [2,3]. Published longer-term patency

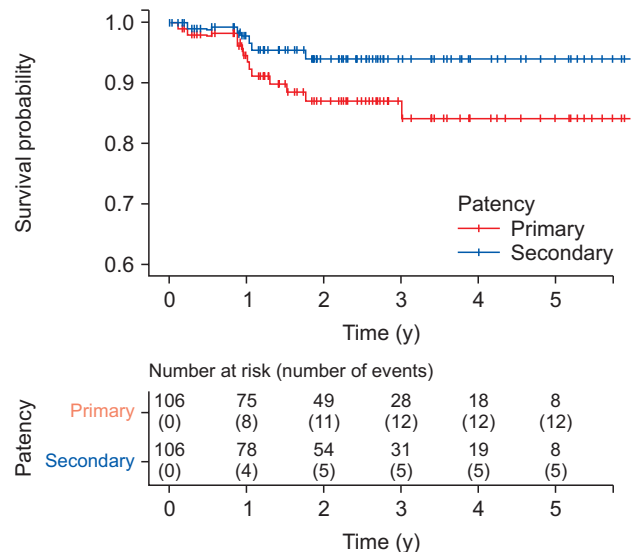


Fig. 2. Kaplan–Meier survival curves showed primary and secondary patency rates.

rates of ABF were better than those of endovascular therapy (87%–91% at 5 years), but this remains a challenge. To the best of our knowledge, this is the first study to specifically address concerns regarding the durability of this procedure in the unaffected contralateral leg in a substantive patient cohort.

This study demonstrated a low frequency of adverse events in the asymptomatic limbs. No complications occurred in 97% of the patients and in three cases (3%), stent occlusion occurred but did not result in major amputation. When comparing these outcomes with other single-stent intervention studies, Suh et al. [16] reported that non-kissing stent strategies resulted in plaque shift to the undiseased limb, with a similar rate of urgent re-intervention required (3%). To date, only Mohamed et al. [13] provided specific data on asymptomatic contralateral limb complications. They recorded an event rate of 13%, with in-stent restenosis rather than occlusion being predominant. These data remain significantly limited by the small numbers (only 24 patients) and truncated follow-up periods (average of 2 years). While our larger study provides a degree of reassurance with a relatively low recorded number of adverse events, the incidence of stent occlusion emphasizes the ongoing importance of meticulous stent placement, appropriate stent sizing, and use of adjunctive antiplatelet therapy. Other factors, such as poor distal run-off and excessive stent protrusion (>20 mm) into the aorta, are postulated as negative influencers of outcome but remain speculative [17].

Our recorded procedural mortality rate of 2% and early 30 day mortality of 3% were within the range of previous reports (0%–2.3%) [13,18–20]. In our series, post-mortem

Table 4. Recurrent events in asymptomatic leg

Complication	n (%)	TASC classification	Stent type	Diameter (mm)	Outcome
Related to CIA intervention	3 (3)				
Unilateral stent occlusion	1	B	Visipro	8	Surgical ABG
Bilateral stent occlusion	2	A	Visipro	8	Surgical ABG
		B	Advanta	7	Conservative management
Unrelated to CIA intervention	3 (3)				
Femoral artery disease	2	A	Balloon	8	Femoral-popliteal bypass
Tibial artery disease	1	A	Visipro	9	Femoral-popliteal bypass
		A	Visipro	10	Tibial artery angioplasty

CIA, common iliac artery; ABG, aortic-bypass graft.

Table 5. Long term recurrent events

Complication	n (%)
Recurrent intermittent claudication	28 (26)
Stent occlusion	8 (8)
Re-intervention (common iliac artery)	7 (7)
Re-intervention (leg)	11 (10)
Amputation	1 (1)

analysis revealed that one patient died of thoracic dissection consequent to adrenergic stress rather than wire intervention (the guidewire also did not pass through the affected region of the thoracic aorta during fluoroscopic screening). Another cause of death was due to unrelated sepsis. Complications occurred in 9% of the patients, which is consistent with the literature (0%-12%). In addition, none of the patients required conversion to open surgery. Incidences of procedural complications and occlusion were also similar to those demonstrated for single-vessel iliac intervention, suggesting that the additive risk of placing an additional stent is marginal [21]. Primary patency rates in this study of 98%, 87%, and 85% (at 1, 3, and 5 years, respectively) compare favorably to larger substantive series enrolling >50 patients, such as by Yilmaz et al. (63% at 3 years) [22], Haulon et al. (79% at 3 years) [23], Björnses et al. (65% at 5 years) [18], and Vértés et al. (77% at 5 years) [17] and begin to approach those of ABF grafts. These series reported higher reintervention rates of up to 30% compared to our observed 7%.

The TASC lesion distribution was reflective of the current recommended practice; 90% of cases were classified as TASC-II A and B [1]. While this composition may suggest a favorable risk profile, other characteristics in this study group were associated with lesion complexity and poorer primary patency, including 60% CLTI, and 32% had at least one occluded CIA [18]. Although prospective randomized controlled trials comparing endovascular therapy against open surgery are lacking, small retrospective series studies

suggest that comparable outcomes can be achieved with stent therapy even for more complex TASC C and D lesions [18,20,24].

Various factors may explain the improvement in procedural and patency outcomes. The routine use of vascular closure devices can reduce the risk of bilateral femoral punctures necessitated by the kissing-stent approach [25]. Newer drug eluting stents theoretically deliver more effective endothelial chemotherapy to dampen neointimal hyperplasia and restenosis, although a consensus on their safety remains pending [26]. Bioabsorbable polymers may further obviate concerns regarding the deployment of a foreign body in asymptomatic vessels [26]. The risk of vessel rupture from intervention in more complex calcified lesions can now be managed through the use of covered stents [27]. As individual and institutional experiences increase, overall proficiency correspondingly develops [28]. This dynamic is optimized by concentrating procedures into high-volume tertiary referral vascular centers.

The strengths of this current study are its large number of patients and long follow-up period. All patients selected for endovascular intervention underwent an MDT review process to reduce selection bias and enhance the applicability to real-world practice. However, while retrospective studies have limitations, our study aimed to provide safety outcome data rather than overturn the existing evidence. There remains a need for high-quality multicenter randomized studies that compare endovascular and surgical techniques across more severe TASC lesion categories.

CONCLUSION

Kissing stent deployment is a safe and effective strategy for treating aortoiliac bifurcation diseases. Unfavorable outcomes due to stenting in the asymptomatic iliac artery are very rare. However, long-term surveillance is necessary due to the risk of late thrombosis or downstream disease progression.

FUNDING

None.

CONFLICTS OF INTEREST

The authors have nothing to disclose.

ORCID

Faheem Asem Ahmad
<https://orcid.org/0000-0003-3886-2936>

Martin Michael Hennessy
<https://orcid.org/0000-0002-9969-0878>
 Alexander Fredrik Nath
<https://orcid.org/0000-0001-7103-1013>

AUTHOR CONTRIBUTIONS

Concept and design: FA and MH. Analysis and interpretation: FAA, MMH. Data collection: FAA. Writing the article: FAA. Critical revision of the article: all authors. Final approval of the article: all authors. Statistical analysis: none. Obtained funding: none. Overall responsibility: all authors.

REFERENCES

- Jaff MR, White CJ, Hiatt WR, Fowkes GR, Dormandy J, Razavi M, et al. An update on methods for revascularization and expansion of the TASC lesion classification to include below-the-knee arteries: a supplement to the inter-society consensus for the management of peripheral arterial disease (TASC II). *Vasc Med* 2015;20:465-478.
- Bredahl K, Jensen LP, Schroeder TV, Sillesen H, Nielsen H, Eiberg JP. Mortality and complications after aortic bifurcated bypass procedures for chronic aortoiliac occlusive disease. *J Vasc Surg* 2015;62:75-82.
- de Vries SO, Hunink MG. Results of aortic bifurcation grafts for aortoiliac occlusive disease: a meta-analysis. *J Vasc Surg* 1997;26:558-569.
- Poulias GE, Doundoulakis N, Prombonas E, Haddad H, Papaioannou K, Lymberiadis D, et al. Aorto-femoral bypass and determinants of early success and late favourable outcome. Experience with 1000 consecutive cases. *J Cardiovasc Surg (Torino)* 1992;33:664-678.
- Nevelsteen A, Wouters L, Suy R. Aortofemoral dacron reconstruction for aorto-iliac occlusive disease: a 25-year survey. *Eur J Vasc Surg* 1991;5:179-186.
- Quan C, Kim DH, Jung HJ, Lee SS. Comparison of results between kissing stent and aortic bifurcated bypass in aortoiliac occlusive disease. *Asian J Surg* 2020;43:186-192.
- Küffer G, Spengel F, Steckmeier B. Percutaneous reconstruction of the aortic bifurcation with Palmaz stents: case report. *Cardiovasc Intervent Radiol* 1991;14:170-172.
- Palmaz JC, Encarnacion CE, Garcia OJ, Schatz RA, Rivera FJ, Laborde JC, et al. Aortic bifurcation stenosis: treatment with intravascular stents. *J Vasc Interv Radiol* 1991;2:319-323.
- Tegtmeyer CJ, Kellum CD, Kron IL, Mentzer RM Jr. Percutaneous transluminal angioplasty in the region of the aortic bifurcation. The two-balloon technique with results and long-term follow-up study. *Radiology* 1985;157:661-665.
- Insall RL, Loose HW, Chamberlain J. Long-term results of double-balloon percutaneous transluminal angioplasty of the aorta and iliac arteries. *Eur J Vasc Surg* 1993;7:31-36.
- Vos T, Flaxman AD, Naghavi M, Lozano R, Michaud C, Ezzati M, et al. Years lived with disability (YLDs) for 1160 sequelae of 289 diseases and injuries 1990-2010: a systematic analysis for the Global Burden of Disease Study 2010. *Lancet* 2012;380:2163-2196. Erratum in: *Lancet* 2013;381:628.
- Brittenden J, Beattie G, Bradbury AW. Outcome of iliac kissing stents. *Eur J Vasc Endovasc Surg* 2001;22:466-468.
- Mohamed F, Sarkar B, Timmons G, Mudawi A, Ashour H, Uberoi R. Outcome of "kissing stents" for aortoiliac atherosclerotic disease, including the effect on the non-diseased contralateral iliac limb. *Cardiovasc Intervent Radiol* 2002;25:472-475.
- Hardman RL, Jazaeri O, Yi J, Smith M, Gupta R. Overview of classification systems in peripheral artery disease. *Semin Intervent Radiol* 2014;31:378-388.
- Rutherford RB, Baker JD, Ernst C, Johnston KW, Porter JM, Ahn S, et al. Recommended standards for reports dealing with lower extremity ischemia: revised version. *J Vasc Surg* 1997;26:517-538. Erratum in: *J Vasc Surg* 2001;33:805.
- Suh Y, Ko YG, Shin DH, Kim JS, Kim BK, Choi D, et al. Outcomes of the single-stent versus kissing-stents technique in asymmetric complex aortoiliac bifurcation lesions. *J Vasc Surg* 2015;62:68-74.
- Vértes M, Juhász IZ, Nguyen TD, Veres DS, Hüttl A, Nemes B, et al. Stent protrusion >20 mm into the aorta: a new predictor for restenosis after kissing stent reconstruction of the aortoiliac bifurcation. *J Endovasc Ther* 2018;25:632-639.

- 18) Björse K, Ivancev K, Riva L, Manjer J, Uher P, Resch T. Kissing stents in the aortic bifurcation--a valid reconstruction for aorto-iliac occlusive disease. *Eur J Vasc Endovasc Surg* 2008;36:424-431.
- 19) Mendelsohn FO, Santos RM, Crowley JJ, Lederman RJ, Cobb FR, Phillips HR, et al. Kissing stents in the aortic bifurcation. *Am Heart J* 1998;136(4 Pt 1):600-605.
- 20) Dorigo W, Piffaretti G, Benedetto F, Tarallo A, Castelli P, Spinelli F, et al. A comparison between aortobifemoral bypass and aortoiliac kissing stents in patients with complex aortoiliac obstructive disease. *J Vasc Surg* 2017;65:99-107.
- 21) Bechter-Hugl B, Falkensammer J, Gorny O, Greiner A, Chemelli A, Fraedrich G. The influence of gender on patency rates after iliac artery stenting. *J Vasc Surg* 2014;59:1588-1596.
- 22) Yilmaz S, Sindel T, Golbasi I, Turkay C, Mete A, Lüleci E. Aortoiliac kissing stents: long-term results and analysis of risk factors affecting patency. *J Endovasc Ther* 2006;13:291-301.
- 23) Haulon S, Mounier-Véhier C, Gaxotte V, Koussa M, Lions C, Haouari BA, et al. Percutaneous reconstruction of the aortoiliac bifurcation with the "kissing stents" technique: long-term follow-up in 106 patients. *J Endovasc Ther* 2002;9:363-368.
- 24) Sharafuddin MJ, Hoballah JJ, Kresowik TF, Sharp WJ. Kissing stent reconstruction of the aortoiliac bifurcation. *Perspect Vasc Surg Endovasc Ther* 2008;20:50-60.
- 25) Patel R, Muller-Hulsbeck S, Morgan R, Uberoi R. Vascular closure devices in interventional radiology practice. *Cardiovasc Intervent Radiol* 2015;38:781-793.
- 26) Brahmabhatt A, Misra S. Techniques in vascular and interventional radiology drug delivery technologies in the superficial femoral artery. *Tech Vasc Interv Radiol* 2016;19:145-152.
- 27) Leung DA, Spinosa DJ, Hagspiel KD, Angle JF, Matsumoto AH. Selection of stents for treating iliac arterial occlusive disease. *J Vasc Interv Radiol* 2003;14(2 Pt 1):137-152.
- 28) Räder SB, Jørgensen E, Bech B, Lönn L, Ringsted CV. Use of performance curves in estimating number of procedures required to achieve proficiency in coronary angiography. *Catheter Cardiovasc Interv* 2011;78:387-393.