

## Endourology

## An exceptional migration of ureteral stent after antegrade placement: A case report



H. Ghaoui-Mansour\*, P. Mortier, Y. Koskas, S. Gaillet, H. Toledano, E. Ragny-Ghazarossian, D. Rossi, C. Bastide

*Urology Surgery Service of Professor Rossi, North Hospital, Marseille, France*

## ARTICLE INFO

**Keywords:**  
Antegrade  
Complication  
Stent  
Heart

## ABSTRACT

We report an exceptional migration of ureteral stent in patient who underwent a robot-assisted laparoscopic right pyelotomy. After stone removal, an antegrade ureteral stenting (7-french; Double J) was performed without fluoroscopic control. A radiographic control was performed the next day and highlighted a migration into the cardiovascular system. The Double J was removed percutaneously through the right femoral vein under fluoroscopic guidance.

## Introduction

Double J (DJ) stents are used to drain urine from the kidney to the bladder or to prevent upper urinary tract obstruction, stenosis and fistula in various urological conditions. It's a routine and easy procedure in urological practice. The DJ stent placement is performed by antegrade or retrograde approach. Ureteral stent migration is a common complication.

We report an exceptional case of DJ migration into the cardiovascular system after antegrade ureteral stenting and the management of this complication.

## Case history

In our department, a 58-yr-old man underwent a robot-assisted laparoscopic pyelotomy for large (5cm) right renal pelvic stone. Medical history included hypertension, asthma, thyroidectomy. Kidney stone was diagnosed by abdominal CT scan after urinary tract infection.

Different therapeutic options were discussed such as: iterative treatments by flexible ureteroscopy, percutaneous nephrolithotomy, extracorporeal shock wave lithotripsy or pyelotomy by robot-assisted laparoscopy. It was decided in agreement with the patient to perform a robot-assisted laparoscopic pyelotomy.

Preoperative bacteriological urine test and blood tests results were normal.

The surgical procedure was performed with the Da Vinci Si system. Operative time was 70mn. No bleeding or preoperative complications were observed. Antegrade ureteral stenting (7-french; 26cm, Double J) was performed without fluoroscopic control.

Day 1 after surgery, a plain abdominal X-ray was performed to check the correct positioning of the DJ stent. The ureteral stent was incorrectly positioned. Indeed, the distal pigtail of the ureteral stent was located in the chest (**Fig. 1**).

A Chest-Abdomen CT scan was performed and showed the distal pigtail of the DJ stent into the right ventricle (**Fig. 2**). The DJ stent passed into the right renal vein, then ascended into the inferior vena cava to the right ventricle. No hematoma or urinoma was observed on a CT scan.

The patient was totally asymptomatic. It was decided to remove the stent by the endovascular procedure with right femoral access. The stent was removed percutaneously. After this endovascular procedure, a DJ stent was placed by retrograde approach without problem.

A prolonged antibiotic prophylaxis was initiated during one week after infectious disease specialist consultation (Imipenem/cilastatin 500mg 3-fold by day).

A preventive anticoagulation therapy during 3 weeks after con-

\* Corresponding author.

E-mail address: [hidie.mansour@ap-hm.fr](mailto:hidie.mansour@ap-hm.fr) (H. Ghaoui-Mansour).

<https://doi.org/10.1016/j.eucr.2019.100932>

Received 21 April 2019; Accepted 30 May 2019

Available online 31 May 2019

2214-4420/ © 2019 Published by Elsevier Inc. This is an open access article under the CC BY-NC-ND license (<http://creativecommons.org/licenses/by-nc-nd/4.0/>).

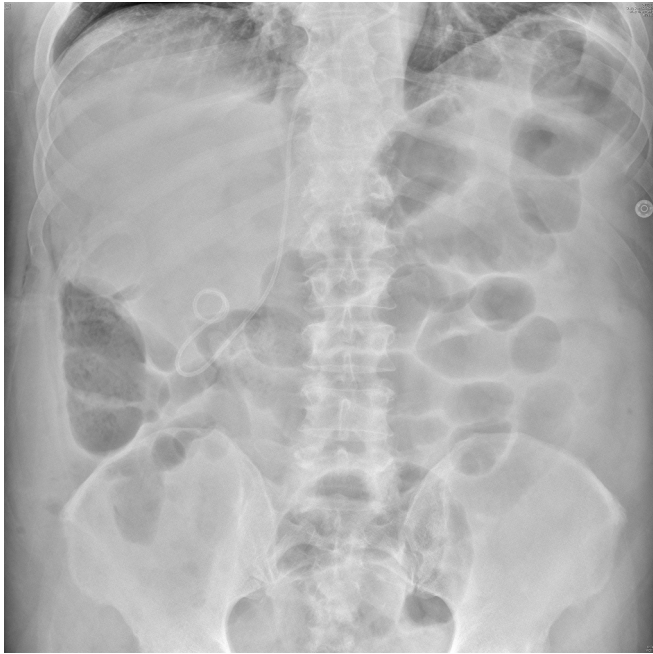

Fig. 1. Plain abdominal X-ray control (day 1 after the surgery).

sultation with cardiologists was initiated. Eight days after surgery, the patient left our department. The DJ stent was removed six weeks later.

## Discussion

Frequent complications induced by DJ stent placement are loin pain, hematuria, lower urinary tract symptoms, vesicoureteral reflux, urinary tract infection, stent migration, encrustation and luminal obstruction.

Our knowledge, only one similar case of intraoperative cardiac migration of a DJ stent after antegrade placement was reported in the literature.<sup>1</sup>

Michalopoulos et al. reported an acute pulmonary embolism immediately after right open pyelotomy for pelvic stone. The antegrade placement of DJ stent was performed without fluoroscopic control. A migration of a DJ stent into the heart and left pulmonary arterial was observed on CT scan. The DJ stent was removed percutaneously by using the femoral vein as an access site.<sup>1</sup>

In these two cases, during the antegrade placement of DJ stent, the guide probably perforated a terminal division branch of the right renal vein, then passed into the renal vein, the inferior vena cava until the

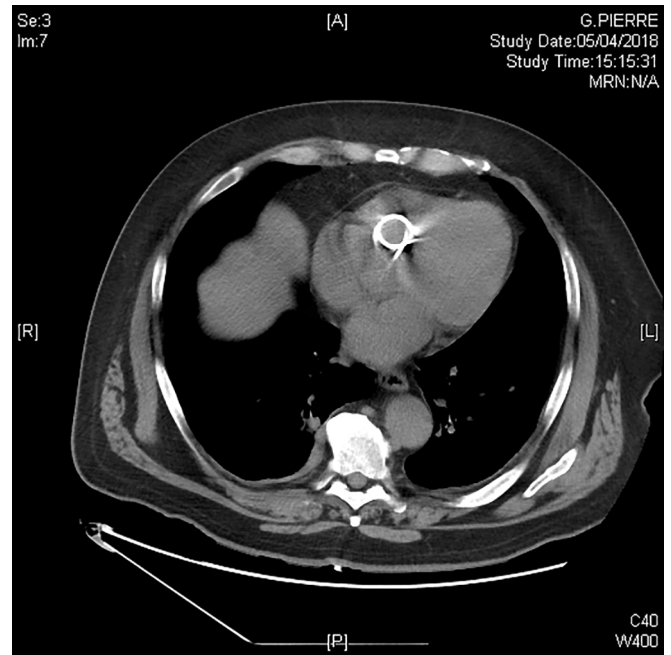


Fig. 2. Chest CT scan.

atrium and the right ventricle.

Conversely, several cases of cardiovascular system DJ stent migration were reported into the literature (Table 1).

To remove DJ stent into cardiovascular system, the best option is a percutaneous procedure under fluoroscopic procedure whenever possible.

The percutaneous procedure is the least morbid. It can be performed under local anesthesia, with a short operating time and the patient can be discharge after only a few days of hospitalization.

Postoperative antibiotic therapy seems necessary since the urine is considered infected.

Several strategies may reduce the risk of such migration: the guidewire should not be forced blindly through the ureter; the surgeon should use hydrophilic wire to prevent passing the wire into the submucosal layer.

The best prevention of this type of complication is the fluoroscopic control of the DJ stent placement. In the absence of fluoroscopy, postoperative X-ray should be considered.

**Table 1**  
Case reports on intracardiac DJ stent migration after retrograde placement.

First author and year	Country	Case history	Removal
<b>Endovascular removal</b>			
Kim et al., 2013 <sup>2</sup>	South Korea	A 29-year-old woman, hemostasis hysterectomy for delivery hemorrhage during an emergency cesarean section. Bladder wound and right ureter, performing a right ureteral reimplantation with intraoperative JJ probe placement.	Removal of the stent by percutaneous, femoral approach.
Arab et al., 2016 <sup>3</sup>	Iran	A 47-year-old patient, DJ placement after ureteroscopy for laser treatment of a low ureter calculation.	Removal by endovascular treatment: femoral approach.
<b>Endoscopic removal</b>			
Özveren et al., 2012 <sup>4</sup>	Turkey	Radiotherapy and chemotherapy after hysterectomy for gynaecological cancer. Placement of a DJ stent for post-radial ureteral stenosis. Iterative change of the probe over the past 3 years.	Removal of the DJ stent by cystoscopy.
<b>Open surgical removal</b>			
Hastaoglu et al., 2014 <sup>5</sup>	Turkey	A 59-year-old woman, placement of a DJ stent for renal colic 3 years previously.	Removal of the ureteral part of the DJ stent by ureteroscopy and then open cardiac surgery to remove the rest of the probe (dissection of a part of the tricuspid valve due to adhesions).

## References

1. Michalopoulos Argyris S, Tzoufi Maria J, Theodorakis George, Mentzelopoulos et Spyros D. Acute postoperative pulmonary thromboembolism as a result of intravascular migration of a pigtail ureteral stent. *Anesth Analg.* 2002;95(5) novembre PMID: 12401589.
2. Kim Tae Nam, Chan Ho Lee, Kong Do Hoon, Dong Kil Shin, Lee et Jeong Zoo. Misplacement or migration? Extremely rare case of cardiac migration of a ureteral J stent. *Korean J Urol.* 2014;55(5) mai <https://doi.org/10.4111/kju.2014.55.5.360>.
3. Arab Davood, Zadeh Arash Ardestani, Eskandarian Rahimeh, Asaadi Mehrshad, Ghods et Kamran. An extremely rare complication of ureteral pigtail stent placement: a case report. *Nephro-Urol Mon.* 2016;8(3) 16 avril PMID: 27570754.
4. Özveren Bora, Şahin et Ahmet. Re: intracaval migration: an uncommon complication of ureteral double-J stent placement. (From: falahatkar S, Hemmati H, Gholamjani Moghaddam K. *J endourol* 2012;26:119–121). *J Endourol.* 2013;27(8):1069–1071 août <https://doi.org/10.1089/end.2012.0656>.
5. Hastaoglu Ismail Oral, Tokoz Hamdi, Kavlak Ela, Bilgen et Fuat. Double J ureteral stent displaced through the right ventricle. *Interact Cardiovasc Thorac Surg.* 2014;18(6):853–854 juin <https://doi.org/10.1093/icvts/ivu037>.