



Tooth hypersensitivity associated with paresthesia after inferior alveolar nerve injury: case report and related neurophysiology

Tae Min You

Department of Advanced General Dentistry, School of Dentistry, Dankook University, Cheonan, Korea

Inferior alveolar nerve (IAN) injury is usually caused by stretching or crushing of the neurovascular structures and postoperative intra-alveolar hematoma or edema after dental procedures. This results in paresthesia in the ipsilateral chin, lip (vermilion border, skin, and mucosa), and labial or buccal alveolar mucosa of the mandibular anterior teeth. However, there are no reports of sensory alterations in the teeth, especially tooth hypersensitivity, after IAN injury. I report a case in which paresthesia of the lower lip and hypersensitivity of the lower anterior teeth occurred simultaneously after the removal of the third molar that was located close to the IAN. In addition, I discuss the reasons for the different sensory changes between the tooth and chin (skin) after nerve injury from a neurophysiological point of view. Since the dental pulp and periodontal apparatus are highly innervated by the inferior alveolar sensory neurons, it seems necessary to pay attention to the changes in tooth sensitivity if IAN injury occurs during dental procedures.

Keywords: Dentin Hypersensitivity; Inferior Alveolar Nerve; Paresthesia.

This is an Open Access article distributed under the terms of the Creative Commons Attribution Non-Commercial License (<http://creativecommons.org/licenses/by-nc/4.0/>) which permits unrestricted non-commercial use, distribution, and reproduction in any medium, provided the original work is properly cited.

INTRODUCTION

The inferior alveolar nerve (IAN) is a branch of the mandibular division of the trigeminal nerve. Anteriorly, at the level of the mandibular 2nd premolar, it gives off the mental nerve, which exits the mandible via the mental foramen. Thereafter, the IAN continues anteriorly within the incisive canal as the incisive nerve. The mental nerve provides sensory innervation to the chin and lower lip, as well as the labial gingiva of the mandibular anterior teeth and premolars; the incisive nerve innervates the mandibular canines and incisors. The IAN carries information regarding tactile and thermal stimuli and nociception to the brain via the dorsal root ganglion [1].

The anatomical position of these nerves places them at an increased risk of injury during dental procedures, such as mandibular third molar removal, dental implant placement, and orthognathic surgery. Damage to the IAN is usually caused by intra-operative stretching or crushing of the neurovascular structures, or excessive pressure on the nerve bundle by postoperative intra-alveolar hematoma or edema [2]. This results in sensory alteration in the ipsilateral chin, lip (vermilion border, skin, and mucosa), and labial or buccal alveolar mucosa of the mandibular anterior teeth. Neurosensory symptoms include a sensation of swelling, tingling, tightness, pricking, shooting, burning, dullness, numbness, and itching, which are diagnosed as hypoesthesia, hyperesthesia, or dysesthesia. The incidence of IAN involvement after mandibular third molar surgery

Received: January 15, 2021 • Revised: March 10, 2021 • Accepted: March 11, 2021

Corresponding Author: Tae Min You, Department of Advanced General Dentistry, School of Dentistry, Dankook University, 119 Dandae-ro, Dongnam-gu, Cheonan-si, Chungnam, 31116, Korea

Tel: +82.41.550.0281 Fax: +82.41.550.0117 E-mail: bestdenmin@naver.com, agdytm@dankook.ac.kr

Copyright© 2021 Journal of Dental Anesthesia and Pain Medicine

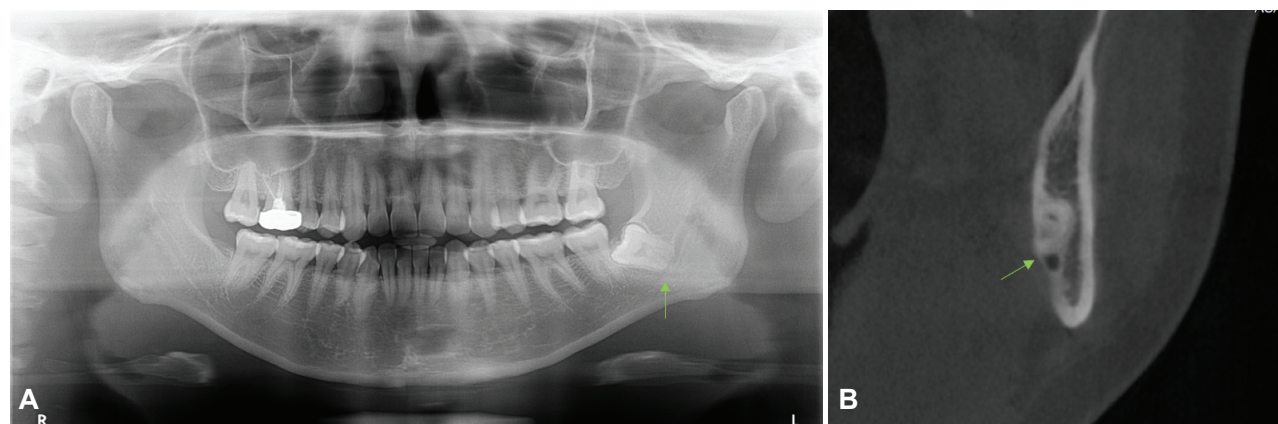


Fig. 1. Preoperative radiographs showing the close approximation of the left lower third molar to the inferior alveolar canal (arrow). (A) Panoramic radiograph (B) Cone beam computed tomography (cross sectional view)

is 1%–5%, and the incidence of sensory disturbance ranges from 0.6%–6.0%. The vast majority (approximately 90%) of these injuries are temporary and resolve within eight weeks. However, if the injury persists beyond six months, it may be permanent [3]. If neurosensory symptoms occur, a 2-month period should be allowed for spontaneous recovery after anti-inflammatory control of damaged nerves, and if there is no recovery, and the patient is symptomatic, surgery should be recommended within six months [4].

In many studies, sensory alteration after IAN injury has been reported in soft tissue areas, and most neurophysiologic quantitative sensory testing is also performed on soft tissues such as the lip and chin [5–7]. However, to the best of my knowledge, there are no reports of sensory changes in the teeth, especially tooth hypersensitivity, after IAN injury. I report a case in which paresthesia of the lower lip and hypersensitivity of the lower anterior teeth occurred simultaneously after the removal of the third molar that was located close to the IAN. In addition, I discuss the reasons for the different sensory changes between the tooth and chin area (skin) after IAN injury, from a neurophysiological point of view.

CASE REPORT

A 33-year-old woman visited the Department of

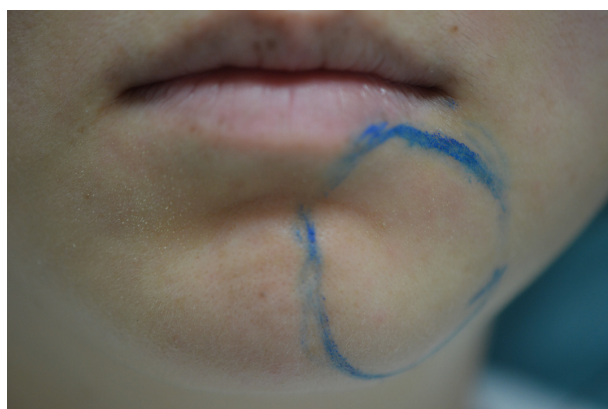

Fig. 2. Skin mapping of the affected area with abnormal sensation: the patient experienced paresthesia from the vermilion border of the lip down to the chin.

Advanced General Dentistry at the Dankook University College of Dentistry for third molar removal in 2020. She had no medical history, and was not on any medication. Radiographic evaluation showed that the left lower third molar was impacted and very close to the inferior alveolar canal (Fig. 1). After informed consent, surgical extraction of lower third molar was performed under IAN block anesthesia using 2% lidocaine with 1:100000 epinephrine (Huons, Sungnamsi, Korea). No intraoperative complications occurred, and the IAN was not visualized during the surgery.

The next day, the patient revisited, complaining of an altered sensation on the left side. The extraction site was not painful, but she felt dullness and swelling in the left half of the lower lip and chin area. She also complained

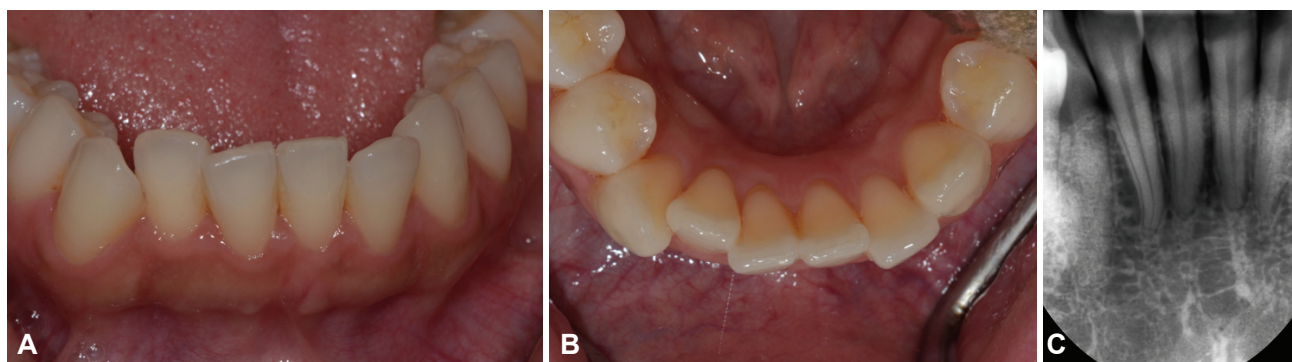


Fig. 3. The affected lower anterior teeth that showed hypersensitivity: (A)(B) Slight crowding is observed, but gingival edema or redness is not observed (C) No periapical lesion or alveolar bone loss are seen in the periapical radiograph

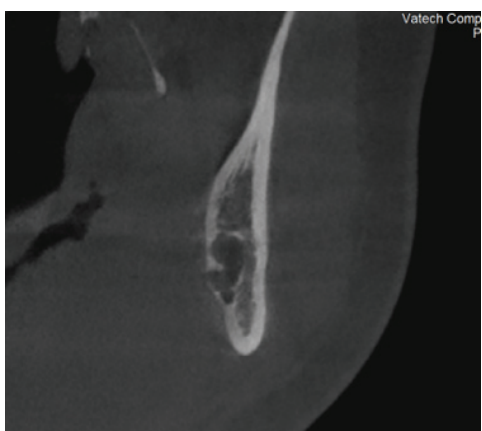

Fig. 4. Postoperative cone-beam computed tomography demonstrating the discontinuity of the upper cortical layer of the inferior alveolar canal (cross sectional view)

of increased sensitivity of the left lower central and lateral incisors to cold stimuli. On clinical examination, paresthesia was observed from the vermilion border of the lip down to the chin, but no edema or redness was observed in the affected area (Fig. 2). Intraoral examination revealed slight swelling and redness of the extraction site, and tenderness in the submandibular area. The lower anterior teeth had slight crowding, but there was no gingival edema or redness around the teeth (Fig. 3 A, B). On radiographic examination, no periapical lesion or alveolar bone loss was observed in the lower anterior teeth (Fig. 3 C). The postoperative cone-beam computed tomography revealed a slight discontinuity of upper cortical layer of the inferior alveolar canal (Fig. 4).

A diagnosis of neurosensory problems of the IAN after third molar removal was made, and neurophysiologic

quantitative sensory testing [3] was performed. To evaluate sensory function, objective symptom tests (brush stroke, pinprick, and two-point discrimination) were performed, and the patient was asked to compare the level of sensory perception on the affected side with that on the unaffected side using a 10-point numeric rating scale (relative affected side score when unaffected side sensation is 10). A cotton swab was gently brushed over the chin area for the assessment of light touch (brush test). A dental explorer was gently pressed on the chin to indent the skin for sharp pain or a pricking sensation (pinprick test). A compass with blunt tips was used to measure the minimum distance between two points that the patient could distinguish on the affected and unaffected sides (two-point discrimination). There was no difference between the left and right sides in the pinprick and two-point discrimination tests, but the left side showed a lower score than the right side in the brush test (Table 1). I performed tooth sensitivity test on cervical area of the lower anterior teeth using an ice stick. The left lower central and lateral incisors had a higher aching response (hypersensitivity) than the adjacent teeth. The response to the percussion test was normal, indicating no inflammation of the periodontal ligament (Table 2). I diagnosed hypoesthesia (paresthesia) of the chin and hyperesthesia (hypersensitivity) of the lower anterior teeth after IAN injury.

To control inflammatory reactions in the injured nerve and improve nerve regeneration, I prescribed steroids, anti-inflammatory drugs, and Vitamin B12. A 30 mg dose

Table 1. The results of neurosensory tests in chin area after inferior alveolar nerve injury*

	Right	Left
Brush test	10	5
Pinprick test	10	10
Two-point discrimination test	9 mm	9 mm

*Relative left side (affected side) score when the right side (unaffected side) sensation was 10.

Table 2. The results of vitality/sensitivity tests in the lower anterior teeth after inferior alveolar nerve injury

	Right		Left			
	Lateral incisor	Central incisor	Central incisor	Lateral incisor	Canine	First premolar
Cold (ice stick) test*	+	+	++	++	+	+
Percussion test**	-	-	-	-	-	-

*+ : Response of normal teeth to an ice stick.

++ : More painful reaction to an ice stick rather than a normal tooth (hypersensitivity)

** - : No pain when tapping the teeth and no inflammation of the periodontal ligament.

(6 tablets of 5 mg) of steroids (Solondo[®], Yuhan, Korea) was prescribed, and the patient was instructed to decrease the dose by 5 mg daily. Ibuprofen 400 mg and Vitamin 0.5 mg (M-Cobal[®], Donghwa, Korea) were prescribed three times daily for 2 week. The patient returned to the clinic two weeks later. The tooth hypersensitivity had disappeared, and the sensory dullness of the lips and chin area decreased. At the follow-up one month later (6 weeks after extraction), the paresthesia of the chin had completely resolved.

DISCUSSION

Seddon classified peripheral nerve injuries into three types: neuropraxia, axonotmesis, and neurotmesis. Neuropraxia is a temporary damage to the myelin sheath without loss of axons, usually lasting an average of six to eight weeks before full recovery [3]. In the present case, the patient possibly had neuropraxia of the IAN, because the altered sensation recovered within 6 weeks. If the IAN is damaged in the third molar region, similar sensory changes (hypoesthesia or hyperesthesia) are expected in all areas of sensory innervation by the nerve. However, in our patient, the touch sensation of the skin was decreased, the pain sensation of the skin remained unchanged, but the sensitivity of the teeth to cold stimuli increased.

The cause of the diversity in sensory changes after nerve injury can be explained as follows:

There are two broad groups of sensory nerve fibers: large, myelinated A-fibers and smaller diameter, unmyelinated C-fibers [8]. A β fibers (6.0-to-12.0 μ m diameter) have a thicker myelin coat, a relatively high conduction speed (35-70 m/s) and convey non-painful tactile stimuli (touch and vibratory sensation). A δ fibers (1.0-to 5.0 μ m diameter) have a thin myelinated sheath, a relatively medium conduction velocity (4.0 to 30 m/sec) and are activated mainly by cold stimuli and fast-onset contact (pricking, probing). C fibers (0.3 to 1.5 μ m diameter) are unmyelinated, have low conduction speed (0.4 to 2.0 m/sec) and are activated by heat stimuli, which are inflammatory mediators implicated in dull aching sensation [9].

The IAN has all three sensory fibers, but the type and density differ by region. The skin is innervated by the thickly myelinated A β fibers (10%), thinly myelinated A δ fibers (20%), and unmyelinated C fibers (60%-90%) [10]. In contrast, the pulp-dentin complex that responds to external stimuli, is innervated mainly by the A δ fibers (A β fibers 7%, A δ fibers 93%) [11]. As the patient showed a decreased response to the brush test, a normal response to the pinprick test, and hypersensitivity in the teeth in response to cold stimuli, it can be inferred that the function of the A β fibers in the skin decreased, the A δ fibers of the skin were normal, and the A δ fibers in

the tooth were hyperactive.

Neurapraxic injuries to the peripheral nerves may be due to ischemia or temporary damage to the myelin sheath. When ischemia for a brief period (such as edema in nearby tissues) is the underlying cause, there are usually no structural changes in the nerve. On the other hand, in neurapraxia with myelin sheath damage, there are anatomical changes affecting the myelin sheath, as the pressure gradient essentially squeezes out the myelin. As a result, the myelin sheath is separated (focal demyelination), and impulse conduction is slowed as the current leaks. Since focal demyelination predominantly affects large nerve fibers [12], we can assume that focal demyelination of the large A β fibers in the area of nerve injury prolonged the time for impulses to reach the threshold and the conduction was markedly slowed, resulting in hypoesthesia in the brush test. However, since small A δ fibers probably did not have myelin damage, there was little change in pain perception in the chin area (pinprick test).

The unique feature of this case is that the lower anterior teeth, which have mainly A δ fibers, were very sensitive to cold stimuli, which differed from the changes in sensitivity in the chin area.

One of the target areas of the IAN endings is the dentin-pulp complex, where the nerve fibers form a dense network of afferent sensory axons. Odontoblasts have processes that extend into the dentinal tubules and mechanosensitive ion channels at their apical poles, close to the sensory terminal web. These structures are mostly involved in thermal and mechanical stimuli and result in classical, short, sharp, and rapid onset pain. This hypersensitivity is a clinical condition encountered daily by dental practitioners, but its mechanism is not completely understood, although several related hypotheses have been suggested [13].

Barron et al. [14] stated that hypersensitivity of the peripheral afferent endings is the result of neuritis caused by a chronic inflammatory process, and A δ fibers appear to contribute to inflammatory hypersensitivity. Diogenes [15] stated in his study that pulpal afferent nerve fibers

demonstrate high plasticity and sprout toward areas of injury, particularly in areas of microbial challenge. The cervical area (cemento-enamel junction) of the tooth adjacent to the gingival sulcus with chronic inflammation is a known area of frequent dentin sensitivity. Therefore, the high density of A δ fibers in the cervical area of the tooth, which is exposed to chronic inflammatory conditions, could be related to a lower threshold response to cold stimuli.

Another possible mechanism could involve the cold receptor, which is expressed in dental afferent neurons. External stimuli trigger dentinal fluid movement and subsequent neuronal depolarization; however, the dental afferent neurons are known to express thermosensitive ion channels, such as transient receptor potential ankyrin type-1 and transient receptor potential melastatin-8. These channels are activated at temperatures below 17°C and 25°C, respectively, and could be involved in the direct transduction of nociceptive signals upon cold stimulus [15,16]. The author speculates that the direct activation of cold receptors within the lower anterior teeth could have induced tooth hypersensitivity by a mechanism different from the A δ fibers in the chin area.

Notably, this patient complained of tooth hypersensitivity only in the anterior teeth and not in the posterior teeth. This could be explained as follows. First, as the anterior teeth are closer to the external environment than the posterior teeth, their frequency of exposure to external stimuli is higher. This patient's IAN injury occurred in winter, so there is a possibility that the patient could easily feel hypersensitivity to the cold stimuli compared to the posterior teeth when talking or breathing. Second, since the anterior teeth are smaller than the posterior tooth, external stimuli can be more easily transmitted to the pulp than in the posterior teeth.

Most of the studies on IAN damage have focused on sensory disturbances in soft tissue areas such as the chin, and lower lip, but to the best of my knowledge, there are no reports of different sensory changes in the teeth and soft tissues. I think that because the soft tissue is exposed to the outside and it easily comes into contact

with external stimuli, patients complain of sensory disturbance in the soft tissue after nerve damage; as a result, dentists have concentrated on it. However, since the dental pulp and periodontal apparatus are highly innervated by inferior alveolar sensory neurons, it seems necessary to pay attention to the changes in tooth sensitivity if IAN injury occurs during dental procedures.

AUTHOR ORCID*s*

Tae Min You: <https://orcid.org/0000-0001-7994-7608>

AUTHOR CONTRIBUTIONS

Tae Min You: Conceptualization, Data curation, Writing — original draft

ACKNOWLEDGEMENTS: The present research was supported by the research fund of Dankook University in 2019 (R-2019-00605).

CONFLICTS OF INTEREST: The author declares no conflicts of interest.

CONSENT: The informed consent was obtained from the patient in this case report. According to the Dankook University Dental Hospital Institutional review board (IRB) policy, case reports are exempt from IRB approval.

REFERENCES

1. Standring S. Gray's Anatomy. 40th ed. ed.: Elsevier. 2008.
2. Coulthard P, Kushnerev E, Yates JM, Walsh T, Patel N, Bailey E, et al. Interventions for iatrogenic inferior alveolar and lingual nerve injury. *Cochrane Database Syst Rev* 2014; CD005293.
3. Pogrel MA. Nerve damage in dentistry. *Gen Dent* 2017; 65: 34-41.
4. Hasegawa T, Yamada SI, Ueda N, Soutome S, Funahara M, Akashi M, et al. Treatment modalities and risk factors associated with refractory neurosensory disturbances of the inferior alveolar nerve following oral surgery: a multicentre retrospective study. *Int J Oral Maxillofac Surg* 2018; 47: 794-801.
5. Van der Cruyssen F, Van Tieghem L, Croonenborghs TM, Baad-Hansen L, Svensson P, Renton T, et al. Orofacial quantitative sensory testing: current evidence and future perspectives. *Eur J Pain* 2020; 24: 1425-39.
6. Dabiri D, Harper DE, Kapila Y, Kruger GH, Clauw DJ, Harte S. Applications of sensory and physiological measurement in oral-facial dental pain. *Spec Care Dentist* 2018; 38: 395-404.
7. Kim HK, Kim KS, Kim ME. Thermal perception as a key factor for assessing effects of trigeminal nerve injury. *J Oral Facial Pain Headache* 2017; 31: 129-38.
8. Jimenez-Andrade JM, Mantyh WG, Bloom AP, Xu H, Ferng AS, Dussor G, et al. A phenotypically restricted set of primary afferent nerve fibers innervate the bone versus skin: therapeutic opportunity for treating skeletal pain. *Bone* 2010; 46: 306-13.
9. Ziccardi VB, Hullett JS, Gomes J. Physical neurosensory testing versus current perception threshold assessment in trigeminal nerve injuries related to dental treatment: a retrospective study. *Quintessence Int* 2009; 40: 603-9.
10. Chapurlat RD, Gensburger D, Jimenez-Andrade JM, Ghilardi JR, Kelly M, Mantyh P. Pathophysiology and medical treatment of pain in fibrous dysplasia of bone. *Orphanet J Rare Dis* 2012; 7 Suppl 1: S3.
11. West NX, Lussi A, Seong J, Hellwig E. Dentin hypersensitivity: pain mechanisms and aetiology of exposed cervical dentin. *Clin Oral Investig* 2013; 17 Suppl 1: S9-19.
12. Kamble N, Shukla D, Bhat D. Peripheral nerve injuries: electrophysiology for the neurosurgeon. *Neurol India* 2019; 67: 1419-22.
13. Magloire H, Maurin JC, Couble ML, Shibukawa Y, Tsumura M, Thivichon-Prince B, et al. Topical review. Dental pain and odontoblasts: facts and hypotheses. *J Orofac Pain* 2010; 24: 335-49.
14. Barron RP, Benoliel R, Zeltser R, Eliav E, Nahlieli O, Gracely RH. Effect of dexamethasone and dipyron on lingual and inferior alveolar nerve hypersensitivity following third molar extractions: preliminary report. *J Orofac Pain* 2004; 18: 62-8.
15. Diogenes A. Trigeminal sensory neurons and pulp regeneration. *J Endod* 2020; 46: S71-80.
16. Son AR, Yang YM, Hong JH, Lee SI, Shibukawa Y, Shin DM. Odontoblast TRP channels and thermo/mechanical transmission. *J Dent Res* 2009; 88: 1014-9.