



## Original Article

### Corresponding Author

Phyo Kim

<https://orcid.org/0000-0002-2957-6463>

Department of Neurologic Surgery,  
Dokkyo University Hospital, 880 Mibu,  
Tochigi, 321-0293, Japan  
Tel: +81-282-87-2159  
Fax: +81-282-86-3276  
E-mail: kim@dokkyomed.ac.jp

Received: February 14, 2018

Revised: March 12, 2018

Accepted: March 12, 2018



This is an Open Access article distributed under the terms of the Creative Commons Attribution Non-Commercial License (<http://creativecommons.org/licenses/by-nc/4.0/>) which permits unrestricted non-commercial use, distribution, and reproduction in any medium, provided the original work is properly cited.

Copyright © 2018 by the Korean Spinal Neurosurgery Society

## INTRODUCTION

Cervical spondylotic myelopathy (CSM) is a common disease among elderlies.<sup>1,2,3</sup> Its prevalence, as assessed by magnetic resonance imaging (MRI) screenings, is reported to be as high as 24% in the population over 65 years old.<sup>3</sup> It causes progressive sensorimotor deficits and deterioration in the quality and independence of daily life. In addition to the typical motor disturbances and sensory symptoms of myelopathy, we occasion-

# Effect of Myoarchitectonic Spinolaminoplasty on Concurrent Hypertension in Patients With Cervical Spondylotic Myelopathy

Kazushige Itoki, Ryu Kurokawa, Tetsuro Shingo, Phyo Kim

Department of Neurologic Surgery, Dokkyo University Hospital, Tochigi, Japan

**Objective:** When treating patients with cervical spondylotic myelopathy (CSM), we often note amelioration in concomitant hypertension after surgery. To assess the effects of surgery and the mechanisms thereof, blood pressure (BP) and parasympathetic nervous activity were monitored prospectively in CSM patients undergoing surgery.

**Methods:** Sixty-eight consecutive CSM patients who underwent surgery with myoarchitectonic spinolaminoplasty were enrolled. BP and electrocardiography were recorded preoperatively and at 1, 3, and 6 months postoperatively. Forty-six patients completed the scheduled follow-ups and were analyzed. Preoperatively, 17 had a mean BP higher than 100 mmHg (the HT group) and 12 had hypertension despite taking medication (the HT-refractory group). To evaluate alterations in parasympathetic function, the coefficient of variation of the RR interval (CVRR) was evaluated.

**Results:** A significant BP reduction was observed in the HT group 6 months after surgery, but not in the normotensive group (n = 29). The effect was more remarkable in the HT-refractory group. A transient BP increase at 1 and 3 months after surgery was observed in all groups. Comparisons were made between groups classified by age (over 65 years or younger than 60 years) and the presence or absence of an intramedullary hyperintense T2 signal on magnetic resonance imaging, but no significant differences were detected. Measurements of CVRR did not significantly differ between the groups over the course of follow-up.

**Conclusion:** Hypertension coexisting with CSM can be ameliorated after surgical treatment. The effect is likely to be mediated by moderation of sympathetic activity, rather than parasympathetic activation. We believe that a combination of adequate decompression of the spinal cord and relief from musculoskeletal stresses effectuate this moderation.

**Keywords:** Cervical spondylosis, Refractory hypertension, Myoarchitectonic spinolaminoplasty, RR interval variance, Parasympathetic tone

ally encounter complaints and symptoms presumably attributable to autonomic nerve actions, such as hypertension, orthostatic hypotension, and dizziness. Postoperatively, patients often report ameliorations in such symptoms along with resolutions of the sensorimotor symptoms. Improvements in preoperative hypertension which had been resistant to medical treatments are repeatedly noted. Hyperactivity of sympathetic nervous system is known to cause intractable hypertension,<sup>4</sup> and it would be conceivable that impingement on the spinal cord may cause

alterations in the autonomic nervous activities. We conducted the present prospective study to assess alterations of blood pressure (BP) and autonomic nerve activity in patients undergoing surgery for CSM.

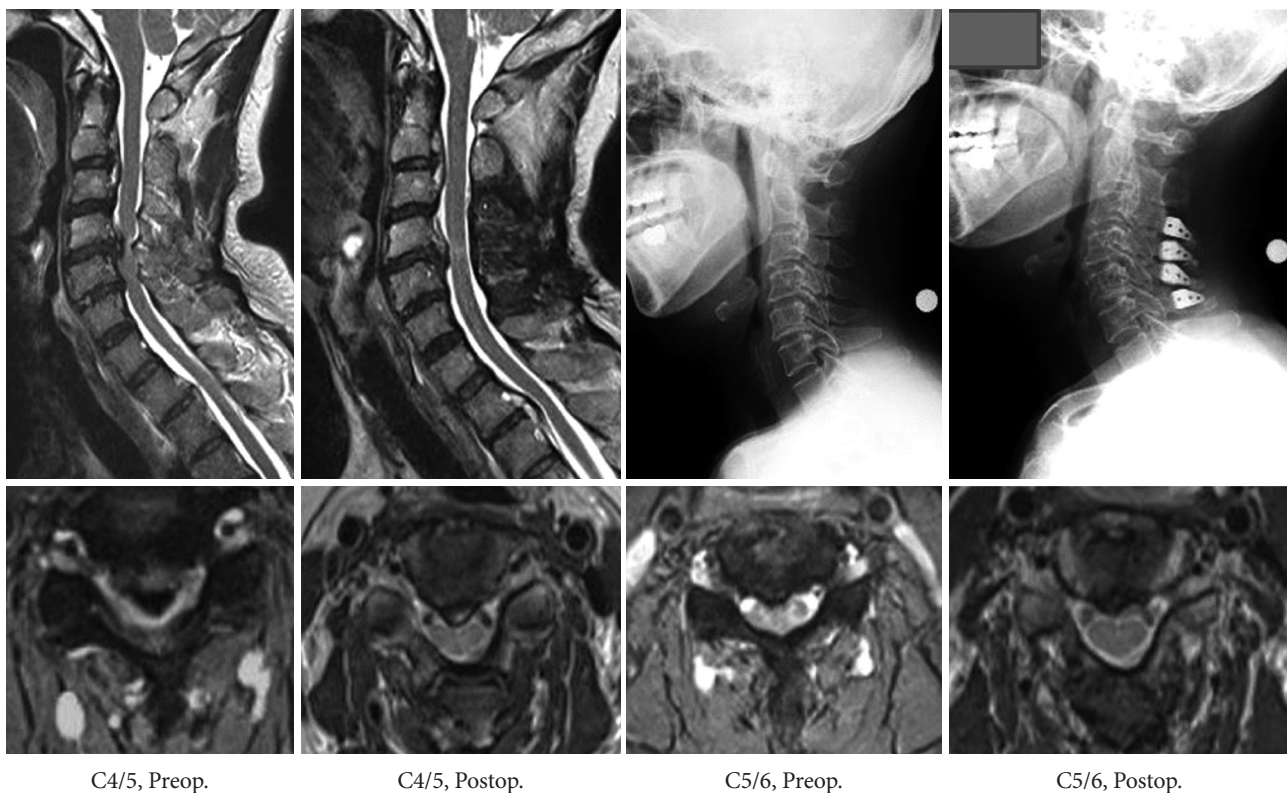## MATERIALS AND METHODS

### 1. Patient Groups

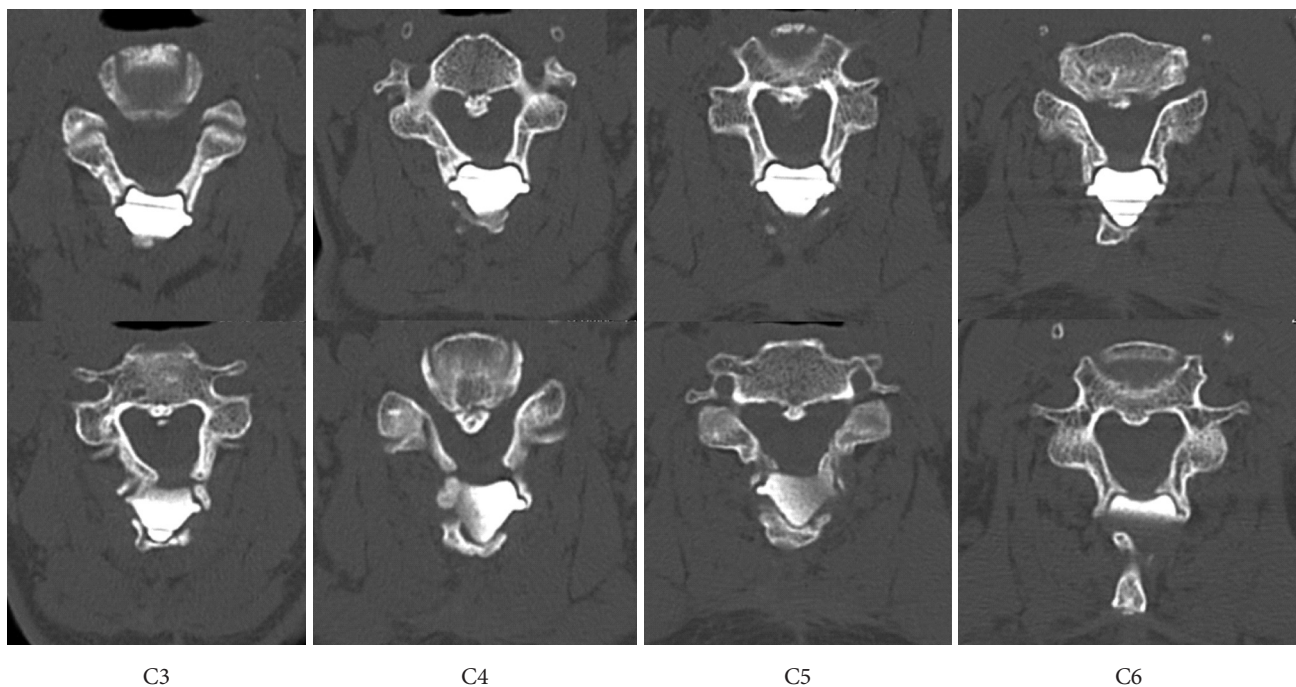
Sixty-eight consecutive patients with CSM who underwent myoarchitectonic spinolaminoplasty (MSLP) of C3, 4, 5, and 6 were included in the study. MSLP is a technical variant of laminoplasty which preserves entire musculoskeletal attachments of the posterior neck (Figs. 1, 2).<sup>5</sup> Its biomechanical efficacy in preservation of alignment, adequate restriction of range of motion, and prevention of postoperative neck pain has been demonstrated.<sup>5</sup> The 68 patients had significant spinal cord impingements on the preoperative MRI studies corresponding to their segmental or long-tract myelopathy symptoms. We did not include patients with CSM who underwent other procedures, such as anterior fusion, conventional laminoplasty or posterior fixations,

or MSLP procedures on the levels different from C3 to C6. Patients with histories of cardiac arrhythmias, ischemic disease, and known atherosclerotic disease were excluded. Patients with factors known to influence the autonomic nervous function, such as diabetes or medications with adrenergic or cholinergic blockers, were excluded as well.

Normal range of BP was defined in the Guideline by Japanese Society of Hypertension as the systolic and diastolic pressure being less than 130 mmHg and 85 mmHg. The combination gives a mean BP (MBP) of 100 mmHg, and the mean value was adopted in the present study as the criterion for hypertension. Patients with MBP greater than 100 mmHg were classified into HT group. Among those, patients with preoperative MBP greater than 100 mmHg despite prescription of antihypertensives, were classified further into HT-refractory group. Patients with MBP less than 100 mmHg were classified into NT group. Patients treated with antihypertensives were classified as medicated group, and those without the treatment as nonmedicated group. Among the patients with MBP less than 100 mmHg (NT group), those treated preoperatively with medications were classified



**Fig. 1.** Treatment of cervical spondylotic myelopathy with myoarchitectonic spinolaminoplasty. A 63-year-old woman presented with disturbances in hand motor control and spastic gait. Postoperative (Postop.) studies were done 1 year after surgery. Note improvement in lordotic alignment along with decompression of the cord. Preop., preoperative.



**Fig. 2.** Osteo-conduction and integration of the hydroxyapatite implants with the lamina, spinous process and muscles, 1 year after myoarchitectonic spinolaminoplasty. The same patient as shown in Fig. 1. All of the musculoskeletal attachments are saved. See text for the technical details.

**Table 1.** Demographic data; patients with cervical spondylotic myelopathy (CSM) and subgroups

Variable	All CSM	HT	NT	Medicated	Nonmedicated	Elderly (≥65 yr)	Middle-aged (≤60 yr)	T2-positive	T2-negative
No. of patients	46	17	29	16	30	13	23	19	27
Sex, male:female	35:11	12:5	23:6	12:4	23:7	9:4	17:6	16:3	19:8
Age (yr)	59.5 ± 10.1	61.8 ± 9.4	58.2 ± 10.4	62.9 ± 9.4	57.7 ± 10.1	70.0 ± 4.9	52.1 ± 8.2	62.7 ± 9.3	57.2 ± 10.2

HT, group with hypertension; NT, group with normal blood pressure; Medicated, group treated with antihypertensive drugs; T2-positive, group with hyper-intense signal on T2WI MRI; T2-negative, group without abnormal intensity on T2WI MRI; T2WI MRI, T2 weighted image magnetic resonance imaging.

into NT-medicated group, and those not taking medications into NT-nonmedicated group. Patients were also divided into groups according to the age (>65 years, elderly group vs. <60 years, middle-aged group). Patients were also grouped according to presence or absence of hyperintense signal in the spinal cord on MRI T2 weighted image (T2WI) in the cord (T2-positive group, T2-negative group). The courses of the BP and coefficient variance of RR intervals (CVRR) prior to and after surgery were compared between the groups (Table 1).

In an independent group of patients undergoing surgery for lumbar stenosis during the same period, BP measurements and electrocardiogram (ECG) recordings were carried out (control-LS group: n = 18; age, 64.4 ± 7.2 years) and compared with the group of patients undergoing the cervical spine surgery.

## 2. Measurement of BP and CVRR on ECG

All patients had BP measurement and ECG monitoring before operation, and postoperatively on the 7th day, 1, 3, and 6 months after surgery. BP was measured using a sphygmomanometer with an automatic pneumatic inflation (Kohrin Seiki, Tokyo, Japan). Patients who missed the scheduled follow-up were excluded from the study. The BP was measured after several minutes of rest in an examination room, and repeated a few to several times, and recorded when the reading became stable. MBP was calculated as the value of diastolic pressure plus one third of the pulse pressure (systolic – diastolic pressure). CVRR was obtained from the recordings of ECG. CVRR is an index based on beat-to-beat variation, and is utilized as an indicator for parasympathetic activity.<sup>6</sup> This index is defined as



the ratio of the standard deviation (SD) of the RR intervals to their average value ( $M$ ), thus  $CVRR (\%) = (SD/M) \times 100$ . ECG was recorded under a well-rested condition. We evaluated postoperative alterations of systolic BP (SBP), diastolic BP (DBP), MBP, and CVRR in ratios relative to the preoperative readings (rSBP, rDBP, rMBP, rCVRR).

### 3. Surgical Treatment

All patients underwent MSLP5 at C3–6 levels (Figs. 1, 2). MSLP is a method variant of cervical laminoplasty and was devised by the authors. The method characteristically preserves the nuchal muscles and reconstitutes all of the musculoskeletal couplings to the posterior elements of the vertebrae. The details of the technique, neurological outcome and biomechanical results are reported elsewhere.<sup>5</sup> Briefly, description of the method is as follows. Patients are positioned prone and linear incision is made in the midline, and myofascia of the three muscle layers are discretely cut in the midline using scalpels, and trapezius (the first layer), semispinalis capitis and splenius capitis (the second layer) are retracted laterally. The spinous processes are split in the midline with muscles remaining attached on both sides (the third layer), and are cut separated at the junction to the lamina. The attachment of semispinalis cervicis to the spinous process are kept intact and the halves of the processes are retracted laterally. The laminae are drilled in the midline with a 3-mm diamond bur (midline gutters) and split completely. Hinge gutters are drilled medial to the junction of the lamina to the facets, and the lamina flaps are elevated with multifidus muscles attached to their caudal edge. The muscle attachments to the posterior surface of the facets, including those of semispinalis capitis, semispinalis cervicis and multifidus are all left intact. After the elevation, the lamina flaps are bridged with trapezoid-shaped implants made of porous hydroxyapatite (HA).<sup>7</sup> HA is the main constituent of naturally occurring bone, and fuses directly with bone and induces osteoconduction on its surface. The bony plates of the split spinous process with attached muscle (semispinalis cervicis) are reapproximated onto the implant. The construct is fused and integrated in 6 to 9 months (Fig. 2). The 3 layers of the myofascia, which constitute the nuchal ligament, are reapproximated and closed tightly in discrete layers. Structural and kinetic elements including muscular attachments to the spinous process, lamina and the posterior surface of the facets are all preserved in the method.

### 4. Data Analysis

The data are expressed as mean  $\pm$  standard error of the mean.

For statistical comparisons of r-BP and r-CVRR values within each subgroup, 1-way analysis of variance was used. For comparison of the courses of alterations between groups, two-way factorial analysis was performed first, and when significant group effect was detected, individual sets of data were further compared using 1-way analysis of variance with critical values of modified t-statistics obtained by the Tukey method. In all comparisons, p-value less than 0.05 were considered as statistically significant. The numbers of patients in each group of data are indicated by  $n$ .

### 5. Ethical Approval

All procedures performed in the study were in accordance with the ethical standards of the institutional and/or national research committee and with the 1964 Helsinki declaration and its later amendments. Informed consent was obtained from all individual participants included in the study.

## RESULTS

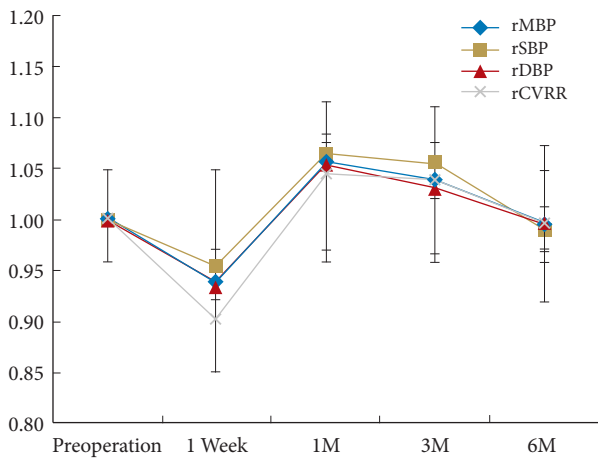
All patients underwent the surgical procedure (Figs. 1, 2) without significant neurological complications. Forty-six patients completed the scheduled protocol of follow-up and were enrolled in the analysis (Table 1). Seventeen of them had preoperative MBP higher than 100 mmHg (HT group; age,  $61.8 \pm 9.4$  years). Among the 17 patients, 11 of them had high BP despite medication (HT-refractory group; age,  $63.9 \pm 9.2$  years). Twenty-nine patients had preoperative value of MBP less than 100 mmHg (NT group; age,  $58.2 \pm 10.4$  years). Among them, 5 patients were on antihypertensive medication (NT-medicated group; age,  $62.9 \pm 9.4$  years). Overall, 16 patients were on medication (medicated group).

When subdivided due to age, 13 patients were older than 65 (elderly group, 65–80 years; mean,  $70.0 \pm 4.9$  years) and 23 were younger than 60 (middle-aged group,  $52.1 \pm 8.2$  years).

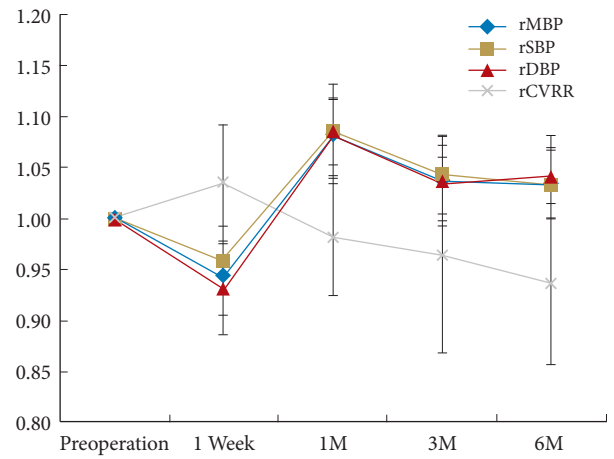
Nineteen patients had hyperintense signal on preoperative MRI T2WI in the spinal cord (T2-positive group; age,  $62.7 \pm 9.3$  years). Twenty-seven patients did not have the abnormality on the T2 WI (T2-negative group; age,  $57.2 \pm 10.2$  years).

When the course of rMBP, rSBP, rDBP, and rCVRR were compared between the group of all the patients with CSM ( $n = 46$ ) and the control-LS group ( $n = 18$ ), no significant difference in the course was detected (Figs. 3, 4). Significant alterations of the parameters were not observed along the course in both groups.

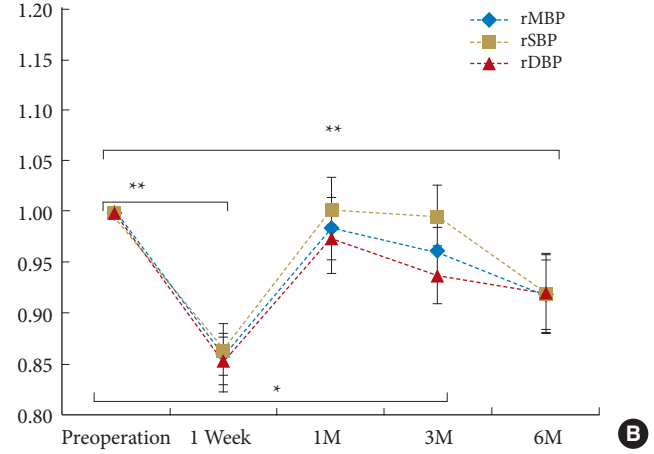
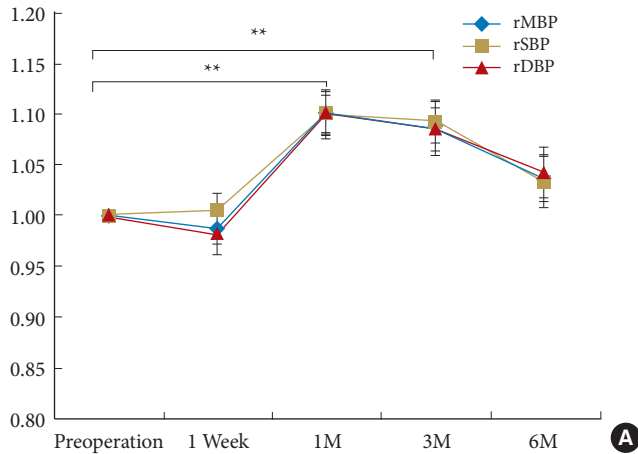
When comparisons were made between NT and HT groups, significant difference was detected in the course of BP (Fig. 5A,



**Fig. 3.** Alteration of blood pressure and coefficient variance of RR (CVRR) interval in the patients with cervical spondylotic myelopathy (n = 46). The postoperative readings of blood pressure and CVRR are expressed in ratio to the preoperative values. No significance was detected in the alterations along the courses of each set of the data. rMBP, ratio of mean blood pressure relative to the preoperative value; rSBP, ratio of systolic blood pressure; rDBP, ratio of diastolic blood pressure; rCVRR, ratio of the coefficient variance of RR interval; M, month.



**Fig. 4.** Alteration of blood pressure and coefficient variance of RR (CVRR) interval in the control group (n = 18). No significant changes were detected in the course of each data. rMBP, ratio of mean blood pressure relative to the preoperative value; rSBP, ratio of systolic blood pressure; rDBP, ratio of diastolic blood pressure; rCVRR, ratio of the coefficient variance of RR interval; M, month.



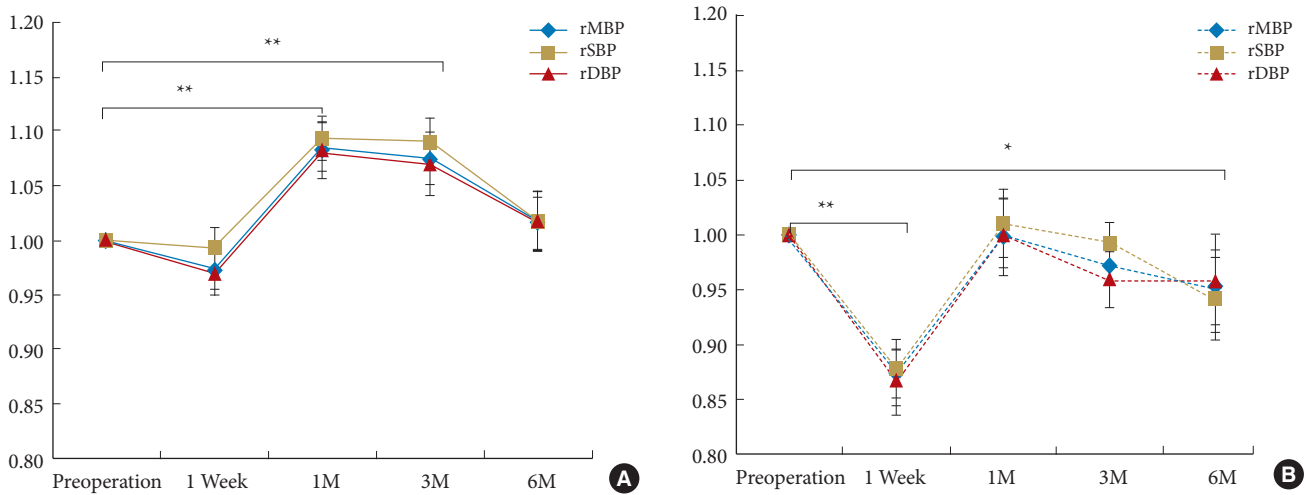
**Fig. 5.** Alteration of blood pressure (BP) in NT group (n = 29) (A) and HT group (n = 17) (B). In the NT group (A), a transient mild increase in the BP parameters were observed in 1 and 3 months after surgery. In the HT group (B), significant decreases in the 3 BP parameters were observed at 1 week and 6 months after the surgery. Diastolic pressure alone decreased as compared to the preoperative value at 3 months. NT, group with normal BP; HT, group with hypertension; rMBP, ratio of mean BP relative to the preoperative value; rSBP, ratio of systolic BP; rDBP, ratio of diastolic BP; rCVRR, ratio of the coefficient variance of RR interval; M, month. \* $p < 0.05$ , statistical significance. \*\* $p < 0.01$ , statistical significance.

B) ( $p < 0.05$ ). When analysis is made along the course in the HT group, rMBP, rSBP, and rDBP decreased significantly at 1 week and 6 months after surgery ( $p < 0.01$ ). At 3 months, a decrease in r-DBP was observed ( $p < 0.05$ ).

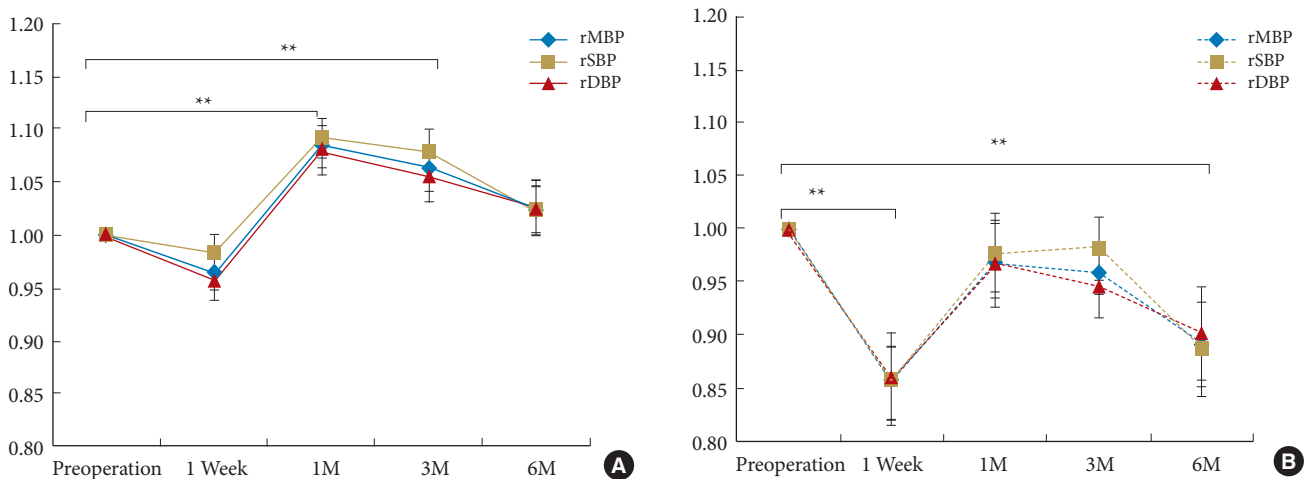
In comparison between nonmedicated group (Fig. 6A) and

medicated group (Fig. 6B) a significant difference in the course of BP was evident ( $p < 0.05$ ).

In the nonmedicated group, transient increase in rMBP, rSBP, and rDBP was observed in 1 and 3 months after surgery ( $p < 0.01$ ). In the medicated group, decrease in the parameters was observed



**Fig. 6.** Alteration of blood pressure (BP) in nonmedicated group (n=30) (A) and medicated group (n=16) (B). In the nonmedicated group, transient increases in the 3 BP parameters were observed in 1 and 3 months after surgery, whereas in the medicated group, decrease was observed in 1 week and 6 months. rMBP, ratio of mean BP relative to the preoperative value; rSBP, ratio of systolic BP; rDBP, ratio of diastolic BP; M, month. \*p < 0.05, statistical significance. \*\*p < 0.01, statistical significance.



**Fig. 7.** Alteration of blood pressure (BP) in cervical spondylotic myelopathy (CSM) patients excluding those with hypertension refractory to medical treatment (n=35) (A) and those in the HT-refractory group (n=11) (B). In the CSM patients excluding the HT-refractory group, transient increases in the BP parameters were observed in 1 and 3 months after surgery, whereas in the HT-refractory group, a significant decrease was observed in 1 week and 6 months. rMBP, ratio of mean BP relative to the preoperative value; rSBP, ratio of systolic BP; rDBP, ratio of diastolic BP; M, month. \*\*p < 0.01, statistical significance.

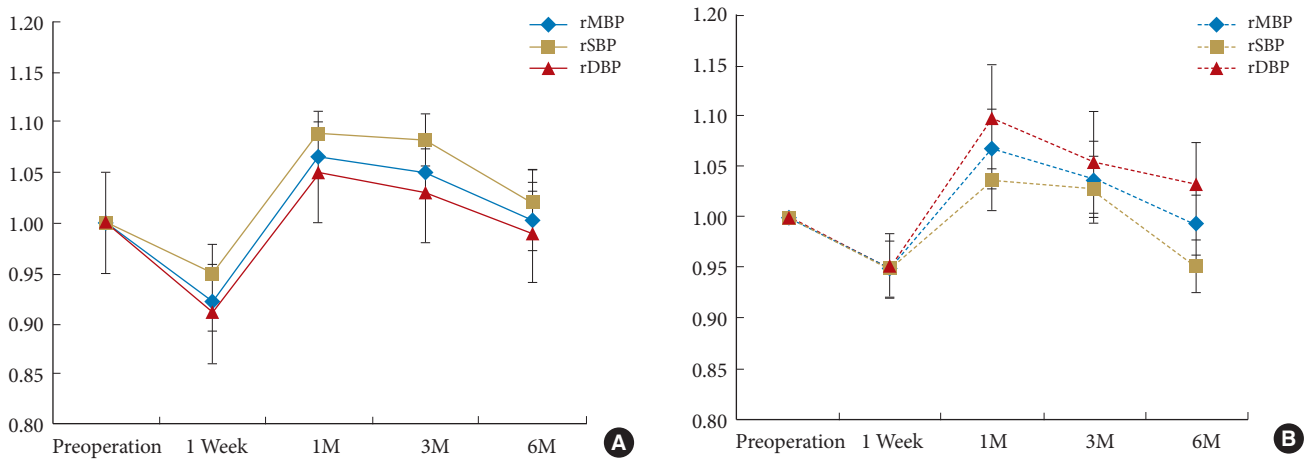
in 1 week (p < 0.01) and 6 months after surgery (p < 0.01).

In the group of CSM patients except for those with hypertension refractory to medical treatment (Fig. 7A), transient increases in the BP parameters were observed in 1 and 3 months after surgery (p < 0.01), whereas in the HT-refractory group (Fig 7B), a significant decrease was observed in 1 week and 6 months (p < 0.01).

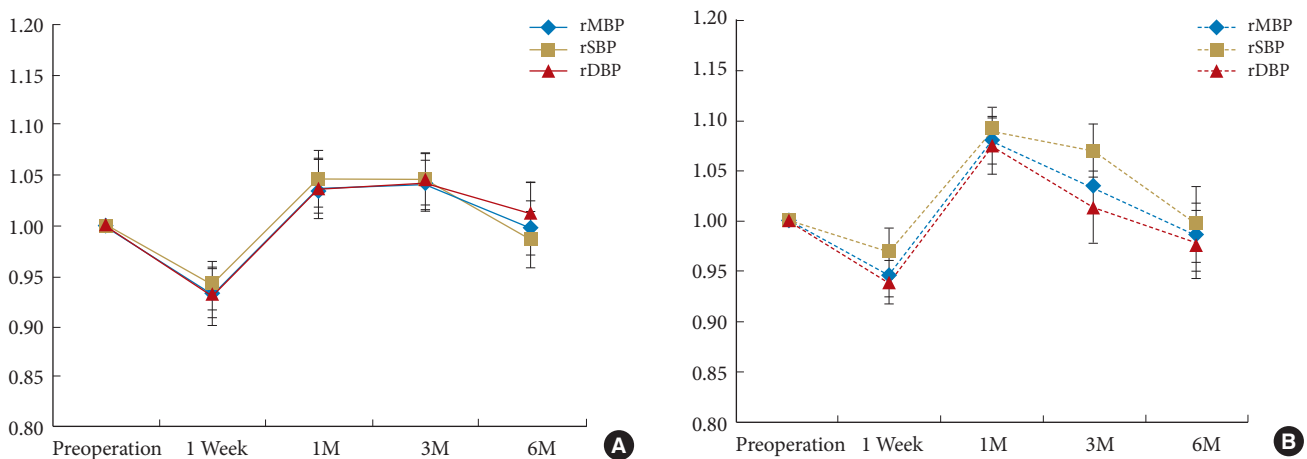
When comparison was made between the groups divided according to age, no differences were detected in the courses of

parameters of BP and CVRR (Fig. 8). Similarly comparison of the groups divided following presence or absence of hyperintense signal on MRI T2WI in the cord revealed no differences in the course of the BP parameters (Fig. 9).

The values of rCVRR showed no significant changes along the postoperative alterations of rBP parameters in the NT and HT groups. When the course of the parameter was compared between the NT, and HT group, no difference was detected between the 2 groups (Fig. 10).



**Fig. 8.** Alteration of blood pressure (BP) in middle-age group (age < 60 years, n = 23) (A) and elderly group (age > 65 years, n = 13) (B). No significant difference in the course of the parameters were detected. rMBP, ratio of mean BP relative to the preoperative value; rSBP, ratio of systolic BP; rDBP, ratio of diastolic BP; M, month.

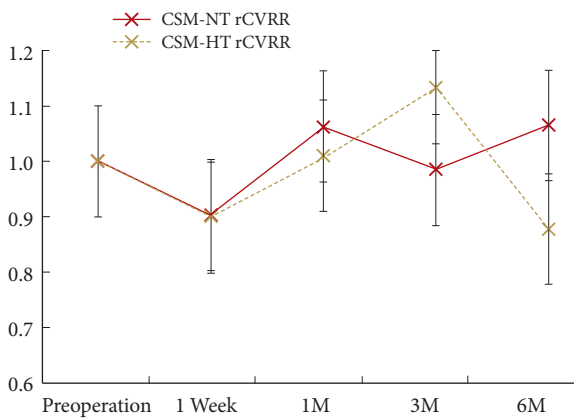


**Fig. 9.** Alteration of blood pressure (BP) in T2-negative group (n = 27) (A) and T2-positive group (n = 19) (B). No significant difference in the course of the parameters was detected. rMBP, ratio of mean BP relative to the preoperative value; rSBP, ratio of systolic BP; rDBP, ratio of diastolic BP; M, month.

**DISCUSSION**

When treating CSM surgically, the indication is determined on the basis of neurological findings and concordant radiological findings. The patients usually present with sensorimotor deficits caused by impairment of the segmental function or long tract conduction in the spinal cord. Besides the typical myelopathic symptoms which usually improve after surgery, we often note postoperative amelioration of adjunctive symptoms such as headache, neck pain, orthostatic dizziness, and hypertension. The present study demonstrated that hypertension coexisting with myelopathy, including that refractory to antihypertensive treatment, improves in 6 months after surgery. The effect is

presumably mediated by multiple mechanisms, such as resolution of cord compression, alleviation of neurogenic pain, relief of musculoskeletal discomfort such as neck or shoulder strain. Our method of MSLP effectively lessens postoperative neck pain by preserving musculoskeletal attachment.<sup>5</sup> Relief of the neurogenic and musculoskeletal symptoms would modulate tonus of the autonomic nervous systems. Result of the present study showed the parasympathetic activities, as assessed by CVRR values, were not altered in the course of decrease in BP. When the BP parameters were decreased at 6 months in the HT group, there was no accompanying increase in rCVRR. The finding indicates parasympathetic activities are not underlying the lowering of BP, and suggests that the changes are mediated by de-



**Fig. 10.** Change of coefficient variance of RR interval (CVRR) in the HT group (n=17) and the NT group (n=29). HT, group with cervical spondylotic myelopathy (CSM) and hypertension at preoperative measurement; NT, group with CSM and normal blood pressure at preoperative measurement; rCVRR, ratio of the coefficient variance of RR interval; M, month.

crease in the sympathetic tone.

### 1. Cervical Spinal Cord and Functional Anatomy of the Sympathetic Nervous System

In patients with cervical spinal cord injury, we observe unstable BP, persistent hypotension or episodes of uncontrolled hypertension.<sup>8</sup> Cardiovascular control is impaired when the cervical spinal cord is injured, and the symptoms include neurogenic shock, autonomic dysreflexia, and orthostatic hypotension.<sup>8,9</sup>

BP control depends upon tonic activation of sympathetic preganglionic neurons by descending input from the supra-spinal structures.<sup>10</sup>

The cardiac sympathetic reflex is mediated by nucleus of solitary tract in the medulla oblongata, as a chief component of the circuitry. The afferent and efferent signal is conducted in the cervical spinal cord.<sup>11</sup> In fact, medullary compression inflicted by elongated vertebral artery has been demonstrated to cause hypertension which tends to be refractory to ordinary medical treatments, and the condition can be reversed by surgical transposition of the offending artery.<sup>12,13</sup> It has been demonstrated that chemical stimulation of the upper cervical spinal cord evokes a potent sympathetic pressure responses, and neurons in the cervical spinal cord which connect to the sympathetic preganglionic neurons participate in the cardiovascular control.<sup>14</sup> Stimulation of the cervical spinal cord is known to affect the cerebral blood flow as well.<sup>15</sup> All these previous findings support the notion that spinal circuits with a descending pathway in the

cervical cord are participating in the control of the thoracic sympathetic preganglionic neuron pool. Therefore it would be reasonable to assume that compression and disturbances of the spinal cord inflicted by impingements cause derangement in the sympathetic outflow and maladjustment of BP, and that the disturbances are to be corrected by adequate decompression.

### 2. Mechanisms of Alteration of BP Following Surgery

When the whole CSM patients were combined altogether, the BP data for the entire group did not show significant decrease after surgery. But when divided into subgroups, the CSM patients with preoperative hypertension (HT group), showed a decrease in BP detected at 1 week and 6 months following surgery. In the subgroup with CSM and medically refractory hypertension (HT-refractory group), decrease in BP was also observed at 7 days and 6 months after surgery. The suppression effect was not observed in the group of patients without hypertension. On the contrary they showed increase in BP at 1 and 3 months after surgery. The discrepancy would be reflecting dysfunction in the cervical spinal sympathetic pathway occurring in those with CSM and hypertension, and not in those with CSM but without hypertension. Our previous study demonstrated that in an experimental model of chronic cervical spinal cord compression, which reproduces the temporal characteristics of clinical CSM,<sup>16</sup> the local spinal cord blood flow is reduced in the compressed segments as compared to noncompressed segment.<sup>17</sup> If similar disturbance in the spinal cord circulation takes place in the condition of clinical CSM, a reflex or autoregulatory mechanism may be in action to raise BP. The mechanism in turn would cause decrease in systemic BP when adequate decompression of the cord and reversal of the circulatory disturbance is achieved. Regarding the decrease of BP observed on the seventh day postoperatively in the HT group, the change may be in part caused by the effect of rest during hospitalization and possibly by relief of psychological factors such as anxiety, both of which would be reducing sympathetic tone. Mild and transient increases of BP observed at 1 and 3 months after surgery in the normotensive patients may reflect increase in their physical activities, resumed social function and increase in sympathetic tone.

## CONCLUSION

CVRR is an excellent indicator of parasympathetic nervous system activities.<sup>6</sup> The method is simple and affordable, and yields reproducible numbers. In the present study, we did not



perform examinations specifically aimed at assessing sympathetic nerve system activity. However, the present finding of relief of hypertension without changes in CVRR suggest that these effects are brought about by normalization of increased sympathetic tone. We believe MSLP, which preserves entire structure and function of the paraspinal muscles, has advantage in this effectuation, if compared to other surgical techniques which violate the structural integrity to some extent and would leave musculoskeletal stresses.

## CONFLICT OF INTEREST

The authors have nothing to disclose.

## REFERENCES

1. Imai T. Cervical spondylotic myelopathy and the anteroposterior diameter of the cervical canal. *Nihon Seikeigeka Gakkai Zasshi* 1970;44:429-38.
2. Ohtsuka K, Terayama K, Yanagihara M, et al. An epidemiological survey on ossification of ligaments in the cervical and thoracic spine in individuals over 50 years of age. *Nihon Seikeigeka Gakkai Zasshi* 1986;60:1087-98.
3. Teresi LM, Lufkin RB, Reicher MA, et al. Asymptomatic degenerative disk disease and spondylosis of the cervical spine: MR imaging. *Radiology* 1987;164:83-8.
4. Benarroch EE, Chang FL. Central autonomic disorders. *J Clin Neurophysiol* 1993;10:39-50.
5. Kim P, Murata H, Kurokawa R, et al. Myoarchitectonic spinolaminoplasty: efficacy in reconstituting the cervical musculature and preserving biomechanical function. *J Neurosurg Spine* 2007;7:293-304.
6. van den Berg MP, Haaksma J, Brouwer J, et al. Heart rate variability in patients with atrial fibrillation is related to vagal tone. *Circulation* 1997;96:1209-16.
7. Kim P, Wakai S, Matsuo S, et al. Bisegmental cervical interbody fusion using hydroxyapatite implants: surgical results and long-term observation in 70 cases. *J Neurosurg* 1998;88:21-7.
8. Krassioukov A, Claydon VE. The clinical problems in cardiovascular control following spinal cord injury: an overview. *Prog Brain Res* 2006;152:223-9.
9. Blackmer J. Orthostatic hypotension in spinal cord injured patients. *J Spinal Cord Med* 1997;20:212-7.
10. Calaresu FR, Yardley CP. Medullary basal sympathetic tone. *Annu Rev Physiol* 1988;50:511-24.
11. Duan YC, Xu B, Shi Z, et al. Nucleus of solitary tract mediates cardiac sympathetic afferent reflex in rats. *Pflugers Arch* 2009;459:1-9.
12. Jannetta PJ, Segal R, Wolfson SK Jr. Neurogenic hypertension: etiology and surgical treatment. I. Observations in 53 patients. *Ann Surg* 1985;201:391-8.
13. Jannetta PJ, Segal R, Wolfson SK Jr, et al. Neurogenic hypertension: etiology and surgical treatment. II. Observations in an experimental nonhuman primate model. *Ann Surg* 1985;202:253-61.
14. Seyedabadi M, Li Q, Padley JR, et al. A novel pressor area at the medullo-cervical junction that is not dependent on the RVLM: efferent pathways and chemical mediators. *J Neurosci* 2006;26:5420-7.
15. Goellner E, Slavin KV. Cervical spinal cord stimulation may prevent cerebral vasospasm by modulating sympathetic activity of the superior cervical ganglion at lower cervical spinal level. *Med Hypotheses* 2009;73:410-3.
16. Kim P, Haisa T, Kawamoto T, et al. Delayed myelopathy induced by chronic compression in the rat spinal cord. *Ann Neurol* 2004;55:503-11.
17. Kurokawa R, Murata H, Ogino M, et al. Altered blood flow distribution in the rat spinal cord under chronic compression. *Spine (Phila Pa 1976)* 2011;36:1006-9.