



Case report

Sigmoid colon diverticula perforation associated with sevelamer hydrochloride administration: A case report



Takahisa Yamaguchi ^{a,*}, Shigekazu Ohyama ^a, Hiroyuki Furukawa ^a, Nariatsu Sato ^a, Ichiro Ohnishi ^a, Satomi Kasashima ^b, Atsuhiko Kawashima ^b, Masato Kayahara ^a

^a National Hospital Organization, Department of Surgery, Kanazawa Medical Center, 1-1 Shimo-Ishibiki, Kanazawa, Ishikawa 920-8650, Japan

^b National Hospital Organization, Department of Pathology, Kanazawa Medical Center, 1-1 Shimo-Ishibiki, Kanazawa, Ishikawa 920-8650, Japan

HIGHLIGHTS

- Sevelamer may contribute to colonic perforation in hemodialysis patients.
- Our patient underwent resection of a perforated portion of sigmoid colon.
- Histopathologically, sevelamer crystals were detected at the site of perforation.

ARTICLE INFO

Article history:

Received 5 May 2016

Received in revised form

24 July 2016

Accepted 24 July 2016

Keywords:

Sevelamer crystal

Colon perforation

Chronic renal failure

Hemodialysis

ABSTRACT

Introduction: Sevelamer is an anion exchange resin used to treat hyperphosphatemia. A common adverse effect of sevelamer is constipation. According to a review of the available literature, colon perforation associated with this resin agent was less common.

Presentation of case: A 66-year-old man complaining of lower abdominal pain was transferred to our hospital. The patient had been undergoing hemodialysis for chronic renal failure due to rapidly progressive glomerulonephritis, and had been receiving sevelamer hydrochloride 4.5 g/day for 8 years as treatment for hyperphosphatemia. Abdominal computed tomography revealed ascites, free air in the abdominal cavity, multiple diverticula of the sigmoid colon, as well as increased fat tissue surrounding the sigmoid colon. We diagnosed colonic perforation and performed emergency surgery, which revealed a 5 × 5 mm perforation in the sigmoid colon surrounded with soft stool. Histopathologically, sevelamer crystals were detected at the perforation site.

Discussion: We theorize that physical stimulation by sevelamer crystals contributed to colon perforation at the already vulnerable diverticulum site.

Conclusion: When sevelamer is administered to patients with hemodialysis, the risk of intestinal perforation should be considered.

© 2016 The Author(s). Published by Elsevier Ltd on behalf of IJS Publishing Group Ltd. This is an open access article under the CC BY-NC-ND license (<http://creativecommons.org/licenses/by-nc-nd/4.0/>).

1. Introduction

Sevelamer is an anion exchange resin used to treat hyperphosphatemia in patients with chronic renal disease [1,2]. It was first approved by the United States Food and Drug Administration in October 1998 as sevelamer hydrochloride (Renagel[®]), and more recently as sevelamer carbonate (Renvela[®]). Sevelamer is calcium free, and therefore does not result in the hypercalcemia and vascular calcification linked to calcium-based agents [3–5]. This

advantage has contributed to the increased use of sevelamer. The most commonly reported adverse effects of sevelamer are gastrointestinal events including abdominal bloating, diarrhea, constipation and intestinal obstruction [6–9]. Though concerns exist that sevelamer may increase the risk of intestinal perforation, there is little written in the literature on this topic. Here we describe a case of sigmoid colon perforation during treatment with sevelamer hydrochloride. Histopathologically, sevelamer crystals were detected at the site of perforated sigmoid colon.

* Corresponding author.

E-mail address: takahisa.1003@gmail.com (T. Yamaguchi).

2. Presentation of case

A 66-year-old man complaining of severe lower abdominal pain was transferred to our hospital in July 2014. His medical history was significant for left renal cancer, which was treated with renal resection. He had been undergoing hemodialysis for chronic renal failure secondary to rapidly progressive glomerulonephritis. Additionally, he had been receiving sevelamer hydrochloride (Renagel[®]) 4.5 g/day for 8 years, to treat hyperphosphatemia, and sodium polystyrene sulfonate (Kayexalate) 10 g/day for 10 years, to treat hyperkalemia. Physical examination on admission revealed a Glasgow coma score of E4 V5 M6, blood pressure of 150/80 mm Hg, pulse of 110 bpm, and temperature of 37.8 °C. Abdominal distension, overall tenderness, and muscular guarding were also noted. Laboratory results showed a significant increase in inflammatory response, with a white blood cell count of 14,400/ μ l and C-reactive protein of 31.2 mg/dl. Blood urea nitrogen was 51.7 mg/dl, and creatinine 11.0 mg/dl. Computed tomography revealed ascites, free air in the abdominal cavity, multiple diverticula of the sigmoid colon, as well as increased fat tissue surrounding the sigmoid colon (Fig. 1). We diagnosed colonic perforation and performed emergency surgery. Surgical findings revealed a 5 × 5 mm perforation in the sigmoid colon surrounded with soft stool (Fig. 2). The sigmoid colon, including the perforation site, was resected, and a colostomy was created in the transverse colon. Diverticula were evident in the resected colon. Histopathologically, the perforated colon revealed sevelamer crystals displayed as broad, curved, and irregularly spaced “fish scales” with a characteristic two-toned color, imparted by bright pink linear accentuations with a rusty yellow background. Violet Kayexalate crystals were seen on hematoxylin and eosin staining (Fig. 3a). On Periodic acid–Schiff staining, sevelamer crystals maintained their internal fish scale appearance with violet color, as opposed to Kayexalate crystals, which were negative (Fig. 3b). The final diagnosis was ruptured diverticulum associated

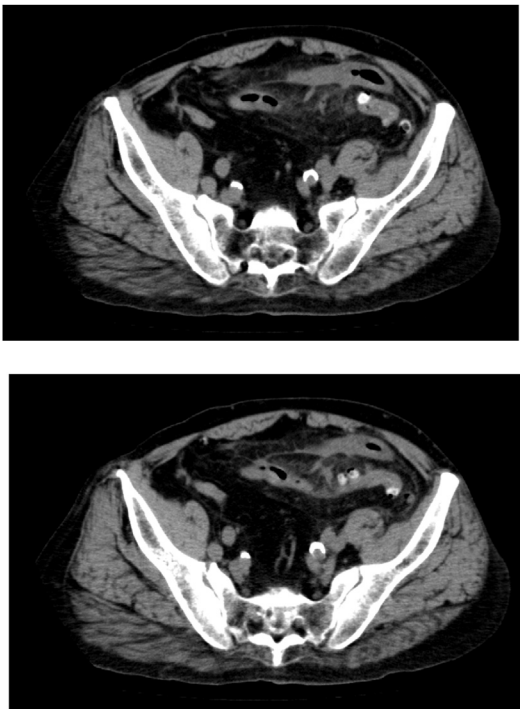


Fig. 1. Computed tomography revealed ascites, free air in the abdominal cavity, multiple diverticula of the sigmoid colon, as well as increased fat tissue surrounding the sigmoid colon.

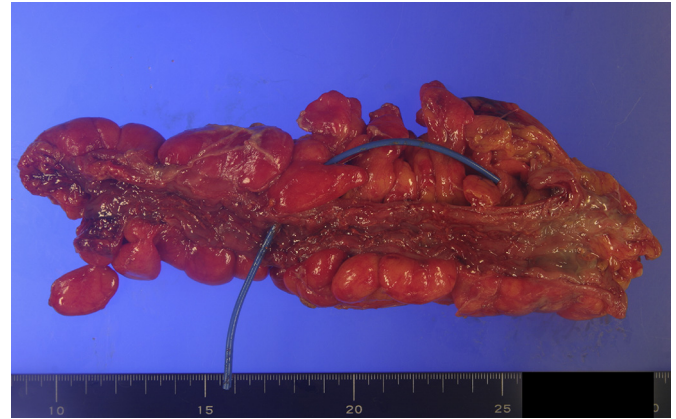


Fig. 2. Resected specimen revealed a 5 × 5 mm perforation in the sigmoid colon.

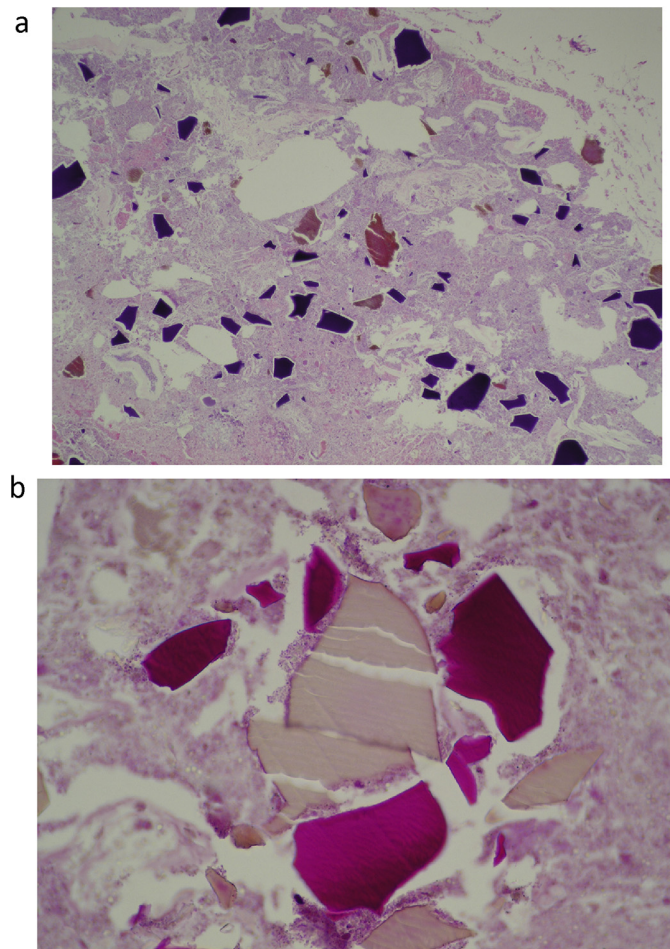


Fig. 3. **3a** Histopathology of the perforated colon revealed sevelamer crystals displayed as broad, curved, and irregularly spaced “fish scales” with a characteristic two-toned color, imparted by bright pink linear accentuations with a rusty yellow background. Violet Kayexalate crystals were seen on hematoxylin and eosin staining. **3b** On Periodic acid–Schiff staining sevelamer crystals maintain their internal “fish scale” appearance with violet color, as opposed to Kayexalate crystals, which were negative. (For interpretation of the references to color in this figure legend, the reader is referred to the web version of this article.)

with sevelamer and Kayexalate crystals. The postoperative course was uneventful, and the patient was discharged from the hospital 1 month after admission.

In preparation of this case report, the CARE criteria were followed as referenced [10].

3. Discussion

Sevelamer is an anion-exchange resin used in the treatment of hyperphosphatemia in patients with chronic renal disease. It was first approved for use in the United States in 1998. It is composed of a non-absorbed hydrogel with ammonia (NH₃) on the hydrochloride or the carbonate. In the acid milieu of the stomach, the polymer dissociates from its anion, is protonated to ammonium (NH₄⁺), and consequently is available to bind phosphate (PO₄³⁻) within the intestine [11]. Because sevelamer is an insoluble polymer, it causes dehydration in the intestinal tract, resulting in the formation of hard stool.

Despite the adverse gastrointestinal effects of sevelamer, reported as bloating, diarrhea, constipation and intestinal obstruction [6–8], there is no direct pathologic evidence on how sevelamer might affect the gastrointestinal tract. Additionally, postmarketing experience has shown rare cases of ileus, intestinal obstruction, and even perforation. The frequency of intestinal tract perforation is unknown, and little is known about the relationship between sevelamer administration and intestinal perforation. The direct mechanical effect of hard stool following sevelamer administration may trigger perforation, but given the lack of investigation into this issue, the potential cause remains unclear.

In patients with chronic renal failure undergoing hemodialysis, hypotension following hemodialysis, uremia, or hypovolemia may cause vasospasm of mesenteric vessels, leading to mesenteric ischemia and intestinal necrosis. Under these conditions, vulnerable intestinal mucosa may be more easily perforated by sevelamer-induced hard stool.

However, Swanson et al. described the histopathology of sevelamer crystals in the gastrointestinal tract, and noted that their presence was associated with mucosal abnormalities including inflammation, ulceration, ischemia, and necrosis [12]. In our case, the resected specimens contained diverticula, with sevelamer crystals evident at the perforation site. In addition, our patient did not report a history of constipation or hard stool. This suggests that it was actually physical stimulation of the vulnerable diverticulum site by sevelamer crystals that produced the perforation.

Kayexalate is an ion-exchange resin used in the treatment of hyperkalemia associated with acute or chronic renal failure. Some authors have reported cases of intestinal necrosis or perforation induced by combined administration of Kayexalate with sorbitol [13–16]. The mechanism of intestinal perforation seen with the administration of Kayexalate is not fully understood, but may be stercoral in nature. There is evidence that Kayexalate crystals directly affect the intestines. In our case, there were many Kayexalate crystals embedded in the perforation site, so it is reasonable to suspect that they contributed to the colonic perforation.

It has been reported that chronic renal failure patients on hemodialysis are at high risk of colonic perforation even without sevelamer administration [17], and it is not known whether the frequency of perforation increases with sevelamer administration. Yang et al. reported that there were no significant changes in the incidence of intestinal perforation before versus after the approval of sevelamer [18]. It might be that sevelamer interacts with other risk factors for intestinal perforation in order to induce gastrointestinal obstruction [12]. There is a need for epidemiologic investigation into this topic. If it is shown that sevelamer administration does increase the risk of intestinal perforation, then alternative methods should be used to control hyperphosphatemia in hemodialysis patients.

4. Conclusion

The case demonstrates the sigmoid colon diverticula perforation associated with sevelamer hydrochloride administration. When sevelamer is administered to hemodialysis patients, the risk of intestinal perforation should be considered.

Ethical approval

This study was conducted upon the submission of its research protocol to the ethics committee of the National Hospital Organization, Kanazawa Medical Center Review Board (study number 127).

Sources of funding

No sources of funding for our research.

Author contribution

Takahisa Yamaguchi conducted the research and finishing manuscript.

Shigekazu Ohyama and Hiroyuki Furukawa assisted during the surgery.

Nariatsu Sato, Ichiro Ohnishi, Atsuhiko Kawashima, and Masato Kayahara designed the study.

Satomi Kasashima wrote draft of manuscript.

Conflicts of interest

none.

Guarantor

None.

References

- [1] J. Delmez, G. Block, J. Robertson, S. Chasan-Taber, A. Blair, M. Dillon, A.J. Bleyer, A randomized, double-blind, crossover design study of sevelamer hydrochloride and sevelamer carbonate in patients on hemodialysis, *Clin. Nephrol.* 68 (6) (2007) 386–391.
- [2] S. Mathew, R.J. Lund, F. Strebeck, K.S. Tustison, T. Geurs, K.A. Hruska, Reversal of the adynamic bone disorder and decreased vascular calcification in chronic kidney disease by sevelamer carbonate therapy, *J. Am. Soc. Nephrol.* 18 (1) (2007) 122–130.
- [3] A.J. Hutchison, Oral phosphate binders, *Kidney Int.* 75 (9) (2009) 906–914.
- [4] C. Wang, X. Liu, Y. Zhou, S. Li, Y. Chen, Y. Wang, et al., New conclusions regarding comparison of sevelamer and calcium-based phosphate binders in coronary-artery calcification for dialysis patients: a meta-analysis of randomized controlled trials, *PLoS One* 10 (7) (2015) e0133938.
- [5] L. Rodriguez-Osorio, D.P. Zambrano, C. Gracia-Iguacel, J. Rojas-Rivera, A. Ortiz, J. Egido, E.G. Parra, Using sevelamer in chronic kidney disease. Beyond phosphorus control, *Nefrol. Publ. Of. la Soc. Espanola Nefrol.* 35 (2) (2014) 207–217.
- [6] P. Evenepoel, R. Selgas, F. Caputo, L. Foggensteiner, J.G. Heaf, A. Ortiz, et al., Efficacy and safety of sevelamer hydrochloride and calcium acetate in patients on peritoneal dialysis, *Nephrol. Dial. Transpl.* 24 (1) (2009) 278–285.
- [7] M. Tonelli, N. Pannu, B. Manns, Oral phosphate binders in patients with kidney failure, *N. Engl. J. Med.* 362 (14) (2010) 1312–1324.
- [8] S.D. Navaneethan, S.C. Palmer, J.C. Craig, G.J. Elder, G.F. Strippoli, Benefits and harms of phosphate binders in CKD: a systematic review of randomized controlled trials, *Am. J. Kidney Dis.* 54 (4) (2009) 619–637.
- [9] P. Madan, S. Bhayana, P. Chandra, J.I. Hughes, Lower gastrointestinal bleeding: association with Sevelamer use, *World J. Gastroenterol.* 14 (16) (2008) 2615–2616.
- [10] J.J. Gagnier, G. Kienle, D.G. Altman, D. Moher, H. Sox, D. Riley, The CARE guidelines: consensus-based clinical case reporting guideline development, *Glob. Adv. Health Med* 2 (5) (2013) 38–43.
- [11] M.M. Barna, T. Kapoian, N.B. O'Mara, Sevelamer carbonate, *Ann. Pharmacother.* 44 (1) (2010) 127–134.
- [12] B.J. Swanson, B.N. Limketkai, T.C. Liu, E. Montgomery, K. Nazari, J.Y. Park, et al., Sevelamer crystals in the gastrointestinal tract (GIT): a new entity associated

- with mucosal injury, *Am. J. Surg. Pathol.* 37 (11) (2013) 1686–1693.
- [13] K.D. Lillemo, J.L. Romolo, S.R. Hamilton, L.R. Pennington, J.F. Burdick, G.M. Williams, Intestinal necrosis due to sodium polystyrene (Kayexalate) in sorbitol enemas: clinical and experimental support for the hypothesis, *Surgery* 101 (3) (1987) 267–272.
- [14] M. Watson, K.C. Abbott, C.M. Yuan, Damned if you do, damned if you don't: potassium binding resins in hyperkalemia, *Clin. J. Am. Soc. Nephrol.* 5 (10) (2010) 1723–1726.
- [15] R.H. Sterns, M. Rojas, P. Bernstein, S. Chennupati, Ion-exchange resins for the treatment of hyperkalemia: are they safe and effective? *J. Am. Soc. Nephrol.* 21 (5) (2010) 733–735.
- [16] N. Takeuchi, Y. Nomura, T. Meda, M. Iida, A. Ohtsuka, K. Naba, Development of colonic perforation during calcium polystyrene sulfonate administration: a case report, *Case Rep. Med.* (2013) 5, 2013 Article ID 102614.
- [17] T. Nozoe, T. Matsumata, K. Sugimachi, Surgical strategy to save patients with colon perforation with chronic renal failure on long-term hemodialysis, *Hepato-gastroenterol* 50 (50) (2002) 385–387.
- [18] J.Y. Yang, T.C. Lee, M.E. Montez-Rath, M. Desai, W.C. Winkelmayr, Trends in the incidence of intestinal perforation in US dialysis patients (1992–2005), *J. Nephrol.* 26 (2) (2013) 281–288.