


CLINICAL ARTICLE

Comparison of Outcomes between Robot-Assisted Minimally Invasive Transforaminal Lumbar Interbody Fusion and Oblique Lumbar Interbody Fusion in Single-Level Lumbar Spondylolisthesis

Xiao-guang Han, MD^{1,2†} , Guo-qing Tang, MD^{3†}, Xiao Han, MD^{1,2}, Yong-gang Xing, MD^{1,2}, Qi Zhang, MD^{1,2}, Da He, MD^{1,2}, Wei Tian, MD, FRCSEd (Ortho)^{1,2}

¹Department of Spine Surgery, Beijing Jishuitan Hospital and ²Beijing Key Laboratory of Robotic Orthopaedics, Beijing and ³Kunshan Hospital of Traditional Chinese Medicine, Kunshan, China

Objective: To compare the safety and effectiveness of robot-assisted minimally invasive transforaminal lumbar interbody fusion (Mis-TLIF) and oblique lumbar interbody fusion (OLIF) for the treatment of single-level lumbar degenerative spondylolisthesis (LDS).

Methods: This is a retrospective study. Between April 2018 and April 2020, a total of 61 patients with single-level lumbar degenerative spondylolisthesis and treated with robot-assisted OLIF (28 cases, 16 females, 12 males, mean age 50.4 years) or robot-assisted Mis-TLIF (33 cases, 18 females, 15 males, mean age 53.6 years) were enrolled and evaluated. All the pedicle screws were implanted percutaneously assisted by the TiRobot system. Surgical data included the operation time, blood loss, and length of postoperative hospital stay. The clinical and functional outcomes included Oswestry Disability Index (ODI), Visual Analog scores (VAS) for back and leg pain, complication, and patient's satisfaction. Radiographic outcomes include pedicle screw accuracy, fusion status, and disc height. These data were collected before surgery, at 1 week, 3 months, 6 months, and 12 months postoperatively.

Results: There were no significantly different results in preoperative measurement between the two groups. There was significantly less blood loss (142.4 ± 89.4 vs 291.5 ± 72.3 mL, $P < 0.01$), shorter hospital stays (3.2 ± 1.8 vs 4.2 ± 2.5 days, $P < 0.01$), and longer operative time (164.9 ± 56.0 vs 121.5 ± 48.2 min, $P < 0.01$) in OLIF group compared with Mis-TLIF group. The postoperative VAS scores and ODI scores in both groups were significantly improved compared with preoperative data ($P < 0.05$). VAS scores for back pain were significantly lower in OLIF group than Mis-TLIF group at 1 week (2.8 ± 1.2 vs 3.5 ± 1.6 , $P < 0.05$) and 3 months postoperatively (1.6 ± 1.0 vs 2.1 ± 1.1 , $P < 0.05$), but there was no significant difference at further follow-ups. ODI score was also significantly lower in OLIF group than Mis-TLIF group at 3 months postoperatively (22.3 ± 10.0 vs 26.1 ± 12.8 , $P < 0.05$). There was no significant difference in the proportion of clinically acceptable screws between the two groups (97.3% vs 96.2%, $P = 0.90$). At 1 year, the OLIF group had a higher interbody fusion rate compared with Mis-TLIF group (96.0% vs 87%, $P < 0.01$). Disc height was significantly higher in the OLIF group than Mis-TLIF group (12.4 ± 3.2 vs 11.2 ± 1.3 mm, $P < 0.01$). Satisfaction rates at 1 year exceeded 90% in both groups and there was no significant difference (92.6% for OLIF vs 91.2% for Mis-TLIF, $P = 0.263$).

Address for correspondence Da He, MD, Department of Spine Surgery, Beijing Jishuitan Hospital, No. 31, Xijiekou East Street, Xicheng District, Beijing, China 100035 Tel: 0086-10-58516959; Fax: 0086-10-58516934; Email: hedamd@vip.163.com

[†]These two authors contributed equally to this work.

Grant Sources: This research was funded by the National Natural Science Foundation of China (NSFC No. U1713221), Beijing Health Technologies Promotion Program (BHTPP202001), Beijing Municipal Science and Technology Project (Z211100003521005), Capital's Funds for Health Improvement and Research (2020-2-2072) and the Natural Science Foundation of Jiangsu Province (No. BK20161274), China.

Disclosure: The authors declare that they have no competing interests.

Received 30 May 2021; accepted 26 August 2021

Conclusion: Robot-assisted OLIF and Mis-TLIF both have similar good clinical outcomes, but OLIF has the additional benefits of less blood loss, less postoperative hospital stays, higher disc height, and higher fusion rates. Robots are an effective tool for minimally invasive spine surgery.

Key words: Minimally invasive; Mis-TLIF; OLIF; Robot; Spondylolisthesis

Introduction

Degenerative lumbar spondylolisthesis (DLS) is a common spinal disease owing to the abnormal vertebral slippage and compression of the neural structures. Symptoms may include intermittent neurogenic claudication, lumbar radiculopathy, and low back pain. The primary treatment for lumbar spondylolisthesis is conservative. When unsuccessful, surgery can be considered to decompress neural structures and stabilize the spine. Transforaminal lumbar interbody fusion (TLIF) is one of the most common and effective treatments which achieve the insertion of an interbody cage packed with bone graft *via* the transforaminal approach. Although the method can obtain satisfactory outcomes, iatrogenic complication, such as nerve injury and stripping of paravertebral muscles that result in long-lasting sequela, cannot be avoided¹. The advent of minimally invasive techniques provides an additional option to address morbidities associated with open spinal surgery approaches^{2,3}. Therefore, minimally invasive techniques such as minimally invasive transforaminal lumbar interbody fusion (Mis-TLIF) and oblique lumbar interbody fusion (OLIF) have been increasingly used^{4,5}.

Mis-TLIF, first introduced in 2003, is a muscle-sparing surgical approach for direct decompression of the neurologic structure. It minimizes soft tissue disruption and spinal segment destabilization, thus leaving the smallest operative footprint while achieving the operative goal. The advantages are lesser paraspinal muscle trauma, lesser perioperative blood loss and pain, shorter hospitalization, and quicker postoperative recovery, while demonstrating similar clinical results as open TLIF⁶⁻⁹. Peng *et al.*¹⁰ demonstrated that although Mis-TLIF is a more technically challenging technique compared to open TLIF, it has similar good long-term clinical outcomes and high fusion rates, with the additional benefits of less initial postoperative pain, early rehabilitation, shorter hospitalization, and fewer complications. OLIF, introduced in 2012, is a retroperitoneal approach between psoas muscle and large abdominal vessels that allows direct access to the disc space, comprehensive disc clearance, and insertion of large interbody cage. The advantages are that it can achieve decompression indirectly, correct the coronal and sagittal imbalance, reduce paraspinal muscle trauma, minimize blood loss, and result in faster patient recovery with fewer complications¹¹⁻¹⁴. Du *et al.*¹⁵ have performed a retrospective comparative study, and demonstrated that, compared with TLIF, OLIF shows the advantages of less surgical invasion, better decompression effect, and faster postoperative recovery in single-level DLS surgery. Many comparative studies have

focused on the comparison of minimally invasive lumbar interbody fusion with conventional open surgery and confirmed the superiority of minimally invasive surgery^{10,15,16}. However, few studies have compared the results of OLIF and Mis-TLIF, and it is still controversial which type of minimally invasive surgery is better for the treatment of lumbar spondylolisthesis.

Further, one of the biggest obstacles of minimally invasive spinal surgery is how to ensure the safety and accuracy of the operation, especially the pedicle screw accuracy. The severe misplacement rate of minimally invasive pedicle screw studied by Schwender is up to 4.1%¹⁷. Screw misplacement might lead not only to a decreased stability but also to neurological, vascular, and visceral injuries. In addition, as anatomic landmarks for placing pedicle screws and intervertebral grafts are lacking, the minimally invasive technique necessitates an obviously increased radiation exposure *via* fluoroscopy for the patient, the surgeon, and entire staff in the operating room. Robots may be ideal surgical assistants in spinal surgery, as they can achieve superior levels of precision^{18, 19}. In a meta-analysis focusing on the comparison of the accuracies of robot-assisted and free-hand pedicle screw insertion, 10 studies were included and analyzed. The study showed that the robot-assisted technique is more accurate than the conventional method²⁰.

Theoretically, the combination of robot with OLIF and Mis-TLIF could be safely and accurately performed as a minimally invasive procedure. To our knowledge, there has been no previous study comparing the safety and effectiveness of robot-assisted OLIF and Mis-TLIF technique. So, the main purposes of this study include: (i) to observe the safety of robot-assisted Mis-TLIF and robot-assisted OLIF (e.g. whether it will be accompanied by obvious complications); (ii) to determine its short-term clinical effects, including postoperative low back pain, leg pain, duration of postoperative hospital stay, and other aspects of the intervention effect; and (iii) to identify its long-term effects based on postoperative functional recovery and the satisfaction of patients as measured during follow-up.

Materials and Methods

Inclusion and Exclusion Criteria

The inclusion criteria were: (i) single-level grade 1 or 2 degenerative spondylolisthesis; (ii) presentation with mechanical low back pain and radicular leg pain with more than 6 months of conservative treatment; (iii) 12 months follow-up.

The exclusion criteria were: (i) cauda equina syndrome; (ii) spinal tumor, infection, fracture, or previous surgery.

Patient Information

A total of 61 patients with single-level degenerative spondylolisthesis and treated between April 2018 to April 2020 were enrolled and evaluated retrospectively. Twenty-eight patients were treated with OLIF (OLIF with robot-assisted posterior percutaneous pedicle screws) and 33 were treated with robot-assisted Mis-TLIF. The characteristics of patients and individual data, including age, gender, surgical segments, are shown in Table 1. Three senior chief physicians performed the surgical treatment. The study was retrospective and ethics committee approval was obtained from the ethic committee at our hospital (Beijing Jishuitan Hospital).

Component of TiRobot System

As described in previous studies¹⁸, the TiRobot (Beijing Tinavi Medical Technology) consists of an optical tracking device, a surgical planning and controlling workstation, and a surgical robotic arm. During operation, images obtained by C-arm are transferred into the robotic workstation and 3-D images are created. Then, surgeons design the screw trajectories on the robotic workstation. Afterwards, the robotic arm with a guidance cannula on its end automatically moves to the surgical field and guides the pin insertion. A fluoroscopic scan is performed and followed by cannulated or conventional screw placements if the optimal pin trajectories are confirmed (Fig. 1).



Fig. 1 The TiRobot system. This system consists of an optical tracking device, a surgical planning and controlling workstation, and a surgical robotic arm.

TABLE 1 Perioperative comparison between OLIF and Mis-TLIF

Characteristics	OLIF	MIS-TLIF	P
Number of patients	28	33	
Age (Mean \pm SD, years)	50.4 \pm 16.0	53.6 \pm 13.5	0.399
Male	12	15	0.839
Female	16	18	
IBM (Mean \pm SD, kg/m ²)	24.9 \pm 3.9	24.1 \pm 3.0	0.350
Diabetes	5	9	0.384
Smoker	11	18	0.234
VAS for back	5.3 \pm 2.0	5.0 \pm 2.2	0.557
VAS for leg	4.9 \pm 1.6	4.6 \pm 1.8	0.562
ODI (%)	46.3 \pm 14.6	46.4 \pm 16.1	0.965
Level of fusion			
L _{3/4}	8	11	0.654
L _{4/5}	19	19	
L ₅ /S ₁	1	3	
Operation time (mins)	164.9 \pm 56.0	121.5 \pm 48.2	0.002*
Blood loss (mL)	142.4 \pm 89.4	291.5 \pm 72.3	0.000*
Day of hospital (d)	3.2 \pm 1.8	4.2 \pm 2.5	0.006*
Complication (n)	8	5	
Satisfaction (%)	92.6	91.2	0.263
Fusion rate (%)	96.0	87	0.006*
Disc height (mm)	12.4 \pm 3.2	11.2 \pm 1.3	0.000*

Values are mean \pm SD. OLIF, oblique lateral lumbar interbody fusion; Mis-TLIF, minimally invasive transforaminal lumbar interbody fusion; BMI, body mass index; Oswestry Disability Index; VAS, visual analog scale; SD, standard deviation; * $P < 0.05$, statistical significance.

Surgical Techniques

Robot-Assisted Mis-TLIF

Step 1: After induction of general anesthesia, the patient was placed in a prone position on a carbon table.

Step 2: A percutaneous reference tracker was placed in the spinal process. After scanning with C-arm, registration was performed automatically, and the surgeons planned the screw trajectories. The robot then steered toward the chosen trajectory and indicated the entry point and direction. The guiding cannula was placed onto the robotic arm and approached the skin closely. Surgeons drilled the guidewires through the guiding tube into the pedicle. A fluoroscopic scan is performed to confirm the position of guidewires.

Step 3: Paramedian incisions 4–5 cm long were made on the symptomatic side between the two guidewires. Sequential soft tissue dilators were then inserted through the incision down to the facet complex.

Step 4: Facetectomy, discectomy, bone grafting, and interbody cage placement were performed *via* tubular retractor.

Step 5: The pedicle screws were inserted percutaneously along the guidewires and fixation.

Robot-Assisted OLIF

Step 1: After induction of general anesthesia, the patient was placed in lateral decubitus position on the right side. The operating segment was marked on the skin *via* a C-arm machine.

Step 2: A 5-cm skin incision was made 6–10 cm anterior to the mid-portion of the marked disc. The intervertebral disc was exposed through an open corridor between the psoas muscle and aorta.

Step 3: After discectomy, an appropriate-sized cage filled with demineralized bone matrix (DBM) was inserted^{11–14}.

Step 4: Subsequently, the patient was placed in the prone position, and percutaneous pedicle screw guidewires were placed assisted by the robot with protocol identically to step 2 of Mis-TLIF group.

Step 5: The pedicle screws were inserted percutaneously along the guidewires and fixation.

Clinical Outcomes

Clinical outcomes were assessed by an experienced clinical research coordinator. Surgical data included the operation time, blood loss, and length of postoperative hospital stay. Functional data include visual analog scale (VAS) for back pain and leg pain and Oswestry Disability Index (ODI). These data were collected before surgery, at 1 weeks, 3 months, 6 months, and 12 months postoperatively.

Oswestry Disability Index (ODI)

Oswestry Disability Index (ODI) is a principal condition-specific outcome measure used in the management of spinal disorders, and to assess patient progress in routine clinical practice²¹. It includes 10 sections: pain intensity, personal care, lifting, walking, sitting, standing, sleeping, sex life, social life, and traveling. For each section of six statements the total score is 5. Intervening statements are scored according to rank. If more than one box is marked in each section, take the highest score. If all 10 sections are completed, the score is calculated as follows: total score out of total possible score \times 100. If one section is missed (or not applicable) the score is calculated: (total score/(5 \times number of questions answered)) \times 100%. A total of 0%–20% is considered mild dysfunction, 21%–40% is moderate dysfunction, 41%–60% is severe dysfunction, and 61%–80% is considered as disability. A score of 81%–100% is either long-term bedridden or exaggerating the impact of pain on their life.

Visual Analog Scale

The Visual Analog Scale (VAS) scoring system was used to evaluate the pain level of patients. The VAS scoring system is self-completed by the patient. Patients mark the location on the 10-cm line corresponding to the amount of pain they experienced. Zero is no pain and 10 is severest pain.

Radiographic Evaluation

Radiographs were taken preoperatively, at 1 week, 3 months, and 12 months postoperatively. Assessment was done for pedicle screw accuracy, disc height, and interbody fusion.

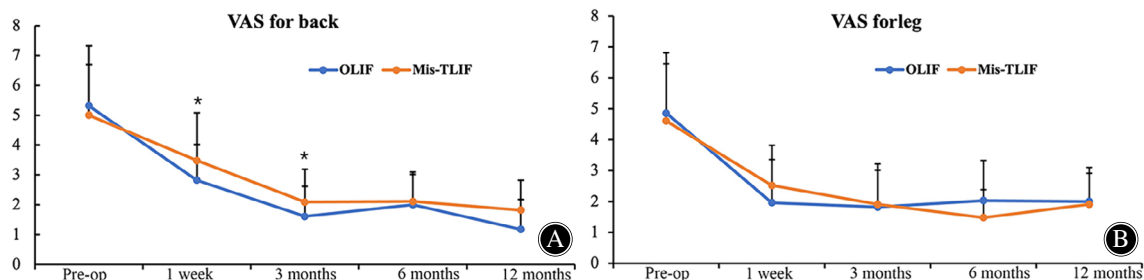


Fig. 2 Average VAS scores for back and leg at baseline and four follow-ups in the OLIF group and Mis-TLIF group. (A) VAS score for back. There was a significant difference between two groups at 1 week and 3 months post-operation ($P < 0.05$). (B) VAS score for leg. There was no significant difference between the two groups.

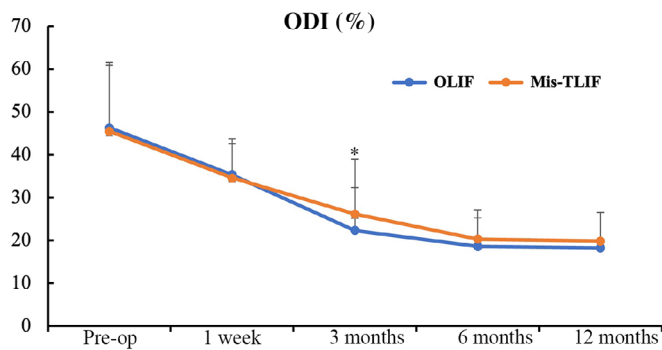


Fig. 3 Average ODI scores at baseline and four follow-ups in the OLIF group and MIS-TLIF group. There was a significant difference between the two groups at 3 months post-operation ($P < 0.05$). There was no significant difference at other follow-ups.

TABLE 2 Pedicle screw accuracy according to the Gertzbein and Robbins classification

Classification	OLIF	Mis-TLIF	P
A	104 (92.9%)	120 (90.9%)	0.58
B	5 (4.7%)	7 (5.3%)	0.76
A + B	109 (97.3%)	127 (96.2%)	0.90
C	4 (3.6%)	3 (2.3%)	1.00
D	0 (0)	2 (1.5%)	–
E	0 (0)	0 (0)	–

Accuracy of Pedicle Screw Placement

Pedicle screw accuracy was assessed on postoperative CT by a radiologist according to the Gertzbein and Robbins scale²². It is classified as grade A (screw completely within the pedicle), grade B (pedicle cortical breach < 2 mm), grade C (pedicle cortical breach ≥ 2 to < 4 mm), grade D (pedicle cortical breach ≥ 4 to < 6 mm), or grade E (pedicle cortical breach ≥ 6 mm). Grades A and B screw positions were considered clinically acceptable.

Disc Height and Fusion Status

Disc height was defined as the distance at mid-position from upper to lower endplate. Fusion status was defined as continuous trabeculae bridging bone formation and no gap between the vertebral endplate and the cage in the coronal or sagittal planes, according to the Bridwell interbody fusion grading system²³.

Patient Satisfaction

Patient satisfaction evaluation was related to patient assessment of the treatment effects of the surgery (focus on the symptoms in the back and lower limbs). Patient satisfaction included four grades: very satisfied, satisfied, neutral (fairly satisfied), and dissatisfied. The questions were measured on a four-point scale from “very satisfied” to “dissatisfied.”

Complications

Postoperative complications, including subsidence, vascular injury, nerve injury, ureteral injury, incision-related complication, and fusion-related complication were recorded and analyzed.

Statistical Analysis

Quantitative variables were expressed as mean standard \pm deviation and qualitative variables were expressed in terms of number and ratio. Continuous variables were evaluated by pooled t-test. The categorical variables were performed by Fisher exact test and Mann–Whitney test. SPSS 23.0 software (IBM Corp., Armonk, New York, USA) was used for statistical analysis of data. $P < 0.05$ difference was statistically significant.

Results

General Results

There were 28 OLIF patients and 33 Mis-TLIF patients enrolled in this study. The perioperative comparison between the two groups is shown in Table 1. The demographics for OLIF and Mis-TLIF groups were comparably matched. The mean age of patients in OLIF group and Mis-TLIF group were 50.4 ± 16.0 and 53.6 ± 13.5 , respectively ($P = 0.399$). The mean BMI for OLIF and Mis-TLIF were 24.9 ± 3.9 and 24.1 ± 3.0 , respectively ($P = 0.350$). Among the 28 OLIF patients, 11 of them had smoking history compared to 18 from the Mis-TLIF group ($P = 0.234$). Five patients from the OLIF group had history of diabetic mellitus while the Mis-TLIF group had nine patients ($P = 0.384$).

Surgical Data

The average operative time for Mis-TLIF group was significantly shorter than OLIF group (121.5 ± 48.2 vs 164.9 ± 56.0 min, $P < 0.01$). There was significantly less blood loss (142.4 ± 89.4 vs 291.5 ± 72.3 mL, $P < 0.01$) and shorter hospital stay (3.2 ± 1.8 vs 4.2 ± 2.5 days, $P < 0.01$) in OLIF group compared with Mis-TLIF group (Table 1).

Visual Analog Scale

Preoperatively, there was no significant difference between the OLIF and Mis-TLIF groups in back and leg pain VAS scores. After surgery, both groups showed significant improvement in clinical outcome scores during follow-up, as compared with the preoperative values (Fig. 2). Back pain VAS scores were significantly lower in the OLIF group than that in the Mis-TLIF group at 1 week (2.8 ± 1.2 vs 3.5 ± 1.6 , $P < 0.005$) and 3 months postoperatively (1.6 ± 1.0 vs 2.1 ± 1.1 , $P < 0.005$). But there was no significant difference between the two group at further follow-ups. There was no significant difference in the leg pain VAS scores in follow-ups between the two groups (Fig. 2).

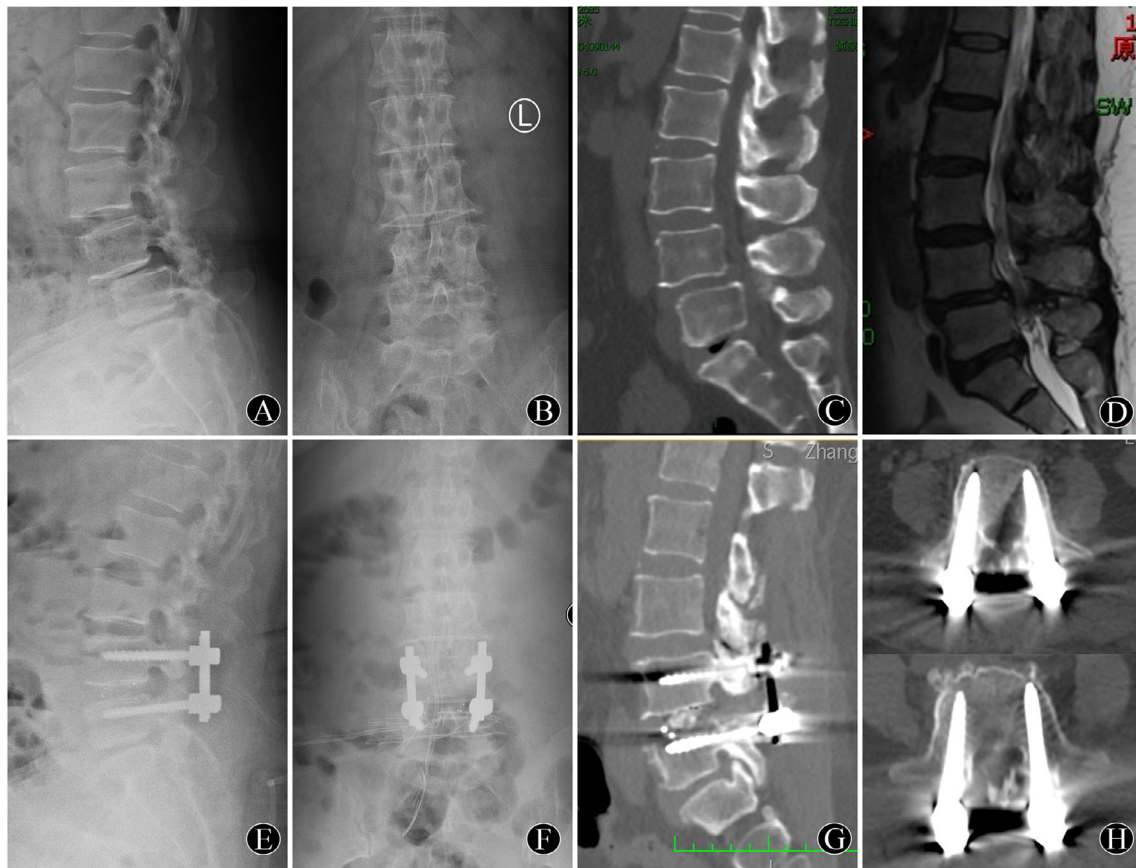


Fig. 4 A 53-year-old woman with lumbar degenerative spondylolisthesis ($L_{4/5}$) underwent robot-assisted Mis-TLIF surgery. (A, B) Preoperative X-ray films showing lumbar degenerative spondylolisthesis ($L_{4/5}$). (C) Preoperative CT image showing lumbar degenerative spondylolisthesis. (D) Preoperative T2WI sagittal MR image showing spondylolisthesis and spinal canal stenosis. (E, F) One-week postoperative X-ray films showing excellent vertebral reduction and pedicle screw position. (G) One-year postoperative CT image showing interbody fusion has been achieved. (H) One-year postoperative CT transverse images showing the precise position of the pedicle screws.

Oswestry Disability Index

Preoperatively, there was no significant difference between the OLIF and Mis-TLIF groups in ODI score. After surgery, both groups showed significant improvement in ODI scores during follow-up, as compared with the preoperative values. ODI score was also significantly lower in the OLIF group than that in the Mis-TLIF group at 3 months (22.3 ± 10.0 vs 26.1 ± 12.8 , $P < 0.005$), but there was no significant difference at other follow-ups (Fig. 3).

Accuracy of Pedicle Screw Placement

In the OLIF group, 92.9% of the screws were perfectly placed (grade A); the remaining screws were graded B (4.7%) and C (3.6%). In the Mis-TLIF group, 90.9% of the screws were graded A; the remaining screws were graded B (5.3%), C (2.3%), and D (1.5%). There was no significant difference in the proportion of clinically acceptable screws (grades A and B) between these two groups (97.3% vs 96.2% , $P = 0.90$) (Table 2).

Disc Height and Fusion Rate

At the 1-year follow-up, the disc heights showed improvements after surgery in both groups. And disc height was significantly higher in the OLIF group than that in the Mis-TLIF group (12.4 ± 3.2 vs 11.2 ± 1.3 mm, $P < 0.01$). Intervertebral fusion was assessed according to the Bridwell grading system²³. The rate of complete fusion was significantly higher in the OLIF group than that in the Mis-TLIF group at 1-year follow-up (96.0% vs 87% , $P < 0.01$).

Patient Satisfaction

Patient satisfaction rate 1 year after surgery was more than 90% in both groups, and there was not significant difference between the OLIF group (92.6%) and Mis-TLIF group (91.2%) ($P = 0.234$).

Complications

In Mis-TLIF group, there were two surgical site infections which were treated with wound debridement and antibiotics.

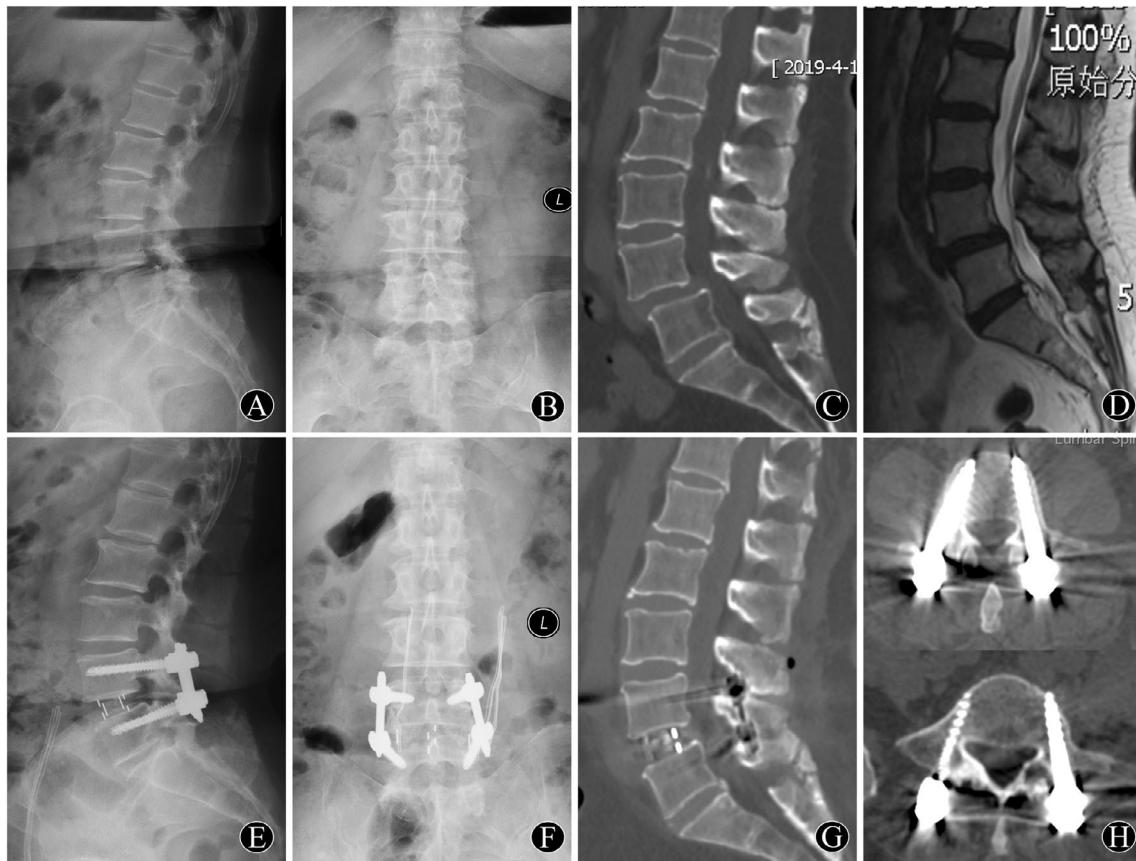


Fig. 5 A 66-year-old woman with lumbar degenerative spondylolisthesis ($L_{4/5}$) underwent robot-assisted OLIF surgery. (A, B) Preoperative X-ray films showing lumbar degenerative spondylolisthesis ($L_{4/5}$). (C) Preoperative CT image showing lumbar degenerative spondylolisthesis. (D) Preoperative T2WI sagittal MR image showing spondylolisthesis and spinal canal stenosis. (E, F) One-week postoperative X-ray films showing excellent vertebral reduction and pedicle screw position. (G) One-year postoperative CT image showing interbody fusion has been achieved. (H) One-year postoperative CT transverse images showing the precise position of the pedicle screws.

Two patients had CSF leaks that were treated conservatively and recovered in 2 weeks. Three patients complained of leg pain/numbness, treated with neurotrophic drugs and non-steroidal anti-inflammatory drugs (NSAIDs), and the symptoms resolved within the first 3 months (Fig. 4). In the OLIF group, there were no abdominal, urologic or intraoperative vascular injuries (Fig. 5). Four patients had sympathetic injury and three patients had transient thigh flexion weakness/numbness, which were transient in nature and improved with observation at the 3-month follow-up.

Discussion

The advent of minimally invasive techniques such as OLIF and Mis-TLIF provides an additional option that seeks to minimize surgical trauma²⁴. But many previous comparative studies have focused on the comparison of minimally invasive lumbar interbody fusion with conventional open approaches. However, few studies have compared the results of OLIF and Mis-TLIF. Lin *et al.* performed a retrospective comparison study and demonstrated that OLIF achieved

equivalent clinical and radiologic outcomes, with less blood loss, shorter operative time, better restoration of disc height, and earlier time to fusion compared with Mis-TLIF²⁵. But a meta-analysis conducted by Li found that the OLIF group showed advantages in operative blood loss and operative time; however, the incidence of complications was greater than that in the Mis-TLIF group²⁶. So, it is still controversial which type of minimally invasive surgery is better for the treatment of lumbar spondylolisthesis. Further, robots may be ideal surgical assistants in orthopaedic surgery, as they can achieve superior levels of precision. To our knowledge, there has been no previous study comparing the safety and effectiveness of robot-assisted OLIF and Mis-TLIF technique. So, the aim of the present study was to compare the safety and effectiveness of robot-assisted Mis-TLIF and OLIF for the treatment of single-level LDS.

Better Early Lumbar Function in OLIF Group

Postoperative pain relief and lumbar function recovery were the main focus of both the surgeons and patients. In this

study, patients in both groups experienced high mean improvements from their preoperative ODI and VAS scores at each time point postoperatively, confirming that both treatment options are efficacious in treatment for degenerated lumbar spondylolisthesis. We found that back pain VAS scores were significantly lower in the OLIF group than that in the Mis-TLIF group at 1 week and 3 months postoperatively. ODI score was also significantly lower in the OLIF group than that in the Mis-TLIF group at 3 months. Further, the patients who underwent OLIF had less intraoperative blood loss, shorter hospital stay than patients who received Mis-TLIF. This means that the short-term (3 months) postoperative pain and lumbar function in the OLIF group were superior to the Mis-TLIF group, although there were no significant differences in long-term follow-up. The reasons may be as follows: (i) less damage to paraspinal muscles and facet joints was found in the OLIF group, so low back pain and lumbar function were better than the Mis-TLIF group at the short-term follow-up; (ii) OLIF surgery did not open the spinal canal and had little stimulation to spinal nerve roots. In this study, the operation time in the OLIF group was longer than that in the MIS-TLIF group. That may be because OLIF requires the position change for posterior screwing.

Higher Disc Height by OLIF

At 1 year, the OLIF group had a higher disc height than the Mis-TLIF group (12.4 ± 3.2 vs 11.2 ± 1.3 mm, $P < 0.001$). The reasons may be as follows: (i) in OLIF group, a large cage with a degree of inclination angle was implanted into the intervertebral space, while in Mis-TLIF group, only a small cage could be implanted through the narrow operating space; (ii) the wide cage in OLIF group allows it to rest on the hard epiphyseal ring around the vertebral body, rather than on the relatively weak area of the cortical bone in the central depression of the endplate; (iii) in this study, most of Mistily surgery, mainly one side of the paravertebral muscle, lamina, and the facet joints were removed while the contralateral side was partially preserved, so the intervertebral space may not be effectively extended, especially for patients with severe facet joint degeneration or even facet joint fusion.

Higher Fusion Rate by OLIF

In this study, the rate of complete fusion was significantly higher in the OLIF group than that in the Mis-TLIF group at 1-year follow-up. We thought the reasons may be as follows: (i) in OLIF group, the intervertebral discs were more completely removed, and the cartilage endplate was more completely scraped. This would create a better graft bed for fusion than the Mis-TLIF group; (ii) in the OLIF group, the cage was bigger, which means that the bed for bone graft was bigger; (iii) in the OLIF group, the structure of the spine segment was less damaged, so it was relatively more stable.

Pedicle Screw Accuracy and Role of Robot

The placement of appropriate instrumentation to supplement bony fusion is critically important in spinal surgery. Robotic assistance theoretically increases accuracy in spinal surgery by ensuring that the placements follow the planned trajectories. Hence, we present the TiRobot system, which is a multi-indication orthopaedic surgical robot that can be used for all levels of spinal instrumentation and pelvic, acetabular, and limb fracture surgeries^{27, 28}. The robot allows clear visualization of the three-dimensional spinal anatomy, which enables the surgeon to choose the optimal entry point and trajectory for pedicle screw placement. Moreover, the surgeons can use the navigation software to choose the optimal diameter and length of the pedicle screws, thereby reducing the rate of screw-related complications. In this study, we found that the accuracy of robot-assisted pedicle screw was very high in both groups (OLIF, 97.3% vs Mis-TLIF, 96.2%, $P = 0.90$), and there was no screw misplacement-associated complications.

Complications

Segmental artery injury and transient thigh numbness were common complications in the OLIF group, because the lumbar plexus, lumbar sympathetic trunk, and segmental artery are all located laterally in front of the lumbar vertebrae and susceptible to being irritated or injured^{13, 14}. In this study, four patients had sympathetic injury and three patients had transient thigh flexion weakness/numbness, and all recovered within the first 3 months. The main complications of TLIF were nerve root stimulation or injury and dural tear⁷⁻⁹. In this study, there were two surgical site infections, two patients had small CSF leaks, and three patients complained of leg pain/numbness. All these patients were treated conservatively and recovered within the first 3 months. Differently from previous study²⁵, we found no significant difference in complication rate between the two groups. It may be because these complications are very related with surgical experience. In this study all the surgeons are experienced with relatively few complications. This result also indicated the safety of the two surgical methods for degenerative spondylolisthesis.

Limitations

Some limitations should be considered when interpreting our data. First, the retrospective design might lead to selection bias and the small sample size might reduce the stringency of our result. Second, this was a single-center study with small sample size. Third, the follow-up time was limited to 1 year, which may be not long enough. Further prospective, long-term studies involving a large sample size are required to confirm our findings.

Conclusion

In conclusion, this study showed that robot-assisted OLIF and Mis-TLIF both have similar good clinical outcomes, but OLIF has the additional benefits of less blood loss, less hospital stays, higher disc height, and higher fusion rates. Both

groups have a higher pedicle screw accuracy. Robots are an effective tool for minimally invasive spine surgery.

Acknowledgments

Thanks to Tengfei Ma and Yumei Wang for their assistance in the experiment.

Authorship Declaration

All the authors listed meet the authorship criteria according to the latest guidelines of the International Committee of Medical Journal Editors, and all authors are in agreement with the manuscript.

References

- Xu DS, Walker CT, Godzik J, Turner JD, Smith W, Uribe JS. Minimally invasive anterior, lateral, and oblique lumbar interbody fusion: a literature review. *Ann Transl Med*, 2018, 6: 104.
- Smith JS, Shaffrey CI, Bess S, et al. Recent and emerging advances in spinal deformity. *Neurosurgery*, 2017, 80: S70–S85.
- Smith ZA, Fessler RG. Paradigm changes in spine surgery: evolution of minimally invasive techniques. *Nat Rev Neurol*, 2012, 8: 443–450.
- Li R, Li X, Zhou H, Jiang W. Development and application of oblique lumbar interbody fusion. *Orthop Surg*, 2020, 12: 355–365.
- Choi WS, Kim JS, Hur JW, Seong JH. Minimally invasive transforaminal lumbar interbody fusion using banana-shaped and straight cages: radiological and clinical results from a prospective randomized clinical trial. *Neurosurgery*, 2018, 82: 289–298.
- Lu Y, Chen J, Chen J, et al. Three-year postoperative outcomes between MIS and conventional TLIF in 1-segment lumbar disc herniation. *Minim Invasive Ther Allied Technol*, 2017, 26: 168–176.
- Khan NR, Clark AJ, Lee SL, Venable GT, Rossi NB, Foley KT. Surgical outcomes for minimally invasive vs open transforaminal lumbar interbody fusion: an updated systematic review and meta-analysis. *Neurosurgery*, 2015, 77: 847–874; discussion 874.
- Kim CH, Easley K, Lee JS, et al. Comparison of minimally invasive versus open transforaminal interbody lumbar fusion. *Global Spine J*, 2020, 10: 143S–150S.
- Zhang H, Chen ZX, Sun ZM, et al. Comparison of the total and hidden blood loss in patients undergoing open and minimally invasive transforaminal lumbar interbody fusion. *World Neurosurg*, 2017, 107: 739–743.
- Peng CW, Yue WM, Poh SY, Yeo W, Tan SB. Clinical and radiological outcomes of minimally invasive versus open transforaminal lumbar interbody fusion. *Spine (Phila Pa 1976)*, 2009, 34: 1385–1389.
- Li JX, Phan K, Mobbs R. Oblique lumbar interbody fusion: technical aspects, operative outcomes, and complications. *World Neurosurg*, 2017, 98: 113–123.
- Abe K, Orita S, Mannoji C, et al. Perioperative complications in 155 patients who underwent oblique lateral interbody fusion surgery: perspectives and indications from a retrospective, multicenter survey. *Spine (Phila Pa 1976)*, 2017, 42: 55–62.
- Mehren C, Korge A. Minimally invasive anterior oblique lumbar interbody fusion (OLIF). *Eur Spine J*, 2016, 25: 471–472.
- Hah R, Kang HP. Lateral and oblique lumbar interbody fusion-current concepts and a review of recent literature. *Curr Rev Musculoskelet Med*, 2019, 12: 305–310.
- Du X, She Y, Ou Y, Zhu Y, Luo W, Jiang D. Oblique lateral interbody fusion versus transforaminal lumbar interbody fusion in degenerative lumbar spondylolisthesis: a single-center retrospective comparative study. *Biomed Res Int*, 2021, 2021: 6693446.
- Jain D, Ray WZ, Vaccaro AR. Advances in techniques and technology in minimally invasive lumbar interbody spinal fusion. *JBSJ Rev*, 2020, 8: e0171.
- Schwender JD, Holly LT, Rouben DP, Foley KT. Minimally invasive transforaminal lumbar interbody fusion (TLIF): technical feasibility and initial results. *J Spinal Disord Tech*, 2005, 18: S1–S6.
- Han X, Tian W, Liu Y, et al. Safety and accuracy of robot-assisted versus fluoroscopy-assisted pedicle screw insertion in thoracolumbar spinal surgery: a prospective randomized controlled trial. *J Neurosurg Spine*, 2019: 1–8. <https://doi.org/10.3171/2018.10.SPINE18487>
- Staub BN, Sadrameli SS. The use of robotics in minimally invasive spine surgery. *J Spine Surg*, 2019, 5: S31–S34.
- Zhang Q, Han XG, Xu YF, et al. Robotic navigation during spine surgery. *Expert Rev Med Devices*, 2020, 17: 27–32.
- Fairbank JC, Pynsent PB. The Oswestry disability index. *Spine (Phila Pa 1976)*, 2000, 25: 2940–2952; discussion 2952.
- Gertzbein SD, Robbins SE. Accuracy of pedicular screw placement in vivo. *Spine (Phila Pa 1976)*, 1990, 15: 11–14.
- Bridwell KH, Lenke LG, McEnery KW, Baldus C, Blanke K. Anterior fresh frozen structural allografts in the thoracic and lumbar spine. Do they work if combined with posterior fusion and instrumentation in adult patients with kyphosis or anterior column defects. *Spine (Phila Pa 1976)*, 1995, 20: 1410–1418.
- Momin AA, Steinmetz MP. Evolution of minimally invasive lumbar spine surgery. *World Neurosurg*, 2020, 140: 622–626.
- Lin GX, Akbary K, Kotheeranurak V, et al. Clinical and radiologic outcomes of direct versus indirect decompression with lumbar interbody fusion: a matched-pair comparison analysis. *World Neurosurg*, 2018, 119: e898–e909.
- Li HM, Zhang RJ, Shen CL. Radiographic and clinical outcomes of oblique lateral interbody fusion versus minimally invasive transforaminal lumbar interbody fusion for degenerative lumbar disease. *World Neurosurg*, 2019, 122: e627–e638.
- Tian W, Liu YJ, Liu B, et al. Guideline for posterior atlantoaxial internal fixation assisted by orthopaedic surgical robot. *Orthop Surg*, 2019, 11: 160–166.
- Tian W, Liu YJ, Liu B, et al. Guideline for thoracolumbar pedicle screw placement assisted by orthopaedic surgical robot. *Orthop Surg*, 2019, 11: 153–159.