



Since January 2020 Elsevier has created a COVID-19 resource centre with free information in English and Mandarin on the novel coronavirus COVID-19. The COVID-19 resource centre is hosted on Elsevier Connect, the company's public news and information website.

Elsevier hereby grants permission to make all its COVID-19-related research that is available on the COVID-19 resource centre - including this research content - immediately available in PubMed Central and other publicly funded repositories, such as the WHO COVID database with rights for unrestricted research re-use and analyses in any form or by any means with acknowledgement of the original source. These permissions are granted for free by Elsevier for as long as the COVID-19 resource centre remains active.



Original article

Aminotransferases disorders associated with venous thromboembolic events in patients infected with COVID-19

Amer Hamadé^{a,*}, Bastien Woehl^a, Marjolaine Talbot^a, Naouel Bensalah^a, Pierre Michel^a, Golnaz Obringer^a, Michèle Lehn-Hogg^a, Nathalie Buschenrieder^a, Mahdi Issa^b, Jonathan Tusch^a, Dominique Stephan^c, Lucas Jambert^a

^a Service de Médecine Vasculaire, GHRMSA, Hôpital Emile Muller, 20, Rue du Dr Laennec, 68051 Mulhouse, France

^b Service de Chirurgie Digestive, GHRMSA, Hôpital Emile Muller, Mulhouse, France

^c Service d'Hypertension et de Maladies Vasculaires, Hôpitaux Universitaires de Strasbourg, Strasbourg, France

ARTICLE INFO

Article history:

Received 16 September 2020

Accepted 6 October 2020

Available online 30 October 2020

Keywords:

COVID-19

Venous thromboembolism

Aminotransferases disorders

Direct oral anticoagulant

Liver disorders

Elevated AST and ALT

ABSTRACT

Introduction and objectives: Since the outbreak of the COVID-19 pandemic, increasing evidence suggests that infected patients present a high incidence of venous thromboembolic (VTE) events and elevated aminotransferases (AT). The objective of this work was to evaluate the incidence of aminotransferases disorders in patients infected with COVID-19 and to manage the VTE events associated with elevated AT. **Patients or Materials and methods:** We report a retrospective study of 46 patients admitted for COVID-19 infection. Venous duplex ultrasound of lower limbs was performed in all patients at Day 0 and Day 5. All patients had antithrombotic-prophylaxis upon admission using low molecular weight heparin with Enoxaparin. Demographics, comorbidities and laboratory parameters were collected and analyzed. **Results:** Elevated AT were reported in 28 patients (61%). 10 had acute VTE events of which eight (17.4%) had aminotransferases disorders. They had been treated with curative Enoxaparin. After a follow-up of 15 and/or 30 days, six of them were controlled, and treated with direct oral anticoagulant (DOACs) after normalization of aminotransferases.

Conclusions: The incidence of aminotransferases disorders associated with acute VTE events in patients infected with COVID-19 is significant. The use of DOACs appear pertinent in these patients. Monitoring of the liver balance should therefore be considered at a distance from the acute episode in the perspective of DOACs relay.

© 2020 Fundación Clínica Médica Sur, A.C. Published by Elsevier España, S.L.U. This is an open access article under the CC BY-NC-ND license (<http://creativecommons.org/licenses/by-nc-nd/4.0/>).

1. Introduction

COVID-19 spread in the East of France after a religious meeting in Mulhouse, which gathered about 2000 people from February 17th to 24th 2020. From March 2nd, our hospital had to face a massive inflow of patients presenting acute respiratory failure [1]. The largest study on COVID-19 to date showed that the prevalence of elevated aminotransferases (AT) in people faring worst was at least double that of others [2]. We further noted that there is a potential link between venous thromboembolic (VTE) events and COVID-19 infection [3]. Before initiating treatment with an oral direct anticoagulant (DOACs), liver function should be assessed. The objective of this work was to evaluate the incidence of aminotransferases disorders in patients hospitalized in a conventional unit infected with

COVID-19 and to manage the VTE events associated with elevated AT.

2. Materials and methods

This monocentric retrospective study was approved by the local ethics committee. We had oral consent from our patients for the various practical tests and for all the data provided for this study following the principles outlines in the declaration to Helsinki. From March 2nd to April 11, 46 patients with COVID-19 infection with mean age (67 ± 12 years) were hospitalized in our unit. 24 (52%) were women. The diagnostics of COVID-19 pneumonia was evaluated by a retrotranscriptase polymerase chain reaction (RT-PCR) of the samples taken with a nasopharyngeal swab. For the patients who were RT-PCR negative, the diagnostics of COVID-19 infection was confirmed by the clinical signs of the infection and the Computed Tomography (CT) following the recommendations of French Society of Thoracic Imaging [3] (Table 1).

* Corresponding author.

E-mail address: hamadea@ghrmsa.fr (A. Hamadé).

Table 1
Lung Parenchyma Lesions on Chest CT : Recommendation of French Society of Thoracic Imaging.

Chest CT Severity	Extent of Lesions %
Stage 1 Minimal	< 10
Stage 2 Moderate	10–25
Stage 3 Extended	25–50
Stage 4 Severe	50–75
Stage 5 Critical	> 75

CT without concentration iodine contrast. In patients with COVID-19 we show a characteristic lung parenchyma lesions : ground glass and crazy paving pattern opacity. These lesions are classified in 5 stages.

Complete venous duplex ultrasound (DU) was performed at Day (D) 0 and D 5 by the team of Vascular Medicine. The calf, popliteal, femoral, great and small saphenous veins were explored using the ultrasound machine Samsung HS50. When it was possible we examined iliac veins and inferior vena cava. The main criteria for a positive diagnosis of venous thrombosis were venous incompressibility under the cross-section probe and the direct visualization of the thrombus. The secondary criteria was the absence of the Doppler flow in the vein. DVT was classified as distal (below the popliteal vein) or proximal (popliteal or above popliteal veins). The DU was carried out according to a strict protocol in order to protect the examiner.

Demographics, comorbidities characteristics were collected and laboratory parameters were automatically extracted from our health information system.

Table 2
Patient Characteristics.

variable	Total 46 patients	36 NO VTE	10 VTE	P value
Age (years)	67.2 ± 12.0	67.1 ± 12.1	67.6 ± 12.4	0.79
F (n,%)	24 (52%)	20 (56%)	4 (40%)	0.48
M (n,%)	22 (48%)	16 (44%)	6 (60%)	
AST (<UI/L)	50.3 ± 34.1	50.4 ± 34.7	50.1 ± 33.7	0.94
ALT (<61UI/L)	50.3 ± 34.1	48.9 ± 31.5	91.5 ± 71.0	0.16
Total Bilirubin (1–17um/L)	9.90 ± 4.01	10.1 ± 4.41	9.40 ± 2.84	1
D-dimer (<500 ng/mL)	2914 ± 5362	1779 ± 2941	7315 ± 9550	0.021
GammaGT (15–85 UI/L)	136 ± 152	128 ± 155	173 ± 145	0.41
Alkaline phosphatase (45–117 UI/L)	149 ± 206	159 ± 230	114 ± 70.7	0.71
CRP (0–3 mg/L)	83.3 ± 61.8	69.7 ± 53.1	110 ± 72.8	0.11
GF >90 ml/min)	78.6 ± 30.0	78.1 ± 31.1	80.7 ± 26.5	1
BMI (kg/m ²)	27.9 ± 4.14	27.8 ± 4.03	28.3 ± 4.74	0.72
aPTT (0.86–1.20)	1.09 ± 0.298	1.09 ± 0.236	1.10 ± 0.456	0.19
NT-proBNP (<194 pg/mL)	2388 ± 5361)	2879 ± 5927	483 ± 480	0.52
CPK (26–192 UI/L)	124 ± 83.3)	134 ± 83.3	46.5 ± 19.1	0.079
Hemoglobin (13.5–16.9 g/dL)	12.7 ± 2.05	12.5 ± 1.87	13.2 ± 2.78	0.23
LDH (57–241 UI/L)	360 ± 151	361 ± 159	356 ± 134	1
Lymphocytes (1.26–3.35 × 10.9/L)	1.28 ± 1.39	1.28 ± 1.57	1.27 ± 0.475	0.16
Platelets (166–308 × 10.9/L)	280 ± 108	280 ± 108	301 ± 87.1	0.36
WBC (3.91–10.9 × 10.9/L)	7.85 ± 4.08)	6.83 ± 3.52	11.2 ± 4.15	<0.01
Prothrombin time %	78.3 ± 13.9	78.3 ± 15.0)	78.4 ± 10.7	0.91
Home	8 (18%)	22(63%)	7 (70%)	0.87
ICU	4 (11%)	6(17%)	2(20%)	
Follow-up care	3(6.5%)	4(11%)	0(0%)	
Death		2(8.6%)	1(10%)	
Hypertension	25 (54.3%)	22(5.5%)	3(30%)	
Diabetes	7 (15.2%)	7(19.4%)	0(0%)	
Dyslipidemia	11 (24%)	10 (27.8%)	1(10%)	
Digestive symptoms	4 (8.7%)	3 (8.3%)	1 (10%)	
History/liver diseases (n,%)	0 (0%)	0(%)	0(%)	
Smoking	10 (21.7%)	10 (27.8%)	0(0%)	
Lymphopenia	29 (63%)	24(67%)	5(50%)	
Active cancer	0 (0%)	0 (0%)	0 (0%)	
History of cancer (n,%)	3 (6.5%)	3 (8.3%)	0(0%)	
History of VTE (n,%)	3 (6.5%)	2(5.5%)	1(10%)	
Chronic Renal Failure	5 (8.7%)	5 (13.9%)	0(0%)	
Haemodialysis	2(4.3%)	2(5.6%)	0(0%)	
Sleep Apnea Syndrome	6 (13%)	4 (11%)	2(20%)	
Septicaemia	0 (0%)	0 (0%)	0 (0%)	

. BMI = Body mass index. CRP = C-reactive protein. LDH = Lactic aciddehydrogenase. ICU = Intensive Care Unit. NT-proBNP = N-terminal prohormone brain natriuretic peptide. aPTT = Activated partial thromblastine time. WBC = White blood cells. CPK = creatine phosphokinase.

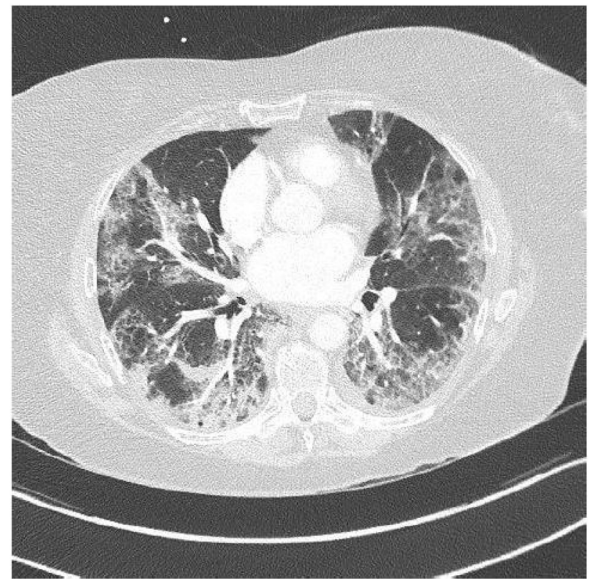


Fig. 1. Lung parenchyma lesions in COVID-19: Patient with COVID-19 infection who presented lung parenchyma lesions on chest CT without iodine contrast, stage (extended lesions 50-75 % of lung parenchyma: bilateral peripheral ground-glass opacities: classification of the French Society of Thoracic Imaging.

Table 3
10 patients (21.7%) of the cohort wit VTE.

	P1	P2	P3	P4	P5	P6	P7	P8	P9	P10
Age (years)	56	70	72	69	67	79	74	81	79	58
Sex	F	M	M	F	F	M	F	M	M	M
DVT	DIST	DIST	PROX	PROX	PROX	NON	PROX	PPROX	DIST	PROX
PE	NO	NO	Lobar	NO	NO	Lobar	Lobar	CT ND	CT N D	CT ND
D-dimer (<500 ng/mL)	4631	1337	25,000	19,889	700	4179	7261	N D	N D	6821
AST (<37 UI/L)	55	115	29	47	30	106	59	47	78	58
ALT (<61 UI/L)	23	190	37	171	25	174	72	88	44	102
Total Bilirubin (1–17um/L)	13	7	6	11	9	7	9	8	8	9
GammaGT(15–85 UI/L)	384	286	95	-----	8	308	21	N D	402	102
Alkaline Phosphatase 45–117 UI/L	84	126	62	253	61	88	56	N D	319	105
aPTT (0.86–1.20)	0.83	1.13	1.08	0.85	1.03	1.36	1.07	1.05	1.21	1.11
PT %	75	76	76	62	84	65	82	57	84	87
GF(> 90 mL/min)	104	97	92	33	90	55	61	63	65	95
Platelets (166–308 × 10.9/L)	249	478	249	318	208	311	180	689	251	364
Treatment	T.LMWH	T.LMWH	T.LMWH	T.LMWH	T.LMWH	T.LMWH	T.LMWH	T.LMWH	T.LMWH	T.LMWH
ICU	NO	Day 2	NO	Day 1	NO	NO	NO	NO	NO	NO
Death	NO	NO	NO	NO	NO	Day 6	NO	NO	NO	NO
Bleeding	NO	NO	NO	NO	NO	NO	NO	NO	NO	NO

T.LMWH = Therapeutic lower molecular weight heparin. Total Bil = Total Bilirubin. DIST = distal. PROX = Proximal CT = Computed tomography. ND =not done. PT = Prothrombin time. P = Patient.

All hospitalized patients had anticoagulation treatment on admission. Classic prophylactic anticoagulation treatment (PAT) is defined by the administration of standard doses of low molecular weight heparin (LMWH) (4000 IU of Enoxaparin every 24 h for patients with a weight less than 100 kg or 6000 IU every 24 h for patients with a weight greater than 100 kg). The patients with a history of VTE had been treated with therapeutic anticoagulation using subcutaneous Enoxaparin (100 UI/12 h).

Qualitative and quantitative variables were analyzed using means or medians, percentages and standard deviations. Univariate analysis were performed, Mann-Whitney and Fisher tests were used to establish the correlation between the variables. P values less than 0.05 were considered to indicate statistical significance.

3. Results

COVID-19 false negative test results can be seen in patients infected [4].PCR was positive in 37 patients (80%), in nine (20%) COVID-19 infection was confirmed with a chest CT showing a characteristic lung parenchyma lesions : bilateral peripheral ground-glass opacities (Fig. 1).

Upon admission, we observed elevated C-reactive protein (CRP) (mean 83.3 ± 61.8 mg/l) in 39 patients (84.8%), 29 % had lymphopenia (mean 1.28 ± 1.39 × 10.9/l), 28 % with anemia (mean Hemoglobin 12.7 ± 2.05 g/dl). In our cohort, the activated partial thromblastine time was 1.09 ± 0.298, prothrombin time was 78.3 ± 13.9%), and glomerular filtration (GF) rate was 78.6 ± 30.mil/min.D-dimer levels and white blood cells rate were significantly associated with VTE events (7317 ± 9550 in the group with VTE versus 1779 ± 2941 ng/ml p = 0.021 and 11.2 ± 4.15 versus 6.83 ± 3.52 × 10.9/L p < 0.01).

Biological cholestasis was observed in 10 patients (21.7%). Patient characteristics are summarized in the Table 2.

Six patients had pulmonary CT angiogram for suspicion of pulmonary embolism (PE) of them three (50%) with acute PE. We reported one primary PE and two associated with proximal deep venous thrombosis of lower limb (DVT).

DU showed acute DVT in nine patients (19.5%) of whom two was diagnosed at D 5 despite PAT. Six were proximal (67%) and three (33%) distal (Table 3).In six patients, DVT was without signs and symptoms, two had pain and leg edema (Table 3).

We observed elevated AT in 28 patients (68.3%),11 of them (24%) had hepatic impairment with AST twice normal (normal <37 UI/L). In five (11%) ALT was twice normal (normal < 61 UI/L). Of the 10

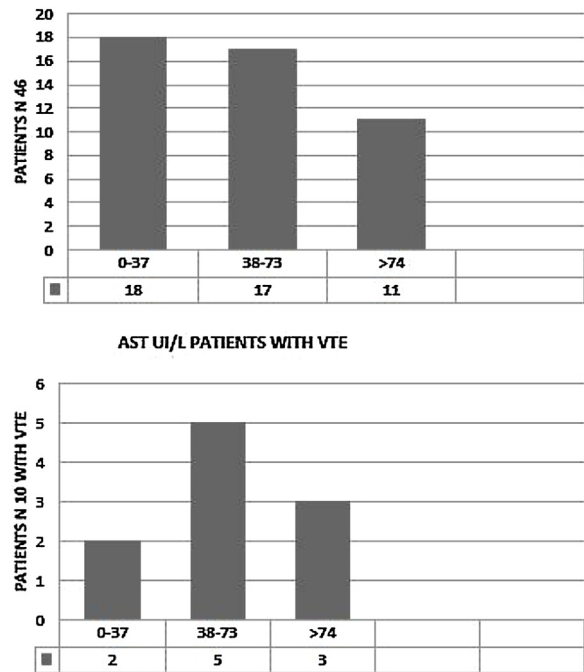


Fig. 2. AST disorders in the cohort (46 patients) and in the patients with VTE (10 patients) AST UI/L, normal < 37 UI/L.

patients with VTE, eight (80%) had elevated AT. AST > 74 UI/L was reported in three patients (37.5%) (Fig. 2) and four (50%) had ALT > 120 UI/L. (Fig. 3). Total Bilirubin rate was normal in all patients (mean 9.90 ± 4.01 um/l).

Four patients (8.7%) described digestive symptomatology (abdominal pain and nausea). None of our patients had history of liver diseases, two had history of VTE. The management consisted of a bi-antibiotic therapy with Cefotaxime and Azithromycin /IV, paracetamol and oxygen therapy. The patients without acute VTE received PAT, those with acute VTE had a therapeutic anticoagulation with Enoxaparin (100 UI/12 h); however, no bleeding tendency was noted (no bruise, hematoma, digestive bleeding or epistaxis were detected). During hospitalization the evolution was marked by a stability of liver enzymes without aggravation after the initiation of the different therapies.

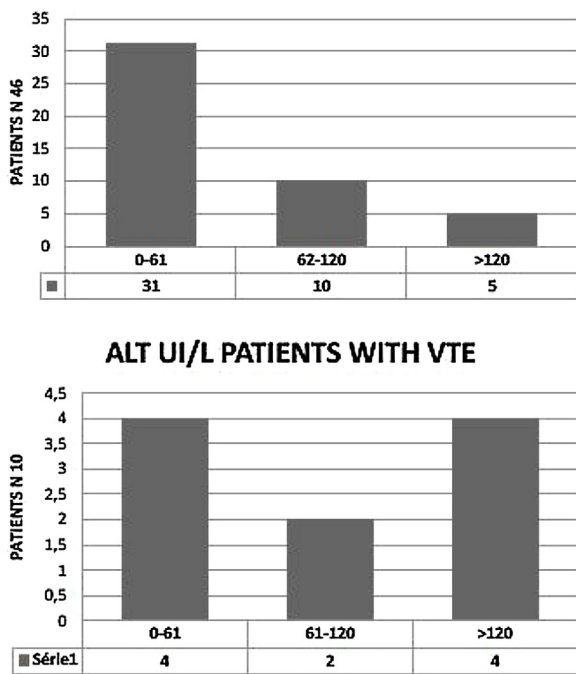


Fig. 3. ALT disorders in the cohort (46 patients) and in the patients with VTE (10 patients) ALT UI/L, normal < 61 UI/L.

Table 4
8 patients (17.4%) Patients Transferred to ICU.

Variable	NO ICU n = 38	ICU n = 8	P value
Age (years)	68.4 ± 12.3	61.5 ± 9.12	0.15
ALT (<61 UI/L)	56.7 ± 44.7	65.2 ± 53.2	0.67
AST (<37UI/L)	52.3 ± 35.6	52.2 ± 32.5	0.73
Total Bilirubin (1–17um/L)	9.79 ± 3.97	9.79 ± 3.97	0.77
GammaGT (15–85 UI/L)	116 ± 131	276 ± 227	0.06
Alkaline phosphatase (45–117 UI/L)		192 ± 132	0.12
D-dimer (<500 ng/mL)	2885 ± 5066	3522 ± 6647	0.91
VTE (n,%)	8(21%)	2(25%)	1
GF (>90 ml/min)	78.0 ± 27.9	81.8 ± 40.7	0.14
BMI (kg/m ²)	27.5 (±4.34)	29.6 (±2.76)	0.13
CPK (26–192 UI/L)	143 (±91.1)	76.6 (±25.7)	0.17
LDH (57–241 UI/L)	374 (±136)	325 (±194)	0.41
Hemoglobin (13.5–16.9 g/dL)	12.9 (±1.96)	11.7 (±2.38)	0.086
Lymphocytes (1.26–3.35 × 10.9/L)	1.31 (±1.53)	1.15 (±0.522)	0.68
NT-proBNP (<194 pg/mL)	2731 (±5945)	1056 (±1400)	0.97
Platelets (166–308 × 10.9/L)	270 (±113)	326 (±69.0)	0.046
Bleeding (n,%)	0 (0%)	0 (0%)	

Eight patients (17.4%) were transferred to the Intensive Care Unit (ICU) for acute respiratory failure. Elevated platelets rate was significantly associated with the transfer (mean 326 ± 69.0 versus 270 ± 113 × 10.9/L, p = 0.046) (Table 4).

Three patients died (6.5%). The age (mean 83.3 ± 6.66 versus 65.5 ± 10.9 years, p value 0.017), AST (mean 125 ± 21.9 versus 84.2 ± 69.4 UI/L p < 0.01), GF rate (mean 35.2 ± 17.8 versus 82.9 ± 27.6 mL/min p < 0.01), white blood cells (mean 12.3 ± 3.13 versus 7.52 ± 3.97 × 10.9/l, p = 0.048) and N-terminal prohormone brain natriuretic peptide rate (mean 8665 ± 7169 versus 1865 (±4960) pg/mL, p = 0.025) were significantly associated with death. The three patients indeed died in the conventional unit after cardio-respiratory failure (Table 5).

After their discharge, the patients with VTE were treated at home with therapeutic Enoxaparin (100 UI/12 h), and those without VTE with PAT for 14 days.

With follow-up of 15 and 30 days, we controlled six patients (75%) who had VTE with elevated AT. A treatment with curative DOACs was initiated after normalization of the aminotransferases

at Day 15 in four patients, in two DAOCs was started at Day 30 (Table 6).

At D30 after their discharge, 12 patients who had elevated AT without VTE were checked. In 10 patients, liver enzymes were normal.

4. Discussion

Thrombosis associated with acute viral infection has been described in the literature. The incidence of thrombosis among hospitalized patients with acute cytomegalovirus (CMV) infection has been studied once by Atzmony L et al. [5]; they retrospectively studied the incidence of DVT as among 140 consecutive patients with acute CMV infection, the incidence of DVT was 2.9%. In our cohort infected with COVID-19, the prevalence of DVT at Day 0 was 9.7%. A relationship between VTE has been reported in patients with COVID-19 pneumonia.

Cui S. et al. [3] described 25% of DVT in 81 patients hospitalized in ICU with COVID-19 pneumonia with elevated D-dimer levels. Middeldrop S. et al. [6] reported 20% of VTE events in 198 patients with COVID-19 pneumonia (38% in ICU) during follow-up of 7 days. 21.7% of our patients had acute VTE with follow-up of 5 days (1 primary PE and 9 DVT).

The significant increase of D-dimer in severe COVID-19 patients is a good index for identifying high-risk groups of VTE. The patients need PTA and in some cases curative anticoagulant treatment [3]. In our study, D-dimer levels were significantly associated with VTE and all the patients had PTA upon admission.

Many viral infections provoke aminotransferases disorders, viral hepatitis in the first place [7]. Other viruses can also disrupt liver function such as CMV [8]. Elevated AT was also observed in respiratory tropism viruses such as Middle East Respiratory Syndrome-Cov [9] and severe acute respiratory syndrome-Cov (SARS) [10]. The pathophysiology of the new SARS-Cov-2 virus is still poorly understood but it is admitted that there are forms with digestive symptomatology [11]. In our population, four patients (8.7%) of 46 had digestive signs and symptoms.

Review of the Chinese studies covering 8 studies for a total of 1,628 patients, showed rates ranging from 16.1% to 53.1% of elevated TA during infection with SARS-Cov-2 [12]. Aminotransferases disorders were observed in our cohort in 28 patients (61%) of them 24% had AST twice normal and in 11% the ALT.

DOACs are indicated in the treatment of thromboembolic events. However, some precautions should be taken before considering their use, especially in cirrhotic patients, cancer, «extreme» weights (≤60 and > 100 kg) [13]. Rarely DOACs can indeed cause liver disorders even in patients without particular risk [14]. The patients with significant hepatic impairment (aminotransferases and bilirubin double) normal) were excluded from studies with DOACs. In the presence of significant hepatic impairment and according to the Child-Pugh classification, DOACs may be used with caution [15]. We were facing a new pathology, the oral treatment with warfarin was also likely to be compromised [16]. For this reason, we preferred to treat all patients with VTE who had elevated AT with therapeutic LMWH until the standardization of the biological balance sheet.

Patients infected with COVID-19 have an excessive inflammation with a cytokine storm [17], elevated CRP in our population (84.8%) could be related to the inflammatory response.

Our study is limited due to the very small number of patients; the significance of elevated AT and VTE events associated with these disorders may have been influenced by this limited cohort. COVID-19 infection is frequently complicated by elevated AT and VTE. The use of DOACs in the acute VTE in these patients does not appear pertinent. Monitoring of the liver balance should therefore be con-

Table 5
3 patients (6.5%) Patients died.

	SURVIVED n = 43 (91.3%)	DIED n = 3 (8.7%)	P value
Age	65.5 ± 10.9	83.3 ± 6.66	0.017
ALT (<61 UI/L)	55.7 ± 43.3	106 ± 65.6	0.097
AST (< 37 IU/L)	84.2 ± 69.4	125 ± 21.9	<0.01
Total Bilirubin (17um/L)	9.89 ± 4.16	8.50 ± 2.12	0.85
GammaGT (15–85 UI/L)	140 ± 155	128 ± 158	0.87
Alkaline phosphatase (45–117 UI/L)	156 ± 218	107 ± 29.8	0.33
D-dimer (<500 ng/mL)	3118 ± 5596	2060 ± 1594	0.72
VTE (n,%)	9(21.4%)	1(33%)	0.54
GF (>90 ml/min)	82.9 ± 27.6	35.2 ± 17.8	<0.01
BMI (kg/m ²)	28.1 ± 4.11	27.9 ± 4.14	0.71
WBC (3.91–10.9 × 10.9/L)	7.52 ± 3.97	12.3 ± 3.13	0.048
Lymphocytes (1.26–3.35 × 10.9/L)	1.05 ± 0.514	4.32 ± 4.54	0.082
Platelets (166–308 × 10.9/L)	281 ± 111	272 ± 76.7	0.96
NT-proBNP (<194 pg/mL)	1865 (±4960)	8665 ± 7169	0.025
LDH (57-241 UI/L)	366 ± 157	304 ± 79.9	0.59
Hemoglobin (13.5-16.9 g/dL)	12.8 ± 1.97	10.8 ± 3.03	0.3
Prothombin Time (%)	78.0 ± 13.9	82.7 ± 15.3	0.5
CPK (26-192 UI/L)	124 ± 83.3	96.5 ± 47.4	0.75
Bleeding (n,%)	0 (0%)	0 (%)	
	DeadP1	DeadP2	DeadP3
Age (years)	79	80	92
GF (>90 ml/min)	55	12	34
WBC (3.91–10.9 × 10.9/L)	10.56	15.92	10.43
AST (< 37 UI/L)	115	120	149
NT-proBNP (<194 pg/mL)	1319	15,643	9032
VTE	Lobar PE	NO	NO

Table 6
Follow-up Patients D15- D 30.

Variable	P 1	P 7	P 9	P 8	P2	P10
Age (years)	56	74	79	81	70	58
Sex	F	F	M	M	M	M
AST D0 UI/L	55	74	78	80	70	58
ALT D 0 UI/L	22	59	44	47	115	102
DVT	D5 distal	D0 Proximal	D0 Distal	D0 Proximal	D0 Distal	D0 Proximal
PE	NO	LOBAR	PCTA ND	PCTA ND	NO	PCTA ND
Transfer ICU	NO	NO	NO	NO	D2 after admission	NO
Death	NO	NO	NO	NO	NO	NO
AST D15	18	30	19	39	50	52
ALT D15	6	45	17	51	100	85
AST D30	-----	-----	-----	----	22	22
ALT D30	-----	-----	-----	-----	60	66
Bleeding	NO	NO	NO	NO	NO	NO
DOACs	D15	D15	D15	D15	D30	D30

PCTA ND = Pulmonary CT angiogram not done.

sidered at a distance from the acute episode in the perspective of DOACs relay.

The patients with COVID-19 pneumonia have a profound hypercoagulable state, and complicating venous thrombotic events are common. COVID-19 infection fulfil the three criteria of the Virchow triad among hypercoagulability, endothelial dysfunction [18] and stasis. Hospitalized COVID-19 patients require an early administration of PTA with LMWH as part of their treatment. Based on these findings, these patients also require a follow-up with vein ultrasonography. DU is a quick, easy and non invasive exam. Abbreviations VTE Venous thromboembolism AT Aminotransferases AST Aspartate aminotransferase DOACs Direct oral anticoagulant CPK Creatine Phosphokinase DVT Deep venous thrombosis PE Pulmonary Embolism LMWH Lower molecular weight heparin PAT Prophylactic anticoagulation treatment DU Duplex ultrasound GFGlomerular filtration CRP C-reactive protein RT-PCR Transcriptase polymerase chain reaction ALT Alanine aminotransferase CT Computed tomography ICU Intensive care unit CMV Cytomegalovirus SARS Severe acute respiratory syndrome D Day

Abbreviations

- VTE Venous thromboembolism
- AT Aminotransferases
- AST Aspartate aminotransferase
- DOACs Direct oral anticoagulant
- CPK Creatine Phosphokinase
- DVT Deep venous thrombosis
- PE Pulmonary Embolism
- LMWH Lower molecular weight heparin
- PAT Prophylactic anticoagulation treatment
- DU Duplex ultrasound
- GF Glomerular filtration
- CRP C-reactive protein
- RT-PCR Transcriptase polymerase chain reaction
- ALT Alanine aminotransferase
- CT Computed tomography
- ICU Intensive care unit
- CMV Cytomegalovirus
- SARS Severe acute respiratory syndrome
- D Day

Sources of funding

None.

Conflicts of interest

The authors declare that there is no conflict of interest for this publication.

Acknowledgements

The authors would like to thank Mrs. Floralie GALLION and Mrs. Céline LAPIERRE to their precious help in the data collection

References

- [1] Kuteifan K, Pasquier P, Meyer C, Escarment J, Theissen O. The Outbreak of COVID-19 in Mulhouse : Hospital Crisis Management and Deployment of Military Hospital During the Outbreak of COVID-19 in Mulhouse. France. *Ann Intensive Care* 2020;10(1):59, doi.org/10.1186/s13613-020-00677.
- [2] Zhang C, Shi L, Sheng Wang F. Liver injury in COVID-19: management and challenges. *Lancet Gastroenterol Hepatol* 2020;5(5):428–30, doi.org/10.1016/S2468-1253(20)30057-1.
- [3] Cui S, Chen S, Li X, Liu S, Wang F. Prevalence of venous thromboembolism in patients with severe novel coronavirus pneumonia. *J Thromb Haemost JTH* 2020, doi :10.1111/jth.14830.
- [4] La société d'Imagerie Thoracique propose un compte-rendu structuré de scanner thoracique pour les patients suspects de COVID-19 [Internet]. SFR e-Bulletin. 2020 [cited 2020 Apr 29]. Available from: <https://ebulletin.radiologie.fr/actualites-covid-19/societe-dimagerie-thoracique-propose-compte-rendu-structure-scanner-thoracique>. Article in French.
- [5] Lauren M, Kucirka LM, Lauer SA, Laeyendecker O, Boon D, Lessler J. Variation in false negative rate of reverse transcriptase polymerase chain reaction–Based SARS- CoV-2 tests by time since exposure. *Ann Intern Med* 2020. M20-1495. doi: 10.7326/M 20-1495.
- [6] Atzmony L, Halutz O, Avidor B, Finn T, Zimmerman O, Steinvil A, et al. Incidence of cytomegalovirus-associated thrombosis and its risk factors: a case-control study. *Thromb Res* 2010;126(6):e439–443, doi.org/10.1016/j.thromres.2010.09.006.
- [7] Middeldorp S, Coppens M, Van Haaps TF, Foppen M, Vlaar AP. Incidence of venous thromboembolism in hospitalized patients with COVID-19. *Journal Throm Haemost. and Haemostasis* 2020;18(8):1995–2002, <http://dx.doi.org/10.1111/jth.14888>.
- [8] Blasco-Perrin H, Péron J-M. Hepatic and extra-hepatic manifestations of hepatitis E virus infection. *Presse Med* 2018;47(7-8 Pt 1):620–4, doi:10.1016/j.lpm.2015.04.017. Article in French.
- [9] Jensen KO, Angst E, Hetzer FH, Gingert C. Acute cytomegalovirus hepatitis in an immunocompetent host as a reason for upper right abdominal pain. *Case Rep Gastroenterol* 2016;10(1):36–43, doi:10.1159/000442972.
- [10] Azhar El, Hui DSC, Memish ZA, Drosten C, Zumla A. The middle east respiratory syndrome (MERS). *Infect Dis Clin North Am* 2019;33(4):891.
- [11] Chau T-N, Lee K-C, Yao H, Tsang T-Y, Chow T-C, Yeung Y-C, et al. SARS-associated viral hepatitis caused by a novel coronavirus: report of three cases. *Hepatology* 2004;39(2):302–10, doi:10.1002/hep.20111.
- [12] Gu J, Han B, Wang J. COVID-19: gastrointestinal manifestations and potential fecal–oral transmission. *Gastroenterology* 2020;158(6):1518–9, <http://dx.doi.org/10.1053/j.gastro.2020.02.054>.
- [13] Tran H, Joseph J, Young L, McRae S, Curnow J, Nandurkar H, et al. New oral anticoagulants: a practical guide on prescription, laboratory testing and periprocedural/bleeding management. *Australasian Society of Thrombosis and Haemostasis. Intern Med J* 2014;44(6):525–36, doi:10.5694/mja2.50004.
- [14] Cordeanu M, Gaertner S, Bensalah N, Hamade A, Stephan D. Rivaroxaban induced liver injury: a cholestatic pattern. *Int J Cardiol* 2016;216:97–8, 8.doi:10.1016/j.icard.2016.04.063.
- [15] Bornet S, Dolapsakis C, Petignat PA, Gobin N. Direct oral anticoagulants : some practical considerations. *Rev Med Suisse* 2016;12(529):1453–9. Article in French.
- [16] Kow CS, Sunter W, Bain A, Zaidi ST, Hasan SS. Management of outpatient warfarin therapy amid COVID-19 pandemic: a practical guide. *Am J Cardiovasc Drugs* 2020;1–9, <http://dx.doi.org/10.1007/s40256-020-00415-z>.
- [17] Jose RJ, Manuel A. COVID-19 cytokine storm: the interplay between inflammation and coagulation. *Lancet Respir Med* 2020;8(6):e46–7, doi.org/10.1016/S2213-2600(20)30216-2.
- [18] Varga Z, Flammer AJ, Steiger P, Haberecker M, Andermatt R, Annelies S, et al. Endothelial cell infection and endotheliitis in COVID-19. *Lancet* 2020;395(10234):1417–8, doi:10.1016/S0140-6736(20)30937-5.