



Since January 2020 Elsevier has created a COVID-19 resource centre with free information in English and Mandarin on the novel coronavirus COVID-19. The COVID-19 resource centre is hosted on Elsevier Connect, the company's public news and information website.


Elsevier hereby grants permission to make all its COVID-19-related research that is available on the COVID-19 resource centre - including this research content - immediately available in PubMed Central and other publicly funded repositories, such as the WHO COVID database with rights for unrestricted research re-use and analyses in any form or by any means with acknowledgement of the original source. These permissions are granted for free by Elsevier for as long as the COVID-19 resource centre remains active.



ELSEVIER

Contents lists available at ScienceDirect

Journal of Gynecology Obstetrics and Human Reproduction

journal homepage: www.elsevier.com/locate/jogoh

Sickle cell disease and COVID-19 in pregnant women

Kamila Kolanska^{a,*}, Radostina Vasileva^a, François Lionnet^b, Aline Santin^b, Suha Jaudi^a,
Yohann Dabi^a, Nathalie Chabbert-Bufferet^a, Emile Daraï^a, Marie Bornes^a

^a Department of Gynecology Obstetrics and Reproductive Medicine, Tenon Hospital, AP-HP, Sorbonne University, 4 rue de la Chine, Paris 75020, France

^b Department of Internal Medicine, Reference Center of Sickle cell Anemia (AP-HP), University Hospital Center of Tenon, Sorbonne University, rue de la Chine, Paris 75020, France



ARTICLE INFO

Article history:

Received 3 November 2021

Revised 21 January 2022

Accepted 27 January 2022

Available online 29 January 2022

Keywords:

COVID-19

Pregnancy complications

Sickle-cell disease

ABSTRACT

Introduction: The effect of coronavirus disease (COVID-19) on pregnancy outcome in women with sickle cell disease (SCD) is unknown.

Objectives: To analyze the severity of the SARS-CoV-2 infection in pregnant women with SCD and its impact on pregnancy.

Methods: This retrospective cohort study included SCD pregnant women tested positive for COVID-19 between March 2020 – February 2021. The primary endpoint was the severity of the COVID-19 infection. Secondary endpoints were pregnancy complications and fetal outcomes.

Results: During the study period among 82 pregnant women with SCD, 8 have presented symptoms suggestive of COVID-19 and were tested positive. A common mild clinical presentation was observed in 6 women (75%), one woman was asymptomatic and one required oxygen. The latter was admitted to the Intensive Care Unit and a cesarean section was performed in the context of an ongoing vaso-occlusive crisis and acute chest syndrome together with incidental preeclampsia. Labor was induced in another patient who developed a vaso-occlusive crisis after COVID-19 remission. Fetal outcomes were good with an average Apgar score of 10 and normal umbilical blood pH at birth. Two newborns were small-for-gestational-age as expected on the ultrasound follow-up before occurrence of COVID-19.

Conclusion: COVID-19 infection in our population of pregnant women with SCD had typical presentation and rarely triggered a sickle cell crisis or other complications. Fetal outcomes were good and did not seem to be directly influenced by the SARS-CoV-2 virus. Further studies are required to confirm these observations as compared to the population of women with SCD without COVID-19 infection.

© 2022 Elsevier Masson SAS. All rights reserved.

Introduction

Sickle cell disease (SCD), the most common inherited hematological disorder with a global birth prevalence of approximately 1–5 per 10,000 predominantly affects subjects of African origin [1]. The condition is associated with early mortality although improved healthcare has raised the life expectancy of patients with SCD to around 50 years [2,3]. The number of pregnant women with SCD is increasing along with this improvement in life expectancy. Nevertheless, despite these advances in healthcare, pregnancy in SCD patients remains associated with a greater risk of both clinical and obstetric maternal and fetal complications than in SCD-free pregnant women [1,4]. Women with SCD are at a higher risk of maternal death (72.4 deaths versus 12.7 per 100,000 deliveries) and are more likely to experience gestational hypertension [5], vaso-

occlusive crises (VOC) [6], deep vein thrombosis, fetal growth restriction, and systemic inflammatory response syndrome [7].

In the current pandemic, the data about the clinical course of the infection with the severe acute respiratory syndrome coronavirus 2 (SARS-CoV-2) in pregnant women without comorbidities are controversial [8,9]. The literature analyzing the impact of coronavirus disease 2019 (COVID-19) on obstetrical and neonatal outcomes shows also conflicting data [8,9].

Additionally, articles analyzing COVID-19 outcomes in patients with SCD conclude that patients with SCD experience a rather mild form of infection [10–12], and some even suggest a lower risk of intubation, Intensive Care Unit (ICU) admission, and death [13]. Of note, subjects carrying the HbSC genotype may display a more severe course of COVID-19 [14].

However, data concerning the course of COVID-19 and pregnancy outcomes in the population of pregnant women with SCD are scarce. One single case of COVID-19 in a pregnant woman with SCD has been reported so far. The SARS-CoV-2 infection at 28

* Corresponding author.

E-mail address: kamila.kolanska@aphp.fr (K. Kolanska).

weeks of gestation (WG) triggered an acute chest syndrome (ACS) but the outcome was ultimately positive [15].

More information is therefore necessary to adapt healthcare during pregnancy for women with SCD experiencing COVID-19. The aim of this study was to describe SARS-CoV-2 infection in the potentially high-risk group of pregnant women with SCD.

Patients and methods

Study setting and participants

We conducted a retrospective cohort study in Tenon Hospital (Paris, France), a secondary care unit and reference center for pregnant women with SCD, between the 1st March 2020 and 1st March 2021. During the study period the unit managed 82 deliveries in women with SCD out of a total of 2489 deliveries. Among women with SCD, 8 had symptoms suggestive of COVID-19 and were tested for SARS-Cov-2.

We enrolled all patients aged over 18 years, with an ongoing pregnancy, and diagnosed with active SARS-CoV-2 infection, and conducted a descriptive analysis in the subset of women with SCD.

Non-inclusion criteria were patients aged under 18 years, patients diagnosed with COVID-19 by a method other than a PCR nasal swab, lack of healthcare insurance, and a language barrier interfering with data collection.

Study protocol

Pregnant women monitored at Tenon Hospital or consulting at the Gynecology and Obstetrics emergency department with COVID-19 compatible symptoms were systematically tested using PCR nasal swabs.

Data from all pregnant women positive for COVID-19 with a proven infection between March 2020 and March 2021 were analyzed. Active viral infection was diagnosed by detection of SARS-CoV-2 RNA from a nasal swab test performed by a trained practitioner. The cohort data were collected from the prospective obstetric database used routinely in the Department of Obstetrics of Tenon Hospital.

During the first wave of the pandemic (March to August 2020), patient specific data about the course of COVID-19 were collected via a daily phone call following a standardized questionnaire administered by trained obstetricians until the symptoms disappeared. From August 2020 to the end of the study period, data were obtained at regular follow-up appointments. If a patient was hospitalized for COVID-19 treatment, data were collected directly from the hospital database completed daily by the unit's physicians.

A subset of patients with SCD was identified among COVID-19 patients to study infection severity and pregnancy outcomes.

Oral informed consent for data collection was obtained from all the patients. The study was approved by the Institutional Review Board of the French College of Obstetricians and Gynecologists – CEROG (registration N° 2021-GYN-0201).

Data analysis

A descriptive analysis of the characteristics and outcomes of cases meeting the inclusion criteria was done. Descriptive analysis included frequencies and percentages for qualitative variables and means with standard deviation or medians with interquartile range (IQR) as appropriate for quantitative variables.

Results

Two hundred fifty-two patients were tested for COVID-19 between March 2020 and March 2021: 162 in the first COVID-19

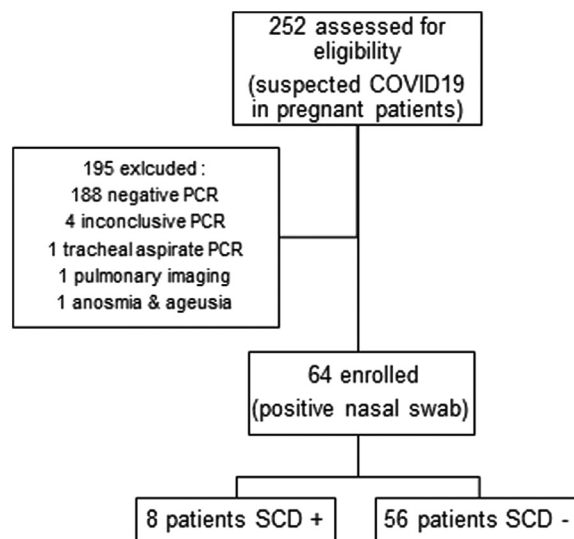


Fig. 1. Flow chart.

wave in France and the following months (March to August); and 90 in the second wave. Four patients were excluded from the analysis because of inconclusive PCR results. Among the patients with a negative PCR nasal swab one patient was diagnosed with COVID-19 after tracheal aspirate during hospitalization in the ICU, one patient was diagnosed after a pulmonary scan, and another was considered positive as she presented with anosmia and ageusia but was not tested. Finally, 64 pregnant women with a positive PCR nasal swab test were enrolled in the cohort, eight of whom (12.5%) were patients with previously diagnosed SCD (Fig. 1). None of the women included in the study was vaccinated.

Characteristics of the population

The baseline characteristics of the eight pregnant patients with SCD diagnosed with COVID-19 are detailed in Table 1. The median maternal age was 30.5 years (24.0–34.3). The median gestational age at COVID-19 diagnosis was 26.5 WG (20–35); three women were in the third trimester and the other five were <28 WG. All the patients were of African origin and all women except one had a normal body mass index (BMI) before the pregnancy (22 (20–24) kg/m²). Only one patient was primiparous (12.5%).

Three patients had a history of cesarean section during a prior pregnancy: one for intrauterine growth restriction (IUGR) and fetal heart rate (FHR) abnormalities, the second for PE, and the third for isolated FHR abnormalities (Table A.1).

Of the eight cases, four (50%) had SS sickle cell anemia (i.e., homozygous for Hemoglobin S gene), two (25%) had double heterozygosity for HbS/β-thal, and two (25%) had HbS/HbC disease. Seven cases (87.5%) had a previous history of VOC, which had occurred during a previous pregnancy for four. Five patients had a history of acute chest syndrome (ACS). Three patients in the cohort had long-term therapy such as exchange transfusion initiated in one patient initiated before the pregnancy and in two others during the current pregnancy, either by manual exchange, or by erythrocytapheresis (Table A.1). Underlying pulmonary disorders were asthma ($n = 1$), restrictive lung disease ($n = 1$), or a history of chronic idiopathic dyspnea ($n = 1$). None of the patients were smokers.

On diagnosis of COVID-19, two patients were using low-dose aspirin: one because of a history of IUGR, and the other because of SCD cerebral vasculopathy. The latter (patient #2) was also receiving anti-epileptic drugs (Levetiracetam 500 mg twice a day and Lamotrigine 150 mg twice a day) and inhaled fluticas-

Table 1
Characteristics of the study population.

Baseline variables	SCD + (n = 8)
Age (years), median (IQR)	30.5 (24 – 34.25)
BMI, median (IQR)	22 (20 – 24.25)
Ethnicity	
African, n (%)	8 (100%)
Primiparous, n (%)	1 (12.5%)
Previous obstetric complications	
History of FDIU/IUGR/PE	3 (37.5%)
History of cesarian section	3 (37.5%)
Sickle cell genotype	
SS, n (%)	4 (50%)
SC, n (%)	2 (25%)
Sbeta, n (%)	2 (25%)
History of VOC/ACS, n (%)	7 (87.5%)
Long term SCD therapy, n (%)	4 (50%)
Chronic respiratory disease, n (%)	3 (37.5%)
Smoking, n (%)	0 (0%)
Other therapies*	
Acetylsalicylic acid	2 (25%)
Hydroxychloroquine	1 (12.5%)
EADs	1 (12.5%)
ICS	1 (12.5%)
Gestational age on infection, median (IQR)	26.5 (20.25 – 35)
Treatment during Covid19 infection	
Enoxaparin	4 (50%)
Antibiotics†	1 (12.5%)

ACS – acute chest syndrome.

EADs – anti-epileptic drugs.

FDIU – fetal death in utero.

ICS – inhaled corticosteroids.

IUGR – intrauterine growth restriction.

PE – preeclampsia.

SCD – sickle cell disease.

VOC – vaso-occlusive crisis.

* Onset of these therapies was previous to current pregnancy or no later than 8 weeks of pregnancy.

† Only antibiotics prescribed as active, full-length therapy are taken in consideration.

one/salmeterol due to asthma. One patient (patient #7) used daily hydroxychloroquine (200 mg twice a day, orally) because of a history of repeated spontaneous miscarriages and fetal death at 5 months of gestation.

The four hospitalized patients (50%) were administered low-molecular-weight heparin (LMWH) (enoxaparin sodium) at a prophylactic dose. Two out of four patients presenting with fever received preventive antibiotic treatment for presumptive exposure to *Listeria* (amoxicillin) until the reception of COVID-19 PCR result. Overall, only one of the infected patients (#8) received active, full-course antibiotic treatment by cefotaxime and spiramycin for the treatment of concomitant ACS. One patient received influenza antiviral medication by oseltamivir which was interrupted on day 3 after admission when a negative nasal swab result was obtained.

Short term course of COVID-19

Common clinical symptoms were reported by seven of the eight patients (88%) and included fever, cough, rhinitis, and headache (Table 2). One patient had no symptoms but had a positive PCR test result from a routine nasal swab after admission for ongoing VOC and suspicion of ACS.

The symptoms persisted for a median of 5.5 days (3.0 – 12.5) and all the patients but one (patient #8) were followed up as outpatients or rapidly discharged from hospital (median hospital stay 4.5 days (3.5–7.25)). On admission of patient #8 COVID-19 symptoms were mild, but dyspnea and PE occurred over the following days. She was admitted to the ICU and high flow oxygen therapy was administered for 4 days. A CT scan of the chest showed an

Table 2
Severity and outcome of the COVID 19 infection.

COVID-19 outcomes	SCD + (n = 8)
Days with persistent symptomatology, median (IQR)	5.5 (3 – 12.5)
Fever	4 (50%)
Cough	3 (37.5%)
Anosmia/ageusia	2 (25%)
Rhinitis	5 (62.5%)
Headache	3 (37.5%)
Hospitalization, n (%)	4 (50%)
Days of hospitalization, median (IQR)	4.5 (3.5 – 7.25)
Pulmonary affection, n (%)	1 (12.5%)
VOC/ACS complications during COVID infection, n (%)	1 (12.5%)
Requirement of supplemental O ₂ , n (%)	1 (12.5%)
Admission to ICU, n (%)	1 (12.5%)

ACS – acute chest syndrome.

ICU – intensive care unit.

SCD – sickle cell disease.

VOC – vaso-occlusive crisis.

Table 3
Obstetric complications and neonatal status.

Pregnancy outcomes	SCD + (n = 8)
Gestational age at birth, median (IQR)	38 (36 – 38)
Obstetric complications after remission	
Pre-eclampsia	1 (12.5%)
Preterm birth	2 (25%)
VOC	2 (25%)
Childbirth delivery methods (n = 7)	
Labor induction, n (%)	5 (71%)
Cesarean section, n (%)	1 (14%)
Fetal weight at birth (g), median (IQR)	2770 (2455 – 3545)
Fetal weight at birth (percentile), median (IQR)	56 (18 – 69)
Apgar, median (IQR)	10
pH, mean (SD)	7.31 (0.05)

SCD – sickle cell disease.

VOC – vaso-occlusive crisis.

aspect suggesting ACS lesions, but COVID-19 related involvement could not be excluded.

None of the patients required a supplementary transfusion related to COVID-19. From the biological point of view the mean hemoglobin level at the moment of COVID-19 was 9.0 ± 1.0 g/dl compared to 9.4 ± 1.0 g/dl 1 month before COVID-19 infection ($p = 0.5$).

Obstetrical course after COVID-19 remission

The median gestational age at childbirth was 38 WG (37–38) (Table 3). Two patients (25%) had preterm labor at 35 WG: patient #2 had labor induction for previously diagnosed IUGR associated with labiopalatoschisis, and patient #8 had a cesarean section at 35 WG because of incidental PE after ICU admission. Patient #8 was discharged without requirement of supplemental oxygen on postpartum day 14 and fetal outcome was favorable despite the preterm birth.

Labor induction for VOC was indicated in patient #1.

At the end of the study, one patient had not yet delivered, one patient (14%) had spontaneous onset of the labor, one patient had a cesarian section (patient #8) and five patients had labor induction (71%) due to cholestasis of pregnancy ($n = 2$), previously diagnosed IUGR ($n = 1$), isolated proteinuria ($n = 1$), and VOC ($n = 1$).

Fetal outcomes were mostly favorable with an average Apgar score of 10/10 5 min after birth and normal umbilical cord arterial blood pH (mean 7.31 ± 0.05). The median birth weight was 2770 g (2455 – 3545) which corresponded to 56th percentile (18 – 69). Birth weight was normal except for two newborns (25%), previously diagnosed with IUGR.

Discussion

During the study period, eight pregnant women with SCD were diagnosed with COVID-19. Both maternal and fetal outcomes were favorable despite high-risk pregnancy status and maternal comorbidities. Complications of SCD after COVID-19 were observed in one case admitted to ICU.

Pregnant women are especially susceptible to severe manifestations of viral infections including pneumonias because of immunologic alterations and physiological adaptive changes during pregnancy [16]. In contrast, in our population pregnancy and SCD were not a risk factor of the severe form of COVID-19. The hypothesis that a chronic inflammatory background and the hemolytic and anemic state in SCD patients might have a protective impact on COVID-19 progression has already been reported [14,17]. On the other hand, the exchange transfusion could have also played a protective role, as it was performed in 38% of women.

The clinical characteristics of COVID-19 in our cohort were similar to those reported by Zaigham and Andersson for pregnant patients without SCD. In a cohort of 108 patients, most of the mothers (97%) were discharged without any major complications. However they also reported cases of severe maternal morbidity with ICU admission as a result of COVID-19 [18].

Previous studies have suggested that COVID-19 is more likely to progress into a severe and critical stage in the presence of risk factors such as older age, male gender, or underlying comorbidities such as hypertension, diabetes, obesity, or pregnancy [19]. In our cohort the only constant risk factors were pregnancy and SCD comorbidities.

One patient in our study, patient #8 with HbSS genotype, was hospitalized due to VOC associated with ACS. However, in this patient a history of PE and VOC during a previous pregnancy already constituted a risk factor in itself [20,21]. She had already been hospitalized twice for VOC at 24 and 32 WG of the current pregnancy. A CT scan performed during the ICU stay showed images of bilateral ground-glass opacities associated with pulmonary condensation in the inferior lobes. Reports were inconclusive about the exact etiology of these abnormalities although SARS-CoV-2 implication could not be excluded. Hence, it is difficult to establish a causality but a hypothesis of the trigger effect of COVID-19 seems plausible as infections participate in the pathogenesis of VOC [22].

In contrast with the literature data [14], none of the two women with HbSC genotype presented with severe symptoms.

The association between VOC and COVID-19 in patient #1 is debatable. The VOC occurred 10 days after the last symptom of COVID-19 in this patient and 20 days after a positive PCR nasal swab. In some cases, SARS-CoV-2 can be detected in follow-up nasal swabs for a longer period of time [23]. However, no control PCR was performed in this case.

Another severe complication of COVID-19 is blood clotting abnormalities leading to deep vein thrombosis, PE, and stroke [24] which is why we administered LMWH as preventative treatment to all of our hospitalized patients. However, to date there is insufficient evidence to determine the risks and benefits of prophylactic anticoagulants for patients hospitalized for COVID-19 [25] and this subject has not yet been studied in the SCD population.

Daily low-dose aspirin for the prevention of an embolic event was prescribed for two of our patients. However, the results of a recent meta-analysis suggest no association between the use of aspirin and mortality in patients with COVID-19 [26] which was confirmed by a randomized controlled trial [27].

Hydroxychloroquine, prescribed in patient #7 as a treatment of repeated spontaneous miscarriages, is no longer considered to be an effective COVID-19 treatment [28].

Finally, some authors recommend that pregnant women with COVID-19 be monitored for fetal growth restriction [29]. In this article, IUGR was related to the patient's history or had differential diagnosis confirmed by additional explorations.

The limitations of our study include a small sample size and its retrospective design. Another limitation is the heterogeneous study period. At the beginning of the pandemic, pregnant women with SCD without any severity criteria were systematically admitted to hospital. As we gained more knowledge about the course of COVID-19, outpatient treatment was preferred. This tendency could have influenced the analysis by overestimating the real need and length of hospitalization. Finally, confounding factors were numerous such as medical history and ongoing treatments.

In conclusion, in our study pregnant women with SCD mainly presented a mild form of COVID-19, independently of the genotype of SCD. COVID-19 impact on pregnancy outcomes was moderate and its course did not seem to differ from that reported in SCD-free patients. Further studies are needed to confirm these results. Comparison of the course of COVID-19 infection in this complex population of patients with that in a general population could contribute to a better understanding of the physiopathology of both diseases. Despite those reassuring data, the anti-COVID vaccination in this population of pregnant women seems crucial.

Declaration of Competing Interest

This research did not receive any specific grant from funding agencies in the public, commercial, or not-for-profit sectors.

CRediT authorship contribution statement

Kamila Kolanska: Conceptualization, Visualization, Funding acquisition, Formal analysis, Methodology, Writing – original draft, Writing – review & editing. **Radostina Vasileva:** Funding acquisition, Formal analysis, Methodology, Writing – original draft, Writing – review & editing. **François Lionnet:** Funding acquisition, Formal analysis, Methodology, Writing – original draft, Writing – review & editing. **Aline Santin:** Funding acquisition, Writing – original draft, Writing – review & editing. **Suha Jaudi:** Funding acquisition, Writing – original draft, Writing – review & editing. **Yohann Dabi:** Funding acquisition, Formal analysis, Methodology, Writing – original draft, Writing – review & editing. **Nathalie Chabbert-Buffer:** Conceptualization, Visualization, Writing – original draft, Writing – review & editing. **Emile Daraï:** Conceptualization, Visualization, Formal analysis, Methodology, Writing – original draft, Writing – review & editing. **Marie Bornes:** Conceptualization, Visualization, Formal analysis, Methodology, Writing – original draft, Writing – review & editing.

Acknowledgements

We would like to thank Felicity Neilson for editing the English of our paper.

Appendix

Table A1

References

- [1] Jain D, Atmapoojya P, Colah R, Lodha P. Sickle cell disease and pregnancy. *Mediterr J Hematol Infect Dis* 2019;11(1). [Internet] Jul 1 [cited 2021 Feb 16] Available from: <https://www.ncbi.nlm.nih.gov/pmc/articles/PMC6613624/>.
- [2] Oteng-Ntim E, Meeks D, Seed PT, Webster L, Howard J, Doyle P, et al. Adverse maternal and perinatal outcomes in pregnant women with sickle cell disease: systematic review and meta-analysis. *Blood* 2015;125(21):3316–25 May 21.
- [3] Johnston EE, Adesina OO, Alvarez E, Amato H, Paulukonis S, Nichols A, et al. Acute care utilization at end of life in sickle cell disease: highlighting the need for a palliative approach. *J Palliat Med* 2020;23(1):24–32 Jan.

Table A1
Overview of the 8 cases demographics, history of the illness and their respective pregnancy outcome.

Other comorbidities/ treatments*	GA at infection	Treatment during Covid19	Days with persistent symptoms
Chronic dyspnea	35	0	14 (rhinitis, sore throat, fever)
Cerebral vasculopathy (aspirin); minor alpha thalassemia; Epilepsy (FLNA gene) (EADs); Asthma (ICS); Splenectomy and cholecystectomy	22	0	3 (cough, rhinitis, muscle pain, anorexia)
No	26	LMWH† Osetlamivir‡ Amoxicillin‡	22 (fever, cough, rhinitis)
No	27	LMWH† Amoxicillin‡	4 (fever, muscle pain, headache)
Restrictive lung disease	36	LMWH†	0 (asymptomatic)
SCD retinopathy, ocular toxoplasmosis, Aspirin (history of IUGR)	15	0	3 (fever, fatigue, headache, sore throat)
Hepatitis B, Hydroxychloroquine (obstetrical history)	8	0	7 (rhinitis, headache, muscle pain, anorexia)
factor XI deficiency	35	LMWH† Cefotaxime Spiramycin	12 (cough, rhinitis initially, dyspnea)

FHRA = fetal heart rate abnormalities, IUGR = intrauterine growth restriction, FDIU = fetal death in utero, PE = preeclampsia; VOC = vaso-occlusive crisis, ACS = acute chest syndrome, EADs = anti-epileptic drugs; ICS = inhaled corticosteroids; LMWH = low-molecular weight heparin; ICU = intensive care unit; * clinical assessment and laboratory investigations did not find underlying pathological cause; † Onset of these therapies was previous to current pregnancy or no later than 8 weeks of pregnancy; ‡ LMWH was prescribed at prophylaxis dose for all patient admitted to hospital; † Antibiotics were initially prescribed to treat Listeriosis and stopped as soon as the etiology of the fever was found as guidelines suggest; antiviral were prescribed until influenza nasal swabs results came negative. ‡ Genetic analysis showed FLNA gene mutation probably explaining the IUGR and the orofacial in fetus clefts which was found on ultrasound exam as well as the mother's epilepsy.

[4] Rees DC, Olujohungbe AD, Parker NE, Stephens AD, Telfer P, Wright J, et al. Guidelines for the management of the acute painful crisis in sickle cell disease. *Br J Haematol* 2003;120(5):744–52 Mar.

[5] Chen C, Grewal J, Betran AP, Vogel JP, Souza JP, Zhang J. Severe anemia, sickle cell disease, and thalassemia as risk factors for hypertensive disorders in pregnancy in developing countries. *Pregnancy Hypertens* 2018;13:141–7 Jul.

[6] Koshy M, Burd L. Management of pregnancy in sickle cell syndromes. *Hematol Oncol Clin North Am* 1991;5(3):585–96 Jun.

[7] Villers MS, Jamison MG, De Castro LM, James AH. Morbidity associated with sickle cell disease in pregnancy. *Am J Obstet Gynecol* 2008;199(2):125.e1–125.e5 Aug.

[8] Overton EE, Goffman D, Friedman AM. The epidemiology of COVID-19 in pregnancy. *Clin Obstet Gynecol* 2022;65(1):110–22 Mar 1.

[9] Wilkinson M, Johnstone ED, Simcox LE, Myers JE. The impact of COVID-19 on pregnancy outcomes in a diverse cohort in England. *Sci Rep* 2022;12(1):942 Jan 18.

[10] AbdulRahman A, AlAli S, Yaghi O, Shabaan M, Otoom S, Atkin SL, et al. COVID-19 and sickle cell disease in Bahrain. *Int J Infect Dis* 2020;101:14–16 Dec.

[11] Heilbronner C, Berteloot L, Tremolieres P, Dupic L, de Saint Blanquat L, Lesage F, et al. Patients with sickle cell disease and suspected COVID-19 in a paediatric intensive care unit. *Br J Haematol* 2020;190(1):e21–4 Jul.

[12] Appiah-Kubi A, Acharya S, Fein Levy C, Vlachos A, Ostover G, Murphy K, et al. Varying presentations and favourable outcomes of COVID-19 infection in children and young adults with sickle cell disease: an additional case series with comparisons to published cases. *Br J Haematol* 2020. [Internet] Aug 1 [cited 2021 Feb 17]; Available from: <https://www.ncbi.nlm.nih.gov/pmc/articles/PMC7405127/>.

[13] Balanchivadze N, Kudirka AA, Askar S, Almadhoun K, Kuriakose P, Fadel R, et al. Impact of COVID-19 infection on 24 patients with sickle cell disease. *One Center Urban Exp*. 2020;44(4):284–9 Detroit, MI, USA. *Hemoglobin* Jul.

[14] Arlet JB, de Luna G, Khimoud D, Odièvre MH, de Montalembert M, Joseph L, et al. Prognosis of patients with sickle cell disease and COVID-19: a French experience. *Lancet Haematol* 2020;7(9):e632–4 Sep.

[15] Justino CC, Campanharo FF, Augusto MN, de Morais SC, Figueiredo MS. COVID-19 as a trigger of acute chest syndrome in a pregnant woman with sickle cell anemia. *Hematol Transfus Cell Ther* 2020;42(3):212–14.

[16] Kourtis AP, Read JS, Jamieson DJ. Pregnancy and Infection. *N Engl J Med* 2014;370(23):2211–18 Jun 5.

[17] Hussain FA, Njoku FU, Saraf SL, Molokie RE, Gordeuk VR, Han J. COVID-19 infection in patients with sickle cell disease. *Br J Haematol* 2020;189(5):851–2 Jun.

[18] Zaigham M, Andersson O. Maternal and perinatal outcomes with COVID-19: a systematic review of 108 pregnancies. *Acta Obstet Gynecol Scand* 2020;99(7):823–9 Jun.

[19] Gao Y, Ding M, Dong X, Zhang J, Azkur AK, Azkur D, et al. Risk factors for severe and critically ill COVID-19 patients: a review. *Allergy* 2021;76(2):428–55.

[20] WHO WHO recommendations for prevention and treatment of pre-eclampsia and eclampsia. WHO World Health Organization; 2011. [Internet] [cited 2021 Mar 15]. Available from: http://www.who.int/reproductivehealth/publications/maternal_perinatal_health/9789241548335/en/.

[21] Chou ST, Alsawas M, Fasan RM, Field JJ, Hendrickson JE, Howard J, et al. American society of hematology 2020 guidelines for sickle cell disease: transfusion support. *Blood Adv*. 2020;4(2):327–55 Jan 27.

[22] Ahmed SG. The role of infection in the pathogenesis of vaso-occlusive crisis in patients with sickle cell disease. *Mediterr J Hematol Infect Dis* 2011;3(1). [Internet] Jul 8 [cited 2021 Mar 16] Available from: <https://www.ncbi.nlm.nih.gov/pmc/articles/PMC3152450/>.

[23] Deng W, Guang TW, Yang M, Li JR, Jiang DP, Li CY, et al. Positive results for patients with COVID-19 discharged from hospital in Chongqing, China. *BMC Infect Dis* 2020;20(1):429 Jun 19.

[24] Giannis D, Ziogas IA, Gianni P. Coagulation disorders in coronavirus infected patients: COVID-19, SARS-CoV-1, MERS-CoV and lessons from the past. *J. Clin. Virol*. 2020;127:104362 Jun 1.

[25] Flumignan RL, Tinôco JD, de S, Pascoal PI, Areias LL, Cossi MS, Fernandes MI, et al. Prophylactic anticoagulants for people hospitalised with COVID-19. *Cochrane Database Syst. Rev*. 2020(10). [Internet] [cited 2021 Mar 15]. Available from: <https://www.cochranelibrary.com/cdsr/doi/10.1002/14651858.CD013739/full>.

[26] Salah HM, Mehta JL. Meta-analysis of the effect of aspirin on mortality in COVID-19. *Am J Cardiol* 2021;142:158–9 Mar 1.

[27] RECOVERY Collaborative Group Aspirin in patients admitted to hospital with COVID-19 (RECOVERY): a randomised, controlled, open-label, platform trial. *Lancet* 2022;399(10320):143–51 Jan 8.

[28] Singh B, Ryan H, Kredon T, Chaplin M, Fletcher T. Chloroquine or hydroxychloroquine for prevention and treatment of COVID-19. *Cochrane Database Syst. Rev*. 2021. [Internet] [cited 2021 Mar 15];(2). Available from: <https://www.cochranelibrary.com/cdsr/doi/10.1002/14651858.CD013587.pub2/full>.

[29] Wang CL, Liu YY, Wu CH, Wang CY, Wang CH, Long CY. Impact of COVID-19 on pregnancy. *Int J Med Sci* 2021;18(3):763–7.