



# Pseudomembranous laryngotracheobronchitis due to coinfection with human bocavirus 1 and *Mycoplasma pneumoniae*: a case report

Shun-Hang Wen<sup>#</sup>, Li Lin<sup>#</sup>, Gang Yu, Chang-Fu Xu, Hai-Lin Zhang, Yang-Ming Zheng

Department of Children's Respiratory Disease, The Second Affiliated Hospital and Yuying Children's Hospital, Wenzhou Medical University, Wenzhou, China

<sup>#</sup>These authors contributed equally to this work.

Correspondence to: Hai-Lin Zhang, Yang-Ming Zheng. Department of Children's Respiratory Disease, The Second Affiliated Hospital and Yuying Children's Hospital, Wenzhou Medical University, 109 West Xueyuan Road, Lucheng District, Wenzhou 325027, China.

Email: zhlwz97@hotmail.com; zym002@126.com.

**Abstract:** Pseudomembranous laryngotracheobronchitis is rarely reported yet potentially life-threatening infectious cause of airway obstruction in children. The causative organisms of this condition are often considered to promote bacterial superinfection following viral infection. We report a case of pseudomembranous laryngotracheobronchitis in a patient caused by human bocavirus 1 and *Mycoplasma pneumoniae* (*M. pneumoniae*). A 2-year-old child was admitted to our hospital presenting with cough, hoarseness, and labored breathing. Computed tomography of the chest revealed atelectasis of the right middle lobe of the lung with bronchostenosis and occlusion. Laryngeal edema, pseudomembrane formation and ulceration of the trachea were found during bronchoscopy. Chronic inflammation of the mucosa and local cellulose exudation with acute and chronic inflammatory cell infiltration were confirmed by hematoxylin-eosin staining. Human bocavirus 1 and *M. pneumoniae* were detected in the bronchoalveolar lavage fluid by next-generation sequencing. The patient tested positive for IgM antibodies against *M. pneumoniae*. Bronchoscopy was performed three times to clear the secretions in the airway, and azithromycin, ceftriaxone, methylprednisolone, budesonide inhalation, and ambroxol were administered as treatment. The patient's condition improved and she was discharged 21 days after admission. Clinicians should be aware of the potential involvement of human bocavirus 1 and *M. pneumoniae* in pseudomembranous laryngotracheobronchitis for accurate diagnosis and timely antibiotic administration, and to lower mortality and morbidity rates.

**Keywords:** Case report; *Mycoplasma pneumoniae* (*M. pneumoniae*); human bocavirus; next-generation sequencing; pseudomembranous laryngotracheobronchitis

Submitted Sep 04, 2020. Accepted for publication Nov 18, 2020.

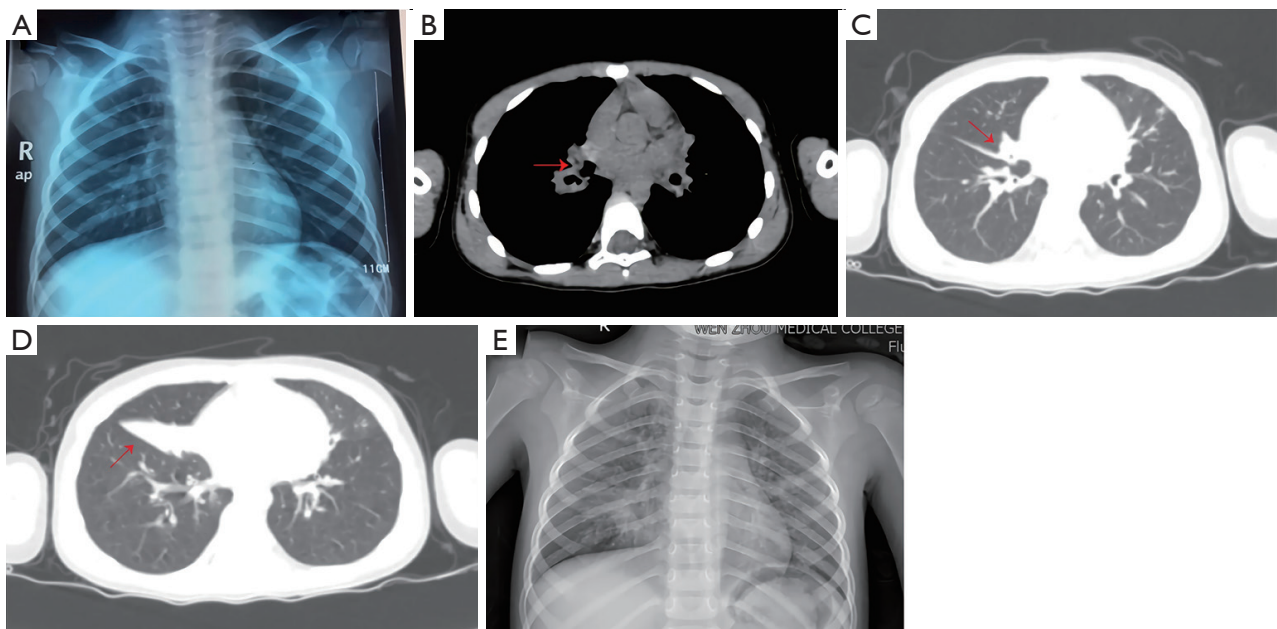
doi: 10.21037/tp-20-278

View this article at: <http://dx.doi.org/10.21037/tp-20-278>

## Introduction

Pseudomembranous laryngotracheobronchitis is an uncommon, although potentially life-threatening, infectious cause of airway obstruction in children (1). It is also known as membranous laryngotracheobronchitis, bacterial laryngotracheobronchitis, or pseudomembranous croup. It is characterized by the formation of tracheal ulcers and

pseudomembrane, and mucopurulent exudate, as well as mucosal detachment. The affected child commonly presents with a prodrome of viral upper respiratory tract infection followed by a rapid onset of high temperatures, stridor, hoarseness, respiratory distress, and a toxic appearance. However, several recent case series reported that some children present with less severe forms of



**Figure 1** Chest radiograph and computed tomography. (A) No obvious abnormalities on chest radiograph at the local hospital. (B) The initial segment of the bronchus of the middle lobe of the right lung is almost completely obstructed with an endobronchial low-density shadow. (C) Obvious stenosis of the bronchus in the middle lobe of the right lung. (D) Obstruction of the middle lobe bronchus of the right lung leading to atelectasis of the middle lobe of the right lung. (E) Shadow in the lower right lung field obscuring the right heart border.

pseudomembranous laryngotracheobronchitis, highlighting that some cases may involve an atypical presentation and a variable clinical course (2,3). In children, the diagnosis of pseudomembranous laryngotracheobronchitis is based on clinical, microbiologic, and endoscopic findings—flexible bronchoscopy, if tolerated, is considered the gold standard.

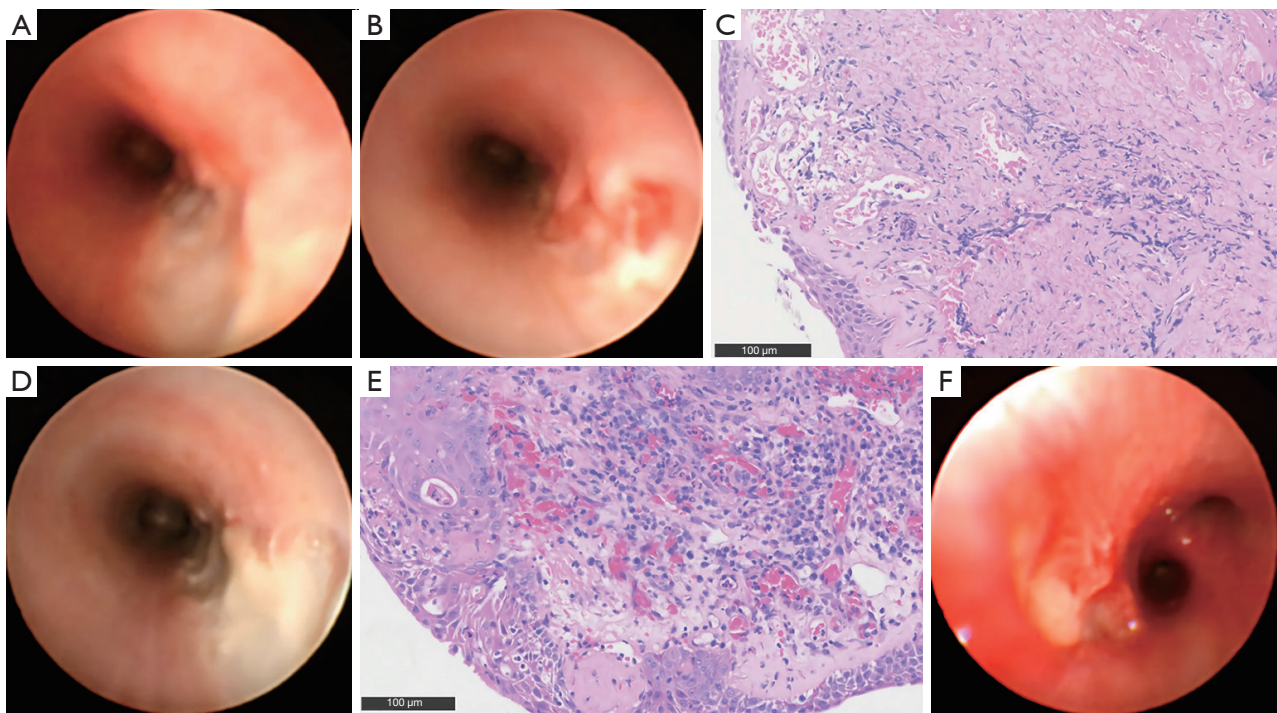
Respiratory viruses and bacterial superinfections are implicated in pseudomembranous laryngotracheobronchitis in children. Methicillin-sensitive *Staphylococcus aureus* was the most common bacterial isolate detected in the bacterial culture of respiratory specimens according to a structured review (2). *Haemophilus influenzae*, *Streptococcus pneumoniae*, and *Moraxella catarrhalis* are also commonly identified. Bacterial superinfection most often occurs in viral tracheobronchitis caused by influenza, parainfluenza, or respiratory syncytial virus, which may be detected by molecular and antigen-based approaches. Metagenomic next-generation sequencing (mNGS) is reported as a promising technology for identifying the causative agent in a given respiratory tract sample (4). mNGS has mainly been employed in the diagnosis of emerging pathogens and rare infectious diseases. To the best of our knowledge, this is the first report describing a child who was diagnosed with pseudomembranous laryngotracheobronchitis

caused by human bocavirus 1 and *Mycoplasma pneumoniae* (*M. pneumoniae*), identified using mNGS.

We present the following case in accordance with the CARE reporting checklist (available at <http://dx.doi.org/10.21037/tp-20-278>).

### Case presentation

A 2-year-old female patient was admitted to the emergency department of our hospital on May 23, 2019, presenting with cough, hoarseness, and dyspnea lasting for 10 days. The patient was previously healthy with an uneventful medical history and family history. There was no contact, or cluster history. Fever occurred at the beginning of symptom presentation. The highest hypersensitive C-reactive protein level was 48.71 mg/L. Peripheral blood cell counts were within the normal range, and due to technical limitations, no etiological examination was performed. Chest radiography indicated no obvious abnormality (Figure 1). Ceftriaxone, methylprednisolone, and budesonide inhalation were administered at a local hospital from May 17 to May 22, 2019; however, her cough, hoarseness, and dyspnea did not significantly improve. She was admitted to our hospital after



**Figure 2** Bronchoscopy and hematoxylin-eosin staining of the pseudomembrane. (A) Pseudomembrane in the trachea on day 4 post admission. (B) Ulcer in the right main bronchus on day 4 post admission. (C) Day 4 post admission: chronic inflammation of the mucous membrane and local cellulose exudation with infiltration of acute and chronic inflammatory cells, with the focal area covered with squamous epithelium. Extensive necrotic tissue with neutrophil infiltration and bacterial overgrowth can be seen. (D) Pseudomembrane in the trachea on day 11 post admission. (E) Day 11 post admission: chronic inflammation of the mucous membrane, hyperplasia of granulation tissue under the squamous epithelium with hyperemia, hemorrhage, and infiltration of inflammatory cells, with cellulose exudate on the surface. (F) The pseudomembrane in the trachea is significantly reduced on day 18 post admission.

her parents consented for discharge.

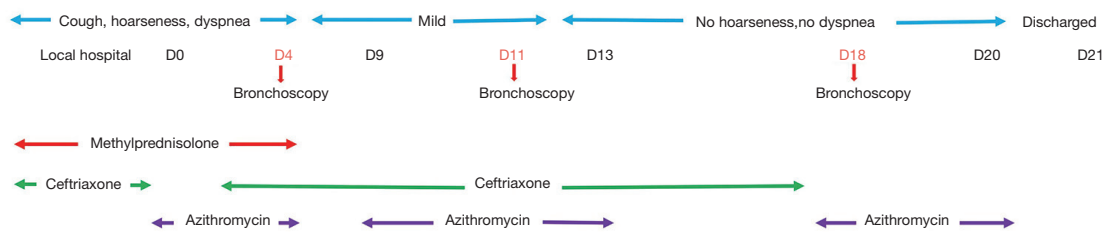
Upon admission, the patient was stable with a fever of 38.2 °C, a blood pressure of 95/65 mmHg, and a heart rate of 145 beats per minute. Her respiratory rate was 42 per minute and increasing. On physical examination, depression of the suprasternal and supraclavicular fossa, and mildly enlarged tonsils were observed. No obvious dry or wet rales were heard in the lungs. Examination of the cardiovascular, abdominal, and nervous systems was unremarkable.

Laboratory investigations upon admission showed an increased white blood cell count of  $19.06 \times 10^9$  cells/L (normal reference range,  $4.0\text{--}12.0 \times 10^9$  cells/L) with 56.4% neutrophils, and hypersensitive C-reactive protein level of 13.85 mg/L (normal reference range, <8 mg/L). Computed tomography (CT) showed that the initial segment of the bronchus of the middle lobe of the right lung was almost completely obstructed with an endobronchial low-density shadow accompanied by atelectasis (Figure 1B,C,D).

Presumptive diagnoses of acute laryngitis, degree II laryngeal obstruction, pneumonia, and foreign body presence in the respiratory tract were considered in the emergency department. The patient was treated with azithromycin, methylprednisolone, budesonide inhalation, and oxygen inhalation.

As the patient was considered to be in a stable condition, she was referred to the children's respiratory ward. Investigations revealed a normal procalcitonin level of 0.063 ng/mL. Sputum tested negative for adenovirus, respiratory syncytial virus, influenza A and B virus, parainfluenza virus 1, 2, and 3 using immunofluorescence. Additionally, the sputum bacterial culture was negative. The patient tested positive for IgM antibodies against *M. pneumoniae*. Azithromycin, methylprednisolone, budesonide inhalation, and ambroxol were continued for three days. The patient's hoarseness and shortness of breath improved slightly during this time.





**Figure 3** Timeline of the case, including clinical presentations, tests, and treatments.

On day 4 post admission, flexible bronchoscopy revealed laryngeal edema, tracheal pseudomembrane formation, ulceration in the right main bronchus, and pyogenic changes of the trachea, mainly in the right middle lobe of the lung. Pathology revealed chronic inflammation of the mucous membrane, local cellulose exudation with extensive infiltration of acute and chronic inflammatory cells, and the focal area covered with squamous epithelium (Figure 2A,B,C); A monistic perspective regarding hoarseness, laryngeal edema, tracheal pseudomembrane formation, and ulceration in the right main bronchus, lead to modification of the diagnosis to pseudomembranous bronchitis. *M. pneumoniae* DNA was detected in the bronchoalveolar lavage fluid (BALF). We reviewed the relevant literatures regarding the management of pseudomembranous bronchitis and considered the possibility of a combined viral and bacterial infection. Ceftriaxone was administered as anti-infective treatment, and azithromycin and methylprednisolone administration were ceased after five days. Pathogen analysis of the BALF was performed by mNGS, and the data were compared with pathogen sequences deposited in the four microbial genome databases, which included 3,446 species of bacteria, 206 species of fungi, 1,515 species of viruses, and 140 species of parasites. The number of sequences of *M. pneumoniae* and bocavirus 1 were 1,357 and 56, respectively. Three courses of azithromycin were administered for anti-infection. To clear the secretion in the airway, a bronchoscope was reemployed again 11 days after admission (Figure 2D,E). Chest radiography showed resorption in the lung with a patchy shadow (Figure 1E). On day 18 post admission, bronchoscopy was performed for the third time, and the tracheal pseudomembrane was visibly reduced (Figure 2F). The child was discharged from the hospital with an occasional cough and no hoarseness or labored breathing on day 21 post admission. The timeline of this case is shown in Figure 3. The child was well without abnormal respiratory signs at the 6-month follow-up.

All procedures performed in studies involving human participants were in accordance with the ethical standards of

the Ethics Committee of The Second Affiliated Hospital and Yuying Children's Hospital of Wenzhou Medical University and with the Helsinki Declaration (as revised in 2013). Written informed consent was obtained from the child's parents.

## Discussion

Pseudomembranous laryngotracheobronchitis is an acute and critical pediatric condition that may cause severe airway obstruction (5). The clinical manifestations of pseudomembranous laryngotracheobronchitis are diverse. In our case, the main presenting symptoms included cough, hoarseness, and dyspnea; there were no precursor symptoms indicating a viral infection of the upper respiratory tract. Stridor or diminished breath sounds are important physical findings for localizing a laryngeal or tracheal lesion. Other potential diagnoses include acute laryngitis, viral laryngotracheobronchitis, epiglottitis, pneumonia, plastic bronchitis, bronchiolitis, and diphtheria. Thus, in patients with an irreversible lack of response to glucocorticoid and/or adrenaline treatment for respiratory failure, the possibility of pseudomembranous laryngotracheobronchitis should be considered as a differential diagnosis (6,7). Investigative imaging is often helpful in distinguishing pseudomembranous laryngotracheobronchitis. A typical X-ray shows irregular borders of the trachea and blurring of the tracheal column, indicating pseudomembranous detachment. Atelectasis of the middle lobe of the right lung with bronchostenosis and occlusion, in combination with a low-density shadow on chest CT as seen in this case, may indicate pseudomembrane detachment and obstruction. Bronchoscopy, the gold standard for the diagnosis of pseudomembranous laryngotracheobronchitis, reveals the formation of tracheal ulcers and pseudomembrane, and mucopurulent exudate, as well as mucosal detachment (1,2). For patients with a stable airway, the clinician should perform laryngoscopy or bronchoscopy in time. A laryngoscope can be used to observe whether there is mucopurulent secretion in the glottic area

or under the glottis. In our case, bronchoscopy was used to observe the formation, detachment, and ulceration of the pseudomembrane in the trachea and bronchus.

Gram staining, bacterial cultures, viral nucleic acid detection, and viral cultures are helpful in identifying pathogens and guiding drug treatment. The main bacterial species involved in pseudomembranous laryngotracheobronchitis include *S. aureus*, *H. influenzae*,  $\alpha$ -hemolytic *Streptococcus*, and *Streptococcus pyogenes* (1,3). Experts generally consider pseudomembranous laryngotracheobronchitis to be a combination of viral and bacterial infections, with the most common viruses including influenza, parainfluenza, respiratory syncytial, and human metapneumovirus (2,8,9). Aspergillus infection is a common cause of pseudomembranous laryngotracheobronchitis in adults (10); however, it has not been reported in children. In the present case, *M. pneumoniae* and human bocavirus 1 were detected by mNGS. *M. pneumoniae* is an important causative agent of pharyngitis, tracheobronchitis, and pneumonia in children. As far as I know, this is the first case of a coinfection of *M. pneumoniae* and bocavirus inducing pseudomembranous laryngotracheobronchitis. Histopathology of the specimens collected from our patient revealed chronic inflammation of the mucous membrane, local cellulose exudation with infiltration of inflammatory cells, and extensive necrotic tissue. The interaction of *M. pneumoniae* with the host respiratory epithelial cells leads to cytokine production and lymphocyte activation—these changes exert cytopathic effects on the respiratory epithelium, characterized by the loss of cilia, vacuolation, exfoliation, and the production of pneumonic infiltrates (11). The evidence of an association between human bocavirus and respiratory tract disease has been well-established (12). Therefore, it is worth noting that human bocavirus seriously damages pseudostratified airway cell cultures by exerting cytopathic effects, which destroy tissue integrity (13). Importantly, this study has differentiated an acute infection from prolonged shedding by detection of human bocavirus RNA. The patient may have been initially infected with human bocavirus and subsequently coinfecting with *M. pneumoniae* after airway damage. Hence, *M. pneumoniae* should be considered as a causative pathogen in patients with pseudomembranous laryngotracheobronchitis.

The main priority when managing children with severe respiratory distress and airway damage is to ensure airway safety (14). The survival rate ultimately depends on the extent of necrotic mucosa in the distal small airway, and whether the necrotic tissue in the airway can be removed. Removal of the pseudomembrane, mucopurulent

exudate, and mucosal detachment using bronchoscopy and bronchoalveolar lavage is the most crucial part of this task. Endotracheal intubation may be necessary to secure an unstable, compromised airway. For children with pseudomembranous laryngotracheobronchitis, broad-spectrum antibiotics should be administered. Empiric antibiotics relevant to their treatment include third-generation cephalosporins (ceftriaxone or cefotaxime) or intravenous vancomycin, adjusted according to the culture results. Therefore, in the present case, even after the diagnosis of pseudomembranous laryngotracheobronchitis, the patient was empirically treated with ceftriaxone for anti-infection. *M. pneumoniae* is a causative agent of pseudomembranous laryngotracheobronchitis. Although there is insufficient evidence regarding the efficacy of antibiotics for *M. pneumoniae* in children, most experts suggest that macrolide antibiotics should be systematically administered in patients with *M. pneumoniae* lower respiratory tract infections (15). However, we have no experience in administering azithromycin for the treatment of pseudomembranous laryngotracheobronchitis. Considering the effect of the pseudomembrane (high exudate production) on the azithromycin tissue concentration, three courses of azithromycin treatment were administered. To date, there is no effective anti-bocavirus treatment. Intravenous immunoglobulins and glucocorticoids have been suggested for severe viral pneumonia. Moreover, N-acetylcysteine nebulization and biphasic cuirass ventilation have also been reported as potential therapeutic options (16). Extracorporeal membrane oxygenation aids patient recovery during critical periods of respiratory failure, and therefore, may be a solution before removal of the pseudomembrane in patients with pseudomembranous laryngotracheobronchitis.

Pseudomembranous laryngotracheobronchitis is rare in children and its clinical presentation may be atypical. In children with hoarseness and severe dyspnea of an unknown cause, refractory to glucocorticoid and adrenaline treatment, pseudomembranous laryngotracheobronchitis should be considered as a differential diagnosis. Bronchoscopy should be performed early to confirm the diagnosis of pseudomembranous laryngotracheobronchitis and to clear any airway obstructions. Although bacteria may be the main pathogen, a coinfection of *M. pneumoniae* and a virus should also be considered to provide effective treatment.

## Acknowledgments

We thank Qiang Xu (Department of Pathology, The Second

Affiliated Hospital and Yuying Children's Hospital, Wenzhou Medical University) for the clinical pathologic work.

**Funding:** The Special Project for Significant New Drug Research and Development in the Major National Science and Technology Projects of China (2020ZX09201002).

## Footnote

**Reporting Checklist:** The authors have completed the CARE reporting checklist. Available at <http://dx.doi.org/10.21037/tp-20-278>

**Peer Review File:** Available at <http://dx.doi.org/10.21037/tp-20-278>

**Conflicts of Interest:** All authors have completed the ICMJE uniform disclosure form (available at <http://dx.doi.org/10.21037/tp-20-278>). The authors have no conflicts of interest to declare.

**Ethical Statement:** The authors are accountable for all aspects of the work in ensuring that questions related to the accuracy or integrity of any part of the work are appropriately investigated and resolved. All procedures performed in studies involving human participants were in accordance with the ethical standards of the Ethics Committee of The Second Affiliated Hospital and Yuying Children's Hospital of Wenzhou Medical University and with the Helsinki Declaration (as revised in 2013). Written informed consent was obtained from the child's parents.

**Open Access Statement:** This is an Open Access article distributed in accordance with the Creative Commons Attribution-NonCommercial-NoDerivs 4.0 International License (CC BY-NC-ND 4.0), which permits the non-commercial replication and distribution of the article with the strict proviso that no changes or edits are made and the original work is properly cited (including links to both the formal publication through the relevant DOI and the license). See: <https://creativecommons.org/licenses/by-nc-nd/4.0/>.

## References

1. Kuo CY, Parikh SR. Bacterial tracheitis. *Pediatr Rev* 2014;35:497-9.
2. Casazza G, Graham ME, Nelson D, et al. Pediatric bacterial tracheitis-a variable entity: case series with literature review. *Otolaryngol Head Neck Surg* 2019;160:546-9.
3. Miranda AD, Valdez TA, Pereira KD. Bacterial tracheitis a varied entity. *Pediatr Emerg Care* 2011;27:950-3.
4. Gu W, Miller S, Chiu CY. Clinical Metagenomic Next-Generation Sequencing for Pathogen Detection. *Annu Rev Pathol* 2019;14:319-38.
5. Guerrero J, Mallur P, Folch E, et al. Necrotizing tracheitis secondary to corynebacterium species presenting with central airway obstruction. *Respir Care* 2014;59:e5-8.
6. Nickinson A, Minhas JS, Bhalla M, et al. Never trust a croup... *BMJ Case Rep* 2011;2011:bcr0320114014.
7. Eskander A, de Almeida JR, Irish JC. Acute Upper Airway Obstruction. *N Engl J Med* 2019;381:1940-9.
8. Park SS, Kim SH, Kim M, et al. A case of severe pseudomembranous tracheobronchitis complicated by co-infection of influenza A (H1N1) and Staphylococcus aureus in an immunocompetent patient. *Tuberc Respir Dis (Seoul)* 2015;78:366-70.
9. Tak R, Semmekrot B, Warris A, et al. Bacterial Tracheitis and Septic Shock. *Pediatr Infect Dis J* 2016;35:226-7.
10. Fernández-Ruiz M, Silva JT, San-Juan R, et al. Aspergillus Tracheobronchitis. *Medicine* 2012;91:261-73.
11. Waites KB, Xiao L, Liu Y, et al. Mycoplasma pneumoniae from the Respiratory Tract and Beyond. *Clin Microbiol Rev* 2017;30:747-809.
12. Schlager R, Ampofo K, Tardif KD, et al. Human Bocavirus Capsid Messenger RNA Detection in Children With Pneumonia. *J Infect Dis* 2017;216:688-96.
13. Huang Q, Deng X, Yan Z, et al. Establishment of a Reverse Genetics System for Studying Human Bocavirus in Human Airway Epithelia. *PLoS Pathog* 2012;8:e1002899.
14. Pflieger A, Eber E. Management of acute severe upper airway obstruction in children. *Paediatr Respir Rev* 2013;14:70-7.
15. Gardiner SJ, Gavranich JB, Chang AB. Antibiotics for community-acquired lower respiratory tract infections secondary to Mycoplasma pneumoniae in children. *Cochrane Database Syst Rev* 2015;1:CD004875.
16. Dolgner A, Bain J, Peterson-Carmichael SL, et al. Extracorporeal membrane oxygenation for refractory air leak in a child presenting with bacterial tracheitis. *Respir Care* 2014;59:e163-5.

**Cite this article as:** Wen SH, Lin L, Yu G, Xu CF, Zhang HL, Zheng YM. Pseudomembranous laryngotracheobronchitis due to coinfection with human bocavirus 1 and Mycoplasma pneumoniae: a case report. *Transl Pediatr* 2021;10(3):673-678. doi: 10.21037/tp-20-278