

The Incidence of Bifid C7 Spinous Processes

Woojin Cho¹ Takeshi Maeda² Yung Park³ Jacob M. Buchowski¹ Colin E. Nabb⁴ Dan Riew¹

¹ Department of Orthopedic Surgery, Washington University School of Medicine, St. Louis, Missouri, United States

² Department of Orthopedic Surgery, Spinal Injuries Center, Iizuka, Japan

³ Department of Orthopedic Surgery, Yonsei University School of Medicine, Seoul, Republic of Korea

⁴ School of Medicine, University of Pittsburgh, Pittsburgh, Pennsylvania, United States

Address for correspondence and reprint requests Woojin Cho, M.D., Ph.D., Department of Orthopedic Surgery, Washington University School of Medicine, 660 S. Euclid Avenue, Campus Box 8233, St. Louis, MO 63110, United States (e-mail: woojincho@aol.com).

Global Spine J 2012;2:99–104.

Abstract

For posterior cervical surgery, if the operation only involves the lower cervical area, counting from C2 is impractical and the level may not be visible on X-rays. In such cases, we usually place a marker at the top of the incision and also rely on the size and monofid shape of the C7 spinous process. Relying on the C7 morphology, however, we initially instrumented the wrong levels in a case where the patient had a bifid C7 spinous process. We therefore sought to determine the frequency of bifid cervicothoracic spinous processes. Computed tomography axial images of C6, C7, and T1 from 516 patients were evaluated. The spinous processes were classified into three categories: “bifid,” “partially bifid,” and “monofid.” C6 spinous process was monofid in 47.9% of cases, partially bifid in 4.2% of cases, and bifid in 47.9% of cases. C7 spinous process was monofid in 99.2% of cases, partially bifid in 0.5% of cases, and bifid in 0.3% of cases. T1 was monofid in all cases. A truly bifid C7 spinous process occurs 0.3% of the time and therefore is not a reliable landmark for choosing fusion levels. This knowledge hopefully helps prevent the type of wrong-level instrumentation that we performed.

Keywords

- ▶ posterior cervical surgery
- ▶ spinous process
- ▶ morphology
- ▶ monofid
- ▶ bifid
- ▶ frequency
- ▶ wrong-level surgery
- ▶ cervicothoracic

Introduction

Wrong-level surgery is one of the most common complications of spine surgery. For posterior cervical surgery, verification of the operative levels is usually done either with intraoperative fluoroscopy or plain radiographs or by counting the levels from the C2 spinous process. If the operation only involves the lower cervical or cervicothoracic spine, counting from the C2 spinous process is impractical. Furthermore, the distal cervical spine and the cervicothoracic junction may not be visible on fluoroscopy or plain radiographs, especially in those with a short or squat neck or those with bulky shoulders. In such cases, we usually place a marker at the top of the incision and also rely on the size and monofid shape of the C7 spinous process.

Relying on the C7 morphology, however, is not without risks. In one case, for example, we instrumented the wrong

levels in a patient who had a bifid C7 spinous process. In that case, as a result of the patient's short squat neck, it was very difficult to visualize the vertebral levels, and we therefore relied in part on the morphology of the spinous processes to determine the levels. With the technique, however, we instrumented in the wrong levels because C7 spinous process was bifid. Even though we were able to change the instrumentation levels before the case is finished, we almost performed the wrong-level surgery (▶**Fig. 1**). Given this experience, we sought to determine the frequency of bifid cervicothoracic spinous processes.

Materials and Methods

A total of 516 patients who visited our institution for any reason and received cervical spine computed tomography

received
April 1, 2012
accepted
May 16, 2012

Copyright © 2012 by Thieme Medical Publishers, Inc., 333 Seventh Avenue, New York, NY 10001, USA.
Tel: +1(212) 584-4662.

DOI <http://dx.doi.org/10.1055/s-0032-1319776>.
ISSN 2192-5682.

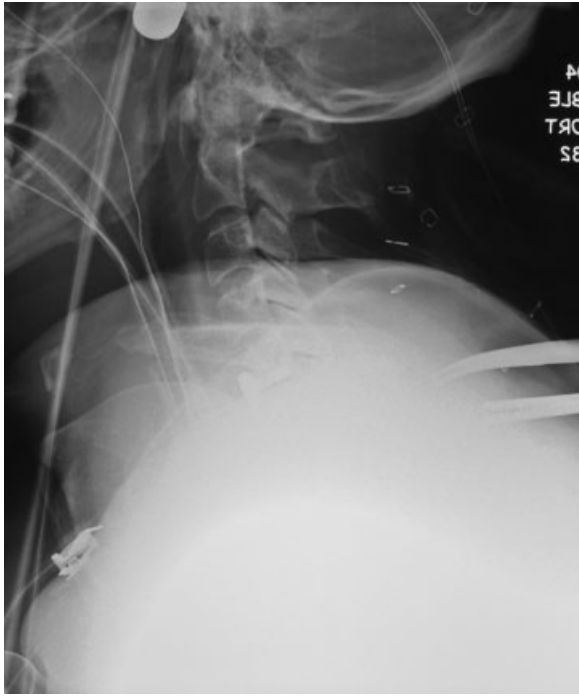

Figure 1 Intraoperative radiograph of the author's case had poor quality due to the patient's short and thick neck, thus leading to invisibility of cervicothoracic junction. Therefore, the authors relied on the C7 morphology, and initially instrumented the wrong levels because the patient had a bifid C7 spinous process.

(CT) imaging were enrolled in our study after Institutional Review Board approval. CT axial images of C6, C7, and T1 from those patients were evaluated by two spine surgeons (A and B: 20 years and 7 years postresidency, respectively). Amongst our patient population, 54 CTs were excluded because of congenital anomalies or prior surgery. Additionally, the tips of the spinous processes were not adequately visualized for all three vertebral levels in some cases, and these patients were also excluded.

Finally, 462 patients' CT axial images were reviewed. The number of images reviewed at each level was 170 for C6, 411 for C7, and 411 for T1. The spinous processes were classified into three categories: "bifid: clearly distinct cleft resulting in two elongated projections," "partially bifid: two distinct tubercles at the end of the spinous process are present without a cleft," and "monofid: rounded or flattened."¹

To determine the incidence of the true bifid, partially bifid, and monofid spinous processes, only the levels where the different cuts in one spinous process had the same morphologies were included first. For those cases, "A" marks were attached meaning anatomically defined classification.

The anatomical classification, however, was only applied when all CT axial cuts looked the same within the spinous process in question. Because of the chevron shape of the spinous process in the coronal view with its convex side up, it is possible to have two different images in the same spinous process depending on the position of CT cut. For example, if the cut is made through the superior part, the cut appears monofid. Conversely, if the cut is made through inferior part

Table 1 Anatomic and Radiographic Definition

Monofid-A	Rounded or flattened
Monofid-R	Monofid + partially bifid
Partially bifid-A	Two distinct tubercles at the end of the spinous process are present
Bifid-R	Partially bifid + bifid
Bifid-A	Clearly distinct cleft resulting in two elongate projections
Partially bifid-R	Bifid + monofid

excluding the real tip, then it will appear bifid. If there were two different CT axial images observed in one spinous process, then the radiological classification was used as shown here. We do not know whether the spinous process will be felt as bifid or monofid, and therefore we developed this scoring system. Thus, if there is at least one bifid cut, there will be higher chance for us to feel it as bifid instead of monofid. For those cases, "R" marks were attached meaning radiographically defined classification (►Table 1) (►Fig. 2).

The vast majority of the spinous processes could be classified with the anatomical classification, but some needed to be classified radiologically. We observed 159 levels from 55 patients by both the surgeons for the interobserver reliability. If there was disagreement between the observers' findings, observer A's decisions were used as the final results when the overall percentages were calculated.

Results

For the C6 level, a total of 142 patients out of 170 met the anatomical definition. Monofid in 68 patients (47.9%), partially monofid in 6 (4.2%), and bifid in 68 (47.9%) were observed.

At the C7 level, a total of 386 patients out of 411 met the anatomical definition. Monofid in 383 patients (99.2%), partially monofid in 2 (0.5%), and bifid in 1 (0.3%) were observed (►Fig. 3).

For the T1 level, a total of 386 patients out of 411 met the anatomical definition. Monofid in 409 patients (100%), partially monofid in 0 (0%), and bifid in 0 (0%) were observed.

Whereas approximately half of the C6 spinous processes were monofid, nearly 100% of the C7 spinous processes were monofid. Surprisingly, 0.3% of C7 spinous processes were bifid and 0.5% were partially bifid. There were no bifid T1 spinous processes (►Table 2).

Using both the anatomical and the radiological classification, additionally, 0.2% of C7 spinous processes were bifid, and 3.9% were partially bifid (►Table 3).

In the C6 group, a total of 28 patients were added as they met the requirements necessary to be defined radiographically instead of anatomically. In each subgroup, radiographically defined images were 10, 11, and 7 patients, respectively. Considering those confounding radiographically defined levels, monofid in 78 patients (45.9%), partially monofid in 17 (10%), and bifid in 75 (44.1%) were observed.

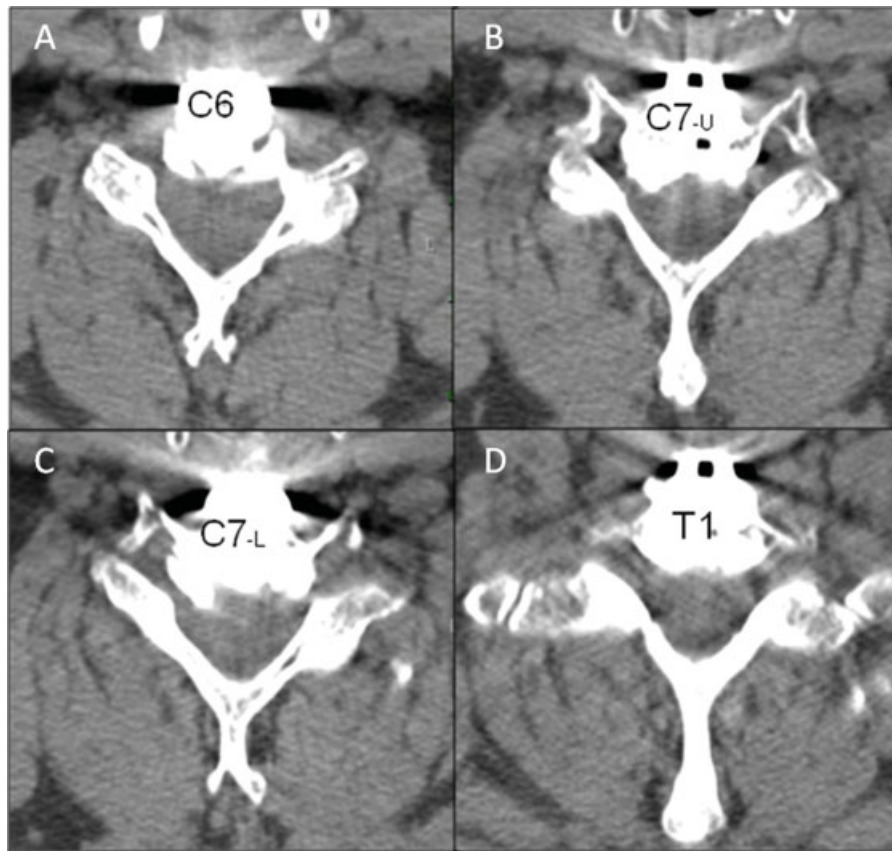


Figure 2 The computed tomography axial cut of the author’s case show the C7 spinous process looks bifid on one cut. (A) C6 spinous process is bifid. (B) Upper cut of C7 spinous process looks monofid. (C) However, lower cut of C7 bifid spinous process looks bifid; thus, radiologically classified as a partially bifid spinous process. (D) T1 spinous process is monofid.

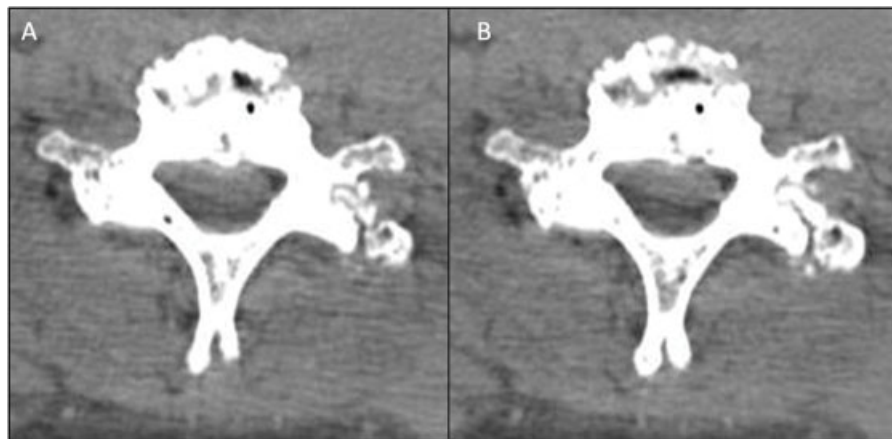


Figure 3 (A) Upper computed tomography axial cut and (B) lower cut of the true bifid C7 spinous process. It does occur 0.3% of the time and therefore is not a reliable landmark for choosing fusion levels.

In the C7 group, a total of 25 patients were added as they met the requirements necessary to be defined radiographically rather than using the anatomical technique. In each subgroup, radiographically defined images were 11, 14, and 0 patients, respectively. Considering those confounding radiographically defined levels, monofid in 394 patients (95.9%), partially monofid in 16 (3.9%), and bifid in 1 (0.2%) were

observed. Our case was radiologically classified as a partially bifid spinous process.

In the T1 group, a total of two patients were added as they met the requirements for a radiographic definition instead of anatomical. In each subgroup, radiographically defined images were 1, 1, and 0 patients, respectively. Taking into account those confounding radiographically defined levels,

Table 2 The Incidence of True Bifid, Partially Bifid, and Monofid Spinous Processes

%	C6 (142 Pt)	C7 (386 Pt)	T1(409 Pt)
Monofid-A	47.9	99.2	100
Partially bifid-A	4.2	0.5	0
Bifid-A	47.9	0.3	0
Total-A	100	100	100

Table 3 The Incidence of Bifid, Partially Bifid, and Monofid Spinous Processes Including Both Anatomically and Radiographically Defined Levels

%	C6 (170 Pt)	C7 (411 Pt)	T1 (411 Pt)
Monofid (A + R)	45.9	95.9	99.8
Partially bifid (A + R)	10	3.9	0.2
Bifid (A + R)	44.1	0.2	0
Total (A + R)	100	100	100

monofid in 410 patients (99.8%), partially monofid in 1 (0.2%), and bifid in 0 (0%) were observed.

Interobserver reliability was measured, and both percent agreement (91%) and kappa (0.77) were high.

Discussion

The characteristic morphology of the cervical spinous process is often used in medicine. In forensic science, for example, the morphology of the cervical spinous process can be used for the identification of individuals.¹ The seventh cervical spinous process is also important for counting levels to insert the epidural catheters by anesthesiologists.² For spine surgeons, spinous process anatomy is important when utilizing a posterior cervical approach. Usually, C2 can be used as a landmark because of its prominence. If the pathology is only confined to the lower cervical or cervicothoracic junction, however, counting from the C2 spinous process is impractical. In those cases, intraoperative plain radiographs and/or fluoroscopy are needed to confirm the levels. In patients with a short neck and bulky shoulders, we assumed that the last bifid spinous process was C6 and initially instrumented the wrong level. We undertook this study to determine the variability of spinous process morphology at the cervicothoracic junction.

We found that, although it is very rare to have a truly bifid C7 spinous process, it does occur 0.3% of the time and therefore the monofid appearance of the C7 spinous process is not a reliable landmark for choosing fusion levels. Our data suggest that, although it is very rare to have a truly bifid C7 spinous process, it does occur 0.3% of the time.

There have been several studies regarding the spinous process morphology. Das et al reported the duplicated spinous process of the C7 vertebra as a case report.³ In addition, Heyer et al reported the unilateral hyperplasia of a cervical

spinous process as a rare congenital variant of the spine in another case report.⁴ Lewit advocated that the deviation of the spinous processes can be the source of a patient's pain.⁵

An extensive anatomical study of the spinous processes of the cervical vertebrae was reported by Shore in the early 20th century.⁶ In that study, he observed 94 subjects from the native races of South Africa, and reported the incidence of bifid or monofid spinous processes in cervical spine and the average slopes of the spinous process in each levels in Bantu, Bushman, and European individuals. Also in the article, cervical spinous processes were classified as bifid and non-bifid. Bifid was then subclassified as bifurcate and cleft, and nonbifid was subclassified as acute, obtuse, pediculate, and clavate. There was a significant difference in the incidence of bifid spinous processes according to the races, but no C7 spinous process was classified as bifid.

Moro et al studied the frequency of bifurcation of the spinous process tip in 47 bleached bones and 3 fixed bodies for anatomical practice.⁷ They classified the spinous process morphology into "remarkable bifurcation," "slight bifurcation," and "absence of bifurcation." They considered both "remarkable and slight bifurcation" as bifurcation. Out of 50 specimens, C2 to C4 were all bifid, but in C5, 47; C6, 21; and C7, 1 were bifid. Accordingly, they advocated that cervical spinous process bifurcation is not useful as a landmark in posterior cervical spine approach. Even though it was well-designed anatomical study, the numbers were small. Also, no radiographic correlation was available.

To our knowledge, ours is the largest series examining the morphology of cervicothoracic spinous processes using CT scans. However, further study is needed to determine the correlation between the CT images and the actual morphologies of the spinous processes.

As a result of this study, we now routinely inspect magnetic resonance and, when available, CT images for the morphologies of the spinous processes at the cervicothoracic junction when performing posterior cervical spine surgery. We hope that our findings can help prevent the type of wrong-level instrumentation that we performed. Our data suggest that, although it is very rare, bifid spinous processes do occur. Therefore, reliance on the C7 spinous process being monofid is inappropriate for choosing fusion levels.

Note

No funds were received for the research of this article.

Disclosures

Woojin Cho, None

Takeshi Maeda, None

Yung Park, None

Jacob M. Buchowski, Consultant: Stryker, Inc., CoreLink, Inc., Globus Medical, Inc.; Teaching Arrangements/Speakers Bureau: Stryker, Inc., Globus Medical, Inc., DePuy, Inc., K2M, Inc.; Institutional Research Support: CSSG/K2M, Inc. Colin E. Nabb, None

Dan Riew, Royalties: Biomet, Medtronic Sofamor Danek, Osprey; Boards: Director/Officer: KASS, CSRS; Editorial:

JBJS, Spine; Stocks: Osprey, Expanding Orthopedics, Spineology, Amedica, Benvenue Medical, Inc., Nexgen Spine, Paradigm Spine, PSD, Spinal Kinetics, Spineology, Vertiflex

References

- 1 Duray SM, Morter HB, Smith FJ. Morphological variation in cervical spinous processes: potential applications in the forensic identification of race from the skeleton. *J Forensic Sci* 1999;44(5):937-944
- 2 Tamakawa S. Comparing the confidence of the 7th cervical spinous process, the inferior angle of the scapula, and Tuffier's line. *Reg Anesth Pain Med* 1999;24(6):585-586
- 3 Das S, Suri R, Kapur V. A duplicated spinous process of the C7 vertebra. *Folia Morphol (Warsz)* 2005;64(2):115-117
- 4 Heyer CM, Nicolas V, Peters SA. Unilateral hyperplasia of a cervical spinous process as a rare congenital variant of the spine. *Clin Imaging* 2007;31(6):434-436
- 5 Lewit K. Deviation of the spinous processes. *Br J Radiol* 1957;30(351):162-164
- 6 Shore LR. A report on the spinous processes of the cervical vertebrae in the native races of South Africa. *J Anat* 1931;65(Pt 4):482-505
- 7 Moro T, Kikuchi S, Konno S, Nishiyama K. Cervical spinous process bifurcation is not useful as a landmark in posterior cervical spine approach. *Fukushima J Med Sci* 2007;53(1):19-25