

Access-Port Fixation on the Left Pectoral Fascia in Laparoscopic Adjustable Gastric Banding

Bas van Wageningen · E. O. Aarts · I. M. C. Janssen ·
F. J. Berends

Published online: 1 May 2010

© The Author(s) 2010. This article is published with open access at Springerlink.com

Abstract Access-port (AP) complications after laparoscopic adjustable gastric banding (LAGB) are often seen but seldom reported in literature. AP complications requiring additional surgery is reported in 3.6% to 24% of LAGB patients (Susmallian et al. *Obes. Surg.*, 4:128–131, 2003; Peterli et al. *Obes. Surg.*, 12(6):851–856, 2002; Busetto et al. *Obes. Surg.*, 12:83–92, 2002; Mittermair et al. *Obes. Surg.*, 19:446–450, 2009; Holeczy et al. *Obes. Surg.*, 9:453–455, 1999; Bueter et al. *Arch. Surg.*, 393:199–205, 2008; Launay-Savary et al. *Obes Surg.*, 18:1406–1410, 2008; Balsiger et al. *J. Gastrointest. Surg.*, 11:1470–1477, 2007; Szold and Abu-Abeid *Surg. Endosc.*, 16:230–233, 2002). We evaluated the effect of fixing the AP on the pectoral fascia using the Velocity™ Injection Port on complication and re-operation rate. From January 2005 till October 2007, 619 LAGB procedures were performed using the SAGB QuickClose™. All procedures were performed by three dedicated surgeons using the pars flaccida technique. APs were placed on the fascia of the pectoral muscle using an infra-mammary incision. The AP device was fixed on the fascia using the Velocity™ Injection Port and Applier. Data was obtained retrospectively and records of 619 consecutive patients were reviewed for access-port complications. Sixty-eight AP complications were observed. Complications could be

divided in four categories. Discomfort was reported in 30 patients, seven needing additional surgery. Infection contributed to 11 patients needing surgical removal of the device. Fourteen Patients with superficial infection were treated conservatively. Nine patients had inaccessible APs. Ultrasound-guided access was required in three patients. The remainder needed surgical relocation of the AP. Leakage of the tube was observed in four patients all of which needed revisional surgery. Our experience shows that fixation of the AP on the left pectoral fascia using the Velocity™ leads to a readily accessible AP with good anaesthetic and aesthetic results. In our series, 68 (11%) complications were recorded, of which 28 (4.5%) needed additional surgery.

Keywords Morbid obesity · Bariatric surgery · Adjustable gastric banding · Access-port

Introduction

Laparoscopic adjustable gastric banding (LAGB) is one of the most often performed bariatric procedure in Europe. Its objective is to induce weight loss by restricting food intake [10]. It involves relative safe and simple laparoscopic surgery. Substantial and sustained weight loss is obtained in approximately 50% of all patients [11]. However, patients with a LAGB are susceptible for complications and there is a high re-operation rate. Other patients just fail to respond to the restrictive procedure, despite thorough selection [12, 13]. Insufficient weight loss and even weight gain is reported in up to 30% of all LAGB patients. Insufficient weight loss can be due to pouch dilatation or slippage of the gastric band. Pouch formation attributes approximately 5% to these so-called non-responders, and these patients need additional surgery. Often considered minor but second in frequency are

B. van Wageningen (✉)
Department of Surgery,
Radboud University Nijmegen Medical Centre,
Postbus 9101, 6500 HB,
Nijmegen, The Netherlands
e-mail: b.vanwageningen@chir.umcn.nl

E. O. Aarts · I. M. C. Janssen · F. J. Berends
Department of Surgery, Rijnstate Hospital,
Postbus 9555, 6815 AD,
Arnhem, The Netherlands

the AP-related complications. These complications can be divided in four different categories; discomfort, infection of the AP and/or LAGB, inability to puncture the reservoir due to dislocation and disconnection/leakage of the tubing [14]. So far, only few papers have addressed these specific LAGB-associated complications [15–17]. In order to reduce the number of AP-related complications an alternative location for the AP, analogue to the fixation site of the Port-a-Cath system, was evaluated in our hospital. This new technique was retrospectively evaluated. A total number of 619 consecutive patients were treated with LAGB and had their AP fixed on the left pectoral fascia using the Velocity™ Injection Port and Applier.

Materials and Methods

Since 1996, minimally invasive gastric banding was implemented in the Rijnstate Hospital in Arnhem. From January 2005 till November 2007, the Swedish Adjustable Gastric Band (SAGB) was combined with the Velocity™ Injection Port and Applier which was fixed on the left pectoral fascia. A prophylactic dose of 2 g cefazoline IC was given 30 min before the onset of surgery. All bariatric procedures were performed by three experienced and dedicated surgeons. All patients agreed to participate in a standardised follow-up used for evaluating the effectiveness of the SAGB. Follow-up procedure was performed by a dedicated nurse, and included an appointment 2 and 8 weeks post-operative. Thereafter, patients were seen annually for the first 5 years. After 8 weeks the gastric band was filled with 2 ml saline independently to weight loss. Later

adjustments were done according to individual weight loss characteristics. Data on post-operative AP complications and re-operation rates were collected retrospectively from this database. Patients were evaluated for AP-related symptoms such as pain, infection, orientation of the port, inability to gain excess to the AP and leakage and/or disconnection of the tubing.

All LAGB devices were placed using a standard five-port laparoscopic technique as described by Belachew [18, 19] and positioned using the pars flaccida technique. In order to gain access to the pectoral fascia, the sub-xiphoid incision was made just left of the midline and extended laterally to approximately 3 cm in the infra-mammary fold. Blunt and electrocautery dissection was performed to create a pocket large enough to fit the AP (see Fig. 1a–d). The AP was then connected to the tube. Fixation of the AP on the pectoral fascia was obtained using the four retractable hooks of the Velocity™. Data was statistically analysed using SPSS 16.0®. All data is reported as mean±95% confidence interval (95%CI). Patients with less than 6 months of post-operative follow-up were contacted by telephone and/or by mail.

Results

From January 2005 till October 2007, a total of 619 patients underwent a LAGB procedure in our hospital all of which are included in this study. Patient characteristics are summarised in Table 1. Total follow-up was 14.4 ± 10.0 months. Reduction in BMI was found to be significant ($p < 0.001$) from time of operation (BMI 44.1 kg/m^2) till

Fig. 1 **a** Infra-mammary incision facilitating the AP place. **b** Tunnelling of the tube in order to reduce wear and tear of the tube. **c** Placement of the AP device on the pectoral fascia. **d** Cosmetic result at termination of the LAGB procedure

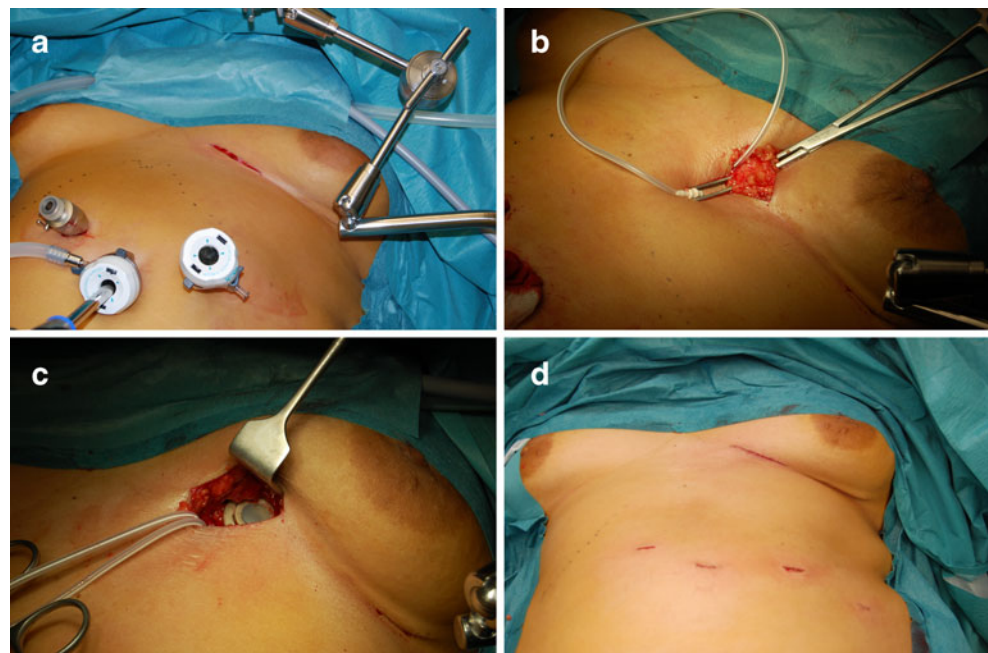


Table 1 Patient characteristics

Gender	
Male (%)	102 (16.5%)
Female (%)	517 (83.5%)
Age (years)	40.1±9.6
Duration of surgery (minutes)	63.4±18.1
Total follow-up (years)	14.4±10.0
BMI at the start (kg/m ²)	44.1±5.0*
BMI at last follow-up (kg/m ²)	36.3±5.7*

* $p < 0.001$, paired *t*-test

date of last follow-up (BMI 36.3 kg/m²). From this group seven (1.1%) patients received a revision of an earlier placed LAGB. These revision were done for pouch dilatation and/or slippage. These were included in this study.

Our AP complications could be stratified in four different categories: discomfort, infection, inaccessibility of the AP device and leakage/disconnection of the tubing (see Table 2).

Post-operative pain was reported in 30 (4.8%) patients but usually subsided within 6 months (23 (3.7%) cases). Seven cases had ongoing chest pain oblivious to conservative treatment and required surgery in which the AP was moved to the left hypochondrial port site. After this intervention, pain resolved in all cases.

Infection was reported in 25 (4.0%) patients. Fourteen (2.3%) patients had just superficial wound infections and could be treated conservatively. Eleven (1.7%) patients required additional surgery. In eight (1.3%) patients only the AP was removed and the tubing was left to rest in the abdominal cavity, while patients received oral antibiotics for a period of 6 weeks. After approximately 6 months, the tubing was recollected laparoscopically and a new AP was placed at the same spot. Three (0.5%) patients had the whole system removed due to infection of the gastric band and the AP. In all three cases this complication manifested itself at least 4 months after primary surgery. Two (0.3%) of these patients underwent additional bariatric surgery and received a laparoscopic Roux-en-Y gastric bypass. One (0.2%) patient renounced from further bariatric procedures and had only the SAGB system removed.

Inaccessibility of the AP was seen in nine (1.5%) patients. This resulted in revisional surgery in six (1.0%)

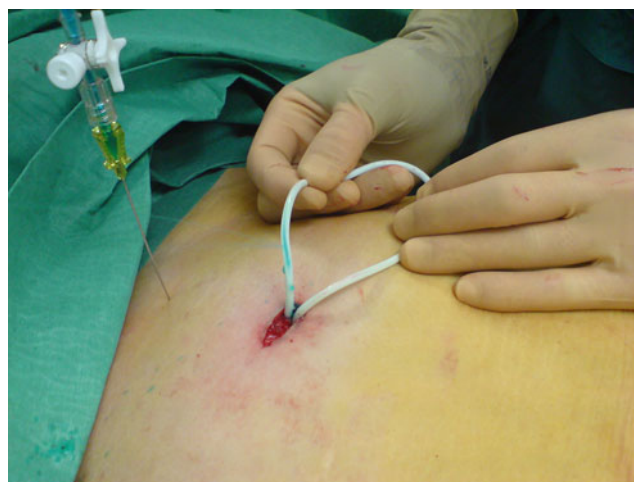

Fig. 2 Blue dye shows leakage of the tubing due to wear and tear on the fascia

patients. Revision was done in day care since it required only superficial surgery. The remaining three (0.5%) patients had their LAGB adjusted using ultrasound guiding.

Four (0.6%) patients were found to have leaks of the tubing from AP to the gastric band. In two (0.3%) patients leakage of the band was found to be intra-abdominally most likely due to damaging of the tubing during implantation. Two tubes were damaged on the spot where the tube passed through the abdominal wall and these lesions were considered to be a result from wear and tear from the fascia on the tube (see Fig. 2). All four (0.6%) patients needed additional surgery in order to reconnect the LAGB to the access-port.

Discussion

After approximately 11 years of experience with LAGB surgery we concluded that AP-related complications are frequent and most often due to technical failure. Some of these complications are caused by the chosen location of the AP and thus it is only logic to try to identify the ideal site for AP fixation. In order to appoint a new location for the AP we considered multiple factors for optimal placement. First of all, the location must be readily accessible for the required and frequent adjustments of the LAGB. One must be able to firmly secure the AP on the designated spot.

Table 2 Complications stratified in four categories

	Discomfort/pain <i>n</i> (%)	Infection <i>n</i> (%)	Inaccessibility <i>n</i> (%)	Leakage/disconnection <i>n</i> (%)	Total <i>n</i> (%)
Conservative	23 (3.7%)	14 (2.3%)	3 (0.5%)	0 (0%)	40 (6.4%)
Surgery	7 (1.0%)	11 (1.7%)	6 (1.0%)	4 (0.6%)	28 (4.5%)
Total	30 (4.8%)	25 (4.0%)	9 (1.5%)	4 (0.6%)	68 (11.0%)

This fixation should give no or little discomfort and should provide acceptable cosmetic characteristics. In the long run, wear and tear on the devices' tubing should be minimised in order to reduce the change of leakage of the system and inducing a failure. To minimise infection rates, antibiotic prophylaxis should be given 30 min before the onset of surgery.

Different port locations are commonly used and include: the anterior rectus sheath, under the anterior rectus sheath, within the subcutaneous fat, sub-xiphoid and left subcostal margin. Ports can be fixed by sutures or with retractable hooks, our even non-fixed. APs seem to be well tolerated by most patients regardless of position and fixation. Subfascial placement may give some more pain complaints during access and may be more difficult to palpate. Ports placed in the subcutaneous fat may become very prominent once a patient has lost weight. Rotation of the port is thought to occur more often making the ports inaccessible.

Fixation of the port on the fascia is time consuming and may give pain complaints. Infra-mammary placement is cosmetically favourable, and makes the AP easy to palpate. By using the mechanical port fixation method, operation time and post-operative discomfort complaints can be reduced.

We choose the left pectoral fascia analogue to years of experience with the port-a-cath system. In order to create a pouch for the AP, we elongated our sub-xiphoid incision laterally in the infra-mammary fold for the best aesthetic result possible. When placing the infra-mammary incision in female patients we made sure it did not interfere with wearing a brassiere, since scar tissue might give rise to irritation of the skin in the infra-mammary fold.

The AP was fixed just lateral of the sternum in order to make needle access to the AP relatively safe and simple. The device was firmly attached on the chest wall in order to prevent friction between connection tube and fascia. In our study population, two early patients had leakage of the tubing due to wear and tear of the device on the fascia (see Fig. 2). The technique used was adjusted by tunnelling our tube parallel to and direct on the fascia in order to minimise mechanical wear. Two other patients were shown to have intra-abdominal leakage using water-soluble contrast. These were considered technical failures, probably due to incorrect handling of the tube during initial placement of the access-port.

Thoracic pain complaints were seen in some of our earlier patients, two of which were even referred to the cardiologist by their family doctor. Complaints were most often short lived and regressed spontaneously. After we started using local anaesthetics (Ropivacaine® 7.5 mg/ml, 10 ml) on the AP fixation site and placed our APs a little laterally of the sternum, pain complaints receded. Thoracic pain is probably due to damaging the periost lining of the

sternum and costae with our suturing device. Dislodgement of the AP was seen in nine (1.5%) patients. Revisional surgery to relocate and fixate the dislocated AP was required in six (1.0%) of our cases.

Overall, we had an 11% complication rate of which only 4.5% needed additional surgery. In literature, a 3.6–24% re-operation rate for AP-related complications is reported [1–9]. We conclude that besides being fast, fixation of the AP on the left pectoral fascia is safe and simple. If the reservoir is firmly attached to the fascia, it lies rather superficial which makes percutaneous access easy. No additional incision is needed since the incision below the xiphoid is extended laterally in the infra-mammary fold, thereby giving good cosmetic results. Discomfort is minimised by using local anaesthetic preoperative. Mechanical wear and tear was minimised by lining the tubing parallel to the fascia and thus reducing the angle in which the tube passed through the fascia. Whether our system can stand up to the wear and tear of time needs yet to be seen since our follow-up is relatively short.

Conflict of interest The authors declare that they have no conflict of interest.

Open Access This article is distributed under the terms of the Creative Commons Attribution Noncommercial License which permits any noncommercial use, distribution, and reproduction in any medium, provided the original author(s) and source are credited.

References

1. Susmallian S, Ezri T, Elis M, et al. Acces-port complications after laparoscopic gastric banding. *Obes Surg.* 2003;4:128–31.
2. Peterli R, Donadini A, Peters T, et al. Re-operations following laparoscopic adjustable gastric banding. *Obes Surg.* 2002;12(6):851–6.
3. Busetto L, Segato G, De Marchi F, et al. Outcome predictors in morbidly obese recipients of an adjustable gastric band. *Obes Surg.* 2002;12:83–92.
4. Mittermair R, Aigner F, Obermuller S. High complication rate after Swedish adjustable gastric banding in younger patients ≤ 25 years. *Obes Surg.* 2009;19:446–50.
5. Holeczy P, Novak P, Kralova A. Complications in the first year of laparoscopic gastric banding: is it acceptable? *Obes Surg.* 1999;9:453–5.
6. Bueter M, Maroske J, Thalheimer A, et al. Short- and long-term results of laparoscopic gastric banding for morbid obesity. *Arch Surg.* 2008;393:199–205.
7. Launay-Savary M, Slim K, Brugere C, et al. Band and port-related morbidity after bariatric surgery: an underestimated problem. *Obes Surg.* 2008;18:1406–10.
8. Balsiger B, Ernst D, Giachino D, et al. Prospective evaluation and 7-year follow-up of Swedish adjustable gastric banding in adults with extreme obesity. *J Gastrointest Surg.* 2007;11:1470–7.
9. Szold A, Abu-Abeid S. Laparoscopic adjustable silicone gastric banding for morbid obesity. *Surg Endosc.* 2002;16:230–3.
10. Tice J, Karliner L, Walsh J, et al. Gastric banding or bypass? A systematic review comparing the two most popular bariatric procedures. *Am J Med.* 2008;121(10):885–93.

11. O'Brien PE, Dixon JB, Brown W, et al. The laparoscopic adjustable gastric band (lap-Band®): a prospective study of medium-term effects on weight, health and quality of life. *Obes Surg.* 2002;12:652–60.
12. Abu-Abeid S, Szold A. Results of complications of laparoscopic adjustable gastric banding: an early and intermediate experience. *Obes Surg.* 1999;9:188–90.
13. Zehetner J, Holzinger F, Triaca H, et al. A 6-year experience with the Swedish adjustable gastric band. *Surg Endosc.* 2005;19:21–8.
14. Kirshstein B, Avinoach E, Mizrahi S, et al. Presentation and management of port disconnection after laparoscopic gastric banding. *Surg Endosc.* 2009;23:272–5.
15. Keidar A, Carmon E, Amir Szold A, et al. Port complications following laparoscopic adjustable gastric banding for morbid obesity. *Obes Surg.* 2005;15:361–5.
16. Arvind N, Bates S, Morgan J, et al. Fixation of the access-port is not required in gastric banding. *Obes Surg.* 2007;17:577–80.
17. Spivak H, Gold D, Guerrero C. Optimization of access-port placement for the Lap-Band® System. *Obes Surg.* 2003;13:909–12.
18. Belachew M, Legrand M, Vincent V. Laparoscopic adjustable gastric banding. *World J Surg.* 1998;22:955–63.
19. Belachew M, Belva PH, Desai C. Long-term results of laparoscopic adjustable gastric banding for the treatment of morbid obesity. *Obes Surg.* 2002;12:564–8.