

Traumatic intralenticular abscess—What is so different?

S Balamurugan, Bharat Gurnani¹, Kirandeep Kaur², Prasanth Gireesh³, Shivanand Narayana⁴

Consultant Uvea Services, ¹Cornea Fellow, ²Pediatric Fellow, ³Consultant Cataract and IOL Services, ⁴Consultant, Cornea and Refractive Services, Aravind Eye Hospital, Pondicherry, India

Correspondence: Dr. Bharat Gurnani, Department of Ophthalmology, Cornea Fellow, Aravind Eye Hospital, Pondicherry - 605 007, India.
E-mail: drgurnanibharat25@gmail.com

Abstract

Intralenticular abscess is a very rare entity that occurs after trauma, cataract surgeries, or as metastatic infection. It is important to pinpoint this sequestered infection and to evacuate the abscess surgically to prevent chronic endophthalmitis. In this report, we describe a case of posttraumatic lenticular abscess highlighting the characteristic clinical features and their management. Additionally, here we report the first time use of Anterior Segment Optical Coherence Tomography as a diagnostic tool in delineating lens abscess from traumatic cataract which further guide the management and prognosis of the case.

Traumatic intralenticular abscess (TILA)—What is so different?

Key words: Anterior segment optical coherence tomography; B scan; intralenticular abscess; moraxella, trauma

Introduction

Intralenticular abscess is an uncommon condition that has been described after penetrating trauma, metastatic spread, and intraocular surgery.^[1] It is a known fact that the lens is damaged in around 30% of perforating injuries of the eye and 10% of all intraocular foreign bodies lodge in the lens and in many of these cases the lens is retained.^[1] There are very few reports of intralenticular abscess in the ophthalmic literature and none of the previous described literature has ever used imaging tool Anterior Segment Optical Coherence Tomography (ASOCT) for description of lenticular abscess.

Case Report

A 65-year-old gentleman presented with right eye defective vision of 1 month duration following thorn

injury. At presentation, visual acuity was hand movements close to face and intraocular pressure was 16 mmHg in right eye. Anterior segment examination revealed healed lamellar corneal tear, 1+ cells and heterogenous opacity of the crystalline lens [Figure 1]. Fundoscopy revealed hazy view. B scan ultrasound revealed no features suggestive of endophthalmitis [Figure 2]. ASOCT showed a heterogenous lenticular opacity suggestive of lens abscess [Figure 3]. Lens extraction was done by manual small incision cataract surgery (MSICS). Primary intraocular lens (IOL) implantation was deferred. Intracameral antibiotic wash was done. Culture of lenticular matter yielded *Moraxella* species. At 3 months, secondary IOL implantation was done as a staged procedure. The visual acuity at last follow-up was 20/40 at 15 months [Figure 4].

This is an open access journal, and articles are distributed under the terms of the Creative Commons Attribution-NonCommercial-ShareAlike 4.0 License, which allows others to remix, tweak, and build upon the work non-commercially, as long as appropriate credit is given and the new creations are licensed under the identical terms.

For reprints contact: reprints@medknow.com

Cite this article as: Balamurugan S, Gurnani B, Kaur K, Gireesh P, Narayana S. Traumatic intralenticular abscess—What is so different? Indian J Radiol Imaging 2020;30:92-4.

Received: 09-Sep-2019

Revised: 23-Oct-2019

Accepted: 26-Nov-2019

Published: 30-Mar-2020

Access this article online

Quick Response Code:



Website:
www.ijri.org

DOI:
10.4103/ijri.IJRI_369_19

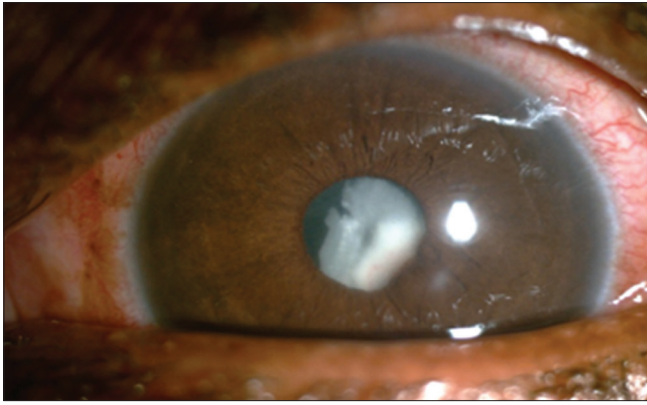


Figure 1: Image of right eye showing pinpoint corneal lamellar laceration with heterogenous lenticular opacity suggestive of lens abscess

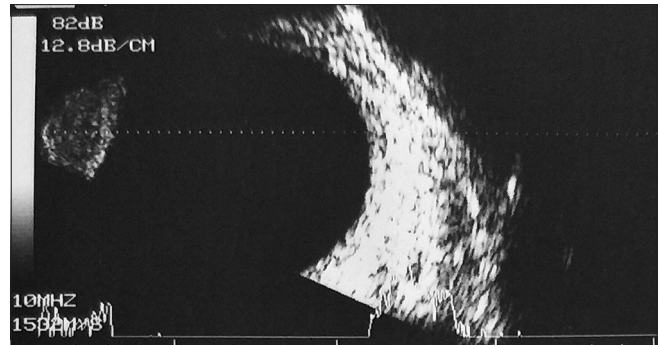


Figure 2: B Scan image of the right eye showing clear vitreous cavity with no signs of Endophthalmitis

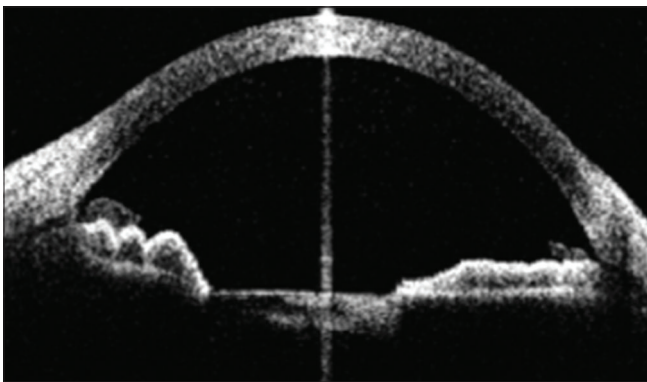


Figure 3: Image of Anterior Segment Optical Coherence Tomography of right eye showing heterogenous lenticular opacity suggestive of lens abscess

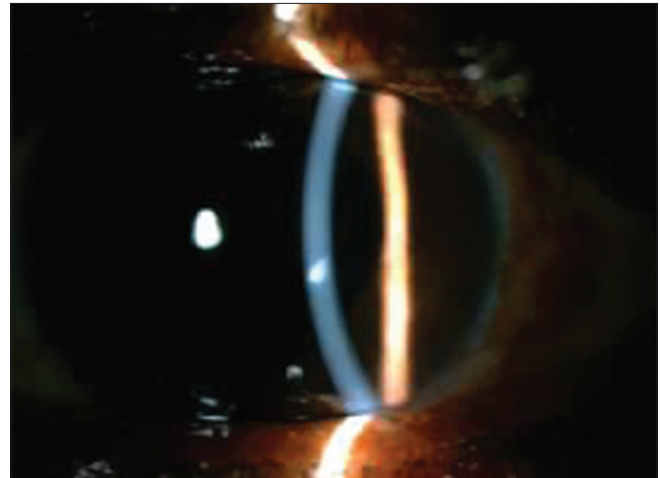


Figure 4: Postoperative image of the same eye showing stable posterior chamber intraocular lens and quite eye

Discussion

ILA may camouflage a complicated cataract. Microbes can reach in by penetrating trauma (externally), metastatic infection (internally), or can be sterile.^[1] Transition to endophthalmitis is possible and merits close monitoring.^[2] It is important to recognize this sequestered infection and evacuate the abscess surgically to prevent chronic endophthalmitis. Thorough literature review on lens abscess revealed application of extracapsular cataract extraction but ASOCT was not appropriately used.^[3] It is highly relevant in assessing the integrity of posterior lens capsule (PC) and delineating the lens abscess. For an astute clinician, the chances of endophthalmitis increases multifold when PC is breached and warrants treatment along those lines. Discerning lens abscess from traumatic cataract is vital as primary IOL implantation is contraindicated. Secondary IOL as a staged procedure is needed to prevent smoldering infections. Early intervention, eradication of microbial load, and meticulous follow-up are the key elements of treatment success. In suspected fungal cases, intravitreal steroids are meticulously avoided. A high index of suspicion to look for secondary sequelae like secondary glaucoma, cystoid macular edema merits attention.^[4,5]

Conclusion

In summary, to the best of our knowledge this is the first report of application of ASOCT as a diagnostic tool for delineating the lenticular abscess from traumatic cataract. In all cases with trauma, early removal of lenticular abscess is necessary to save the eye and prevent further complications. In our experience with this patient, staged surgical procedures helped in resolution of infection and attain an excellent final visual outcome.

Declaration of patient consent

The authors certify that they have obtained all appropriate patient consent forms. In the form the patient(s) has/have given his/her/their consent for his/her/their images and other clinical information to be reported in the journal. The patients understand that their names and initials will not be published and due efforts will be made to conceal their identity, but anonymity cannot be guaranteed.

Financial support and sponsorship

Nil.

Conflicts of interest

There are no conflicts of interest.

References

1. Rajaraman R, Lalitha P, Raghavan A, Palanisamy M, Prajna NV. Traumatic lenticular abscess: Clinical description and outcome. *Am J Ophthalmol* 2007;144:144-6.
2. Salman A, Parmar P, Philip VR, Thomas PA, Jesudasan CA. Traumatic intralenticular abscess: A case series. *Clin Exp Ophthalmol* 2007;35:252-5.
3. Manners RM, Canning CR. Posterior lens abscess due to *Propionibacterium acnes* and *Staphylococcus epidermidis* following extracapsular cataract extraction. *Br J Ophthalmol* 1991;75:710-2.
4. Moore DC. Intralenticular abscess. *Aust NZ J Ophthalmol* 1989;17:313-5.
5. Hutchinson K, Kempster R, Conrad D. Intralenticular abscess caused by *Stenotrophomonas maltophilia*. *Eye* 2001;15:349-50.