

# Catch Me While You Scan: Primary Ovarian Pregnancy

Sweta Singh, Prashanta Kumar Rout, Pavithra Ayyanar<sup>1</sup>

Departments of Obstetrics and Gynaecology and <sup>1</sup>Pathology, All India Institute of Medical Sciences, Bhubaneswar, Odisha, India

ABSTRACT

Primary ovarian pregnancy is rare, accounting for 0.5%–3.0% of all ectopic gestations. It was earlier diagnosed by the classical Spiegelberg's criteria. Ultrasonographic diagnostic criteria have now been described for preoperative diagnosis. We report a case of primary ovarian pregnancy in a 30-year-old woman, where the diagnosis was made preoperatively, and discuss the challenges in diagnosis and management for optimal patient outcomes.

**KEYWORDS:** Ovarian pregnancy, tubal gestation, ultrasonography

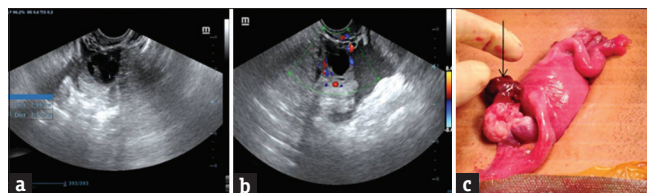
## INTRODUCTION

Ovarian pregnancy accounts for 0.5%–3.0% of all ectopic gestations.<sup>[1]</sup> Preoperative diagnosis continues to be challenging, despite advances in ultrasonography.<sup>[2]</sup> We report a case of primary ovarian pregnancy in a 30-year-old woman, where a preoperative ultrasonographic diagnosis was made, and discuss the imaging and therapeutic challenges.

## CASE REPORT

A 30-year-old woman presented in the emergency hours with lower abdominal pain of 7 days' duration. Pain was continuous in nature and increasing in intensity, getting relieved with analgesics, and was not associated with any bleeding per vaginum or dysuria. She was para 1, having had a full-term normal vaginal delivery 4 years back, with no history of any contraceptive usage. Her menstrual cycles were regular, with average flow, and she had missed her periods by 4 days. There was no significant past or family history. On examination, her vitals were stable. There was mild pallor with diffuse tenderness in the right iliac fossa along with rigidity and guarding. Per speculum examination was unremarkable. Per vaginum examination revealed a normal-sized uterus with boggy and tenderness in the right fornix, and presence of cervical motion tenderness. Her urine pregnancy test was positive. Her hemoglobin was 10.8 g/dL and serum beta-human chorionic gonadotropin was 2000 IU/mL.

Ultrasonography revealed an empty uterine cavity with fluid in the pouch of Douglas. The right ovary showed a gestational sac measuring 1.98 cm × 1.71 cm [Figure 1a], with color Doppler showing the presence of vascularity around it [Figure 1b]. A preoperative diagnosis of ruptured right ovarian pregnancy was made. The patient was taken up for exploratory laparotomy. Intraoperatively, there was presence of hemoperitoneum of 200 mL, with right ovary showing a gestational sac measuring 2 cm × 2 cm arising from the top of the right ovary with bleeding from the area [Figure 1c]. Bilateral Fallopian tubes and the left ovary were normal. Right ovarian wedge resection was done. Histopathology revealed ovarian parenchyma with prominent hemorrhage and corpus luteum, with the adjoining stroma showing



**Figure 1:** (a) Two-dimensional ultrasonography showing the right ovary with a gestational sac measuring 1.98 cm × 1.71 cm. (b) Color Doppler ultrasonography showing the ring-of-fire appearance, along with free fluid. (c) Intraoperative image showing normal bilateral Fallopian tubes and left ovary with the right ovary showing a gestational sac measuring 2 cm × 2 cm with bleeding from the area (black arrow)

**Address for correspondence:** Dr. Sweta Singh, Department of Obstetrics and Gynaecology, All India Institute of Medical Sciences, Bhubaneswar - 751 019, Odisha, India. E-mail: swetsingh@hotmail.com

Received: 27-03-2020

Revised: 04-06-2020

Accepted: 10-08-2020

Published: 28-06-2021

### Access this article online

#### Quick Response Code:



**Website:**  
www.jhrsonline.org

**DOI:**  
10.4103/jhrs.JHRS\_50\_20

This is an open access journal, and articles are distributed under the terms of the Creative Commons Attribution-NonCommercial-ShareAlike 4.0 License, which allows others to remix, tweak, and build upon the work non-commercially, as long as appropriate credit is given and the new creations are licensed under the identical terms.

**For reprints contact:** WKHLRPMedknow\_reprints@wolterskluwer.com

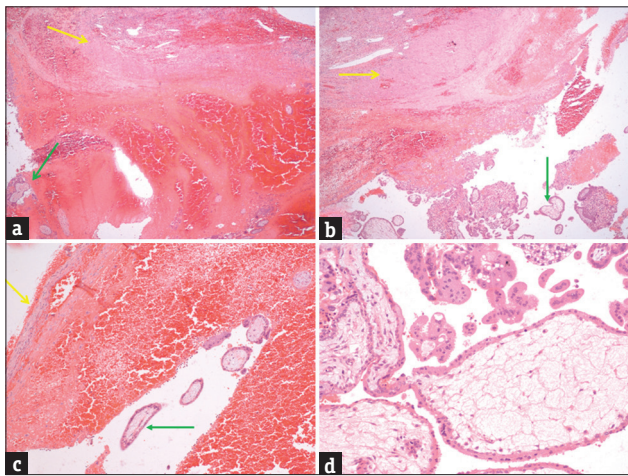
**How to cite this article:** Singh S, Rout PK, Ayyanar P. Catch me while you scan: Primary ovarian pregnancy. J Hum Reprod Sci 2021;14:200-2.

hemorrhage containing chorionic villi, trophoblastic cells, and blood clots [Figure 2]. The patient is on follow-up for 4 months now and is doing well.

## DISCUSSION

Primary ovarian pregnancy is rare, with an estimated incidence of 1 in 25,000–40,000 pregnancies, comprising 0.5%–3.0% of all ectopic gestations.<sup>[1,2]</sup> Risk factors include prior use of intrauterine device, assisted reproductive techniques, concurrent endometriosis, and pelvic adhesions.<sup>[1,3,4]</sup> However, in our case, no such history was identified. The most common presenting feature is abdominal or pelvic pain,<sup>[1]</sup> as was seen in our case also. Bleeding per vaginum is usually absent.

Preoperative diagnosis continues to be challenging, despite the advances in ultrasonography.<sup>[5]</sup> Tubal ectopic



**Figure 2:** (a) Scanning magnification of the ovarian parenchyma showing corpus luteum (yellow arrow) with marked hemorrhage and blood clot containing chorionic villi (green arrow). (b) Low-power magnification of the ovarian parenchyma (corpus luteum yellow arrow), with hemorrhage and blood clot containing chorionic villi (green arrow). (c) Ovarian stroma (yellow arrow) with marked hemorrhage and blood clot containing chorionic villi (green arrow). (d) Chorionic villi lined by cytotrophoblast and few syncytiotrophoblasts

pregnancies have been diagnosed with clinical criteria along with ultrasonographic features of an empty uterus, free fluid, an adnexal ring or mass separate from the ovary, ring-of-fire sign, and extrauterine embryonic cardiac activity.<sup>[6]</sup>

Classically, primary ovarian pregnancy is diagnosed by the Spiegelberg's criteria, where each of the following criteria should be met: (i) bilateral Fallopian tubes should be intact, (ii) gestational sac should be in the position of normal ovaries, (iii) ovary with the gestational sac should be connected to the uterus through the utero-ovarian ligament, and (iv) ovarian tissue should be present in the wall of the gestational sac.<sup>[4]</sup> The ultrasound diagnostic criteria for ovarian pregnancy have been suggested as (i) presence of a wide echogenic ring with an internal echolucent area on the surface of ovary; (ii) the presence of ovarian cortex, including corpus luteum or follicles around the mass; and (iii) echogenicity of the ring being greater than that of the ovary itself.<sup>[4-7]</sup> Embryonic structures are usually not seen, as progression beyond early stages is rare, and development in relation to age of gestation is delayed. Recently, a case of ovarian pregnancy rupture in the second trimester has been reported.<sup>[8]</sup>

The differential diagnosis of ovarian pregnancy is tubal ectopic gestation and rupture of corpus luteal cyst [Table 1]. Intraoperatively, the lesion has been differentiated from the hemorrhagic corpus luteum in only 28% of cases, hence the need for histopathological confirmation.<sup>[5]</sup> Primary ovarian ectopic gestation is best treated by either ovarian wedge resection or oophorectomy,<sup>[8]</sup> as was done in our case also. Medical management with methotrexate is currently not recommended.<sup>[9]</sup>

To conclude, primary ovarian pregnancy is rare, and a high index of suspicion must be kept in mind to differentiate it from its common mimickers such as

**Table 1: Differentiation of primary ovarian pregnancy from tubal gestation and rupture of corpus luteal cyst**

	Tubal gestation	Rupture of corpus luteal cyst	Primary ovarian pregnancy
Pain abdomen	+	+	+
Bleeding per vaginum	+	-	-
Amenorrhea	+	-	+/-
Urine pregnancy test	+	-	+
Elevated serum beta-human chorionic gonadotropin	+	-	+
Ultrasonography	Empty uterus, free fluid, an adnexal ring or mass separate from the ovary, ring-of-fire sign, extrauterine embryonic cardiac activity <sup>[6]</sup>	Eccentric location with a thick hypervascular echogenic ring surrounding a central hypoechoic area, ring-of-fire sign <sup>[6]</sup>	(1) Presence of wide echogenic ring with an internal echolucent area on the surface of ovary (2) presence of ovarian cortex, including corpus luteum or follicles around the mass, and (3) greater echogenicity of the ring than that of the ovary <sup>[4-7]</sup>

tubal gestation and rupture of corpus luteum cyst. A combination of preoperative ultrasonographic diagnosis along with operative and histopathologic confirmation leads to best patient outcomes.

#### Declaration of patient consent

The authors certify that they have obtained all appropriate patient consent forms. In the form the patient(s) has/have given his/her/their consent for his/her/their images and other clinical information to be reported in the journal. The patients understand that their names and initials will not be published and due efforts will be made to conceal their identity, but anonymity cannot be guaranteed.

#### Financial support and sponsorship

Nil.

#### Conflicts of interest

There are no conflicts of interest.

#### REFERENCES

1. Ghasemi Tehrani H, Hamoush Z, Ghasemi M, Hashemi L. Ovarian ectopic pregnancy: A rare case. *Iran J Reprod Med* 2014;12:281-4.
2. Smith JP, Krishnamurthy S, Mansour FW. Ovarian pregnancy. *J Obstet Gynaecol Canada* 2016;38:1-2.
3. Marcus SF, Brinsden PR. Primary ovarian pregnancy after *in vitro* fertilization and embryo transfer: Report of seven cases. *Fertil Steril* 1993;60:167-9.
4. Ciortea R, Costin N, Chiroiu B, Mălutan A, Mocan R, Hudacsko A, *et al.* Ovarian pregnancy associated with pelvic adhesions. *Clujul Med* 2013;86:77-80.
5. Raziel A, Schachter M, Mordechai E, Friedler S, Panski M, Ron-El R. Ovarian pregnancy-a 12-year experience of 19 cases in one institution. *Eur J Obstet Gynecol Reprod Biol* 2004;114:92-6.
6. Levine D. Ectopic pregnancy. *Radiology* 2007;245:385-97.
7. Comstock C, Huston K, Lee W. The ultrasonographic appearance of ovarian ectopic pregnancies. *Obstet Gynecol* 2005;105:42-5.
8. Hwang DW, Choi HW, Choi YY, Kim HS, Kim YA, Chun KC. Ovarian pregnancy rupture in second trimester manifesting mental change in pregnancy: A case report. *Obstet Gynecol Sci* 2020;63:209-12.
9. Practice Committee of American Society for Reproductive Medicine. Medical treatment of ectopic pregnancy: A committee opinion. *Fertil Steril* 2013;100:638-44.