

Teaching Point
(Section Editor: A. Meyrier)

A case of bilateral renal masses: dilemmas in their evaluation and management

Emily J. Tweed, Ian S. D. Roberts, David Cranston and Christopher G. Winearls

¹Medical School, University of Oxford, UK, ²Department of Cellular Pathology, Oxford Radcliffe Hospitals NHS Trust, Oxford, UK, ³Department of Urology, Churchill Hospital, Oxford Radcliffe Hospitals NHS Trust, Oxford, UK, and ⁴Oxford Kidney Unit, Churchill Hospital, Oxford Radcliffe Hospitals NHS Trust, Oxford, UK

Correspondence and offprint requests to: Christopher G. Winearls; E-mail: Chris.Winearls@orh.nhs.uk

Keywords: small renal mass, oncocytoma, oncocytosis, renal biopsy

Introduction

The finding of solid contrast-enhancing renal masses on imaging presents a diagnostic and therapeutic dilemma as these are most likely to be malignant but can be benign. We describe a patient with multiple solid renal masses detected incidentally, who underwent open bilateral radical nephrectomy for presumed renal cell carcinoma that proved to be renal oncocytosis.

Case history

A 49-year-old woman underwent computed tomography (CT) examination of the chest and abdomen following a road traffic accident. This revealed bilateral solid renal masses. A subsequent CT examination with intravenous contrast demonstrated one solid enhancing lesion of 26 mm in the upper pole of the right kidney and two solid enhancing lesions of 27 mm each in the left kidney, one of which extended into the renal sinus fat (Figure 1). There was no evidence of vascular invasion or lymphadenopathy. Since these lesions were considered highly suspicious for renal cell carcinoma, the patient was scheduled for an open bilateral partial nephrectomy. A biopsy was not performed because of concerns about the potential for coexisting malignancy in patients with benign change identified on biopsy.

The patient had Stage 4 chronic kidney disease as a result of anti-neutrophil cytoplasmic antibody (cANCA)-positive vasculitis treated 13 years previously but this was in remission on mycophenolate mofetil. Her creatinine concentration was 230 $\mu\text{mol/L}$ (eGFR = 20 mL/min) and she was aware that she would ultimately require renal replacement treatment. She was counselled about the possibility that partial nephrectomy might be inappropriate and therefore that bilateral nephrectomy might be necessary. She was

familiar with the treatment of end-stage renal disease (ESRD) as her husband, father-in-law and sister-in-law had all undergone renal transplantation for ESRD caused by Adult Polycystic Kidney Disease.

On the day of surgery, the kidneys were exposed via a midline incision. Multiple tumours were palpable throughout both kidneys. These were much more extensive and numerous than demonstrated by the CT examination, precluding nephron-sparing partial nephrectomy as previously planned. Bilateral nephrectomy was therefore performed after discussion in theatre with the renal physician responsible for her care. A Tenckhoff catheter was sited for peritoneal dialysis.

Histopathology showed multiple oncocytic tumours present within both kidneys, comprising nests, tubules and solid sheets of cells with abundant eosinophilic cytoplasm and round monomorphic nuclei showing minimal nuclear atypia and no mitotic figures (Figure 2a). Immunohistochemical staining (CK8/18 diffuse +, CK7 focal single cell cytoplasmic +, c-kit diffuse +, AMACR –, Vimentin –, RCC –) confirmed the tumours to be oncocytomas, with no evidence of renal cell carcinoma. Renal parenchyma around the tumours showed multiple microscopic foci of oncocytosis (Figure 2b). In addition, the renal cortex showed moderate chronic damage associated with focal segmental and global glomerulosclerosis and marked glomerulomegaly, indicative of hyperfiltration injury. There was no evidence of active glomerulonephritis or vasculitis.

The patient made an uncomplicated recovery. After a brief period of haemodialysis, she performed automated peritoneal dialysis at home for 8 months before receiving a living donor kidney transplant from her mother.

Discussion

The pathological diagnosis in this case was oncocytosis with multiple oncocytomas. Renal oncocytomas are benign tumours of the renal parenchyma, estimated to account for 3–9% solid renal masses [1, 2]. They are usually solitary

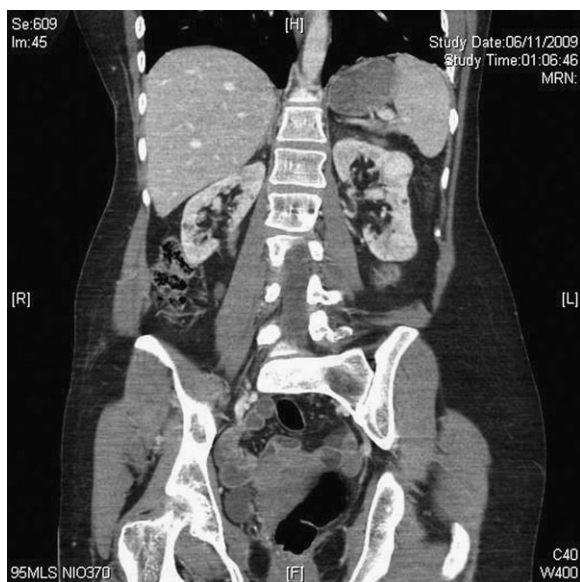


Fig. 1. Coronal CT with intravenous contrast.

lesions but several surgical case series have reported rates of bilaterality or multifocality of 4–5% and 6–13%, respectively [3, 4]. The coexistence of both bilateral and multifocal disease is rare and, as in this case, is sometimes associated with renal oncocytosis, a condition where multiple oncocytomas coexist with oncocytic change throughout the kidney [5]. These oncocytic lesions can coexist with chromophobe renal cell carcinoma. Although sometimes associated with Birt-Hogg-Dube syndrome, the lack of skin lesions or history of spontaneous pneumothorax make this diagnosis unlikely in this patient. One recent case series suggested that renal oncocytosis is a distinct entity from isolated sporadic oncocytomas and chromophobe renal cell carcinoma, with characteristic immunohistochemical and genetic markers [6].

While this patient's existing renal impairment is not typical of patients with an incidentally detected renal mass, her case does illustrate three key clinical dilemmas in this field: (i) the difficulty of distinguishing benign from malignant renal masses on imaging, (ii) the role of biopsy in evaluation of renal masses and (iii) the potential for conservative management of incidentally detected renal masses.

The widespread use of imaging techniques such as CT and magnetic resonance imaging has led to an increase in the incidental detection of asymptomatic solid renal masses, but the best management of such 'incidentalomas' is unclear.

As this case illustrates, it is frequently impossible to distinguish benign from malignant lesions on imaging. One retrospective case series of 143 solitary renal masses diagnosed as renal cell carcinoma by experienced urologists found 16% of such lesions to be benign on histopathological examination [7].

In particular, there is no method of reliably differentiating between renal cell carcinoma and oncocytoma with current imaging techniques. Both appear as solid enhanc-

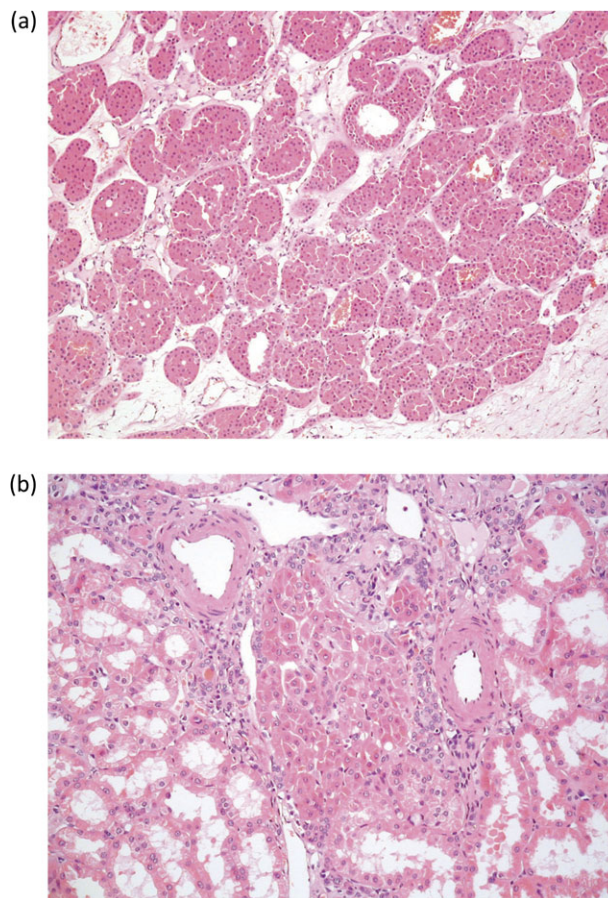


Fig. 2. Histology of the nephrectomy specimens. (a) Part of an oncocytoma (haematoxylin and eosin staining, $\times 10$ object magnification) and (b) oncocytosis in renal cortex (haematoxylin and eosin staining, $\times 20$ object magnification).

ing lesions on CT and features previously thought characteristic of oncocytoma, such as a central stellate scar, have been shown to be unreliable [8]. Some oncocytomas can even show invasive features such as vascular or perinephric invasion [4].

As a result, some patients undergo extensive surgery for asymptomatic lesions which are then found to be benign. A large study of 2935 solid renal masses resected between 1970 and 2000 at a single centre in the US found that 13% were benign, of which 73% were oncocytomas [2]. The proportion of benign lesions increased to 25% for masses <3 cm in diameter.

The reported incidence of bilateral and multifocal disease appears to be similar for oncocytoma and renal cell carcinoma, hence the detection of either characteristic on preoperative imaging is unlikely to be of use in distinguishing the two tumour types [9].

Given the uncertainty of pre-operative diagnosis, percutaneous needle core biopsy may be of use in the evaluation of small renal masses. Until recently, renal core biopsy was rarely performed due to concerns about low sensitivity, immediate complications, such as haemorrhage and the potential long-term risk of needle track seeding. However, with recent improvements in technique and image guidance, rates of minor complications are reported to be

<5% with no cases of needle track seeding since 1994 [10]. The same review, which reviewed papers published since 2001, found the accuracy of renal mass biopsy (defined as the percentage of biopsies with sufficient material for analysis in which the biopsy diagnosis was not indeterminate, false negative or false positive) to be 88% compared to final pathological diagnosis.

However, most such studies of percutaneous biopsy in the investigation of small renal masses are retrospective case series reviewing a highly selected population of patients who underwent biopsy rather than primary resection, with only a proportion of biopsy diagnoses evaluated against definitive histopathology on resected lesions.

Furthermore, oncocytomas present a particular challenge in that certain renal cell carcinomas (such as the chromophobe subtype) may be difficult to distinguish from oncocytoma on conventional histology, while in some cases, oncocytic elements may coexist with renal cell carcinoma [3]. A biopsy suggesting oncocytoma may therefore be insufficient to rule out malignant disease, diminishing the negative predictive value of biopsy and potentially resulting in greater diagnostic uncertainty. Markers such as the S100A1 protein have been proposed as a method for differentiating chromophobe renal cell carcinoma from oncocytoma [11].

Use of percutaneous biopsy to obtain a pre-operative histological diagnosis of incidentally detected small renal masses has increased in recent years, as the value of aggressive intervention in such patients has been challenged. Data from the US SEER cancer registry programme suggest a rise in renal cancer mortality over the last few decades despite increased detection of small tumours, which challenges the prevailing assumption that the early discovery of such lesions presents an opportunity for treatment of less advanced disease and therefore better outcomes [12]. Recent data demonstrating the adverse effects of radical nephrectomy for small renal tumours on long-term renal function have further underlined the need to avoid radical resection [13]. Partial nephrectomy is now the preferred option in tumours <4 cm. In the case of small tumours or patients who are elderly or have significant co-morbidity, monitoring may be all that is necessary, thereby avoiding unnecessary surgical intervention. Other, less invasive treatments for small renal lesions such as radiofrequency ablation may be appropriate in certain situations.

Although no randomized controlled trials of the management of this problem have been carried out, a 2008 meta-analysis of 286 'expectantly managed' localized renal masses reported a mean growth rate of 0.28 cm/year and only three cases (1% of masses followed) of metastasis, over a mean follow-up of 34 months [14]. This suggests that watchful waiting, with regular clinical and radiological review, is a justifiable management option to offer patients with small renal masses, particularly those unfit or unwilling to undergo surgery. However, it is important to note that most of the available studies on expectant management relate to patients who are older or who have multiple co-morbidities, for whom long-term avoidance of cancer progression is less of an issue. Their value is also limited by the relatively short duration of follow-up. Thus, the appropri-

ateness of expectant management of young and otherwise healthy patients remains an open question because of uncertainty about the risk of disease progression. The one group for whom good evidence for this approach exists is patients with Von Hippel-Lindau disease, 50% of whom will develop renal cell carcinoma. In these patients, there have been no reports of metastatic disease in the world literature for any tumour <2.9 cm, so renal masses can safely be observed until their tumour reaches 2.5 cm, at which stage they should be removed [15].

In this case, the decision to proceed to bilateral nephrectomy was made in the operating theatre by the surgeon and the renal physician caring for the patient on the basis that (i) malignancy in the failed kidneys could not be excluded and (ii) end-stage renal disease was inevitable and its advent likely to be accelerated by the multiple space-occupying lesions. Removal of the kidneys and establishing the patient on dialysis allowed the possibility of cure and then renal transplantation. She was told the results of the histology after the surgery and that the tumours, although space-occupying, were benign and agreed that the decision was appropriate.

Although our patient's existing chronic renal failure meant that bilateral nephrectomy was an appropriate option, in patients with normal renal function, a more conservative approach to the incidentally detected renal mass may often be justifiable.

Conclusions

The bilateral multifocal lesions in this case proved to be oncocytosis with multiple oncocytomas. While this particular condition is rare, renal oncocytoma is a common cause of a small renal mass and continues to present a diagnostic dilemma for clinicians, given the limitations of imaging in distinguishing benign and malignant lesions and the potential morbidity associated with radical or partial nephrectomy.

Teaching points

- (1) Increasing use of abdominal imaging in recent decades has led to more frequent detection of small renal masses in asymptomatic patients. Management depends on the size and position of the lesion as well as the age and general health of the patient, necessitating careful discussion about the options and possible outcomes.
- (2) Imaging alone is insufficient for distinguishing benign from malignant small renal masses in some situations, resulting in some surgical resections being performed for lesions ultimately found to be benign. Patients need to be warned of the risk of the risk of this preoperatively, especially when small lesions are to be resected.
- (3) Percutaneous renal biopsy may be safer and more informative than previously thought but information on this issue is limited.
- (4) Many small renal masses grow slowly and have a low risk of metastasis, so 'watchful waiting' may be an

option in some patients, such as the elderly and those with significant co-morbidity.

Acknowledgements. The authors would like to thank Nigel Cowan for helpful comments on the manuscript.

Conflict of interest statement. The authors declare no conflicts of interest. The results presented in this manuscript have not been published previously in whole or part. All authors have read and approved the manuscript and have contributed significantly to the work.

References

- Romis L, Cindolo L, Patard JJ *et al.* Frequency, clinical presentation and evolution of renal oncocytomas: multicentric experience from a European database. *Eur Urol* 2004; 45: 53–57
- Frank I, Blute ML, Cheville JC *et al.* Solid renal tumors: an analysis of pathological features related to tumor size. *J Urol* 2003; 170: 2217–2220
- Dechet CB, Bostwick DG, Blute ML *et al.* Renal oncocytoma: multifocality, bilateralism, metachronous tumor development and co-existent renal cell carcinoma. *J Urol* 1999; 162: 40–42
- Perez-Ordóñez B, Hamed G, Campbell S *et al.* Renal oncocytoma: a clinicopathologic study of 70 cases. *Am J Surg Pathol* 1997; 21: 871–883
- Tickoo SK, Reuter VE, Amin MB *et al.* Renal oncocytosis: a morphologic study of fourteen cases. *Am J Surg Pathol* 1999; 23: 1094–1101
- Gobbo S, Eble JN, Delahunt B *et al.* Renal cell neoplasms of oncocytosis have distinct morphologic, immunohistochemical, and cytogenetic profiles. *Am J Surg Pathol* 2010; 34: 620–626
- Kutikov A, Fossett LK, Ramchandani P *et al.* Incidence of benign pathologic findings at partial nephrectomy for solitary renal mass presumed to be renal cell carcinoma on preoperative imaging. *Urology* 2006; 68: 737–740
- Choudhary S, Rajesh A, Mayer NJ *et al.* Renal oncocytoma: CT features cannot reliably distinguish oncocytoma from other renal neoplasms. *Clin Radiol* 2009; 64: 517–522
- Grimaldi G, Reuter V, Russo P. Bilateral non-familial renal cell carcinoma. *Ann Surg Oncol* 1998; 5: 548–552
- Lane BR, Samplaski MK, Herts BR *et al.* Renal mass biopsy—a renaissance? *J Urol* 2008; 179: 20–27
- Rocca PC, Brunelli M, Gobbo S *et al.* Diagnostic utility of S100A1 expression in renal cell neoplasms: an immunohistochemical and quantitative RT-PCR study. *Mod Pathol* 2007; 20: 722–728
- Hollingsworth JM, Miller DC, Daignault S *et al.* Rising incidence of small renal masses: a need to reassess treatment effect. *J Natl Cancer Inst* 2006; 98: 1331–1334
- Huang WC, Levey AS, Serio AM *et al.* Chronic kidney disease after nephrectomy in patients with renal cortical tumours: a retrospective cohort study. *Lancet Oncol* 2006; 7: 735–740
- Chawla SN, Crispen PL, Hanlon AL *et al.* The natural history of observed enhancing renal masses: meta-analysis and review of the world literature. *J Urol* 2006; 175: 425–431
- Turner KJ, Huson SM, Moore N *et al.* Von Hippel-Lindau disease: renal tumours less than 3cm can metastasize. *J Urol* 2001; 165: 1207

Received for publication: 31.1.11; Accepted in revised form: 8.2.11