

Endoscopic Ganglionectomy of the Extensor Digitorum Longus Tendon: An Extraganglionic Approach



Chi Kit Chan, and Tun Hing Lui, M.B.B.S (HK), F.R.C.S.Ed., F.H.K.A.M., F.H.K.C.O.S.

Abstract: Ganglion is the most common soft tissue mass in the foot and can be painful and affect comfort wearing shoes. The usual treatment of a ganglion is conservative: careful neglect, manual rupture, or aspiration. When the lesion is recurrent or painful, surgical excision is recommended. The purpose of this Technical Note is to describe the extraganglionic approach of endoscopic ganglionectomy of the extensor digitorum longus tendon. This surgery has the advantage of being minimally invasive and having better cosmetic result, with less surgical trauma to the soft tissue. **Level of Evidence:** Level 1: foot and ankle; Level 2: other (ganglion).

Introduction

The ganglion is a common cystic lesion that has a relatively thin wall with mucinous content.¹ Eleven percent of all ganglia around the body occur in the foot and ankle region, and the ganglion is the most common soft tissue mass in the foot.^{1,2} Ganglia of the foot often make wearing shoes difficult and painful because of their relatively large size.¹ The ganglia can also lead to stress on soft tissues, and pain, including compression on abutting local nerves, leads to paresthesia.³ These myxoid cystic lesions usually occur in areas of mechanical stress or trauma and can arise from the joint, periosteum, muscle, tendon sheath, and nerve.^{1,3} Ganglion from the tendon sheath generally has a higher recurrence rate after excision.¹ It is probable that the skip lesion or satellite mass can occur, considering the mass spreads along the tendon. Failure of identification and removal of the satellite mass could

lead to recurrence of the ganglion.¹ The usual treatment of a ganglion is conservative: careful neglect, manual rupture, or aspiration. When the lesion is recurrent or painful, surgical excision is recommended.¹ Techniques of endoscopic ganglionectomy of the foot and ankle have been reported.^{4,5} In this report, we describe the technical details of the extraganglionic approach of endoscopic ganglionectomy of the extensor digitorum longus tendon. It is indicated for symptomatic ganglia arising from the extensor digitorum longus tendon at the foot dorsum that is recalcitrant to conservative treatment. It is contraindicated when there is other pathology that demands open surgery or when the ganglion arises from underlying joints (Table 1). Intratendinous ganglion of the extensor digitorum longus is not a contraindication.^{3,6}

Technique

Preoperative Assessment

Preoperative magnetic resonance imaging is important to study the anatomical relationship between the ganglion and the extensor tendons and underlying joints, the presence of any associated pathology or satellite lesions of the tendon, and whether the ganglion is multiloculated or not.¹ In cases of ganglion cysts originating from the tendon sheath, careful attention should be paid to locate satellite masses to avoid recurrence.¹

Patient Positioning and Portal Placement

The patient is in a supine position with a thigh tourniquet applied to provide a bloodless operative field. A

From the Department of Orthopaedics and Traumatology, North District Hospital, Sheung Shui, NT Hong Kong SAR, China (T.H.L.) and Yan Chai Hospital, Hong Kong SAR, China (C.K.C.)

Full ICMJE author disclosure forms are available for this article online, as supplementary material.

Received April 10, 2021; accepted May 14, 2021.

Address correspondence to Tun Hing Lui, M.B.B.S (HK), F.R.C.S.Ed., F.H.K.A.M., F.H.K.C.O.S., Department of Orthopaedics and Traumatology, North District Hospital, 9 Po Kin Rd., Sheung Shui, NT Hong Kong SAR, China. E-mail: luithderek@yahoo.co.uk

© 2021 THE AUTHORS. Published by Elsevier Inc. on behalf of the Arthroscopy Association of North America. This is an open access article under the CC BY-NC-ND license (<http://creativecommons.org/licenses/by-nc-nd/4.0/>). 2212-6287/21568

<https://doi.org/10.1016/j.eats.2021.05.002>

Table 1. Indications and Contraindications of the Endoscopic Ganglionectomy of the Extensor Digitorum Longus Tendon: An Extraganglionic Approach

Indications	Contraindications
1. Symptomatic ganglia arising from the extensor digitorum longus tendon at the foot dorsum recalcitrant to conservative treatment.	1. There is other pathology that demands open surgery 2. The ganglion arises from underlying joints.

2.7-mm 30° arthroscope (Henke Sass Wolf, Tuttlingen, Germany) is used for this procedure. Fluid inflow is driven by gravity, and arthro-pump is not used.

The endoscopic procedure is performed via the proximal and distal portals, which are at the proximal lateral and distal corners of the ganglion, respectively (Fig 1). Three- to four-millimeter skin incisions are made at the portal sites. The subcutaneous tissue is bluntly dissected with a haemostat down to the ganglion. A plane is carefully developed between the ganglion and the overlying soft tissue by the haemostat, and this plane is the initial endoscopic working area.

Fenestration of the Ganglion Sac and Drainage of the Mucinous Content

The distal portal is the viewing portal, and the proximal portal is the working portal. Fenestration of the superficial wall of the ganglion is performed with an arthroscopic shaver (Dyonics, Smith and Nephew, Andover, MA) (Fig 2). The mucinous content of the ganglion is then drained out and removed by the suction of the shaver (Fig 3).

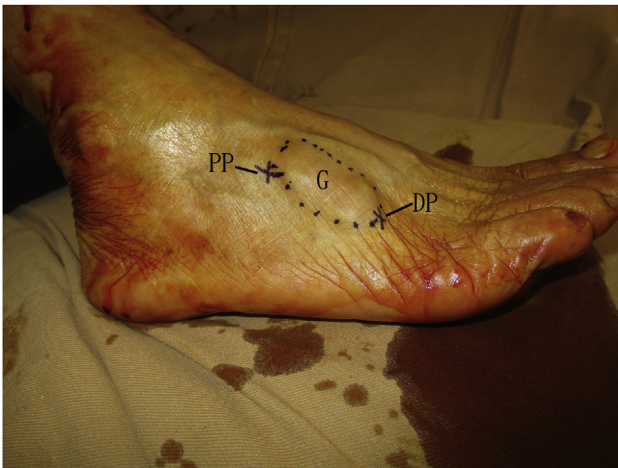

Fig 1. Endoscopic ganglionectomy of the extensor digitorum longus tendon of the right foot: an extraganglionic approach. The patient is in a supine position. The endoscopic procedure is performed via the proximal and distal portals, which are at the proximal lateral and distal corners of the ganglion, respectively. DP, distal portal; G, ganglion; PP, proximal portal.

Resection of Proximal Part of the Ganglion Sac, Exposure of the Extensor Tendons, and Extensor Digitorum Brevis Muscle

The distal portal is the viewing portal, and the proximal portal is the working portal. The proximal part of the ganglion sac is resected by the shaver with caution to preserve the extensor tendons and the extensor digitorum brevis muscle (Fig 4).

Resection of Distal Part of the Ganglion Sac

The proximal portal is the viewing portal, and the distal portal is the working portal. The distal part of the ganglion sac is resected by the shaver with caution to preserve the extensor tendons (Fig 5).

Postoperative Management

After the procedure, the portal incisions are closed with simple sutures, and compression dressing is applied for 2-4 weeks (Fig 6, Video 1, Table 2).

Discussion

For this reported technique, the proximal portal is located at the proximal lateral corner rather than the proximal end of the ganglion in order to avoid hindrance of instrument mobility of the proximal portal by the ankle and distal leg. The endoscopic working space is just superficial to the ganglion, and the instrumentation is working toward the ganglion, and injury to branches of the superficial peroneal nerve is minimized, as the nerve branches are superficial to the working space. However, if the ganglion extends medially to the level of first intermetatarsal space, resection of the medial edge of the ganglion may injure the deep peroneal nerve. Sometimes, the cutaneous nerve branches, such as the sural nerve or superficial peroneal nerve may attach to the ganglion cyst wall.¹ In these cases, endoscopic dissection of the nerve branches from the cyst should be performed before endoscopic ganglionectomy. If endoscopic nerve dissection is impossible, the part of the ganglion cyst wall can be left untouched, or the endoscopic procedure is converted to open surgery.

This endoscopic technique has the potential advantages of small incisions and better cosmetic result, minimal dissection, reduced risk of peritendinous fibrosis, and reduced risk of superficial peroneal nerve injury. The potential risks of this technique

Fig 2. Endoscopic ganglionectomy of the extensor digitorum longus tendon of the right foot: an extraganglionic approach. The patient is in a supine position. (A) The distal portal is the viewing portal and the proximal portal is the working portal. (B) Fenestration of the superficial wall of the ganglion is performed with an arthroscopic shaver. AS, arthroscopic shaver; DP, distal portal; G, ganglion; PP, proximal portal.

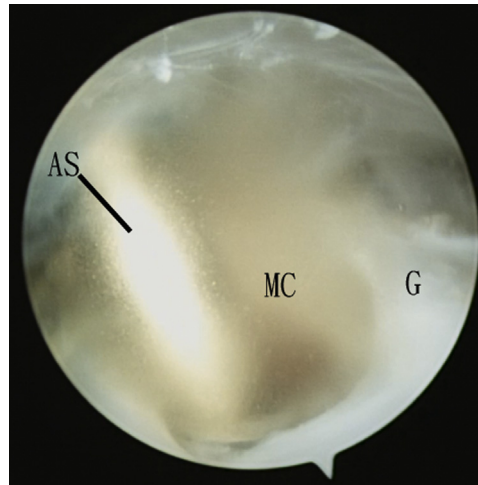
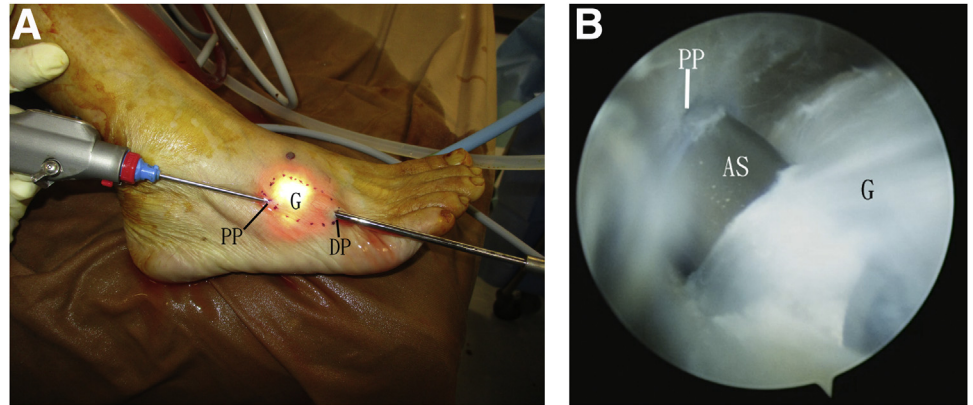


Fig 3. Endoscopic ganglionectomy of the extensor digitorum longus tendon of the right foot: an extraganglionic approach. The patient is in a supine position. The distal portal is the viewing portal, and the proximal portal is the working portal. The mucinous content of the ganglion is then drained out and removed by the suction of the shaver. AS, arthroscopic shaver; G, ganglion; MC, mucinous content of the ganglion.

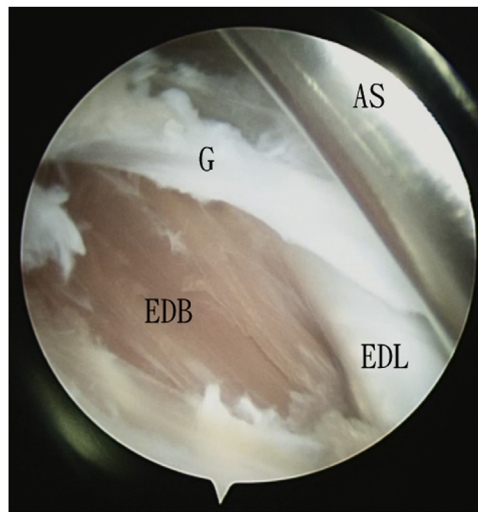


Fig 4. Endoscopic ganglionectomy of the extensor digitorum longus tendon of the right foot: an extraganglionic approach. The patient is in a supine position. The distal portal is the viewing portal, and the proximal portal is the working portal. The proximal part of the ganglion sac is resected by the shaver with caution to preserve the extensor tendons and the extensor digitorum brevis muscle. AS, arthroscopic shaver; EDL, extensor digitorum longus tendon; EDB, extensor digitorum brevis muscle; G, ganglion.

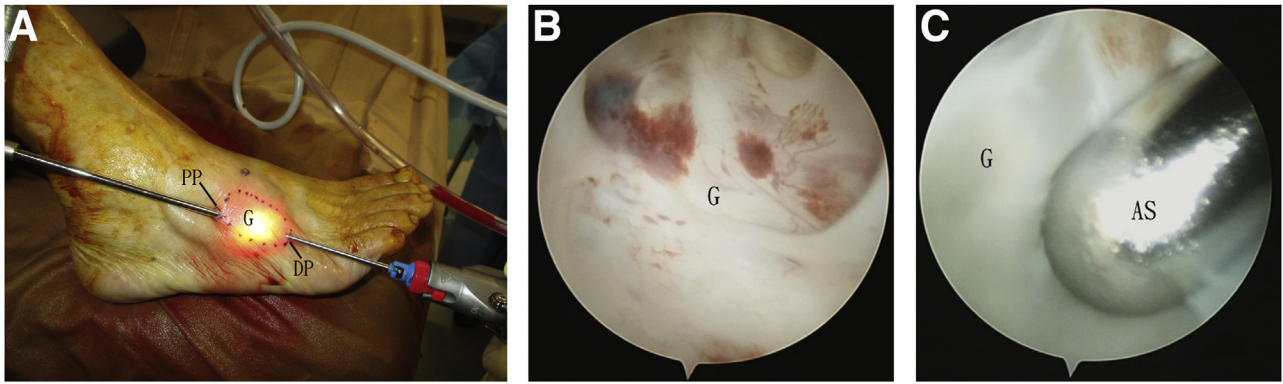


Fig 5. Endoscopic ganglionectomy of the extensor digitorum longus tendon of the right foot: an extraganglionic approach. The patient is in a supine position. (A) The proximal portal is the viewing portal, and the distal portal is the working portal. (B) Endoscopic view of the distal end of the ganglion sac. (C) The distal part of the ganglion sac is resected by the shaver. AS, arthroscopic shaver; DP, distal portal; G, ganglion; PP, proximal portal.

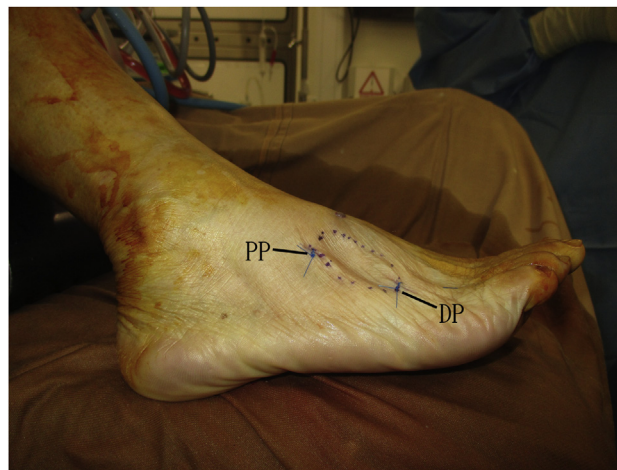


Fig 6. Endoscopic ganglionectomy of the extensor digitorum longus tendon of the right foot: an extraganglionic approach. The patient is in a supine position. The portal incisions are closed with simple sutures. DP, distal portal; PP, proximal portal.

Table 2. Pearls and Pitfalls of the Endoscopic Ganglionectomy of the Extensor Digitorum Longus Tendon: An Extraganglionic Approach

Pearls	Pitfalls
<ol style="list-style-type: none"> 1. The proximal portal is located at the proximal lateral corner rather than the proximal end of the ganglion in order to avoid hindrance of instrument mobility of the proximal portal by the ankle and distal leg. 2. The endoscopic working space is just superficial to the ganglion, the instrumentation is working toward the ganglion, and injury to branches of the superficial peroneal nerve is minimized as the nerve branches are superficial to the working space. 	<ol style="list-style-type: none"> 1. The branches of the superficial peroneal nerve may be injured if the shaver is working in the subcutaneous tissue. 2. If the ganglion extends medially to the level of first intermetatarsal space, resection of the medial edge of the ganglion may injure the deep peroneal nerve.

Table 3. Advantages and Risks of the Endoscopic Ganglionectomy of the Extensor Digitorum Longus Tendon: An Extraganglionic Approach

Advantages	Risks
1. Small incisions and better cosmetic result	1. Injury to the injury to the branches of the superficial peroneal nerve
2. Minimal dissection and reduced risk of peritendinous fibrosis	2. Injury to the deep peroneal nerve
3. Reduced risk of superficial peroneal nerve injury.	3. Injury to the sural nerve
	4. Injury to the extensor tendons
	5. Injury to the extensor digitorum brevis muscle

include injury to the branches of the superficial peroneal nerve, deep peroneal nerve, sural nerve, extensor tendons, or the extensor digitorum brevis muscle (Table 3). This procedure is not technically demanding and can be attempted by averaged foot and ankle arthroscopists.

References

- Ahn JH, Choy WS, Kim HY. Operative treatment for ganglion cysts of the foot and ankle. *J Foot Ankle Surg* 2010;49:442-445.
- Kirby EJ, Shereff MJ, Lewis MM. Soft tissue tumors and tumor-like lesions of the foot, an analysis of 83 cases. *J Bone Joint Surg Am* 1989;71:621-626.
- Xu H, Gazes MI, Jariwala T, Gambardella PT. Intra-tendinous ganglion cyst of the extensor digitorum longus: A case report. *J Am Podiatr Med Assoc* 2020;110:46-49.
- Lui TH. Arthroscopic ganglionectomy of the foot and ankle. *Knee Surg Sports Traumatol Arthrosc* 2014;22:1693-1700.
- Lui TH. Extensor tendoscopy of the ankle. *J Foot Ankle Surg* 2011;17:e1-e6.
- Robinson C, Kocialkowski C, Bhosale A, Pillai A. Intra-tendinous ganglion cyst of the extensor digitorum longus tendon: A case report. *Foot (Edinb)* 2016;27:46-49.