

Does maternal autoantibody that transfer to newborn cause disease?

Toshio Ichiwata¹, Manabu Ishida¹, Yuko Itoh², Nobutaka Kitamura² & Koh Nakata² 

¹Hachioji Medical Center, Tokyo Medical University, Tokyo, Japan.

²Bioscience Medical Research Center, Niigata University Medical and Dental Hospital, Niigata, Japan.

Keywords

Autoimmune pulmonary alveolar proteinosis, granulocyte-macrophage colony-stimulating factor autoantibody, pregnancy, childbirth.

Correspondence

Koh Nakata, Clinical and Translational Research Center, Niigata University Medical and Dental Hospital, 1-754 Asahimachi-dori, Niigata 951-8520, Japan. E-mail: radical@med.niigata-u.ac.jp

Received: 13 August 2019; Revised: 31 August 2019; Accepted: 3 September 2019; Associate Editor: Arata Azuma.

Respirology Case Reports, 7 (9), 2019, e00494

doi: 10.1002/rcr2.494

Abstract

Autoimmune pulmonary alveolar proteinosis (aPAP) is associated with excess amount of granulocyte-macrophage colony-stimulating factor (GM-CSF) autoantibody (GMAb) in the lung and blood. We experienced a female case with severe aPAP who could continue her pregnancy under home oxygen therapy and delivered a newborn by caesarean section. Maternal serum GMAb remained high level for up to one year after the delivery, although aPAP entered remission by whole lung lavage. While the newborn oxygen saturation as well as serum Krebs von den Lungen-6 and surfactant protein-D levels had been normal until one year. As GMAb likely transfer to the newborn and might cause the same disease, we carefully monitored both maternal and the newborn serum GMAb levels after the birth for up to one year. We confirmed that GMAb passively transferred to the newborn circulation but rapidly decreased exponentially to the cut-off level. It is suggested that this rapid decrease might prevent the newborn from developing aPAP.

Introduction

Pulmonary alveolar proteinosis (PAP) is a rare lung disease characterized by abnormal surfactant accumulation in the terminal respiratory tracts [1]. Aetiologically PAP has been classified into three disease types: hereditary, secondary, and autoimmune PAP. Autoimmune PAP (aPAP), consisting 90% of all PAP cases, is caused by excess production of granulocyte-macrophage colony-stimulating factor (GM-CSF) autoantibody (GMAb) [1]. GMAb interferes with GM-CSF signalling in alveolar macrophages, causing maturation arrest and dysfunction and thus impairing surfactant catabolism. Recently, we reported that the incidence of aPAP was estimated to be 1.65 per million [2].

To date, no cases of pregnancy or delivery have been reported in aPAP. Theoretically, as maternal IgG type GMAb can move through placenta into the blood of foetus, so it likely causes PAP. Here, we report a case of newborn delivered from a mother who had severe aPAP with high concentration of GMAb in the blood.

Case Report

Inherently healthy, an asymptomatic 19-year-old woman showed an abnormal chest shadow on physical examination in 2001. Thereafter, she was diagnosed with aPAP by video-assisted thoracic surgery and serological test at a local hospital. For several years she was followed up and remained asymptomatic until she became aware of shortness of breath at the end of 2014. Peripheral capillary oxygen saturation (SpO₂), Krebs von den Lungen-6 (KL-6, normal range: <500 U/mL), Surfactant protein-D (SP-D; normal range <110 ng/mL) were 90%, 7704 U/mL, and 455 ng/mL, respectively. She was referred to Hachioji Medical Center where she underwent six times whole lung lavages (WLL) repeatedly during March 2015 to May 2017. Her aPAP condition recurred with remission and exacerbation during the period, and she became pregnant in July 2017. She continued her pregnancy in consultation with her treating doctor who decided to avoid WLL because of its adverse effects on the foetus. However, her hypoxaemia became progressively worse with partial pressure of oxygen (PaO₂) under 60 mmHg at

room air, and thus, she was forced to receive home oxygen therapy (HOT; Fig. 1) to keep oxygen saturation more than 88%. At 36-week gestation, the patient delivered a girl by caesarean section.

Hypoxaemia of the mother with PaO₂ at 56.3 mmHg (room air) just before the delivery did not improve but further exacerbated to the level of 39.3 mmHg within one week. Therefore, she underwent three times WLL that improved her hypoxaemia from SpO₂ level at 88% (3 L O₂ nasal cannula) to 97% (room air) within a month. As aPAP entered remission, HOT was discontinued. The remission has continued until now without elevation in the serum KL-6 and SP-D level [3,4]. On the other hand, the newborn did not show hypoxaemia after delivery with stable SpO₂ ranging from 98% to 100% (Fig. 1, red bar). As both serum KL-6 and SP-D have kept within normal limit (68–125 U/mL and 49.5–70.8 ng/mL, respectively),

we consider that the newborn has developed normally so far. These data indicated that the newborn did not develop aPAP.

The serum GMAb level in the mother had been as high as 150 µg/mL increasing slightly after the delivery according to the increase in the total IgG, peaked at 3 months, and then gradually decrease to the baseline level (Fig. 2). In contrast, the serum GMAb level in the newborn rapidly decreased exponentially to the level under the cut-off level (1.65 µg/mL), whereas the serum IgG level also decreased by 3 months after the birth and then reached a steady state.

Discussion

As the ratio of serum GMAb to the total IgG (0.18) in the newborn was similar to the maternal ratio (0.15), it was

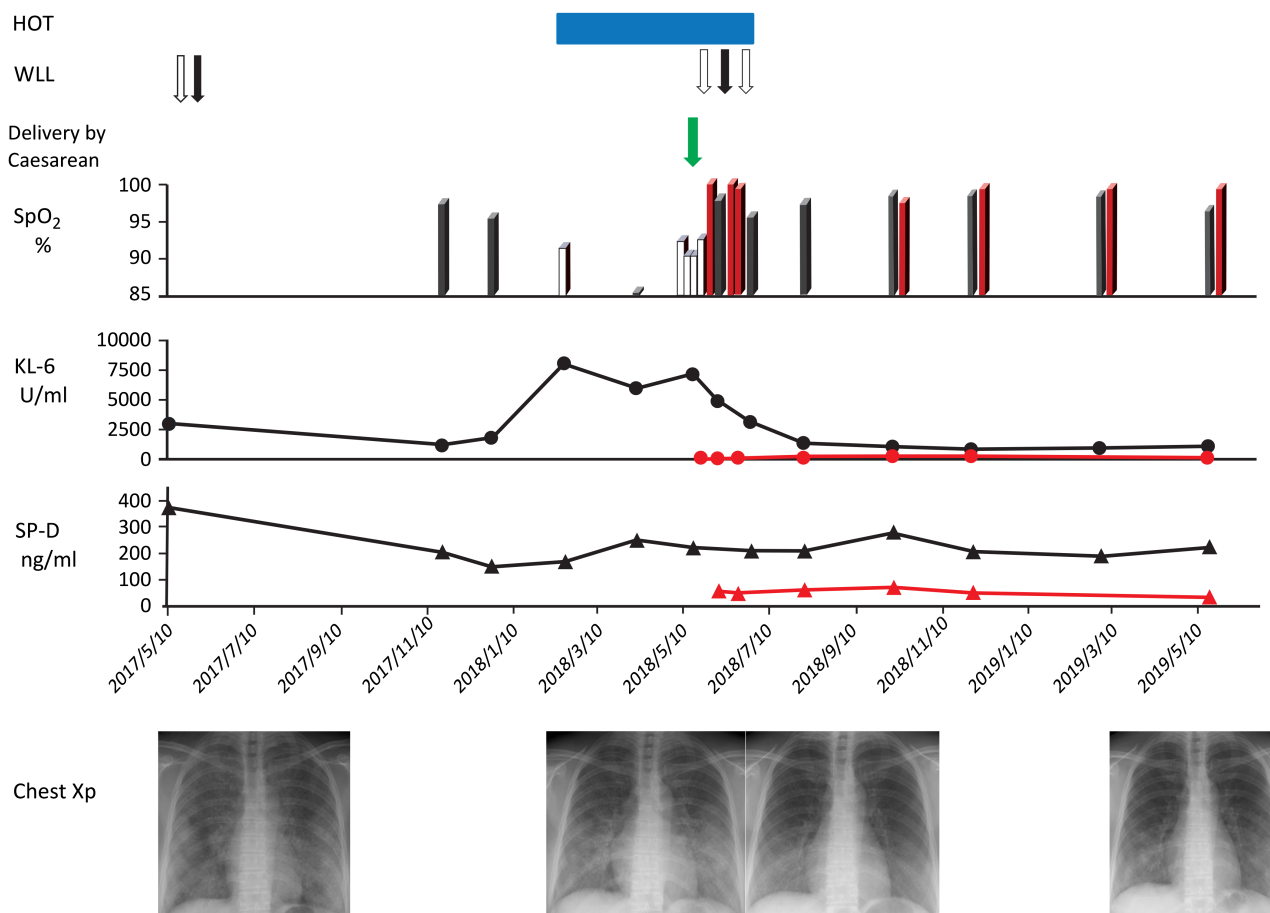


Figure 1. Clinical course of a pregnant woman with autoimmune pulmonary alveolar proteinosis. The blue bar indicates the period for home oxygen therapy. Whole lung lavage is indicated as open (the left lung) and closed (the right lung) arrow. The upper column indicates peripheral capillary oxygen saturation (SpO₂) of the mother under room air (solid bar) or under 3 L/min oxygen through nasal cannula (open bar), and the newborn under room air (red bar). The middle column indicates the serum levels of Krebs von den Lungen-6 (KL-6). Surfactant protein-D (SP-D) is shown at the lower column. Chest X-ray images are presented at the bottom.

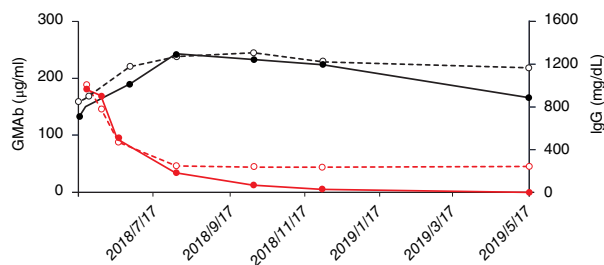


Figure 2. Course of serum granulocyte-macrophage colony-stimulating factor (GM-CSF) autoantibody (GMAB; solid line) and total IgG (dotted line) concentration in mother (black line) and newborn (red line). The date of birth was shown as green arrow. The concentrations were monitored since 17 May 2018 to 17 May 2019.

rational to consider that maternal GMAB passed through placenta with total IgG and entered newborn circulation. It was noteworthy that newborn serum GMAB level rapidly reduced exponentially, suggesting that there was no GMAB production system in the newborn. Sakagami et al. reported that a passive transfer of the patient-derived GMAB reproduced PAP in non-human primates [5]. In this case, they repeated the injection of GMAB maintaining serum levels greater than 40 µg/mL for up to 11 months. In contrast, the present case revealed that maternal GMAB passively transferred to the newborn circulation rapidly and exponentially decreased to the cut-off level. We suspect that this rapid decrease might prevent the newborn from developing aPAP. When GMAB binds with intrinsic GM-CSF that might be present in the newborn circulation forming high-molecular-weight immune complexes, such complexes should be rapidly degraded in an Fc receptor-dependent manner [6]. Thus, this mechanism might promote the degradation of circulating maternal GMAB in the newborn.

Disclosure Statement

Appropriate written informed consent was obtained for publication of this case report and accompanying images.

Acknowledgments

We appreciate Ms Marie Mori's help for preparing this manuscript. Grant-in-Aid for Scientific Research, Category B supported this work in part with grants from categories 15H04829 (K. Nakata) and 15K15321 (K. Nakata).

References

1. Trapnell BC, Whitsett JA, and Nakata K. 2003. Pulmonary alveolar proteinosis. *N. Engl. J. Med.* 349:2527–2539.
2. Kitamura N, Ohkouchi S, Tazawa R, et al. 2019. Incidence of autoimmune pulmonary alveolar proteinosis estimated using Poisson distribution. *ERJ Open Res.* 18:00190–00201.
3. Takahashi T, Munakata M, Suzuki I, et al. 1998. Serum and bronchoalveolar fluid KL-6 levels in patients with pulmonary alveolar proteinosis. *Am. J. Respir. Crit. Care Med.* 158: 1294–1298.
4. Nagae H, Takahashi H, Kuroki Y, et al. 1997. Enzyme-linked immunosorbent assay using f(ab)₂ fragment for the detection of human pulmonary surfactant protein D in sera. *Clin. Chim. Acta* 266:157–171.
5. Sakagami T, Beck D, Uchida K, et al. 2010. Patient-derived granulocyte macrophage colony-stimulating factor autoantibodies reproduce pulmonary alveolar proteinosis in nonhuman primates. *Am. J. Respir. Crit. Care Med.* 182:49–61.
6. Piccoli L, Campo I, Fregni CS, et al. 2015. Neutralization and clearance of GM-CSF by autoantibodies in pulmonary alveolar proteinosis. *Nat. Commun.* 6:7375.