

RESEARCH ARTICLE

Hereditary neuralgic amyotrophy in childhood caused by duplication within the *SEPT9* gene: A family study

Katharina Neubauer¹ | Doris Boeckelmann¹ | Udo Koehler² | Julia Kracht³ |
Janbernd Kirschner⁴ | Manuela Pendziwiat⁵ | Barbara Zieger¹

¹Division of Pediatric Hematology and Oncology, Department of Pediatrics and Adolescent Medicine, University Medical Center, Medical Faculty, University of Freiburg, Freiburg, Germany

²Department of Medical Genetics, MGZ - Medical Genetics Center, Munich, Germany

³Division of General Pediatrics, Department of Pediatrics and Adolescent Medicine, University Medical Center, Medical Faculty, University of Freiburg, Freiburg, Germany

⁴Department of Neuropediatrics and Muscle Disorders, University Medical Center, Faculty of Medicine, University of Freiburg, Germany

⁵Department of Neuropediatrics, Christian-Albrechts-University of Kiel and University Medical Center Schleswig-Holstein, Kiel, Germany

Correspondence

Barbara Zieger, Department of Pediatrics and Adolescent Medicine, Division of Pediatric Hematology and Oncology, Medical Center, Faculty of Medicine, University of Freiburg, Mathildenstraße 1, 79106 Freiburg, Germany. Email: barbara.zieger@uniklinik-freiburg.de

Funding information

Deutsche Forschungsgemeinschaft DFG, Grant/Award Numbers: ZI 486/4-1, ZI 486/8-1

Abstract

Hereditary neuralgic amyotrophy (HNA) is an autosomal dominant disorder associated with episodic, recurrent, and painful neuropathies affecting the nerves of the brachial plexus. In this study, we report on a family of Lebanese descent with HNA onset in early childhood. The affected family members presented with platelet dysfunction. Platelet aggregation was reduced after stimulation with the agonists ADP and epinephrine in all affected family members. Flow cytometric analyses revealed impaired platelet δ -secretion. The index patient and one brother suffered from kidney cysts. Molecular genetic analysis revealed a heterozygous duplication of exon 2 within the *septin 9* (*SEPT9*) gene in all the affected family members. Such a young child with HNA (aged 2 years) caused by *SEPT9* duplication has not been described so far.

KEYWORDS

early onset, hereditary neuralgic amyotrophy, pain attack, septins, septin 9

1 | INTRODUCTION

Neuralgic amyotrophy (NA), also known as brachial neuritis or Parsonage-Turner syndrome, is a neuropathy affecting mainly the upper brachial plexus (Parsonage & Turner, 1948). NA is clinically characterized by an acute onset of severe pain usually in the shoulder or arm region, followed by weakness and atrophy of the affected muscles and occasional sensory impairment. The typically deep, sharp or burning pain lasts for up to several weeks. Most patients experience a full recovery within weeks to months, but residual weakness and sensory deficits of the affected limbs or muscles can persist (Kuhlenbaumer, Stogbauer, Timmerman, & De Jonghe, 2000;

van Alfen & van Engelen, 2006). Attacks are normally unilateral and monophasic, but they can be bilateral and recurrent. NA can be idiopathic (INA) or hereditary in autosomal dominant fashion (HNA), with few phenotypical variations between the two. Patients with INA usually suffer from only one attack in life, whereas attacks recur up to 20 times in life in HNA. In fact, HNA is a disorder with a wide spectrum of clinical manifestations. Some HNA patients display dysmorphic features such as hypotelorism, epicanthal folds, and occasional cleft palate (Jeannet, Watts, Bird, & Chance, 2001; Laccione et al., 2008).

Compared to INA, HNA is the much rarer form. The estimated annual prevalence of total NA varies extremely in the literature from

1 to 3 cases per 100,000 people per year (Beghi, Kurland, Mulder, & Nicolosi, 1985; MacDonald, Cockerell, Sander, & Shorvon, 2000) to an incidence rate of 1 per 1,000 (van Alfen et al., 2015), confirming that NA may be often misdiagnosed. Mean age of NA onset has been described to be in the fourth or fifth decade of life (van Alfen & van Engelen, 2006). Unlike HNA, early onset of INA has been reported (Al-Ghamdi & Ghosh, 2018; Host & Skov, 2010; Jain, Bhatt, Rai, & Bhan, 2014; van Alfen, Schuurung, van Engelen, Rotteveel, & Gabreels, 2000; van Alfen & van Engelen, 2006).

Treatment with corticosteroids in the acute phase of NA seems to relieve pain and improve the course and outcome of the attacks (van Alfen, van Engelen, & Hughes, 2009; van Eijk et al., 2009).

Whereas INA is believed to be immune mediated (van Alfen et al., 2000), HNA has been linked in some families to mutations in the *septin 9* (*SEPT9*) gene on chromosome 17q25 (Meulemann et al., 1999; Pellegrino et al., 1997; Stogbauer et al., 1997; Watts, O'Brian, & Chance, 2002; Wehnert et al., 1997). Septins are a family of 13 cytoskeletal proteins that form higher order structures like nonpolar filaments and are involved in multiple biological processes including formation of the cytoskeleton, cell motility, and polarity (Hall & Russell, 2004; Kinoshita, 2003; Trimble, 1999). Septins have been implicated in exocytosis (Tokhtaeva et al., 2015). Several septins have been co-purified with the exocyst complex (Hsu et al., 1998) which is essential for vesicle targeting and neurite outgrowth (Vega & Hsu, 2001). A patient with a homozygous *SEPT5* deletion and impaired platelet secretion has been described (Bartsch et al., 2011).

In this study, we investigated an HNA-affected family with first onset in childhood. Due to a possible relation between septin mutations and platelet disorders, we analyzed their platelet secretion. HNA caused by *SEPT9* mutations has rarely been documented in children (Chuk, Sheppard, Wallace, & Coman, 2016; Laccone et al., 2008; Leshinsky-Silver et al., 2013). Such young children with HNA (at age 2) caused by a *SEPT9* duplication, as shown here, have not been described so far.

2 | MATERIALS AND METHODS

2.1 | DNA analysis

Genomic DNA was extracted from EDTA blood using standard procedures and the Blood and Cell DNA Kit from Qiagen (Qiagen GmbH, Hilden, Germany).

MLPA (Multiplex Ligation-dependent Probe Amplification)-analysis was performed using the *SEPT9* MLPA-Kit P307 B2 0315 V07 (MRC-Holland). Also Sanger-Sequencing of all coding regions, exon-intron boundaries and partial regions of the 5' and 3' untranslated regions (UTR) was performed for the index patient.

2.2 | Platelet function analyses

2.2.1 | Platelet count and platelet aggregometry analyses

Citrated-anticoagulated blood samples were obtained after informed consent. Platelet count was measured using an automated cell counter (Sysmex KX-21 N, Norderstedt, Germany). Platelet-rich plasma (PRP)

and platelet-poor plasma (PPP) were prepared by centrifugation as described before (Lahav et al., 2002). Platelet counts in PRP were adjusted to a concentration of 250 G/L with PPP. Platelet aggregometry analyses were performed after stimulation with the platelet agonists: collagen (2 µg/mL; Takeda, Linz, Austria), adenosine diphosphate (ADP; 4 and 10 µmol/L; Sigma-Aldrich, St. Louis, MO, USA), epinephrine (8 and 16 µmol/L; Sanofi-Aventis, Frankfurt, Germany), and ristocetin (1.2 mg/mL; American Biochemical and Pharmaceutical LTD, Frankfurt, Germany) using APLACT 4004 (Labitec, Ahrensburg, Germany).

2.3 | Flow cytometry analyses

Flow cytometry analyses were performed according to Lahav et al. (Lahav et al., 2002) using FACSCalibur (Becton Dickinson, Heidelberg, Germany). Aliquots of diluted PRP (5×10^7 platelets/mL) were fixed and stained with FITC-labeled monoclonal surface antibody against CD41 (fibrinogen receptor GPIIb/IIIa-complex), CD42a (von Willebrand factor [VWF] receptor GPIb/IX), and CD42b (VWF receptor GPIb) (Coulter, Immunotech, Marseille, France), respectively.

For VWF-binding analyses, diluted PRP (5×10^7 platelets/mL) was stimulated with different concentrations of ristocetin (0–1 mg/mL) and ADP (0–2 µmol/L) for 3 min at RT, respectively. Platelets were stained with FITC-labeled anti-VWF (Bio-Rad AbD Serotec, Puchheim, Germany) and Alexa Fluor 488-labeled anti-fibrinogen (Invitrogen, Waltham, MA, USA).

For secretion analyses, diluted PRP (5×10^7 platelets/mL) was stimulated with different concentrations of thrombin (0, 0.05, 0.1, 0.2, 0.5, and 1 U/mL; Siemens Healthineers, Marburg, Germany) in the presence of 1.25 mM Gly-Pro-Arg-Pro (Bachem, Bubendorf, Switzerland). Platelets were stained with monoclonal FITC-labeled anti-CD63 antibody (lysosomal membrane associated glycoprotein 3, LAMP-3; Immunotech, Marseille, France).

3 | RESULTS

3.1 | Patients

We report about a Lebanese girl (index patient) diagnosed with neuralgic shoulder amyotrophy at the age of 2 years. She was born in 1998 as the second child of consanguineous parents (second degree) (Figure 1). At the age of 4 months, she presented with epicanthal folds, four finger furrows, and large tongue. Ultrasound analysis revealed large, hyperechogenic kidneys on both sides with reversed mark-bark differentiation. Karyotype analysis revealed a normal female karyotype (46 XX). At age 2, she experienced the first attack with pain and weakness involving the left arm and left hand which resolved spontaneously. Symptoms started with acute pain in the left shoulder and arm followed by motor weakness predominantly affecting the radial nerve with her left hand falling and inhibited adduction.

At age 8, she suffered from the next severe painful attack involving the right shoulder. She could not elevate her arm because of extreme muscle weakness and pain. The pain resolved over the disease course, but the muscle weakness remained.

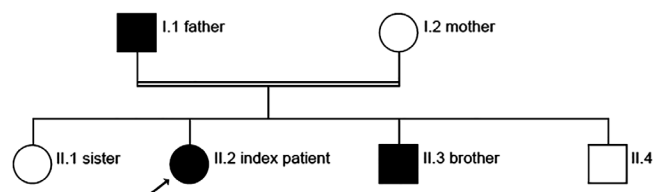


FIGURE 1 Pedigree: Females are shown as circles, males as squares. Filled symbols represent affected individuals with an exon 2 duplication of the *SEPT9* gene and a HNA onset during childhood (I.1 first onset at age 14, II.2 at age 2, and II.3 at age 6). Open symbols indicate non-affected individuals and a slanting arrow the index patient. II.4 was not tested because of his age and because he refused the blood draw, however, he is also clinically affected

We diagnosed slight atrophy of the right M. deltoideus and a loss of sensibility in the right upper arm. Muscle atrophy in the left hand impairing her fine-motor skills was also observed. Electromyography (EMG) and electroneurography (ENG) analyses were pathologic. Electrophysiologic examinations (EMG and ENG) revealed signs of denervation in clinically weak muscles but no signs of generalized neuropathy. Cranial and cervical spine magnetic resonance imaging (MRI) was normal. Ultrasound analysis revealed multiple cysts in both kidneys (Figure 2).

At age 16, she complained of extreme pain again in the right shoulder and right arm. She could not stretch or lift her right arm. The pain resolved within 2 to 3 weeks, however, atrophy in the right shoulder remained and persists. She suffers alternately from recurring slight pain in both shoulders and arms. In daily routine, she is able to look after her own affairs without assistance, however, she is slightly disabled and unable to carry out all activities. In the acute phase, she received anti-inflammatory drugs and an analgesic (Ibuprofen) and underwent physical therapy. She was not given long-term medication subsequently. She presents with no comorbidities and no particular pre-existing conditions.

Likewise, her father (born in 1968) suffered from pain attacks at ages 14 and 21 lasting 2 weeks. He experienced weakness in the right and left proximal arm and presented severe shoulder atrophy. The weakness disappeared completely; however, the sensory deficiency

remained in his proximal arms and elbows. The index patient's father also has epicanthal folds. He suffers from no kidney cysts.

Her oldest brother born in 2004 presented with sudden onset of extreme pain in his right proximal arm at the age of six years followed by weakness in the affected limb. The pain resolved completely within 2 to 3 weeks. Severe muscle atrophy in the area of the right shoulder and arm was observed. He had no sensory symptoms and presents no kidney cysts.

The youngest brother born in 2010, who also suffered from a pain attack in his arm and shoulder at age 2, presented with a cyst in his left kidney. He would not let us draw blood in our outpatient-clinic, making molecular genetic analysis impossible thus far.

All three HNA patients (index patient, father, and older brother) claim strenuous exercise of the affected limb as triggering factors. Clinical features of the patients are summarized in Table 1. The index patient's mother and her sister are unaffected and present no genetic *SEPT9* alterations. All family members' red and white blood cell counts, electrolytes, liver enzymes, and C-reactive protein values were normal.

3.2 | Platelet count and function analyses

All affected family members' platelet counts and size were normal.

Platelet aggregometry analyses from the index patient, her father, and brother were impaired after stimulation with adenosine diphosphate (ADP) and epinephrine (Table 2).

Flow cytometry analyses revealed that the index patient had slightly reduced platelet CD63 expression implying a mild platelet δ -granule secretion defect (Figure 3a). Her father and oldest brother presented with a more strongly decreased platelet CD63 expression than the index patient's, suggesting a moderate platelet δ -granule secretion defect (Figure 3b,c). The index patient, her father, and brother showed normal values for surface expression of GPIIb/IX and GPIIb/IIIa. Ristocetin-induced VWF-binding and ADP-induced fibrinogen-binding to platelets were within normal limits.

Platelet-function analyses of the unaffected mother and index patient's sister were normal.

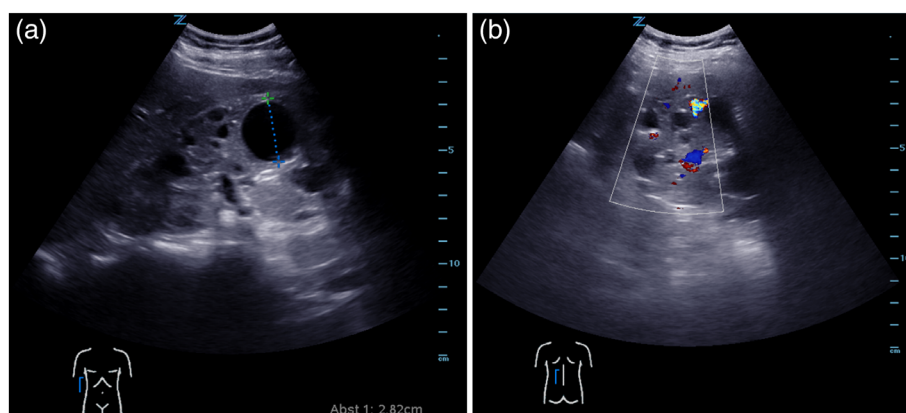


FIGURE 2 Ultrasonography of kidneys: (a) multiple renal cysts detectable in right kidney (longitudinal view, front). (b) Color Doppler analysis of left kidney; Perfusion is detectable in the vessels, but not in the cysts (longitudinal view, back)

TABLE 1 Clinical features of the affected family members

	Index patient	Patient's father	Patient's older brother
Age of onset	2	14	6
Pain	Yes	Yes	Yes
Attack frequency	3	2	1
Affected side	Left, right	Left, right	Right
Atrophy	Yes	Yes	Yes
Weakness	Yes	Yes	Yes
Sensory symptoms	Yes	Yes	No
Recovery	Partial	Partial	Complete

3.3 | Molecular genetics results

MLPA-analysis of the *SEPT9* gene for the index patient revealed a heterozygous exon 2 duplication: GRHch37/hg19 RefSeq. NM_006640.4; transcript v3: c.(22+1_23-1)_(293_668-1)dup. This duplication comprises intron 1, exon 2, and intron 2 (about 162 kb). This duplication was not detected in healthy family members (mother, sister). The index patient's additional Sanger-Sequencing revealed no other mutations in *SEPT9*.

We also identified this exon 2 duplication within the *SEPT9* gene in the affected oldest brother and father.

4 | DISCUSSION

Three different point mutations with pathogenic clinical significance in *SEPT9_v3* have been identified in HNA-affected patients so far: a transversion c.-134G>C and two missense mutations p.R88W (c.262C>T, p.Arg88Trp) and p.S93F (c.278C>T, p.Ser93Phe) (Hannibal et al., 2009; Kuhlenbaumer et al., 2005). R88W was reported to be the most frequent *SEPT9* mutation in HNA-affected families with a worldwide distribution (Chuk et al., 2016; Hannibal et al., 2009; Kuhlenbaumer et al., 2005; Laccone et al., 2008; Leshinsky-Silver et al., 2013; Ueda et al., 2010). Landsverk et al. described for the first time a 38 kb intragenic duplication within the *SEPT9* gene in some families (Landsverk et al., 2009). Although the duplications were genetically heterogeneous, all of these duplicated regions contained a 645 bp exon within the *SEPT9* gene. Furthermore, two of the three originally discovered HNA-linked mutations, R88W and S93F, are located in this 645 bp exon. Recently, a

TABLE 2 Platelet aggregation of the patients' platelets

Stimulation	Max. Aggregation		
	Index patient (%)	Patient's father (%)	Patient's older brother (%)
Collagen (2 µg/mL)	84	80	81
ADP (4 µmol/L)	35	37	31
ADP (10 µmol/L)	62	54	54
Epinephrine (8 µmol/L)	58	20	57
Epinephrine (16 µmol/L)	21	51	
Ristocetin (1.2 mg/mL)	81	96	89

Platelet aggregation was stimulated with collagen (2 µg/mL) adenosine diphosphate (4 and 10 µmol/L), and epinephrine (8 and 16 µmol/L). Platelet agglutination was induced with ristocetin (1.2 mg/mL). Values $\geq 70\%$ of the maximum aggregation is normal.

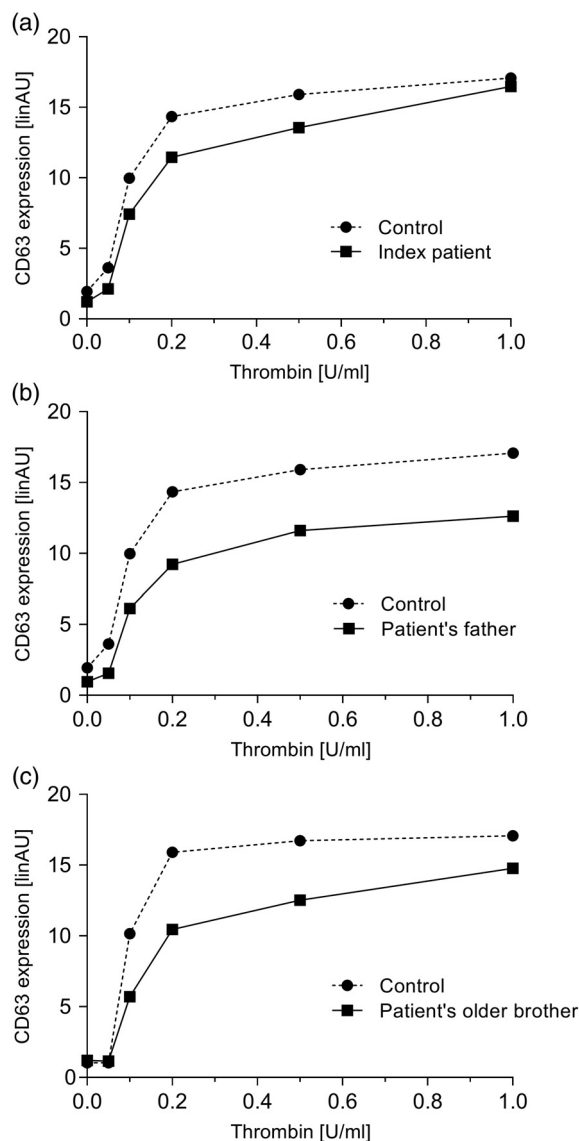


FIGURE 3 Flow cytometry analyses: (a) index patient, (b) index patient's father, (c) index patient's older brother. Platelet granule secretion stimulated with thrombin (concentrations: 0, 0.05, 0.1, 0.2, 0.5, and 1.0 U/mL)

Mildly impaired δ -granule secretion in the index patient (a) and moderately impaired δ -granule secretion in the index patient's father (b) and older brother (c) indicated by reduced platelet CD63 expression compared to the healthy control. Data are expressed as linear arbitrary units (linAU) of anti-CD63-stained unstimulated and thrombin-stimulated platelets from the patients and a healthy control

Danish HNA patient was identified with a maternally inherited duplication of 1.5 Mb comprising the entire *SEPT9* gene (Jurgensen, Fagerberg, Kibaek, & Brasch-Andersen, 2016). Nevertheless, HNA is in general genetically heterogeneous. In only 55% of the affected families, HNA can be linked to a mutation or duplication in the *SEPT9* gene (Collie, 2010). Perhaps one or more still unknown genes could be associated with HNA. A similar clinical phenotype has been reported in patients with a mutation in the *PMP22* gene (Russo et al., 2011).

In this study, we present an HNA family with a heterozygous duplication of exon 2 of the *SEPT9* gene with typical HNA symptoms: recurrent pain attacks, shoulder-arm atrophy and muscle weakness of the

affected muscles. Noteworthy is our patient's early attack onset. The latest hypothesis is that the attacks are triggered by infections, immunization, surgery, and exposure to cold or pregnancy (van Alfen & van Engelen, 2006). Interestingly, immune modulating therapies with interleukin-2 or interferon occurred as trigger factors for NA (Bernsen, Wong Chung, Vingerhoets, & Janssen, 1988; Suarez et al., 1996). The hypothesis of immune-response involvement is supported by the observation of multiple microvessels with epineural perivascular inflammatory infiltrates in nerve biopsies of HNA patients (Klein et al., 2002). In addition, emotional stress or strenuous use of the affected muscle at physical work or during athletic activity can provoke attacks of brachial plexus neuritis (van Alfen, 2007). In our study, all three patients reported that strenuous exercise of the affected limb was the trigger factor for the attacks. The family reports that the index patient's first attack at age 2 occurred after intensive playing and exercise with her siblings. Since strenuous exercise was also trigger factor for the first attack at age 2, this might explain the rarity of early onset, since toddlers are unlikely to engage in strenuous exercise. Interestingly, Host and Skov reported in their INA children study that pain was only present in about one out of two patients (Host & Skov, 2010).

Furthermore, our index patient and her father exhibit minor signs of dysmorphism (epicanthal folds both, enlarged tongue in the index patient). The following dysmorphic features have been rarely described in patients with HNA: a long, narrow face, small mouth, hypotelorism, epicanthal folds, shortened palpebral fissures, cleft palate, minor syndactyly, circular skin creases, and short stature (Airaksinen, Iivanainen, Karli, Sainio, & Haltia, 1985; Jeannet et al., 2001; Laccone et al., 2008; Orstavik, Ro, & Orstavik, 1997).

In addition to the known HNA symptoms, our patients presented with impaired platelet function. Septins are known to be involved in vesicle transport and exocytosis (Tokhtaeva et al., 2015). Genetic deletion of SEPT5, for example, leads to impaired granule secretion in mice, suggesting that SEPT5 regulates platelet function via association with platelet storage granules (Martinez et al., 2006). A patient with a homozygous SEPT5 deletion has also been described as suffering from a platelet secretion defect (Bartsch et al., 2011). In this study, platelet aggregation was impaired after stimulation with platelet agonists in all patients. The index patient revealed a slight platelet δ -granule secretion defect, whereas her father and older brother presented with a distinct platelet δ -granule secretion defect. The phenotype differs in the severity of the platelet secretion defect in our three affected patients with only a heterozygous SEPT9 defect. In families with platelet disorders (for example Hermansky Pudlak syndrome), platelet secretion can be mild impaired or even normal in heterozygous family members compared to severe platelet secretion defect in homozygous family members (Enders et al., 2006). Whether our patients' platelet secretion defect is due to the SEPT9 defect remains unclear.

The phenotype associated with kidneys cysts also differs in our patients; only the index patient and her youngest brother have cystic kidneys. In zebrafish embryogenesis, Sept7b plays an essential role in the structural and functional organization of the pronephros. Knockdown of Sept7b resulted in kidney-cyst formation (Dash et al., 2014). Furthermore, SEPT9 is upregulated in kidney cells undergoing epithelial-mesenchymal transition (Dolat et al., 2014), a process suggested to play a key role in polycystic disease (Togawa et al., 2011). A

reason for this varying phenotype could be incomplete penetrance of the heterozygous SEPT9 duplication.

5 | CONCLUSION

We describe an HNA family with a heterozygous SEPT9 duplication and early disease onset. Such a young child with HNA with disease onset at age 2 caused by SEPT9 duplication has not been described so far. The affected family members presented platelet dysfunction in addition to the typical HNA symptoms (recurrent pain attacks, arm-shoulder atrophy, and muscle weakness). Furthermore, two patients suffered from kidney cysts. Genetic testing should be considered in patients presenting HNA onset also at a young age to increase the compliance of the patient and family members and to facilitate therapy (i.e., physiotherapy, anti-inflammatory therapy).

ACKNOWLEDGMENT

We gratefully acknowledge the expert technical assistance of Anja Kahle, Simone Rosenfelder, and Sandra Wiegert. This work was financially supported by Deutsche Forschungsgemeinschaft DFG (ZI 486/4-1 and ZI 486/8-1).

CONFLICT OF INTEREST

All authors have no competing interests to declare.

REFERENCES

- Airaksinen, E. M., Iivanainen, M., Karli, P., Sainio, K., & Haltia, M. (1985). Hereditary recurrent brachial plexus neuropathy with dysmorphic features. *Acta Neurologica Scandinavica*, *71*(4), 309–316.
- Al-Ghamdi, F., & Ghosh, P. S. (2018). Neuralgic amyotrophy in children. *Muscle & Nerve*, *57*(6), 932–936.
- Bartsch, I., Sandrock, K., Lanza, F., Nurdan, P., Hainmann, I., Pavlova, A., ... Zieger, B. (2011). Deletion of human GP1BB and SEPT5 is associated with Bernard-Soulier syndrome, platelet secretion defect, polymicrogyria, and developmental delay. *Thrombosis and Haemostasis*, *106*(3), 475–483.
- Beghi, E., Kurland, L. T., Mulder, D. W., & Nicolosi, A. (1985). Brachial plexus neuropathy in the population of Rochester, Minnesota, 1970–1981. *Annals of Neurology*, *18*(3), 320–323.
- Bernsen, P. L., Wong Chung, R. E., Vingerhoets, H. M., & Janssen, J. T. (1988). Bilateral neuralgic amyotrophy induced by interferon treatment. *Archives of Neurology*, *45*(4), 449–451.
- Chuk, R., Sheppard, M., Wallace, G., & Coman, D. (2016). Pediatric hereditary neuralgic Amyotrophy: Successful treatment with intravenous immunoglobulin and insights into SEPT9 pathogenesis. *Child Neurology Open*, *3*, 2329048X16668970.
- Collie, A. M., Landsverk, M. L., Ruzzo, E., Mefford, H. C., Buysse, K., Adkins, J. R., ... Hannibal, M. C. (2010). Non-recurrent SEPT9 duplications cause hereditary neuralgic amyotrophy. *Journal of Medical Genetics*, *47*(9), 601–607.
- Dash, S. N., Lehtonen, E., Wasik, A. A., Schepis, A., Paavola, J., Panula, P., ... Lehtonen, S. (2014). Sept7b is essential for pronephric function and development of left-right asymmetry in zebrafish embryogenesis. *Journal of Cell Science*, *127*(Pt 7), 1476–1186.
- Dolat, L., Hunyara, J. L., Bowen, J. R., Karasmanis, E. P., Elgawly, M., Galkin, V. E., & Spiliotis, E. T. (2014). Septins promote stress fiber-mediated maturation of focal adhesions and renal epithelial motility. *The Journal of Cell Biology*, *207*(2), 225–235.

- Enders, A., Zieger, B., Schwarz, K., Yoshimi, A., Speckmann, C., Knoepfle, E. M., ... Ehl, S. (2006). Lethal hemophagocytic lymphohistiocytosis in Hermansky-Pudlak syndrome type II. *Blood*, *108*(1), 81–87.
- Hall, P. A., & Russell, S. E. (2004). The pathobiology of the septin gene family. *The Journal of Neurology*, *204*(4), 489–505.
- Hannibal, M. C., Ruzzo, E. K., Miller, L. R., Betz, B., Buchan, J. G., Knutzen, D. M., ... Chance, P. F. (2009). SEPT9 gene sequencing analysis reveals recurrent mutations in hereditary neuralgic amyotrophy. *Neurology*, *72*(20), 1755–1759.
- Host, C., & Skov, L. (2010). Idiopathic neuralgic amyotrophy in children. Case report, 4 year follow up and review of the literature. *European Journal of Paediatric Neurology*, *14*(6), 467–473.
- Hsu, S. C., Hazuka, C. D., Roth, R., Foletti, D. L., Heuser, J. & Scheller, R. H. (1998). Subunit composition, protein interactions, and structures of the mammalian brain sec6/8 complex and septin filaments. *Neuron*, *20*(6), 1111–1122.
- Jain, S., Bhatt, G. C., Rai, N., & Bhan, B. D. (2014). Idiopathic brachial neuritis in a child: A case report and review of the literature. *Journal of Pediatric Neurosciences*, *9*(3), 276–277.
- Jeannot, P. Y., Watts, G. D., Bird, T. D., & Chance, P. F. (2001). Craniofacial and cutaneous findings expand the phenotype of hereditary neuralgic amyotrophy. *Neurology*, *57*(11), 1963–1968.
- Jurgensen, L., Fagerberg, C., Kibaek, M., & Brasch-Andersen, C. (2016). Neuralgic amyotrophy is an overlooked diagnosis by sudden onset of shoulder pain. *Ugeskrift for Laeger*, *178*(34).
- Kinoshita, M. (2003). The septins. *Genome Biology*, *4*(11), 236.
- Klein, C. J., Dyck, P. J., Friedenberg, S. M., Burns, T. M., Windebank, A. J., & Dyck, P. J. (2002). Inflammation and neuropathic attacks in hereditary brachial plexus neuropathy. *Journal of Neurology, Neurosurgery, and Psychiatry*, *73*(1), 45–50.
- Kuhlenbaumer, G., Hannibal, M. C., Nelis, E., Schirmacher, A., Verpoorten, N., Meuleman, J., ... Chance, P. F. (2005). Mutations in SEPT9 cause hereditary neuralgic amyotrophy. *Nature Genetics*, *37*(10), 1044–1046.
- Kuhlenbaumer, G., Stogbauer, F., Timmerman, V., & De Jonghe, P. (2000). Diagnostic guidelines for hereditary neuralgic amyotrophy or hereditary familial neuritis with brachial plexus predilection. On behalf of the European CMT consortium. *Neuromuscular Disorders*, *10*(7), 515–517.
- Laccone, F., Hannibal, M. C., Neesen, J., Grisold, W., Chance, P. F., & Rehder, H. (2008). Dysmorphic syndrome of hereditary neuralgic amyotrophy associated with a SEPT9 gene mutation—a family study. *Clinical Genetics*, *74*(3), 279–283.
- Lahav, J., Jurk, K., Hess, O., Barnes, M. J., Farndale, R. W., Luboshitz, J., & Kehrel, B. E. (2002). Sustained integrin ligation involves extracellular free sulfhydryls and enzymatically catalyzed disulfide exchange. *Blood*, *100*(7), 2472–2478.
- Landsverk, M. L., Ruzzo, E. K., Mefford, H. C., Buysse, K., Buchan, J. G., Eichler, E. E., ... Hannibal, M. C. (2009). Duplication within the SEPT9 gene associated with a founder effect in north American families with hereditary neuralgic amyotrophy. *Human Molecular Genetics*, *18*(7), 1200–1208.
- Leshinsky-Silver, E., Ginzberg, M., Dabby, R., Sadeh, M., Lev, D., & Lerman-Sagie, T. (2013). Neonatal vocal cord paralysis—an early presentation of hereditary neuralgic amyotrophy due to a mutation in the SEPT9 gene. *European Journal of Paediatric Neurology*, *17*(1), 64–67.
- MacDonald, B. K., Cockerell, O. C., Sander, J. W., & Shorvon, S. D. (2000). The incidence and lifetime prevalence of neurological disorders in a prospective community-based study in the UK. *Brain: A Journal of Neurology*, *123*(Pt 4), 665–676.
- Martinez, C., Corral, J., Dent, J. A., Sesma, L., Vicente, V., & Ware, J. (2006). Platelet septin complexes form rings and associate with the microtubular network. *Journal of Thrombosis and Haemostasis*, *4*(6), 1388–1395.
- Meulemann, J., Kuhlenbaumer, G., Schirmacher, A., Wehnert, M., De Jonghe, P., De Vriendt, E., ... Timmerman, V. (1999). Genetic refinement of the hereditary neuralgic amyotrophy (HNA) locus at chromosome 17q25. *European Journal of Human Genetics: EJHG*, *7*(8), 920–927.
- Orstavik, K., Ro, H., & Orstavik, K. H. (1997). Recurrent brachial plexus neuropathy in a family with subtle dysmorphic features – a case of hereditary neuralgic amyotrophy. *Clinical Genetics*, *51*(6), 421–425.
- Parsonage, M. J., & Turner, J. W. (1948). Neuralgic amyotrophy; the shoulder-girdle syndrome. *Lancet*, *1*(6513), 973–978.
- Pellegrino, J. E., George, R. A., Biegel, J., Farlow, M. R., Gardner, K., Caresse, J., ... Chance, P. F. (1997). Hereditary neuralgic amyotrophy: Evidence for genetic homogeneity and mapping to chromosome 17q25. *Human Genetics*, *101*(3), 277–283.
- Russo, M., Laura, M., Polke, J. M., Davis, M. B., Blake, J., Brandner, S., ... Reilly, M. M. (2011). Variable phenotypes are associated with PMP22 missense mutations. *Neuromuscular Disorders*, *21*(2), 106–114.
- Stogbauer, F., Young, P., Timmerman, V., Spoelders, P., Ringelstein, E. B., Van Broeckhoven, C., & Kurlmann, G. (1997). Refinement of the hereditary neuralgic amyotrophy (HNA) locus to chromosome 17q24-q25. *Human Genetics*, *99*(5), 685–687.
- Suarez, G. A., Giannini, C., Bosch, E. P., Barohn, R. J., Wodak, J., Ebeling, P., ... Dyck, P. J. (1996). Immune brachial plexus neuropathy: Suggestive evidence for an inflammatory-immune pathogenesis. *Neurology*, *46*(2), 559–561.
- Togawa, H., Nakanishi, K., Mukaiyama, H., Hama, T., Shima, Y., Sako, M., ... Yoshikawa, N. (2011). Epithelial-to-mesenchymal transition in cyst lining epithelial cells in an orthologous PCK rat model of autosomal-recessive polycystic kidney disease. *American Journal of Physiology Renal Physiology*, *300*(2), F511–F520.
- Tokhtaeva, E., Capri, J., Marcus, E. A., Whitelegge, J. P., Khuzakhmetova, V., Bukharaeva, E., ... Vagin, O. (2015). Septin dynamics are essential for exocytosis. *The Journal of Biological Chemistry*, *290*(9), 5280–5297.
- Trimble, W. S. (1999). Septins: A highly conserved family of membrane-associated GTPases with functions in cell division and beyond. *Journal of Membrane Biology*, *169*(2), 75–81.
- Ueda, M., Kawamura, N., Tateishi, T., Sakae, N., Motomura, K., Ohyagi, Y., & Kira, J. I. (2010). Phenotypic spectrum of hereditary neuralgic amyotrophy caused by the SEPT9 R88W mutation. *Journal of Neurology, Neurosurgery, and Psychiatry*, *81*(1), 94–96.
- van Alfen, N. (2007). The neuralgic amyotrophy consultation. *Journal of Neurology*, *254*(6), 695–704.
- van Alfen, N., Schuurin, J., van Engelen, B. G., Rotteveel, J. J., & Gabreels, F. J. (2000). Idiopathic neuralgic amyotrophy in children. A distinct phenotype compared to the adult form. *Neuropediatrics*, *31*(6), 328–332.
- van Alfen, N., van Eijk, J. J., Ennik, T., Flynn, S. O., Nobacht, I. E., Groothuis, J. T., ... van de Laar, F. A. (2015). Incidence of neuralgic amyotrophy (parsonage turner syndrome) in a primary care setting—a prospective cohort study. *PLoS One*, *10*(5), e0128361.
- van Alfen, N., & van Engelen, B. G. (2006). The clinical spectrum of neuralgic amyotrophy in 246 cases. *Brain: A Journal of Neurology*, *129*(Pt 2), 438–450.
- van Alfen, N., van Engelen, B. G., & Hughes, R. A. (2009). Treatment for idiopathic and hereditary neuralgic amyotrophy (brachial neuritis). *Cochrane Database of Systematic Reviews*. (3):CD006976. [https://doi.org/10.1002/14651858.CD006976.pub2\(3\):CD006976](https://doi.org/10.1002/14651858.CD006976.pub2(3):CD006976)
- van Eijk, J. J., van Alfen, N., Berrevoets, M., van der Wilt, G. J., Pillen, S., & van Engelen, B. G. (2009). Evaluation of prednisolone treatment in the acute phase of neuralgic amyotrophy: An observational study. *Journal of Neurology, Neurosurgery, and Psychiatry*, *80*(10), 1120–1124.
- Vega, I. E., & Hsu, S. C. (2001). The exocyst complex associates with microtubules to mediate vesicle targeting and neurite outgrowth. *The Journal of Neuroscience: The Official Journal of the Society for Neuroscience*, *21*(11), 3839–3848.
- Watts, G. D., O'Briant, K. C., & Chance, P. F. (2002). Evidence of a founder effect and refinement of the hereditary neuralgic amyotrophy (HNA) locus on 17q25 in American families. *Human Genetics*, *110*(2), 166–172.
- Wehnert, M., Timmerman, V., Spoelders, P., Meuleman, J., Nelis, E., & Van Broeckhoven, C. (1997). Further evidence supporting linkage of hereditary neuralgic amyotrophy to chromosome 17q. *Neurology*, *48*(6), 1719–1721.

How to cite this article: Neubauer K, Boeckelmann D, Koehler U, et al. Hereditary neuralgic amyotrophy in childhood caused by duplication within the SEPT9 gene: A family study. *Cytoskeleton*. 2019;76:131–136. <https://doi.org/10.1002/cm.21479>