

Case Report

Clarithromycin-induced acute interstitial nephritis and minimal change disease

Wendy Russell and William Smith

Renal Unit, Monklands Hospital, Airdrie ML6 0JS, Lanarkshire, UK

Correspondence and offprint requests to: William Smith; E-mail: William.Smith@lanarkshire.scot.nhs.uk

Abstract

Drug associated acute interstitial nephritis and minimal change disease has been well documented but the simultaneous presentation of both is rare and has not been reported with clarithromycin. We describe a case of simultaneous acute tubulointerstitial nephritis and minimal change disease induced by clarithromycin. The patient had acute kidney injury, nephrotic syndrome, eosinophilic pneumonitis and a maculopapular skin rash. The role of steroid therapy in acute interstitial nephritis is controversial but is accepted as beneficial in minimal change nephrotic syndrome. Steroid therapy in our patient resulted in complete clinical resolution.

Keywords: acute interstitial nephritis; clarithromycin; eosinophilic pneumonitis; nephrotic syndrome

Background

Drug induced acute interstitial nephritis is well recognized with antimicrobials especially β -lactam antibiotics but is also described with macrolides including clarithromycin [1,2]. Minimal change disease secondary to drugs including antibiotics and NSAIDs is also documented [3]. Simultaneous combined acute interstitial nephritis and minimal change glomerulonephritis have rarely been reported with non-steroidals and amoxicillin but not with clarithromycin [4].

Case report

A 65-year-old presented to his primary care physician with a cough and was given an antibiotic without symptomatic benefit. Over the following 2 weeks, his cough did not settle and he noticed ankle swelling, shortness of breath and developed an itchy red rash over the trunk and limbs.

He was referred to hospital where he was found to be febrile, markedly oedematous and a chest x-ray revealed left upper lobe collapse and consolidation. His creatinine

was raised at 221 $\mu\text{mol/l}$ and serum albumin was low at 18 g/l. He had microscopic haematuria and urinary albumin-to-creatinine ratio was raised at 395 mg/mmol and a 24 h urine protein was 9.6 g. The total peripheral white cell count was marginally elevated ($12.7 \times 10^9/l$) but neutrophils were normal. It was noted that he had a marked blood eosinophilia, (eosinophils $5 \times 10^9/l$, normal range 0–0.4). He was treated initially with oral amoxicillin for pneumonia and commenced on an intravenous furosemide infusion.

Chest x-ray continued to show left upper lobe changes, and when his fever and CRP failed to settle on single antibiotic therapy, clarithromycin was added for the assumed pneumonia.

A CT scan of chest and abdomen revealed collapse and consolidation of the left upper lobe, bilateral pleural effusions and no lymphadenopathy or abnormalities of the upper abdomen. Renal ultrasound was normal. Liver function tests, ANCA, ANA and complement were normal, and microbiological screening was negative. Whilst his oedema was improving, there was recurrence of the widespread maculopapular rash.

A renal biopsy was undertaken, and light microscopy (Figure 1) showed that the glomeruli were normal with no crescents or necrotising lesions but there was patchy tubulointerstitial nephritis with lymphocytic and eosinophilic infiltration. There was also an ill-defined non-caseating granuloma raising the suspicion of a drug reaction. Immunofluorescence was negative, and electron microscopy (Figure 2) showed widespread foot process effacement in keeping with coexistent minimal change disease.

With all the above, we questioned his initial presentation and treatment further, and on investigation discovered that the initial antibiotic given in the community was clarithromycin. Clarithromycin had been changed to amoxicillin on presentation to hospital and the rash had largely settled; however, not long after clarithromycin was reinstated in hospital, the rash flared up. A skin biopsy showed a mononuclear infiltrate with eosinophils and mast cells in keeping with a drug induced reaction.

He was commenced on oral prednisolone 60 mg od. Promptly his eosinophil count fell to normal, and there

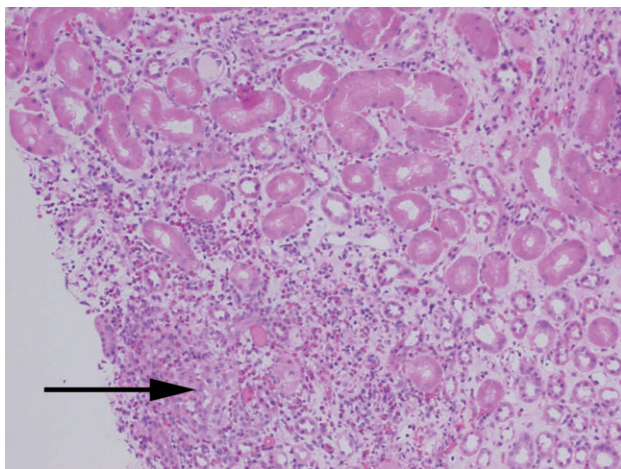


Fig. 1. Acute eosinophilic tubulointerstitial infiltration and non-caseating granuloma (arrow). Stain H&E, magnification $\times 100$.

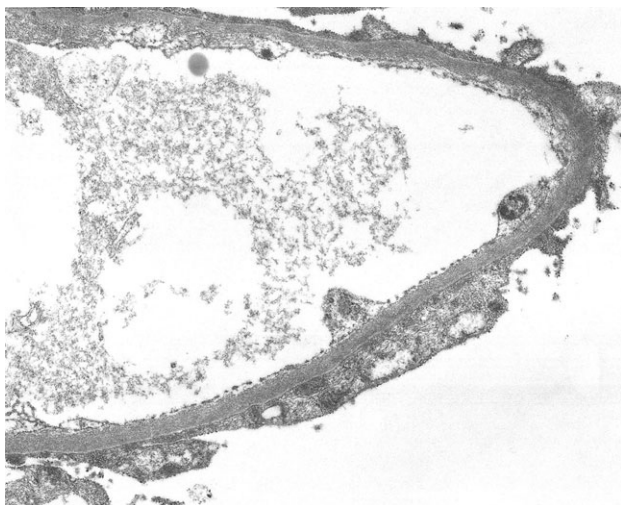


Fig. 2. Electron micrograph. Foot process effacement magnification $\times 9000$.

was a progressive improvement in his albumin, creatinine and proteinuria. The rash and pneumonitis gradually settled, and he was discharged on a slow reducing dose of corticosteroids. Within 3 months, all clinical, radiological and laboratory abnormalities had returned to normal.

Discussion

In our patient, the original exposure to clarithromycin in the community induced a cell-mediated hypersensitivity reaction resulting in acute kidney injury, nephrotic syndrome, eosinophilic pneumonitis and a skin rash. When rechallenged with clarithromycin, there was exacerbation of the skin rash and blood eosinophilia.

A renal biopsy showed simultaneous features of acute eosinophilic tubulointerstitial nephritis with a non-caseating granuloma and foot process effacement in keeping with minimal change disease. This drug-induced dual pathology has not previously been reported with clarithromycin. The role of steroid therapy in minimal change disease is widely accepted, but in drug-related acute interstitial nephritis, it is more controversial with some studies showing benefit and others not [5,6]. Clarithromycin-induced eosinophilic pneumonia has rarely been cited, but again there is debate as to whether steroids are beneficial [7,8]. In our case, there was a rapid clinical response to the cessation of clarithromycin and introduction of prednisolone.

Conflict of interest statement. None declared.

References

- Rossert J. Drug-induced acute interstitial nephritis. *Kidney Int* 2001; 60: 804–817
- Audimoolam V, Bhandari S. Clarithromycin-induced granulomatous tubulointerstitial nephritis. *Nephrol Dial Transplant* 2006; 21: 2654–2655
- Glasscock R. Secondary minimal change disease. *Nephrol Dial Transplant* 2003; 18(Suppl 6): vi52–vi58
- Dharnidharka V, Rosen S, Somers M. Acute interstitial nephritis presenting as presumed minimal change nephrotic syndrome. *Pediatr Nephrol* 1998; 12: 576–578
- Buysen J, Houthoff H, Krediet R *et al.* Acute interstitial nephritis: a clinical and morphological study in 27 patients. *Nephrol Dial Transplant* 1990; 5: 94–99
- Clarkson M, Giblin L, O'Connell F *et al.* Acute interstitial nephritis: clinical features and response to steroid therapy. *Nephrol Dial Transplant* 2004; 19: 2778–2783
- Terzano C, Petroianni A. Clarithromycin and pulmonary infiltration with eosinophilia. *BMJ* 2003; 326: 1377–1378
- Ohnishi H, Abe M, Yokoyama A *et al.* Clarithromycin-induced eosinophilic pneumonia. *Intern Med* 2004; 43: 231–235

Received for publication: 17.5.09; Accepted in revised form: 11.6.09