

INVITED REVIEW

Emerging signs of autism spectrum disorder in infancy: Putative neural substrate

Mijna Hadders-Algra^{1,2} 

¹University of Groningen, University Medical Center Groningen, Department of Paediatrics, Section of Developmental Neurology, Groningen, the Netherlands

²University of Groningen, Faculty of Theology and Religious Studies, Groningen, the Netherlands

Correspondence

Mijna Hadders-Algra, University Medical Center Groningen, Developmental Neurology, Hanzeplein 1, 9713 GZ Groningen, the Netherlands.
Email: m.hadders-algra@umcg.nl

Abstract

Autism spectrum disorder (ASD) is characterized by altered development of the social brain with prominent atypical features in the fronto-temporo-parietal cortex and cerebellum. Early signs of ASD emerge between 6 and 12 months: reduced social communication, slightly less advanced motor development, and repetitive behaviour. The fronto-temporo-parietal cortex and cerebellum play a prominent role in the development of social communication, whereas fronto-parietal-cerebellar networks are involved in the planning of movements, that is, movement selection. Atypical sensory responsivity, a core feature of ASD, may result in impaired development of social communication and motor skills and/or selection of atypical repetitive behaviour. In the first postnatal year, the brain areas involved are characterized by gradual dissolution of temporary structures: the fronto-temporo-parietal cortical subplate and cerebellar external granular layer. It is hypothesized that altered dissolution of the transient structures opens the window for the expression of early signs of ASD arising in the impaired developing permanent networks.

Autism spectrum disorder (ASD) is an umbrella term describing a group of neurodevelopmental disorders characterized by two core features: impaired social communication and restricted and repetitive behaviours, which include atypical responses to sensory information.¹⁻³ ASD has a heterogeneous aetiology, in which genetic risk involving many heterogenous genetic variants plays a large role.^{1,2} Unfavourable prenatal, perinatal, and neonatal conditions, including advanced parental age and birth before 32 weeks of gestation, are associated with an increased risk of ASD.¹ The prevalence of ASD, currently estimated as 1% to 2%, has increased during the last years, most likely because of growing awareness and improved diagnostics.¹⁻³ Males are affected 3 to 4 times more often than females.¹⁻³ ASD is often accompanied by other disorders, including intellectual disability, anxiety disorder, and depression.^{1,2}

A recent meta-analysis⁴ indicated that ASD in children is diagnosed at an average age of 43 months. However, accumulating evidence indicates that the first signs of ASD arise during infancy.⁵⁻⁷ The first aim of this review is to summarize the signs of ASD emerging in the first postnatal year. Our knowledge of the early signs was boosted by studies that prospectively followed infants at high familial risk of ASD, who at the age of 2 or 3 years most likely had ASD or who did not meet the criteria for probably having ASD, and infants at low familial risk of ASD. The review's second aim is to discuss the pathophysiology underlying the emergence of ASD signs in infancy. From neuropathological and neuroimaging studies in adolescents and adults, it is well known that ASD is associated with widespread alterations in the so-called 'social brain'. The social brain consists of extensive networks to which the frontal, temporal, and parietal cortices and cerebellum largely

Abbreviation: ASD, autism spectrum disorder; EGL, external granular layer

This is an open access article under the terms of the [Creative Commons Attribution-NonCommercial](https://creativecommons.org/licenses/by-nc/4.0/) License, which permits use, distribution and reproduction in any medium, provided the original work is properly cited and is not used for commercial purposes.

© 2022 The Author. *Developmental Medicine & Child Neurology* published by John Wiley & Sons Ltd on behalf of Mac Keith Press.

contribute.^{3,8,9} The current review hypothesizes that the dissolution of the temporary neural structures in these parts of the brain, that is, an altered dissolution of the cortical subplate in the frontal, temporal, and parietal cortices resulting in an excess of white matter interstitial neurons¹⁰ and the dissolution of the cerebellar external granular layer (EGL),¹¹ may underlie the emergence of the early signs of ASD.

SIGNS OF ASD DURING INFANCY

Signs of altered social communication

Subtle impairments in social communication are the first specific signs of ASD.¹² These impairments can be detected from 6 months onwards.^{5,6} The first signs especially consist of lower rates of social behaviour, including gazing at an adult's face, smiling or vocalizing to an adult with eye contact, initiating joint attention, and responding to one's name.^{5,6,13} Most likely, impaired attention to biological motion, in particular to the movements of other persons' eyes and mouth, plays a pivotal role in the development of social signs.^{14,15} Impaired attention to biological motion results, among others, in reduced joint attention, which in turn interferes with language development and the acquisition of social knowledge.^{14,16,17} The lower rates of social behaviour emerging between 6 and 12 months are generally due to regression, that is, a significant decrease in (or loss of) previously acquired behaviour.⁵

At the beginning of the second year, impairments in social communication are clearer.^{1,18} In addition, other social signs may emerge, such as lower rates of sharing gestures, lower social reciprocity, and less coordinated communication involving gaze, facial expression, and vocalizations.^{6,18} In response, parent behaviour may change. For instance, parents may produce fewer labelling utterances; in response to the infant's limited signs of communication, parents may produce more play actions.¹⁸

This indicates that the expression of impaired social communication starts in the second half of the first year. However, during this period signs are mostly too subtle to be picked up by parents and clinicians. In general, it is from the age of about 12 months onwards that parental screening questionnaires¹⁹ and spontaneously uttered parental concerns about their infant's social and language skills^{20,21} get predictive validity for ASD in infants with high familial risk.

Signs of altered sensory processing

Sensory concerns, such as hyperresponsiveness to sound or touch, are among the first signs that distinguish infants later diagnosed with ASD (i.e. infants with ASD) from infants without ASD.²⁰ With increasing age, the difference in sensory responsivity between infants with ASD and typically developing infants increases.²² At preschool age, signs of hyporesponsiveness are reported, such as ignoring loud noise, lacking attention for novel objects, and not responding to pain.²³

What this paper adds

- The early social and motor signs of autism spectrum disorder emerge between the ages of 6 and 12 months.
- Altered dissolution of transient brain structures in the fronto-temporo-parietal cortex and cerebellum may underlie the emergence of these early signs.

Signs of altered motor development

Infants with ASD may also show impaired motor development. Currently, it is unclear whether or not abnormal general movements may assist the prediction of ASD because the limited data available are contradictory.⁷ It is conceivable that infants with ASD have a higher prevalence of poor repertoire general movements or fidgety movements with an abnormal quality, but most likely these signs have limited predictive power for ASD.⁷ Presumably, prediction will be best in groups of infants at high familial or biological risk (see the section on the 'Pathophysiology of altered motor function in ASD').

The meta-analysis by Lim et al.⁷ indicated that motor signs in the form of less advanced gross and fine motor skills emerge around 6 months. The study by Sacrey et al.²⁰ indicated that parents also report motor concerns in infants with ASD from such an early age onwards. However, Tran et al.²¹ could not confirm this finding. Between 6 and 12 months, infants with ASD may start to produce more repetitive movements, such as hand flapping, than infants without ASD.²⁴ The motor signs in the second half of the first year are subtle. For instance, the motor performance of infants with ASD aged 6 to 12 months is less advanced than that of infants without ASD; however, infants with ASD generally perform within the norms.²⁵ This may explain the contradictory findings on the parental concerns regarding motor development of infants with ASD. From 12 months onwards, delays in achieving motor skills and the presence of repetitive, ritualistic behaviour (e.g. simple motor strategies or lining up of toys) are more prominent.^{6,7}

PATHOPHYSIOLOGY OF THE EARLY SIGNS OF ASD

Neuropathology, neuroimaging, and electrophysiology

Neuropathological and neuroimaging studies in adolescents and adults reported that ASD is associated with widespread alterations in the social brain.^{3,8,9} The social brain includes the medial prefrontal cortex, the association areas in the parietal and temporal cortices, the cerebellum, amygdala, and brainstem.²⁶ The alterations in individuals with ASD include overconnectivity, underconnectivity, and a more

diffuse connectivity between networks. This results in reduced network specialization and a loss of hubs (nodes on which global long-range connectivity converges) in the prefrontal, temporal, and parietal cortices.^{3,8}

The pathogenesis of ASD starts during prenatal life and involves many of the complex, interacting, and long-lasting processes of brain development, including neural proliferation, migration, dendrite and axon outgrowth, synaptogenesis, neural cell death, synapse reorganization, and network configuration.²⁷ Recent neuropathological studies suggested that the development of the cortical subplate is also altered since the frontal, temporal, and parietal cortices of adults with ASD contain an excess of subplate neurons, especially white matter interstitial neurons.^{10,28,29}

Neuroimaging studies in young children with high and low familial risk revealed that brain development in children with ASD is characterized by aberrant growth: early overgrowth is followed by regression.³⁰ This is best documented for the frontal, temporal, and cingulate cortices.³⁰ Early overgrowth is the net result of a decreased growth in grey matter and increased white matter growth. This is visible around 12 months.³¹ At the age of 2 years, the white matter trajectories of children with ASD start to show reduced integrity compared to those of children without ASD.³² From this age onwards, the volumes of the striatum and amygdala and the thickness of the temporal cortex decrease with increasing age, whereas the thickness of the frontal cortex increases in individuals with ASD.³³

Whether the social brain of children with ASD functions differently from that of children without ASD already at birth is currently unclear since resting-state functional magnetic resonance imaging studies in infants with high familial risk provided contradictory results.^{34,35} Yet, a diffusion tensor imaging study in 6-week-old infants reported that infants with high familial risk pair thalamic-prefrontal underconnectivity with thalamic-occipital and thalamic-motor overconnectivity.³⁶ Also, a multichannel electroencephalography study in 3-month-old infants indicated that infants with high familial risk showed signs of decreased connectivity in the frontal area and increased connectivity in the temporoparietal areas. In addition, the early parameters of altered connectivity are associated with higher rates of signs of ASD at 18 months.³⁷ A morphometric study focusing on the subcortical regions and cerebellum described that at the age of 4 to 6 months the volume of both areas was larger in infants with high familial risk than in infants with low familial risk. The larger volumes in early infancy were related to higher scores of repetitive behaviour at the age of 3 years.³⁸ These findings correspond to those by Wolff et al.³² that signs of altered development of cerebellar pathways and the genu of the corpus callosum at 6 months are associated with higher scores of repetitive behaviour and sensory impairment at the age of 2 years.

These data demonstrate that even during infancy the brain development of children with ASD differs from that of children without ASD. They also indicate that the impairments are increasingly clear with increasing age, in

particular after the age of 12 months. The impairments are widespread in the social brain, with the most prominent deviances found in the cortico-subcortical networks involving the frontal, temporal, and parietal cortices and cerebellum. The widespread alterations in the young social brain explain why social signs are the most specific early signs of ASD.

Altered sensory processing

Atypical sensory responsivity occurs in most individuals with ASD, affecting all sensory modalities.³⁹ Robertson and Baron-Cohen suggested that sensory impairments are a core characteristic of the neurobiology of ASD.³⁹ A key feature of sensory impairment is the large intertrial response variability.³⁹ The variable and thus less reliable sensory information may underlie the altered development of both social communication and motor development. Less accurate sensory feedback may hamper the interpretation of especially complex non-verbal face and gaze signals, the development of joint attention, and motor skills.^{16,40,41}

In ASD, all sensory modalities are affected, including the visual system. In children with severe or profound visual impairment, the prevalence of ASD is significantly increased.^{42,43} The most common ophthalmological disorders associated with ASD are retinopathy of prematurity, optic nerve hypoplasia, Leber congenital amaurosis, and microphthalmia/anophthalmia.⁴² Most children with these disorders have additional neurological pathologies, most commonly cerebral visual impairment.⁴³ The additional neurological abnormalities and their underlying neuropathology largely explain the increased prevalence of ASD among children with severe visual impairment. In children in whom visual impairment is based on peripheral ophthalmic pathology only, the risk of ASD is not or only slightly increased.⁴⁴

When the mirror neuron system, the group of neurons that mirror the neural activity involved in the actions of others, was discovered in the early 1990s, it was soon thought that an impaired mirror neuron system could be a core characteristic of ASD.⁴⁵ Indeed, children with ASD have somewhat limited capacities to imitate: on average they perform between the 18th and 21st centile of typically developing children.⁴⁶ However, it is increasingly clear that this impairment cannot be attributed to an impaired mirror neuron system.^{45,47,48} Rather than being attributed to a deficit in the mirror neuron system, the mildly impaired capacities to imitate may be explained by impaired abilities to process biological motion.⁴⁹

Pathophysiology of altered motor function in ASD

Children, young people, and adults with ASD often show impaired motor skills.^{50–52} Their motor behaviour is especially characterized by impaired planning of movements, in particular complex movements.⁵³ The impairments

frequently qualify for the diagnosis of developmental coordination disorder but often this diagnosis is not provided due to a lack of attention to motor problems.⁵¹ A recent systematic review indicated that the neural correlate of developmental coordination disorder consists of widespread alterations in the brain involving the corticospinal tract, basal ganglia, and frontal, parietal, and temporal cortices.⁵⁴ The review noted that the cerebellum received little research attention.⁵⁴ Recent studies on the neural substrate of motor impairments in individuals with ASD indicated involvement of the prefrontal⁵⁰ and parietal cortices,⁵⁵ cerebellum,⁵⁶ and corticospinal tract.⁵⁷ The latter study indicated that the corticospinal projections from the primary motor cortex were not involved; only projections originating in the premotor and supplementary motor cortices were affected.⁵⁷

We know that limited movement variation in infancy, for example, reflected by poor repertoire general movements, is on the one hand associated with damage of the periventricular white matter and corticospinal tract, with or without lesions in the basal ganglia; on the other hand, it is associated with cerebral palsy.⁵⁸ It is conceivable that infants with ASD may also show a reduced motor repertoire. The latter may be expressed in general movements with a poor repertoire. In addition, altered sensory processing may result in fidgety movements with an atypical quality ('breakdance fidgety').⁵⁹ Most likely, repertoire reduction in infants with ASD is less pronounced than that in children with cerebral palsy, a suggestion that is supported by the pilot study by Wilson et al.⁶⁰ Presumably, repertoire reduction especially occurs in infants later diagnosed with the combination of ASD and developmental coordination disorder.

During typical development, infants gradually learn to select from their movement repertoire those movements that are best adapted to the situation. This means that infants shift from a feedback movement control to an efficient feedforward movement selection. The development of this adaptive motor behaviour starts to bloom in the second half of the first postnatal year.⁶¹ It is based on active trial-and-error learning and its associated sensory information.⁶¹ As mentioned earlier, sensory feedback in children with ASD is less reliable, which may interfere with the process of selection. This may have two consequences. First, it may mean that children with ASD need more trial-and-error experience to find their most efficient movement strategy and therefore need more time to develop motor skills.^{10,11} Second, the altered sensory input and its possibly altered reference values may also result in an atypical selection of preferred motor behaviour, that is, the selection of repetitive movement sequences. This corresponds to reports of young people with ASD that repetitive behaviour helps to focus the mind, relax, and cope with overwhelming sensory information.⁶² It is conceivable that the selection of atypical, repetitive movements is facilitated by the presence of a limited motor repertoire.

The putative role of the cortical subplate in ASD pathophysiology

The cortical subplate is a temporary structure between the cortical plate and the future white matter. From animal research, we know that it is a hotspot of brain development and brain function during fetal life. By establishing transient connections, the cortical subplate assists the development of the huge number of afferent and corticocortical pathways characteristic of the human brain.^{10,11,63,64} The latter is especially true for the frontal, temporal, and parietal association areas, where the subplate is thickest and more prominently present for longer than in other cortical areas.¹⁰ The subplate starts to shrink at the beginning of the third trimester of gestation due to programmed cell death. Other neurons start to populate the cortical plate, that is, the site of the permanent cortical networks. Around 3 months post-term, the transient cortical subplate has largely disappeared in the primary motor, somatosensory, and visual cortices, but it takes until the end of the first year before this stage is reached in the frontal, temporal, and parietal association areas.^{10,11} In humans, the subplate neurons do not entirely disappear; interstitial neurons remain in the gyral white matter.¹⁰ These neurons play a role in finding the optimal balance between glutamatergic (excitatory) and GABAergic (inhibitory) neural activity, thus allowing for a modulation of the afferent input to the deep cortical layers.¹⁰ Increasing evidence suggests that (1) in ASD altered subplate dissolution in the frontal, temporal, and parietal areas results in an excess of white matter interstitial neurons,^{28,29} and (2) ASD is characterized by an altered glutamatergic–GABAergic balance.^{65,66} Thus, the following sequence of events is conceivable. Brain development in ASD may start with an often genetically determined alteration of the glutamatergic–GABAergic balance and an altered dissolution of the cortical subplate resulting in a surplus of white matter interstitial neurons ('first hit').⁶⁵ Next, the resulting altered sensitivity to sensory information may give rise to a further altered development of corticocortical connectivity, especially in the frontal, temporal, and parietal association areas ('second hit').⁶⁵ In addition, the altered development of the subplate may also affect cerebellar development.¹⁰

Putative neural substrate underlying the emerging signs of ASD in infancy

Signs of neural impairment generally emerge when the underlying neural circuitries have been developed sufficiently to express function. For instance, dyslexia is mostly diagnosed at school age, when the neural networks involved in reading and writing have been sufficiently established. The same holds true for the expression of the first specific signs of ASD: they arise in the second half of the first year (Figure 1). The emergence of signs runs parallel to the last phase of the dissolution of the two temporary structures in

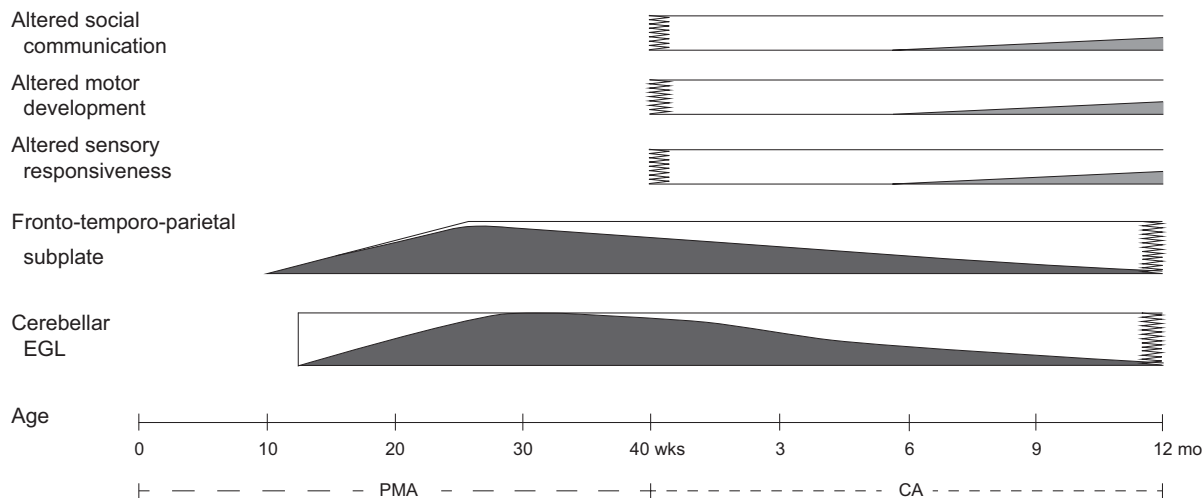


FIGURE 1 Schematic representation of the emergence of the specific signs of autism spectrum disorder and the presence and dissolution of transient structures during early development. The bottom line denotes age, first in weeks postmenstrual age (PMA) and after term age (40 weeks) in months corrected age (CA). In the three upper bars, the hatching denotes the presence of a sign of autism spectrum disorder. In the lowest two bars, the grey shading depicts typical development and dissolution of the transient neural structures: the cortical subplate in the frontal, temporal, and parietal association areas and the cerebellar external granular layer (EGL). Note that in autism spectrum disorder, dissolution of the subplate in the frontal, temporal, and parietal association areas is altered, resulting in an excess of white matter interstitial neurons (not depicted).

the brain, that is, the dissolution of the cerebellar EGL and the altered dissolution of the cortical subplate in the frontal, temporal, and parietal association areas resulting in an excess of white matter interstitial neurons. Based on these concurrent developments, we may hypothesize that the altered dissolution of the temporary structures in the brain areas, which are clearly involved in ASD pathology, allows for the behavioural expression of the early signs of ASD.

Previously and similarly, it has been hypothesized that the dissolution of the cortical subplate in the sensorimotor cortex around 3 months post-term largely facilitates the predictive value of general movement assessment.⁵⁸ In ASD, the suggested course of events is the following. The altered dissolution of the subplate in the fronto-temporo-parietal areas and the dissolution of the cerebellar EGL may facilitate the expression of signs of impaired social communication. Likewise, the dissolution of the cerebellar EGL and the altered dissolution of the subplate in the parietal cortex may promote the expression of motor signs, that is, impaired adaptability giving rise to slower motor development and the emergence of repetitive motor sequences.^{32,38,67,68}

CONCLUSION

Children with ASD have an altered development of the social brain, with prominent atypical features in the fronto-temporo-parietal cortex and cerebellum. The early specific signs of ASD emerge between 6 and 12 months. They consist of reduced social communication, slightly less advanced motor development (with performances that mostly fall within the typical range), and the emergence of repetitive behaviour. This means that the signs appear in the period that is typically characterized by rapid improvements in social communication and adaptability

in motor behaviour. Social communication is mediated by the social brain with prominent roles of the fronto-temporo-parietal cortex and cerebellum, whereas the fronto-parietal-cerebellar networks are involved in the preprogrammed selection of movement sequences. The latter may not only result in adaptive movements, but also in repetitive behaviour. In the first postnatal year, these parts of the brain are characterized by the gradual dissolution of temporary structures, that is, major parts of the subplate in the fronto-temporo-parietal cortex and the EGL in the cerebellum. This means that in the second half of the first year, the brain gradually gets rid of almost all of its transient fetal structures. Simultaneously, the developing permanent circuitries get fully in charge of behavioural programming. It is therefore conceivable that the altered dissolution of the temporary structures opens the window for the emergence of the early signs of ASD. This hypothesis is supported by the finding that screening questionnaires¹⁹ and spontaneously uttered parental concerns²¹ in infants with high familial risk have predictive value from 12 months onwards, that is, from the age that the transient fetal structures have largely disappeared.


ACKNOWLEDGMENTS

I thank the skilful technical assistance of Ms Anneke Kracht in the preparation of Figure 1. I also gratefully acknowledge the critical and constructive comments of Schirin Ahkbari Ziegler, Roelof Hadders, Patricia van Iersel, and Uta Tacke on a previous draft of the manuscript.

DATA AVAILABILITY STATEMENT

The paper is based on publicly available literature

ORCID

Mijna Hadders-Algra  <https://orcid.org/0000-0001-6845-5114>

REFERENCES

- Lord C, Elsabbagh M, Baird G, Veenstra-Vanderweele J. Autism spectrum disorder. *Lancet*. 2018; 392: 508–20. doi: [https://doi.org/10.1016/S0140-6736\(18\)31129-2](https://doi.org/10.1016/S0140-6736(18)31129-2).
- Happé F, Frith U. Annual Research Review: Looking back to look forward – changes in the concept of autism and implications for future research. *J Child Psychol Psychiatry*. 2020; 61: 218–32. doi: <https://doi.org/10.1111/jcpp.13176>.
- Müller RA, Fishman I. Brain connectivity and neuroimaging of social networks in autism. *Trends Cogn Sci*. 2018; 22: 1103–16. doi: <https://doi.org/10.1016/j.tics.2018.09.008>.
- van 't Hof M, Tisseur C, van Berckeleer-Onnes I, et al. Age at autism spectrum disorder diagnosis: A systematic review and meta-analysis from 2012 to 2019. *Autism*. 2021; 25: 862–73. doi: <https://doi.org/10.1177/1362361320971107>
- Ozonoff S, Iosif AM. Changing conceptualizations of regression: What prospective studies reveal about the onset of autism spectrum disorder. *Neurosci Biobehav Rev*. 2019; 100: 296–304. doi: <https://doi.org/10.1016/j.neubiorev.2019.03.012>.
- Tanner A, Dounavi K. The emergence of autism symptoms prior to 18 months of age: A systematic literature review. *J Autism Dev Disord*. 2021; 51: 973–93. doi: <https://doi.org/10.1007/s10803-020-04618-w>.
- Lim YH, Licari M, Spittle AJ, et al. Early motor function of children with autism spectrum disorder: A systematic review. *Pediatrics*. 2021; 147: e2020011270. doi: <https://doi.org/10.1542/peds.2020-011270>.
- Hull JV, Dokovna LB, Jacokes ZJ, Torgerson CM, Irimia A, Van Horn JD. Resting-state functional connectivity in autism spectrum disorders: A review. *Front Psychiatry*. 2017; 7: 205. doi: <https://doi.org/10.3389/fpsy.2016.00205>.
- Fetit R, Hillary RF, Price DJ, Lawrie SM. The neuropathology of autism: A systematic review of post-mortem studies of autism and related disorders. *Neurosci Biobehav Rev*. 2021; 129: 35–62. doi: <https://doi.org/10.1016/j.neubiorev.2021.07.014>.
- Kostović I. The enigmatic fetal subplate compartment forms an early tangential cortical nexus and provides the framework for construction of cortical connectivity. *Prog Neurobiol*. 2020; 194: 101883. doi: <https://doi.org/10.1016/j.pneurobio.2020.101883>.
- Hadders-Algra M. Early human brain development: Starring the subplate. *Neurosci Biobehav Rev*. 2018; 92: 276–90. doi: <https://doi.org/10.1016/j.neubiorev.2018.06.017>.
- Klin A, Micheletti M, Klaiman C, Shultz S, Constantino JN, Jones W. Affording autism an early brain development re-definition. *Dev Psychopathol*. 2020; 32: 1175–89. doi: <https://doi.org/10.1017/S0954579420000802>.
- Plate S, Yankowitz L, Resorla L, et al. Infant vocalizing and phenotypic outcomes in autism: Evidence from the first 2 years. *Child Dev*. 2022; 93: 468–83. doi: <https://doi.org/10.1111/cdev.13697>
- Klin A, Shultz S, Jones W. Social visual engagement in infants and toddlers with autism: early developmental transitions and a model of pathogenesis. *Neurosci Biobehav Rev*. 2015; 50: 189–203. doi: <https://doi.org/10.1016/j.neubiorev.2014.10.006>.
- Constantino JN, Kennon-McGill S, Weichselbaum C, et al. Infant viewing of social scenes is under genetic control and is atypical in autism. *Nature*. 2017; 547: 340–4. doi: <https://doi.org/10.1038/nature22999>.
- Mundy P. A review of joint attention and social-cognitive brain systems in typical development and autism spectrum disorder. *Eur J Neurosci*. 2018; 47: 497–514. doi: <https://doi.org/10.1111/ejn.13720>.
- Nyström P, Thorup E, Bölte S, Falck-Ytter T. Joint attention in infancy and the emergence of autism. *Biol Psychiatry*. 2019; 86: 631–38. doi: <https://doi.org/10.1016/j.biopsych.2019.05.006>.
- Gaffrey MS, Markert S, Yu C. Social origins of self-regulated attention during infancy and their disruption in autism spectrum disorder: implications for early intervention. *Dev Psychopathol*. 2020; 32: 1362–74. doi: <https://doi.org/10.1017/S0954579420000796>.
- Hadders-Algra M. Early diagnostics and early intervention in neurodevelopmental disorders: Age-dependent challenges and opportunities. *J Clin Med*. 2021; 10: 861. doi: <https://doi.org/10.3390/jcm10040861>.
- Sacreay LA, Zwaigenbaum L, Bryson S, et al. Can parents' concerns predict autism spectrum disorder? A prospective study of high-risk siblings from 6 to 36 months of age. *J Am Acad Child Adolesc Psychiatry*. 2015; 54: 470–8. doi: <https://doi.org/10.1016/j.jaac.2015.03.014>.
- Tran AT, Del Rosario M, Nosco E, et al. Early concerns in parents of infants at risk for autism. *Dev Med Child Neurol*. 2021; 63: 1410–6. doi: <https://doi.org/10.1111/dmnc.14925>.
- Gunderson J, Worthley E, Grzadzinski R, et al. Social and non-social sensory responsiveness in toddlers at high-risk for autism spectrum disorder. *Autism Res*. 2021; 14: 2143–55. doi: <https://doi.org/10.1002/aur.2556>.
- Baranek GT, Watson LR, Boyd BA, Poe MD, David FJ, McGuire L. Hyporesponsiveness to social and nonsocial sensory stimuli in children with autism, children with developmental delays, and typically developing children. *Dev Psychopathol*. 2013; 25: 307–20. doi: <https://doi.org/10.1017/S0954579412001071>
- Purpura G, Costanzo V, Chericoni N, et al. Bilateral patterns of repetitive movements in 6- to 12-month-old infants with autism spectrum disorder. *Front Psychol*. 2017; 8: 1168. doi: <https://doi.org/10.3389/fpsyg.2017.01168>.
- Choi B, Leech KA, Tager-Flusberg H, Nelson CA. Development of fine motor skills is associated with expressive language outcomes in infants at high and low risk for autism spectrum disorder. *J Neurodev Disord*. 2018; 10: 14. doi: <https://doi.org/10.1186/s11689-018-9231-3>.
- Hadders-Algra M. Human face and gaze perception is highly context specific and involves bottom-up and top-down neural processing. *Neurosci Biobehav Rev*. 2022;132: 304–23. doi: <https://doi.org/10.1016/j.neubiorev.2021.11.042>.
- Courchesne E, Gazestani VH, Lewis NE. Prenatal origins of ASD: The when, what and how of ASD Development. *Trends Neurosci*. 2020; 43: 326–42. doi: <https://doi.org/10.1016/j.tins.2020.03.005>.
- Hutsler JJ, Casanova MF. Review: cortical construction in autism spectrum disorder: columns, connectivity and the subplate. *Neuropathol Appl Neurobiol*. 2016; 42: 115–34. doi: <https://doi.org/10.1111/nan.12227>.
- Avino T, Hutsler JJ. Supernumerary neurons within the cerebral cortical subplate in autism spectrum disorders. *Brain Res*. 2021; 1760: 147350. doi: <https://doi.org/10.1016/j.brainres.2021.147350>.
- Hiremath CS, Sagar KJV, Yamini BK, et al. Emerging behavioral and neuroimaging biomarkers for early and accurate characterization of autism spectrum disorders: a systematic review. *Transl Psychiatry*. 2021; 11: 42. doi: <https://doi.org/10.1038/s41398-020-01178-6>.
- Cárdenas-de-la-Parra A, Lewis JD, Fonov VS, et al. A voxel-wise assessment of growth differences in infants developing autism spectrum disorder. *Neuroimage Clin*. 2021; 29:102551. doi: <https://doi.org/10.1016/j.nicl.2020.102551>.
- Wolff JJ, Swanson MR, Elison JT, et al. Neural circuitry at age 6 months associated with later repetitive behavior and sensory responsiveness in autism. *Mol Autism*. 2017; 8: 8. doi: <https://doi.org/10.1186/s13229-017-0126-z>.
- Van Rooij D, Anagnostou E, Arango C, et al. Cortical and subcortical brain morphometry differences between patients with autism spectrum disorder and healthy individuals across the lifespan: Results from the ENIGMA ASD Working Group. *Am J Psychiatry*. 2018; 175: 359–69. doi: <https://doi.org/10.1176/appi.ajp.2017.17010100>.
- Ciarrusta J, O'Muircheartaigh J, Dimitrova R, et al. Social brain functional maturation in newborn infants with and without a family history of autism spectrum disorder. *JAMA Netw Open*. 2019; 2: e191868. doi: <https://doi.org/10.1001/jamanetworkopen.2019.1868>.
- Rolison M, Lacadie C, Chawarska K, Spann M, Scheinost D. Atypical intrinsic hemispheric interaction associated with autism spectrum disorder is present within the first year of life. *Cereb Cortex*. 2022; 32: 1212–22. doi: <https://doi.org/10.1093/cercor/bhab284>.
- Nair A, Jalal R, Liu J, et al. Altered thalamocortical connectivity in 6-week-old infants at high familial risk for autism spectrum disorder. *Cereb Cortex*. 2021; 31: 4191–205. doi: <https://doi.org/10.1093/cercor/bhab078>.

37. Dickinson A, Daniel M, Marin A, *et al.* Multivariate neural connectivity patterns in early infancy predict later autism symptoms. *Biol Psychiatry Cogn Neurosci Neuroimaging*. 2021; 6: 59–69. doi: <https://doi.org/10.1016/j.bpsc.2020.06.003>.
38. Pote I, Wang S, Sethna V, *et al.* Familial risk of autism alters subcortical and cerebellar brain anatomy in infants and predicts the emergence of repetitive behaviors in early childhood. *Autism Res*. 2019; 12: 614–27. doi: <https://doi.org/10.1002/aur.2083>.
39. Robertson CE, Baron-Cohen S. Sensory perception in autism. *Nat Rev Neurosci*. 2017; 18: 671–84. doi: <https://doi.org/10.1038/nrn.2017.112>.
40. Frazier TW, Strauss M, Klingemier EW, *et al.* A meta-analysis of gaze differences to social and nonsocial information between individuals with and without autism. *J Am Acad Child Adolesc Psychiatr*. 2017; 56: 546–555. doi: <https://doi.org/10.1016/j.jaac.2017.05.005>.
41. Griffin JW, Bauer R, Scherf KS. A quantitative meta-analysis of face recognition deficits in autism: 40 years of research. *Psychol Bull*. 2021; 147: 268–92. doi: <https://doi.org/10.1037/bul0000310>.
42. De Verdier K, Ulla E, Löfgren S, Fernell E. Children with blindness – major causes, developmental outcomes and implications for habilitation and educational support: a two-decade, Swedish population-based study. *Acta Ophthalmol*. 2018; 96: 295–300. doi: <https://doi.org/10.1111/aos.13631>.
43. Chokron S, Kovarski K, Zalla T, Dutton GN. The inter-relationship between cerebral visual impairment, autism and intellectual disability. *Neurosci Biobehav Rev*. 2020; 114: 201–10. doi: <https://doi.org/10.1016/j.neubiorev.2020.04.008>.
44. Sonksen PM, Dale N. Visual impairment in infancy: impact on neurodevelopmental and neurobiological processes. *Dev Med Child Neurol*. 2002; 44: 782–91. doi: <https://doi.org/10.1017/s0012162201002936>.
45. Heyes C, Catmur C. What happened to mirror neurons? *Perspect Psychol Sci*. 2022; 17: 153–68. doi: <https://doi.org/10.1177/1745691621990638>.
46. Edwards LA. A meta-analysis of imitation abilities in individuals with autism spectrum disorders. *Autism Res*. 2014; 7: 363–80. doi: <https://doi.org/10.1002/aur.1379>.
47. Happé F, Cook JL, Bird G. The structure of social cognition: In(ter)dependence of sociocognitive processes. *Annu Rev Psychol*. 2017; 68: 243–67. doi: <https://doi.org/10.1146/annurev-psych-010416-044046>.
48. Cracco E, Bardi L, Desmet C, *et al.* Automatic imitation: A meta-analysis. *Psychol Bull*. 2018; 144: 453–500. doi: <https://doi.org/10.1037/bul0000143>.
49. Chan MMY, Han YMY. Differential mirror neuron system (MNS) activation during action observation with and without social-emotional components in autism: a meta-analysis of neuro-imaging studies. *Mol Autism*. 2020; 11: 72. doi: <https://doi.org/10.1186/s13229-020-00374-x>.
50. Albajara Sáenz A, Villemonteix T, Van Schuerbeek P, *et al.* Motor abnormalities in Attention-Deficit/Hyperactivity Disorder and autism spectrum disorder are associated with regional grey matter volumes. *Front Neurol*. 2021; 12: 666980. doi: <https://doi.org/10.3389/fneur.2021.666980>.
51. Miller HL, Sherrod GM, Mauk JE, Fears NE, Hynan LS, Tamplin PM. Shared features or co-occurrence? Evaluating symptoms of developmental coordination disorder in children and adolescents with autism spectrum disorder. *J Autism Dev Disord*. 2021; 51: 3443–55. doi: <https://doi.org/10.1007/s10803-020-04766-z>.
52. Wang LAL, Petrulla V, Zampella CJ, Waller R, Schultz RT. Gross motor impairment and its relation to social skills in autism spectrum disorder: A systematic review and two meta-analysis. *Psychol Bull*. 2022, epub ahead of print. doi: <https://doi.org/10.1037/bul0000358>.
53. Sacrey LA, Germani T, Bryson SE, Zwaigenbaum L. Reaching and grasping in autism spectrum disorder: a review of recent literature. *Front Neurol*. 2014; 5: 6. doi: <https://doi.org/10.3389/fneur.2014.00006>.
54. Subara-Zukic E, Cole MH, McGuckian TB, *et al.* Behavioral and neuroimaging research on developmental coordination disorder (DCD): A combined systematic review and meta-analysis of recent findings. *Front Psychol*. 2022; 13: 809455. doi: <https://doi.org/10.3389/fpsyg.2022.809455>.
55. Wymbs NF, Nebel MB, Ewen JB, Mostofsky SH. Altered inferior parietal functional connectivity is correlated with praxis and social skill performance in children with autism spectrum disorder. *Cereb Cortex*. 2021; 31: 2639–52. doi: <https://doi.org/10.1093/cercor/bhaa380>.
56. Wang Z, Wang Y, Sweeney JA, Gong Q, Lui S, Mosconi MW. Resting-state brain network dysfunctions associated with visuomotor impairments in autism spectrum disorder. *Front Integr Neurosci*. 2019; 13: 17. doi: <https://doi.org/10.3389/fnint.2019.00017>.
57. Hau J, Kohli JS Shryock I, *et al.* Supplementary and premotor aspects of the corticospinal tract show links with restricted and repetitive behaviors in middle-aged adults with autism spectrum disorder. *Cereb Cortex*. 2021; 31: 3962–72. doi: <https://doi.org/10.1093/cercor/bhab062>.
58. Hadders-Algra M. Neural substrate and clinical significance of general movements: An update. *Dev Med Child Neurol*. 2018; 60: 39–46. doi: <https://doi.org/10.1111/dmcn.13540>.
59. Hadders-Algra M. Atypical motor development of the foetus and young infant. In: Hadders-Algra M, editor. *Early dection and early intervention in developmental motor disorders – from neuroscience to participation*. London: Mac Keith Press, 2021.
60. Wilson RB, Vangala S, Elashoff D, Safari T, Smith BA. Using wearable sensor technology to measure motion complexity in infants at high familial risk for autism spectrum disorder. *Sensors (Basel)*. 2021; 21: 616. doi: <https://doi.org/10.3390/s21020616>.
61. Hadders-Algra M. Early human motor development: From variation to the ability to vary and adapt. *Neurosci Biobehav Rev*. 2018; 90: 411–27. doi: <https://doi.org/10.1016/j.neubiorev.2018.05.009>.
62. Joyce C, Honey E, Leekam SR, Barrett SL, Rodgers J. Anxiety, intolerance of uncertainty and restricted and repetitive behaviour: Insights directly from young people with ASD. *J Autism Dev Disord*. 2017; 47: 3789–802. doi: <https://doi.org/10.1007/s10803-017-3027-2>.
63. Kostović I, Jovanov-Milošević N, Radoš M, *et al.* Perinatal and early postnatal reorganization of the subplate and related cellular compartments in the human cerebral wall as revealed by histological and MRI approaches. *Brain Struct Funct*. 2014; 219: 231–53. doi: <https://doi.org/10.1007/s00429-012-0496-0>.
64. Luhmann HJ, Kirischuk S, Kilb W. The superior function of the subplate in early neocortical development. *Front Neuroanat*. 2018; 12: 97. doi: <https://doi.org/10.3389/fnana.2018.00097>.
65. Carroll L, Braeutigam S, Dawes JM, *et al.* Autism spectrum disorders: Multiple routes to, and multiple consequences of, abnormal synaptic function and connectivity. *Neuroscientist*. 2021; 27: 10–29. doi: <https://doi.org/10.1177/1073858420921378>.
66. Montanari M, Martella G, Bonsi P, Meringolo M. Autism spectrum disorder: Focus on glutamatergic neurotransmission. *Int J Mol Sci*. 2022; 23: 3861. doi: <https://doi.org/10.3390/ijms23073861>.
67. Andersen RA, Cui H. Intention, action planning, and decision making in parietal-frontal circuits. *Neuron*. 2009; 63: 568–83. doi: <https://doi.org/10.1016/j.neuron.2009.08.028>.
68. Frosch IR, Mittal VA, D'Mello AM. Cerebellar contributions to social cognition in ASD: A predictive processing framework. *Front Integr Neurosci*. 2022; 16: 810425. doi: <https://doi.org/10.3389/fnint.2022.810425>.

How to cite this article: Hadders-Algra M. Emerging signs of autism spectrum disorder in infancy: putative neural substrate. *Dev Med Child Neurol*. 2022;64(11): 1344–1350. <https://doi.org/10.1111/dmcn.15333>