

Retrospective evaluation of hypertrophic cardiomyopathy in 68 dogs

Karsten E. Schober¹  | Phillip R. Fox²  | Jonathan Abbott³  | Etienne Côté⁴ | Virginia Luis-Fuentes⁵  | Jose Novo Matos^{5,6}  | Joshua A. Stern⁷ | Lance Visser⁷  | Katherine F. Scollan⁸ | Valerie Chetboul⁹  | Donald Schrope¹⁰ | Tony Glaus⁶ | Roberto Santilli¹¹  | Romain Pariaut¹² | Rebecca Stepien¹³ | Vanessa Arqued-Soubeyran⁴ | Marco Baron Toaldo⁶  | Amara Estrada¹⁴ | Kristin MacDonald¹⁵ | Emily T. Karlin¹⁶ | John Rush¹⁶ 

¹Department of Veterinary Clinical Sciences, The Ohio State University, Columbus, Ohio, USA

²Department of Cardiology, The Animal Medical Center, New York, New York, USA

³Department of Small Animal Clinical Sciences, University of Tennessee, Knoxville, Tennessee, USA

⁴Ecole Nationale Vétérinaire d'Alfort, Unité de Cardiologie d'Alfort (UCA), Université Paris-Est, Maisons-Alfort, France

⁵Clinical Sciences and Services, Royal Veterinary College, London, UK

⁶Clinic for Small Animal Internal Medicine, University of Zürich, Zürich, Switzerland

⁷Department of Medicine and Epidemiology, University of California, Davis, California, USA

⁸Department of Clinical Sciences, Oregon State University, Corvallis, Oregon, USA

⁹Atlantic Veterinary College, University of Prince Edward Island, Prince Edward Island, Canada

¹⁰Department of Cardiology, Oradell Animal Hospital, Paramus, New Jersey, USA

¹¹Clinica Veterinaria Malpensa, Samarate-Varese, Italy

Abstract

Background: There is a lack of clinical data on hypertrophic cardiomyopathy (HCM) in dogs.

Hypothesis/Objectives: To investigate signalment, clinical signs, diagnostic findings, and survival in dogs with HCM.

Animals: Sixty-eight client-owned dogs.

Methods: Retrospective multicenter study. Medical records were searched between 2003 and 2015. The diagnosis of left ventricular (LV) hypertrophy was made by echocardiographic examination.

Results: Three hundred and forty-five dogs with LV hypertrophy were identified, of which 277 were excluded. The remaining 68 dogs were 0.3 to 14 years old and predominantly <10 kg (85%), and without a sex predilection. Twenty-four % were Shih Tzu and 24% terrier breeds. Most (80%) had a systolic heart murmur. Owner-determined exercise intolerance (37%) and syncope (18%) were most commonly reported signs. The majority (84%) of dogs had symmetrical LV hypertrophy, whereas asymmetrical septal and LV free wall hypertrophy was observed in 9% and 6% of dogs, respectively. Isolated basal interventricular septal hypertrophy was not observed. Commonly recorded were systolic anterior motion of the mitral valve (60%) and LV diastolic dysfunction (89% of dogs where diastolic function was

Abbreviations: 2D, 2-dimensional; A, peak velocity of late diastolic transmitral flow; Ao, aortic valve dimension; A-V, atrioventricular; BW, body weight; CFD, color flow Doppler; CHF, congestive heart failure; DLVOTO, dynamic left ventricular outflow tract obstruction; E, peak velocity of early diastolic transmitral flow; HCM, hypertrophic cardiomyopathy; IVSd, thickness of the interventricular septum at end-diastole; LA, left atrial; LAD, maximum left atrial dimension; LADN, normalized maximum left atrial dimension; LV, left ventricular; LVD, left ventricular dimension; LVDd, left ventricular dimension at end-diastole; LVDDN, normalized left ventricular end-diastolic dimension; LVFWd, thickness of the left ventricular free wall at end-diastole; LVOTO, left ventricular outflow tract obstruction; NSA, normal sinus arrhythmia; NSR, normal sinus rhythm; PAC, premature atrial contraction; PVC, premature ventricular contraction; RAD, right atrial dimension; RVD, right ventricular dimension; RVFW, right ventricular free wall; SAM, systolic anterior motion of the mitral valve leaflets; SD, sudden death; Vmax, maximum velocity.

This is an open access article under the terms of the [Creative Commons Attribution-NonCommercial-NoDerivs](https://creativecommons.org/licenses/by-nc-nd/4.0/) License, which permits use and distribution in any medium, provided the original work is properly cited, the use is non-commercial and no modifications or adaptations are made.

© 2022 The Authors. *Journal of Veterinary Internal Medicine* published by Wiley Periodicals LLC on behalf of American College of Veterinary Internal Medicine.

¹²Department of Clinical Sciences, Cornell College of Veterinary Medicine, Ithaca, New York, USA

¹³Department of Medical Sciences, University of Wisconsin School of Veterinary Medicine, Madison, Wisconsin, USA

¹⁴Department of Small Animal Clinical Sciences, University of Florida, Gainesville, Florida, USA

¹⁵VCA Animal Care Center, Rohnert Park, California, USA

¹⁶Cummings School of Veterinary Medicine, Tufts University, North Grafton, Massachusetts, USA

Correspondence

Karsten E. Schober, Department of Veterinary Clinical Sciences, The Ohio State University, 601 Vernon L Tharp Street, Columbus, OH 43210, USA.
 Email: schober.4@osu.edu

evaluated). Six dogs died unexpectedly, and 3 developed congestive heart failure. Known survival times were between 1 day and 114 months after diagnosis.

Conclusions and Clinical Importance: Hypertrophic cardiomyopathy in dogs should be considered as a differential diagnosis if LV hypertrophy is identified. Small breed dogs are overrepresented, and it is uncommon for dogs with HCM to develop CHF although sudden death can occur.

KEYWORDS

canine, dynamic outflow tract obstruction, HCM, LV hypertrophy, veterinary

1 | INTRODUCTION

Hypertrophic cardiomyopathy (HCM) is rare in dogs when compared to cats and humans with, to the authors knowledge, fewer than 30 cases documented in either single case reports¹⁻⁵ or small case series.⁶⁻¹¹ Based on earlier publications, the majority of dogs identified have been males, diagnosed before to 3 years of age, and of large breed (eg, Rottweilers, Pointers, Dalmatians, and German shepherds).^{7,9,12,13-15} However, later studies confirmed that HCM in dogs can be identified at any age, with no sex predilection, and often in small breed dogs.^{1,3,4,8}

Similar to HCM in cats,¹⁶ HCM in dogs seems to differ from human HCM in several aspects, including frequent absence of both disproportionate hypertrophy of the interventricular septum and myocardial fiber disarray.^{11,12,17-19} Moreover, while dynamic left ventricular (LV) outflow tract (LVOT) obstruction (DLVOTO) is common in cats and people and part of the phenotypic and functional spectrum of HCM,^{16,18,20} these relationships are unknown in dogs with HCM. Further, any association between HCM with DLVOTO and mitral valve malformation remains uncertain in the dog.^{1,9,13,15,21-24}

While major efforts were made in the 1980s and 1990s to summarize diagnostic findings in dogs with HCM, there has been a paucity of data on this entity in the past 30 years. In addition, echocardiography was rarely used in these earlier studies, and blood pressure was not evaluated in most dogs,^{6,7,11,12,17,25} casting doubts on the clinical diagnosis of HCM. No systematic research on HCM in dogs with regard to epidemiology and diagnostic findings has been reported. Therefore, our objective was to investigate signalment, clinical and diagnostic findings, and outcome in a large sample of dogs with HCM.

2 | MATERIALS AND METHODS

This retrospective study did not need approval by local authorities.

2.1 | Definitions and data acquisition

For the purpose of this study, HCM was defined as echocardiographically-demonstrated LV concentric hypertrophy in the absence of another known cardiac, systemic, or metabolic disease capable of producing the magnitude of LV wall thickening evident.²⁶ Study planning and data acquisition started in January 2014 and were completed by January 2017. Seventeen board-certified cardiologists practicing at referral academic or private veterinary hospitals were invited to identify and submit suitable cases. A study proposal including a list of potential investigators, background information and literature review on HCM in dogs, objectives of the study, summary of study methods, time frame for data acquisition, and investigator roles regarding data analysis, manuscript writing, and publication was sent to all participants. Three additional instructional files were provided to all investigators to favor consistency of data acquisition: a Power Point file with 16 illustrated slides on echocardiographic imaging views and measurement technique to be used; an echocardiography measurement form including 25 measured variables, 7 calculated variables, and 13 subjective variables; and an Excel spreadsheet for final data entry. Investigators were instructed to search their medical record data base between 2003 and 2015 for entries in the diagnosis field using the search terms “HCM,” “hypertrophic cardiomyopathy,” “canine HCM,” “left ventricular hypertrophy,” “LV hypertrophy,” and “canine LV hypertrophy.” Cases identified underwent a thorough review of the medical record at the investigator's site, remeasurement and reanalysis of all echocardiographic data, and (if available) selection of representative images and video loops to be sent to the principal investigator for final case review (but not remeasurement).

Inclusion criteria were HCM as determined by echocardiography, based on a combination of both subjective and objective echocardiographic criteria (see “Echocardiography,” below). Exclusion criteria were a systolic blood pressure >160 mm Hg, absent blood pressure data, dehydration,^{27,28} recent blood loss, cancer, treatment with

diuretics (within the last 14 days),²⁸ administration of L-thyroxine or phenylpropanolamine, systemic disease possibly affecting the cardiovascular system, endocrinopathies (hyperadrenocorticism,²⁹ diabetes mellitus, known pheochromocytoma), known kidney disease (all IRIS stages), pulmonary thromboembolism, heartworm disease, congenital heart disease, poor echocardiographic image quality, and dogs with evidence of mitral valve malformation^{2,9,13,21,22} as assessed by the on-site investigator. Investigators were also instructed to identify age, sex, and body weight (BW)-matched healthy dogs for each dog with HCM enrolled and examined during the case acquisition period and measure their echocardiograms using the same diagnostic methods. These dogs were to serve as a control group for LV wall thickness measurements. However, as investigator submission rate of case-control dogs was only approximately 25%, it was decided later to instead use case-control dogs from a recently published study of normal dogs³⁰ in order to find an age and BW match for each study dog enrolled (details are explained later under paragraph “Echocardiography”). Addition of a control group was deemed necessary because 2-dimensional (2D) reference values of LV wall thickness with consideration to body weight and breed, were not available. Therefore, including control dogs served as an additional quality control measure aimed at ensuring correct case inclusion. Finally, investigators were directed to provide outcome and survival data based upon medical record review and/or by telephone interview of the dog owners.

2.2 | Echocardiography

Transthoracic echocardiographic examinations were performed in all dogs using standard techniques and right and left parasternal long- and short-axis imaging views.^{30,31} Measurements similar to those in cats with HCM³² were obtained as an average of 3 to 5 cardiac cycles, regardless of respiratory phase. For LV wall thickness, the largest dimension derived either from short-axis or long-axis 2D images was considered for final data analysis. The diagnosis of HCM was made by 4 methods, all of which had to conclude that LV hypertrophy was present: the initial assessment was made by the site investigator using, first, subjective diagnosis (visual evaluation of wall thickness by comparison to internal reference structures, personal experience and opinion, and consideration of expected findings in normal dogs) and, second, increased end-diastolic LV wall thickness based on the site-investigators commonly used echocardiographic reference values. If inclusion criteria of the study were met, wall thickness was remeasured using methods as outlined in the study protocol, and the case material was forwarded to the principal investigator for validation. Third, submitted LV wall thickness data were then compared with data of age, sex, and body-weight matched case-control dogs for initial confirmation. To qualify for the diagnosis of LV hypertrophy, affected dogs had to have increased LV wall thickness compared to control that was beyond reported measurement variability for LV wall thickness measurements in healthy dogs. A diagnostic cut-off of 20% above the value of the matched control dog considering the combined predicted intra- and interobserver measurement variability as well as

the between-day measurement variability was used.³³⁻³⁵ Finally, the diagnosis of LV hypertrophy had to include increased LV wall thickness measurements above the 95% prediction intervals of allometrically scaled 2D echocardiographic wall thickness measurements derived from a population of 122 healthy dogs. While in the latter study³⁰ normalized maximum left atrial dimensions (LADN) and normalized left ventricular end-diastolic dimensions (LVDDN) were reported, allometrically-scaled LV wall thickness measurements were missing. Therefore, 2D LV wall thickness data acquired from this population³⁰ were provided and the allometric scaling exponents for IVSd and LVFWd computed (L Visser, personal communication). Relative LV wall thickness (IVSd + LVFWd/LVDDd) indicating presence and type (concentric vs eccentric) of LV hypertrophy^{36,37} was also determined using both right parasternal long-axis and short-axis views. Published reference values (mean ± 2SD) in normal small and large breed dogs (0.53 ± 0.22 and 0.47 ± 0.22, respectively) were used for comparison.³⁷ Asymmetrical septal and asymmetrical LV free wall thickening was considered if the ratio of interventricular septal thickness at end-diastole (IVSd) and LV free wall thickness at end-diastole (LVFWd; IVSd : LVFWd) was >1.30 and <0.70, respectively.^{2,17,18} Left atrial enlargement was diagnosed using 95% prediction intervals of allometrically-scaled data.³⁰ Color flow (CFD) and spectral Doppler echocardiography was used to identify and quantify dynamic LVOTO, detect valve regurgitation, and to rule out congenital heart disease.

From the 2D right-parasternal 4-chamber long-axis view, maximum LA dimension (LAD) was measured midchamber at end-systole (of the ventricle) using a line drawn approximately parallel to the mitral annulus. This measurement extended from the inner edge of the region of the fossa ovale to the internal reflection of the bright (hyperechoic) pericardium in the far field.³⁸ The maximum right atrial dimension (RAD) was measured in a similar way. From the same 2D right parasternal 4-chamber long-axis imaging view and the 2D right parasternal short-axis imaging view at the level of the papillary muscles, maximum end-diastolic wall thickness of the LVFW, the RV free wall (RVFW), and the IVS was measured using the blood-pericardial and blood-tissue interface for measurements, respectively.³² Similarly, the minimum and maximum LV (LVD) and maximum RV (RVD) internal dimensions were measured. Maximum LVD was normalized to body weight using an allometric scaling method.³⁰ Left ventricular shortening fraction was calculated from M-mode right-parasternal long-axis or short-axis images.³⁹ The pattern of LV hypertrophy was classified into the following phenotypes by visual estimation and, if in doubt, results of electronic caliper measurements: using the right-parasternal 4-chamber long-axis view—symmetrical that included all wall segments and the papillary muscles, predominantly IVS (IVS at least 50% thicker than the LVFW), predominantly LVFW (LVFW at least 50% thicker than the IVS), predominantly the basilar half of the septum (basilar part of the IVS at least 50% thicker than the apical part) LV hypertrophy confined only to the basilar (most upper) IVS, and hypertrophy confined to the LV apex or, using the right-parasternal short-axis view—predominantly the papillary muscles (disproportionate thickening of the papillary muscles compared to both the IVS and LVFW based on subjective evaluation). Increased end-diastolic thickness of the RVFW was assessed subjectively (personal opinion based on experience,

consideration of expected data as found in healthy dogs, and qualitative comparison of RVFW thickness with the thickness of the IVS and the LVFW) as opposed to objectively by both the site investigators and the principal investigator (hypertrophy—yes/no). Presence of DLVOTO due to SAM of the mitral valve or muscular obstruction was evaluated using 2D and M-mode (systolic motion of the septal mitral valve leaflet toward the IVS), continuous wave Doppler (accelerated aortic flow >2.5 m/s with a “dagger”-shaped LV outflow signal demonstrating late systolic flow acceleration), and/or CFD (abnormal flow turbulence), while severity of obstruction was quantified with continuous wave Doppler peak flow velocities only. Mid-LV obstruction (yes/no) was subjectively assessed by CFD (flow turbulence) and quantified by continuous wave Doppler (peak flow velocity). Presence of mitral regurgitation (yes/no) was recorded. Malformation of the mitral valve^{2,9,13,21,22} was diagnosed subjectively by each investigator based on their judgment of echocardiographic appearance of leaflet and chordae tendineae morphology. This included valve thickness, leaflet motion, position and number of papillary muscles, relative length of the anterior leaflet, and direction of the mitral regurgitant jet. Short chordae tendineae, direct insertion of papillary muscles into mitral valve leaflets, unequivocally elongated septal mitral valve leaflets, or a mitral regurgitant jet directed toward the atrial septum were judged to be consistent with malformation of the mitral valve.

From right parasternal short-axis (cross sectional) images, LV and RV wall thickness and chamber dimensions and maximum flow velocity in the RV outflow tract were assessed. The right parasternal heart base view was used to quantify aortic valve dimension and LA dimension and computing the LA to aortic valve dimension ratio (LA : Ao).³⁸ The left apical 5-chamber view was used to measure peak velocity in the LV outflow tract using pulsed wave or continuous wave Doppler. From the left apical 4-chamber view, isovolumic relaxation time⁴⁰ and transmitral flow patterns were evaluated and class of diastolic function determined based on the E : A ratio.⁴¹ From the left parasternal 4-chamber view optimized for the RV inflow tract, RAD and RVD were measured and RV ventricular shortening fraction calculated.⁴² Presence and velocity of tricuspid regurgitation were noted.

2.3 | Other diagnostic methods

Noninvasive arterial blood pressure was measured in all dogs using various methods, depending upon the preference of each site-investigator. Information from thoracic radiographs taken in orthogonal views was available for some dogs. Presence of cardiomegaly and radiographic signs of heart failure were evaluated using standard methods. If available, single lead (recorded during the echocardiographic study) and 6-lead ECGs were evaluated.

2.4 | Statistical analysis

Statistical analyses were performed using commercial software (Statistical Analysis Software, version 9.4, SAS Institute, Inc, Cary, North Carolina and GraphPad Prism, version 8, GraphPad Software, Inc,

San Diego, California). Descriptive statistics are reported as mean and SD for normally distributed variables and median and interquartile range [IQR] for nonnormally distributed variables. Variables were tested for normality using visual inspection of data points and the Shapiro-Wilk test. Equality of variances was assured using an F-test. Logarithmic transformation was applied for selected variables due to the violation of normality assumption of residuals. Categorical variables were compared using chi-square statistics. Continuous variables were compared using a *t*-test or Mann-Whitney Rank Sum test, depending on the distribution of data. *P* values $<.05$ were considered significant.

3 | RESULTS

Data from 16 specialty hospitals were available for analysis. For 9 investigators the data search included a time period of 13 years (2003-2015), for 4 a search period of 7 years (2008-2015), and 3 investigators had no access to the full medical record data base and only submitted cases they remembered. One additional investigator who was invited did not provide data. A total of 345 dogs were identified. Of those, 258 were excluded at the local study sites after full case review. From the remaining 87 cases, 19 additional dogs were

TABLE 1 Reasons for exclusion from data analysis after review of initially identified cases (n = 277 dogs)

Reason	n
Systemic hypertension	104
Chronic kidney disease	78
Dehydration	24
Hyperadrenocorticism	17
Congenital heart disease	18
Blood pressure not recorded	12
Cancer	11
Poor echocardiographic image quality	11
Concurrent use of furosemide	10
Pheochromocytoma	10
Drugs possibly leading to LV hypertrophy	10
Hyperthyroidism or L-thyroxine supplementation	5
Subaortic stenosis	5
Severe systemic disease	5
Records not available	4
Diabetes mellitus	2
Severe pulmonary hypertension with LV underfilling	2
Polycythemia vera	2
Concurrent use of prednisone	2
Equivocal LV wall thickening	2
Amyloidosis	1
Severe arteriosclerosis	1

Note: Some dogs had multiple reasons for exclusion. Abbreviation: LV, left ventricular.

excluded after review of the submitted case information and echocardiographic data by the principal investigator. Reasons consisted of young dogs (<2 years) with severe DLVOTO and LV hypertrophy where a congenital mitral valve malformation could not be ruled out ($n = 5$), current use of furosemide ($n = 4$), blood pressure not recorded ($n = 3$), dehydration ($n = 3$), chronic kidney disease ($n = 3$), systemic hypertension ($n = 2$), equivocal echocardiographic data ($n = 2$), L-thyroxin supplementation, ongoing prednisone treatment, and systemic disease (each $n = 1$). Several dogs had multiple reasons for exclusion. Therefore, the final number of dogs identified and analyzed was 68/345 (20%). Reasons for exclusion of the 277 dogs are summarized in Table 1. Of dogs included, representative echocardiographic still frames and video loops were available for review by the principal investigator in 60 dogs (89%). The median number of cases submitted per center was 5 (range, 1-9).

Epidemiological data of study dogs and control dogs regarding age, BW, sex, and breed are summarized in Table 2. Most dogs (41/68; 60%) had some degree of DLVOTO associated with SAM. Distribution of age and body weight of the dogs is displayed in Figures 1 and 2. Arbitrarily grouped, 21 (31%) dogs were ≤ 2 years old, 19 (28%) were between >2 years and 6 years old, 13 (19%) were between >6 years and 10 years old, and 15 (22%) were >10 years old. Arbitrarily grouped, 28 dogs (41%) were <5 kg of body weight, 27 dogs (40%) were between 5 and 10 kg of body weight, and 13 dogs (19%) were >10 kg of body weight.

Comorbidities were detected in 31 dogs (45%) including upper airway (7 dogs; 11%), neurologic (5 dogs; 7%) and orthopedic diseases (4 dogs; 6%); ACVIM stage B1 myxomatous mitral valve disease (4 dogs; 6%); urinary tract, allergic, liver, immune-mediated, and skin disease (2 dogs each; 3%); and a benign mass (1 dog; 1%). In 37 (55%) dogs no concurrent disease or disorder was identified.

At the time of diagnosis, 41 dogs (60%) were not receiving medications, whereas 27 dogs (40%) were receiving medical therapy. This included 15 dogs taking cardiac medications (ACE inhibitor [7], atenolol [5], pimobendan [2], and spironolactone [1]); 5 dogs on antibiotics; 4 dogs on nonsteroidal anti-inflammatory drugs; 3 on gastrointestinal medications; and 1 each on phenobarbital, hydroxyzine, and inhaled fluticasone. Some dogs received on >1 medication. After echocardiographic diagnosis, 47 dogs (69%) were receiving medical therapy including 30 dogs (44%) treated with atenolol; 7 dogs (10%) treated with an ACE-inhibitor; 2 dogs (3%) each treated with sotalol, diltiazem, or spironolactone; 1 dog treated with digoxin, and 9 dogs (13%) treated with noncardiac medications. Six dogs (9%) were prescribed >1 medication.

Historical and diagnostic data (physical examination, ECG, and thoracic radiography) are summarized in Table 3. Exercise intolerance (owner-determined reluctance to exercise and/or tiring much more easily and sooner than usual) and syncope/collapse were the most commonly observed clinical findings. Blood pressure was reevaluated at least once in 39 (57%) dogs and was <160 mm Hg in all (median 75 days, 25/75 percentiles 30/160 days).

Table 4 and Figure 3 record selected echocardiographic findings. Most dogs (84%) had symmetrical LV hypertrophy. Considering both right parasternal short and long-axis images, the IVSd : LVFWd ratio was >1.30 in 4 (6%) dogs and < 0.70 in 2 (3%) dogs, indicating asymmetrical LV hypertrophy. Neither apical HCM nor LV hypertrophy confined to only the basilar IVS were observed. Relative LV wall thickness (median; 5/95 percentiles) from right parasternal long-axis and right parasternal short-axis measurements was 1.0 (0.67-1.92) and 0.98 (0.54-1.54), respectively. Mitral regurgitation was recorded in most dogs (49, 72%); 41 (60%) had LV shortening fraction >45% and 3 (4%) <25%; 15 (22%) had LA : Ao ≥ 1.60 ; 41 (60%) had a maximum LV outflow velocity > 2 m/s (mild to severe dynamic LVOTO),

TABLE 2 Age, body weight, sex, and breed of the study group and the control group

	Study	Control	P
n	68	68	
Age (y)	5.50 (3.0/10.0)	5.07 (3.32/6.93)	.33
BW (kg)	5.70 (3.65/9.15)	6.22 (3.96/10.10)	.3
Sex ^a (f/m)	38/30	34/34	.49
Breed (n)	16 Shih Tzu, 5 Chihuahua, 4 Boston terrier, 4 Maltese, 3 Fox terrier, 3 Pug, 3 Miniature dachshund, 3 miniature poodle, 3 Yorkshire terrier, 3 Dalmatian 2 German shepherd, 2 mixed breed, 2 Jack Russell terrier, 1 each: Rottweiler, Boxer, Maltipoo, Bassett hound, rat terrier, English bulldog, Cairn terrier, Feist terrier, Welsh terrier, Samoyed, Lhasa Apso, Golden retriever, Yugoslavian shepherd, Czechoslovakian wolfhound, and Shetland sheepdog	8 Terrier cross breed, 8 Chihuahua, 8 Yorkshire terrier, 6 Shih Tzu, 5 dachshund, 4 Maltese, 3 miniature poodle, 2 Jack Russell terrier, 2 Sarplaninac, 2 Fox terrier, 2 Golden retriever, 2 Maltipoo, 2 Bichon Frise, 2 German Shepherd dog 1 each: Collie, Labrador retriever, Papillon, American Pitbull, Australian shepherd, Havanese, German shorthair pointer, Cocker spaniel, Border Collie, English bulldog, Chow Chow, and French bulldog	

Note: Mean \pm SD or median (25/75 percentile).

Abbreviation: BW, body weight.

^aBoth intact and spayed/neutered.

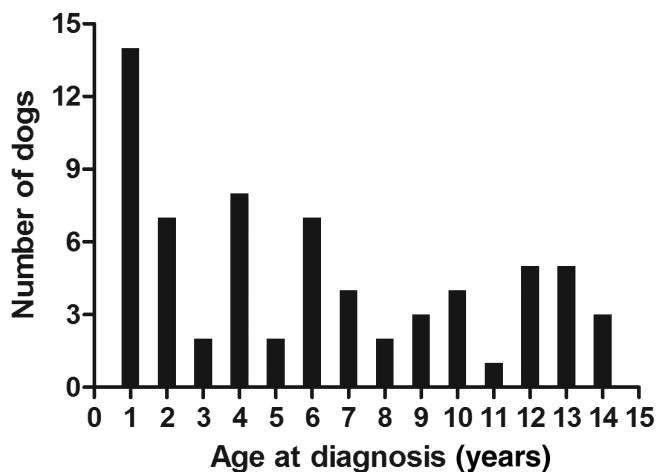


FIGURE 1 Age distribution of study dogs. The age numbers on the X-axis represent ranges (eg, 1 indicates ≤ 1 year; 2 indicates >1 year and ≤ 2 years; 3 indicates >2 years and ≤ 3 years)

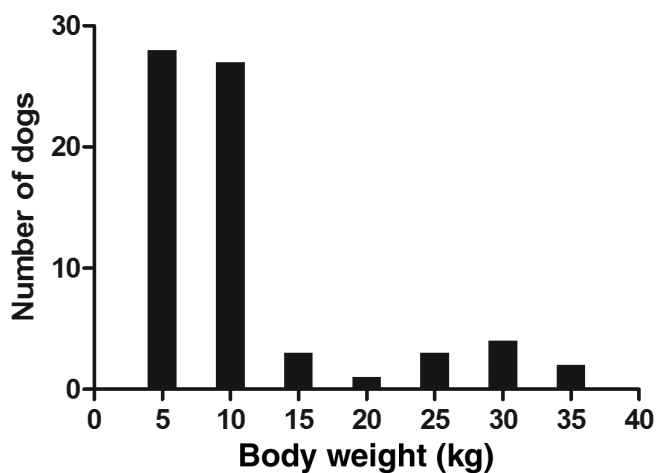


FIGURE 2 Body weight distribution of study dogs. The numbers on the X-axis represent ranges (eg, 5 indicates ≤ 5 kg; 10 indicates >5 kg and ≤ 10 kg; 15 indicates >10 kg and ≤ 15 kg)

including 16 (24%) dogs >4 m/s; 7 (10%) dogs had a maximum RV outflow tract velocity > 2 m/s (but <3 m/s in all corresponding to mild dynamic RV outflow tract obstruction); early transmitral diastolic flow velocity (E wave) was <1 m/s in all but 3 (6%) dogs in which it was recorded; and peak tricuspid regurgitation velocity was >3 m/s in 3 (17%) dogs (3.26, 3.27, and 3.52 m/s). Echocardiographic measures quantifying left-sided chamber dimension and wall thickness are listed in Table 5 and Figure 4. Considering the upper limit (97.5 percentile) of the prediction interval (normalized maximum left atrial dimension, $LADN = 1.57$),³⁰ 8 (12%) of the dogs had LA enlargement. Using the upper (97.5 percentile) and lower (2.5 percentile) limits of the prediction interval (normalized diastolic LVD [LVDDN], right-parasternal short-axis 2D measurement) of 1.62 and 1.16, respectively,³⁰ 47 (69%) dogs had a decreased LV end-diastolic diameter while no dog had LV dilation. Using LVDDN determined from right parasternal long-axis 2D measurements and a 97.5% prediction interval of 1.16 to

TABLE 3 History, physical examination, blood pressure, ECG, and radiographic findings in the study group at first examination

	Dogs (n = 68)
History and physical examination	
Heart murmur	54
Gallop sound	2
Exercise intolerance	25
Weakness	2
Syncope/collapse	12
Respiratory signs (non-CHF)	8
Respiratory signs (CHF)	3
Neurologic signs	6
Arrhythmia	2
Other clinical signs	10
No clinical signs	28
Blood pressure (mm Hg) ^a	131 \pm 18 (68-159)
ECG ^b	
NSR/NSA/sinus tachycardia	65
Atrial flutter	1
Second degree A-V block	2
AIVR	2
Supraventricular tachycardia	1
PACs	1
PVCs	13
R > 3.0 mV	9
ST depression >0.2 mV	9
Thoracic radiographs	
Cardiomegaly	15
Signs of left-sided CHF	2
Signs of biventricular CHF	1

Note: Complete data sets for ECG, determined in only 65 dogs and thoracic radiographs determined in only 16 dogs.

Abbreviations: AIVR, accelerated idioventricular rhythm; CHF, congestive heart failure; NSR/NSA, normal sinus rhythm/normal sinus arrhythmia; PAC, premature atrial complex; PVC, premature ventricular complex.

^aMean \pm SD (minimum – maximum).

^b6-Lead ECG or single lead ECG during echocardiography.

1.59,³⁰ 44 (65%) dogs had a reduced LV end-diastolic dimension. No dog had LVDDN above the upper limit of the 95% prediction interval.

At the end of the data acquisition period, 15 of the 68 dogs (22%) were dead and 28 (41%) alive. Twenty-five dogs (37%) were lost for follow up. Eight dogs died ascribed to HCM—6 dogs with sudden unexpected death (defined as the dog being found dead, or unexpected death as witnessed by the owner without prior clinical signs of illness), and 2 dogs with CHF. This was 12% of all dogs and 19% of the dogs not lost to follow-up. Signalment, age at diagnosis of HCM and cardiac death, time between diagnosis and cardiac death, and cause of death are summarized in Table 6. One dog was euthanized on the day of diagnosis at the owner's request without a reported reason. No dog was known to have clinical signs compatible with a

TABLE 4 Selected echocardiographic findings in the 68 study dogs

Heart rate (bpm)	134 ± 31
LA enlargement	8
Pattern of LV hypertrophy	
Symmetrical	57
Predominantly IVS	6
Predominantly LVFW	4
IVSd : LVFWd (right parasternal long-axis)	1.04 ± 0.25
IVSd : LVFWd (right parasternal short-axis)	1.05 ± 0.21
Papillary muscle hypertrophy only	1
Hypertrophy of the papillary muscles (subjective)	48
RV hypertrophy (subjective)	26
SAM	41
Mid-LV obstruction	9
Mitral insufficiency	49
Aortic insufficiency	10
LV shortening fraction (%)	50 ± 14
LA : Ao	1.45 ± 0.33
Vmax aorta (m/s)	2.47 (1.60/4.12)
IVRT (ms)	67 (61/81)
E (m/s)	0.70 ± 0.22
E : A	0.83 (0.57/1.32)
Diastolic filling pattern	
Normal	6
Delayed relaxation	31
Pseudonormal	12
Restrictive	5
Not recorded	14
RV shortening fraction (%)	48 ± 16
Tricuspid regurgitation	18
Dogs with follow-up information >2 years after diagnosis	22
Dogs with follow-up echocardiograms	26
Number of follow-up echocardiograms per dog	1-12
Time between echocardiograms (mo)	6-13

Note: Mean ± SD or median (25/75 percentile). Complete data sets, except for transmitral flow data (only 54 dogs). "Subjective" relates to visual (as opposed to objective/quantitative) evaluation of the anatomical site, comparison to internal reference structures, and personal opinion based on experience and consideration of findings as expected in normal dogs. "Symmetrical LV hypertrophy," hypertrophy including all wall segments and the papillary muscles. "Predominantly IVS," asymmetrical pattern of LV hypertrophy with the IVS at least 50% thicker than the LVFW. "Predominantly LVFW," asymmetrical pattern of LV hypertrophy with the LVFW at least 50% thicker than IVS.

Abbreviations: A, peak velocity of late diastolic transmitral flow; E : A, ratio between E and A; E, peak velocity of early diastolic transmitral flow; IVS, interventricular septum; LA : Ao, ratio between the left atrial (LA) dimension and the aortic valve (Ao) dimension from a right parasternal short axis view; LA, left atrial; LV, left ventricular; LVFW, left ventricular free wall; RV, right ventricular; SAM, systolic anterior motion of the mitral valve leaflets; Vmax, maximum velocity.

diagnosis of systemic arterial thromboembolism. Six dogs were euthanized for noncardiac reasons (3, 4, 12, 31, 31, and 48 months after diagnosis). Dogs that were alive at the end of the data acquisition period had survived a median of 20 months after diagnosis (25/75 percentiles, 12/77 months, minimum to maximum 3-114 months). One dog underwent autopsy and histopathological examination of the heart, confirming presence of myocyte hypertrophy, myofiber disarray, intraluminal coronary arterial narrowing, and interstitial and replacement fibrosis.

4 | DISCUSSION

This retrospective, multicenter study contributes new information that identifies clinical and echocardiographic characteristics consistent with HCM in dogs. Affected dogs were predominantly small breed, with a wide age range, and without a sex predilection. Heart murmurs were frequent. Exercise intolerance and syncope were identified rarely. Left ventricular hypertrophy in most affected dogs with HCM was concentric and symmetrical. Absence of LA enlargement, presence of concurrent RV hypertrophy, DLVOT obstruction with SAM, and LV diastolic dysfunction were also frequently identified. Many dogs survived for an extended period of time (years). Some died suddenly, 2 developed CHF and CHF-related death. Arterial thromboembolism was not observed.

Hypertrophic cardiomyopathy is a rare cause of heart disease in dogs.^{1,2,5,6} While post mortem findings of HCM in dogs have been well-characterized,^{2,3,7,8,11,13,17,26} clinical,^{1,4,6,43} angiographic,^{2,6} hemodynamic,² and echocardiographic^{1,4} findings in dogs with HCM are infrequently reported. Hypertrophic cardiomyopathy has been identified in many breeds of dogs, with large breed male dogs including German shepherds, Rottweilers, Dalmatians, German shorthaired-pointers, Weimaraners, Boxers, and Golden retrievers most often reported in earlier studies.^{6,7,11,12,17,44} However, more recent data^{3,4,8} suggest that HCM is also found in small breed dogs, in particular in terrier breeds. Most dogs with HCM in the present study were small breed dogs, with Shih Tzus, Chihuahuas, and terrier breeds overrepresented. Although more female than male dogs were affected, there was no clear trend toward a sex predilection, which is in contrast to other reports.^{7,12,17,25} The age range of dogs with HCM at diagnosis was between 3 months and 14 years with approximately one third of dogs younger than 2 years. Other studies report a higher prevalence in older dogs.^{1,3,4,6}

It should also be considered that LV hypertrophy diagnosed in older dogs of previous reports might have been related to noncardiac disease. In our study, 15 dogs (22%) were older than 10 years. Although we cannot completely eliminate the possibility of enrolling dogs incorrectly diagnosed with HCM (type-I error) in the present study, our inclusion criteria were stringent leading to the exclusion of 277 of 345 (80%) dogs initially identified with LV hypertrophy. In addition, systolic blood pressure was measured in all study dogs, and dogs with values >160 mm Hg were excluded, making systemic hypertension an unlikely cause of LV wall thickening.

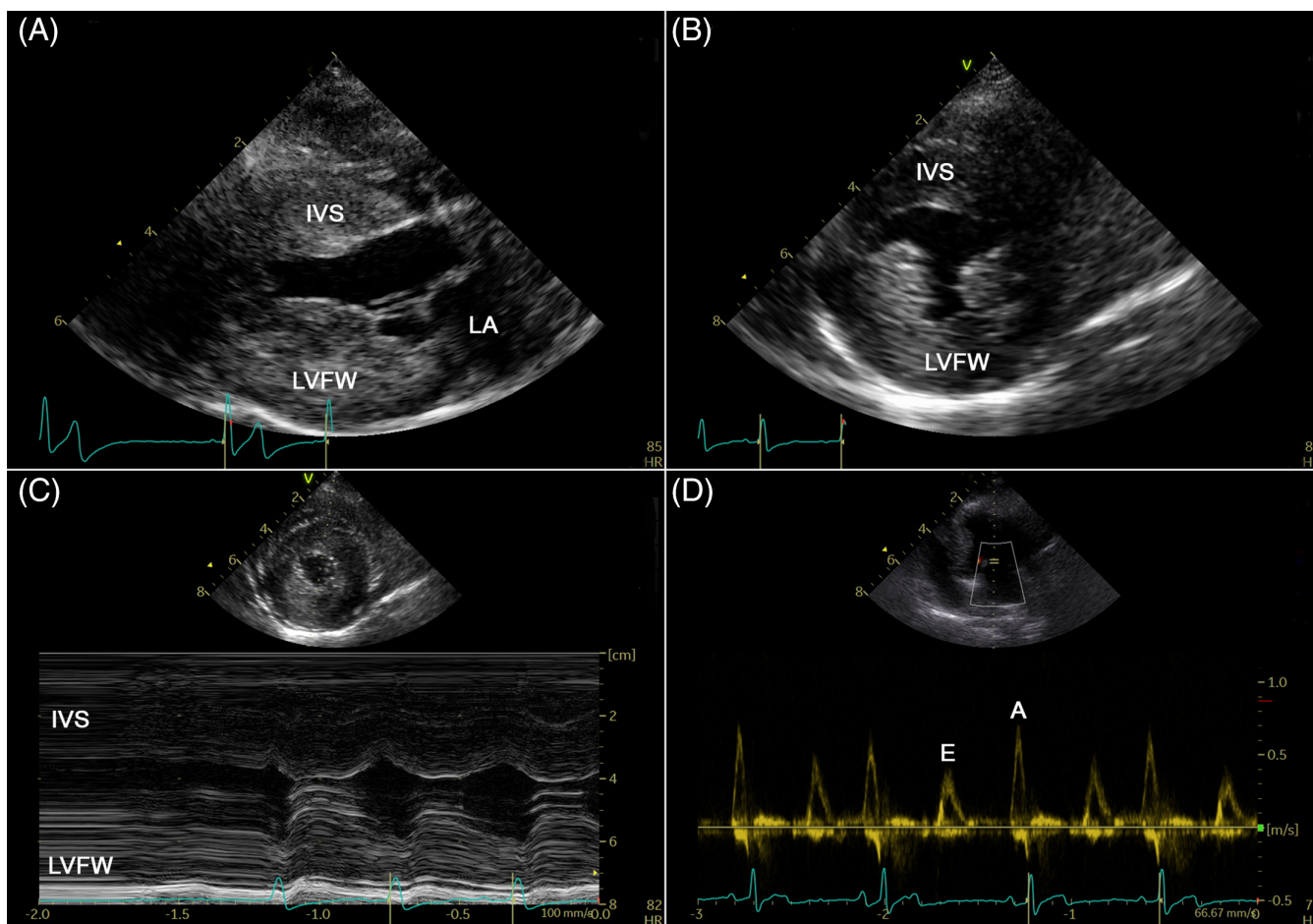


FIGURE 3 Echocardiographic images of an 8-year old 8.6 kg female Cairn terrier with hypertrophic cardiomyopathy. Concentric left ventricular (LV) hypertrophy, increased systolic function, and abnormal transmitral flow indicating LV diastolic dysfunction are present. Systolic blood pressure was 140 mm Hg. (A) Right parasternal long-axis 4-chamber image. Thickness of the interventricular septum in diastole (IVS) was 15.3 mm (normalized 0.95; matched control dog 0.44) and of the left ventricular (LV) free wall (LVFW) 16.2 mm (normalized 0.98; matched control dog 0.46). Left ventricular dimension in diastole was 24.2 mm (normalized: 1.30; matched control dog 1.45). (B) Right-parasternal short-axis image recorded at the level of the papillary muscles. (C) LV M-mode echocardiogram displaying increased LV systolic function. Segmental shortening fraction was 55% (matched control dog 37%). (D) Pulsed wave Doppler transmitral flow pattern displaying decreased velocity of early LV diastolic filling flow (E) and a ratio of E to late diastolic flow velocity (A) of 0.52 (matched control dog 1.48) indicating presence of mild LV diastolic dysfunction (delayed-relaxation filling pattern)

Another source of type-I error in our study could have been enrollment of young dogs with LV hypertrophy and SAM. This could raise the suspicion of malformation of the mitral valve leading to DLVOTO as an underlying or contributing cause of concentric LV wall thickening.^{9,15,24,44} Dynamic LVOTO with evidence of reversible LV hypertrophy has recently been reported in 9 dogs.^{21,22}

In the latter studies with 8/9 dogs ≤ 9 months old, treatment with atenolol led to resolution of the outflow tract obstruction and regression of LV hypertrophy within 3 to 9 months of treatment. We elected to include young dogs (<2 years) with DLVOTO in this study, as long as the presence of a potential mitral valve malformation as the primary reason for LV wall thickening was ruled out based on the absence of detectable mitral valve abnormalities from 2D imaging, as well as the persistence of LV hypertrophy, despite treatment with atenolol and resolution of the DLVOTO.

Nevertheless, although dogs with characteristic echocardiographic signs of congenital mitral valve malformation were not included, echocardiography might not be sensitive enough to identify subtle mitral valve abnormalities. Thus, presence of mitral valve malformation could not be completely ruled out if follow up examinations were not performed.

Many dogs in this study were subclinical and presented for diagnostic work-up of a systolic heart murmur. Owner-determined exercise intolerance and syncope/collapse were the most commonly recorded clinical complaints, whereas CHF was documented rarely. Similar observations have been reported elsewhere.^{4,9,12,21,43} In contrast, left and/or right-sided CHF in dogs with HCM have been observed more frequently in previous studies^{1,12} (up to 40% in 1 study). Paraparesis, possibly due to systemic arterial thromboembolism, has only been documented in 1 dog with HCM.⁴

TABLE 5 Left atrial dimension, left ventricular (LV) wall thickness, and LV dimension of 2D echocardiographic measurements in the study group (n = 68) and control group (n = 68)

	b	Raw data		Normalized data	
		Study	Control	Study	Control
RP long-axis view					
LAD (cm)	0.309	2.29 (1.92/2.91)	n.d.	1.37 (1.23/1.48)	n.d.
IVSd (cm)	0.223	0.99 (0.76/1.28)	0.61 (0.58/0.70)	0.63 (0.57/0.77)	0.41 (0.39/0.44)
LVDd (cm)	0.316	1.91 (1.59/2.28)	n.d.	1.10 (0.98/1.18)	n.d.
LVFWd (cm)	0.235	0.95 (0.81/1.18)	0.65 (0.54/0.77)	0.64 (0.56/0.71)	0.41 (0.38/0.47)
RP short-axis view					
IVSd (cm)	0.230	1.01 (0.78/1.22)	0.74 (0.66/0.83)	0.63 (0.54/0.74)	0.48 (0.43/0.52)
LVDd (cm)	0.316	1.99 (1.72/2.43)	n.d.	1.12 (1.05/1.25)	n.d.
LVFWd (cm)	0.266	0.92 (0.79/1.15)	0.66 (0.57/0.78)	0.57 (0.50/0.66)	0.41 (0.38/0.43)

Note: Raw data and body weight-normalized (allometrically-scaled) data are presented. Median (25/75 percentiles); scaling exponents for LVDd are derived from Visser et al (2019)³⁰ and for IVSd and LVFWd from Visser using the same population³⁰ of dogs (personal communication). Within a line, the difference between study and control groups for raw and normalized data is significant ($P < .001$).

Abbreviations: 2D, 2-dimensional; b, scaling exponent used in the allometric equation; IVSd, thickness of the interventricular septum at end-diastole; LAD, left atrial dimension; LVDd, left ventricular end-diastolic dimension; LVFWd, thickness of the left ventricular free wall at end-diastole; n.d., not determined; RP, right parasternal.

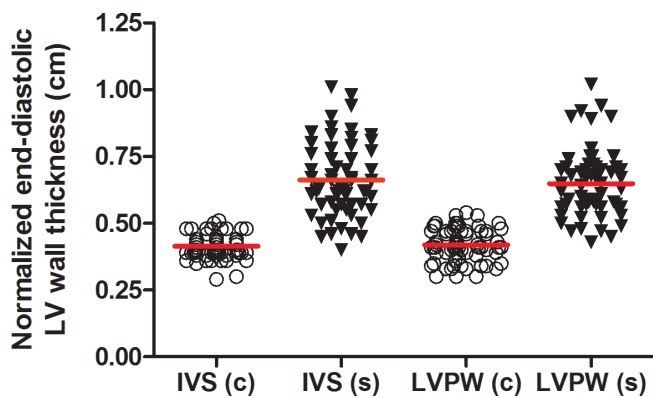


FIGURE 4 Body weight-normalized (allometrically scaled) end-diastolic wall thickness measurements of the interventricular septum (IVS) and left ventricular free wall (LVFW) recorded from a right-parasternal long-axis 4-chamber view and measured from 2-dimensional still frames in matched control dogs (c) and study dogs (s). Individual data points and the mean are displayed. There was a significant difference between control and study dogs for both the IVS and the LVFW (all $P < .001$). The overlap between control and study dogs relates to both the presence of asymmetrical LV wall thickening in some dogs and the fact that measurements of only right-parasternal long-axis images (as opposed to both long-axis and short-axis images) are displayed. Both short and long-axis images were considered in the diagnosis of HCM

Based on the retrospective nature of this study, outcome data were limited. Sudden death and CHF death were rare and observed in <12% of dogs. Most sudden deaths (4/6) occurred within 4 months of diagnosis. Overall, known survival time ranged between 1 and 114 months after diagnosis, and this seems comparable to cats with HCM.⁴⁵ Sudden death as the first sign of the disease, most often observed during general anesthesia, has been reported in up to 50%

of dogs with HCM in small scale studies.^{7,12,25} Sudden death is a relatively uncommon outcome in cats^{45,46} and people^{17,19} with HCM and is linked to the severity of LV hypertrophy, the degree of myocardial fibrosis, and the development of malignant ventricular tachyarrhythmias. However, the mechanisms and risk factors of sudden death in dogs with HCM remain unknown.

While the gross anatomical and histopathological features of HCM in dogs are well described,^{6,7,11,12,17,25} there is a paucity of echocardiographic data with only single case reports documenting echocardiographic patterns in dogs with HCM.^{1,4,5,44} In most (85%) dogs with HCM in this study, LV hypertrophy was symmetrical. A minority of dogs had asymmetrical septal hypertrophy. This finding is similar to the pattern of LV hypertrophy in cats with HCM,^{16,47} but deviates from HCM in people where asymmetrical septal hypertrophy is the most common phenotype.^{18,19,48} The present study stands in contrast to initial findings in dogs, where disproportionate septal thickening was reported in necropsy studies in 8/10 dogs with HCM.⁷ The reason for this discrepancy is not clear, but one could speculate that population differences, different breeds (almost all dogs⁷ were of large breeds), the small sample size in earlier studies, and application of different diagnostic methods may account for the divergent findings. Although only evaluated subjectively by visual assessment, the RV was also hypertrophied, with some dogs having comparable RV and LV wall thickness, but this was not a prominent feature of the disease in most dogs. Concurrent RV hypertrophy has also been reported in HCM in cats⁴⁹ and people.⁵⁰

Evidence of DLVOTO was observed in most of the dogs in our study, with SAM rather than muscular obstruction being the main mechanism. A minority of dogs also had mid-LV obstruction. Hypertrophic cardiomyopathy in people is predominantly an obstructive disease of the LVOT,^{18,19,51} with most patients having either resting or inducible obstruction. Many cats with HCM also have DLVOTO.⁴⁵

TABLE 6 Outcome data of dogs with cardiac death

Breed	Sex	Age at diagnosis (mo)	Age at death (mo)	Time between diagnosis and death (mo)	Cause of death
Boston Terrier	mn	5	8	3	CHF
Pug	m	3	63	60	SD
Shih Tzu	fs	12	16	4	SD
Chihuahua	mn	96	97	1	SD
Shih Tzu	fs	84	88	4	CHF ^a
Jack Russell Terrier	mn	156	158	2	SD
Dalmatian	mn	118	118	2 days	SD
Shih Tzu	fs	121	169	48	SD

^aEuthanasia due to refractory CHF.

Abbreviations: CHF, congestive heart failure; fs, female spayed; m, male intact; mn, male neutered; mo, months; SD, sudden death (defined as the dog being found dead, or unexpected death as witnessed by the owner without prior clinical signs of illness).

Concentric LV hypertrophy and dehydration⁵² leading to a small LV chamber lumen, increased LV systolic function, and geometric changes of the LV cavity including papillary muscle hypertrophy and displacement⁵³ all contribute to the development of DLVOTO.⁵¹ In this study, LV cavity dimension was reduced in most dogs, and LV systolic function indices were increased in the vast majority of dogs. Whether or not papillary muscles were displaced contributing to the obstruction remains unknown; however, papillary muscles were subjectively enlarged in most dogs, possibly favoring obstruction.

Although LV diastolic dysfunction was frequently recorded based on abnormal Doppler echocardiographic LV filling patterns^{40,54} (present in the vast majority of dogs where nonsummated LV Doppler inflow velocity profiles were available), the maximum LAD was usually unremarkable. This finding is difficult to explain. Many cats with HCM have LV diastolic dysfunction and evidence of LA enlargement,⁵⁵ and an association between LA enlargement and severity of LV diastolic dysfunction has been identified in people.⁵⁶ However, not all cats with HCM, even with severe LV hypertrophy, develop LA enlargement,⁵⁵ with 1 study reporting a normal LA size in 34% of cats with HCM.⁵⁷ One may speculate that LV diastolic dysfunction in most dogs with HCM in this study was not severe enough to cause LA enlargement. Additional factors including presence of mitral regurgitation secondary to SAM, degree of neurohormonal activation with fluid retention, concurrent development of LA myocardial fibrosis and cardiomyopathy, and chronicity of the condition may all play a role in the development of LA enlargement in HCM beyond the presence of LV diastolic abnormalities.

Our study had several limitations. This was a retrospective study, and incomplete data sets particularly pertaining to ECG, radiographic, and outcome data were present. Not all investigators had full access to their medical record data base, and some considered only a few rather than 13 years of the observational period. Necropsy with histopathologic examination was performed in only 1 dog. Therefore, LV hypertrophy due to other reasons including but not limited to myocardial neoplastic infiltration,^{58,59} storage disease,⁶⁰ myocarditis,⁶¹ and hyperadrenocorticism²⁹ could not be ruled out completely. Despite measurement of systolic blood pressure in all

dogs, presence of systemic hypertension cannot completely be ruled out due to limited accuracy of noninvasive blood pressure determination in dogs. Although LV and RV wall thickness were evaluated, it was not possible to appreciate the full degree of myocardial hypertrophy by heart weight (necropsy) or cardiac magnetic resonance imaging, the diagnostic gold standards. However, we used both allometrically scaled prediction intervals as well as matched control dogs for quantification of LV wall thickening, which, in the absence of pseudohypertrophy,²⁸ represent accepted clinical methods to identify LV hypertrophy. Moreover, LV mass was not estimated by echocardiography,⁶² a possibly more accurate method than simple wall thickness measurements. Some dogs were evaluated only a single time which may have affected the conclusions of this study. Left ventricular diastolic function was evaluated by echocardiographic methods that have been incompletely validated in dogs with cardiac disease. No attempts were made to evaluate observer variability of echocardiographic measurements, but site-investigators were provided with an instructional slide set and data entry forms to improve consistency in data collection. Some dogs had comorbidities possibly affecting clinical, echocardiographic, and outcome data. Finally, elimination of dogs with echocardiographic abnormalities of the mitral valve may have led to selection bias, as abnormalities of the mitral valve apparatus contribute to the phenotypic spectrum of HCM in dogs,^{13,15} cats,⁶³ and people.⁶⁴

In conclusion, the results of this study demonstrate that HCM occurs in dogs in the clinical setting and thus should be considered as a differential diagnosis if concentric LV hypertrophy is identified. The echocardiographic evaluation is most often triggered by the incidental detection of a systolic heart murmur rather than overt clinical signs. Small breed dogs are overrepresented compared to large breed dogs, no sex predilection is apparent, and it is uncommon for dogs with HCM to experience CHF or arterial thromboembolism while sudden death may occur. Main echocardiographic characteristics include symmetrical concentric LV hypertrophy, DLVOTO, normal LAD, RV hypertrophy, and LV diastolic dysfunction. Long-term outcome of HCM in the present study seemed good in most dogs with survival times after diagnosis between 8 months and 14 years observed.

ACKNOWLEDGMENT

No funding was received for this study. The authors acknowledge support of Vassiliki Gouni and Tim Vojt for their contributions.

CONFLICT OF INTEREST DECLARATION

Authors declare no conflict of interest.

OFF-LABEL ANTIMICROBIAL DECLARATION

Authors declare no off-label use of antimicrobials.

INSTITUTIONAL ANIMAL CARE AND USE COMMITTEE (IACUC) OR OTHER APPROVAL DECLARATION

Authors declare no IACUC or other approval was needed.

HUMAN ETHICS APPROVAL DECLARATION

Authors declare human ethics approval was not needed for this study.

ORCID

Karsten E. Schober  <https://orcid.org/0000-0002-1286-0759>

Phillip R. Fox  <https://orcid.org/0000-0003-4089-0573>

Jonathan Abbott  <https://orcid.org/0000-0001-6981-8968>

Virginia Luis-Fuentes  <https://orcid.org/0000-0001-8076-3806>

Jose Novo Matos  <https://orcid.org/0000-0001-8128-8111>

Lance Visser  <https://orcid.org/0000-0002-3563-0737>

Valerie Chetboul  <https://orcid.org/0000-0001-7891-1814>

Roberto Santilli  <https://orcid.org/0000-0001-5937-2050>

Marco Baron Toaldo  <https://orcid.org/0000-0001-9609-1856>

John Rush  <https://orcid.org/0000-0002-8277-8996>

REFERENCES

- Marks CA. Hypertrophic cardiomyopathy in a dog. *J Am Vet Med Assoc.* 1993;203:1020-1022.
- Thomas WP, Mathewson JW, Suter PF, et al. Hypertrophic obstructive cardiomyopathy in a dog: clinical, hemodynamic, angiographic, and pathologic studies. *J Am Anim Hosp Assoc.* 1984;20:253-260.
- Pang D, Rondenay Y, Hélie P, Cuvelliez SG, Troncy E. Sudden cardiac death associated with occult hypertrophic cardiomyopathy in a dog under anesthesia. *Can Vet J.* 2005;46:1122-1125.
- Washizu M, Takemura N, Machida N, et al. Hypertrophic cardiomyopathy in an aged dog. *J Vet Med Sci.* 2003;65:753-756.
- Yamada E. A canine case of hypertrophic cardiomyopathy. *J Jpn Vet Med Assoc.* 1983;36:12-16.
- Tilley LP, Liu SK. Cardiomyopathy in the dog. *Rec Adv Card Struct Metab.* 1975;10:641-653.
- Liu SK, Maron BJ, Tilley LP. Hypertrophic cardiomyopathy in the dog. *Am J Pathol.* 1979;94:497-508.
- Baumgartner C, Glaus TM. Erworbene Herzerkrankungen beim Hund: Eine retrospektive Analyse. *Swiss Arch.* 2004;146:423-430.
- De Majo M, Britti D, Masucci M, et al. Hypertrophic obstructive cardiomyopathy associated with mitral valve dysplasia in the Dalmatian dog: two cases. *Vet Res Com.* 2003;27(Suppl 1):391-393.
- Sisson D, Thomas W, Keene B. Primary myocardial disease in the dog. In: Ettinger SJ, Feldman EC, eds. *Textbook of Veterinary Internal Medicine.* 5th ed. Philadelphia: WB Saunders; 2000:886-890.
- Liu SK, Maron BJ, Tilley LP. Canine hypertrophic cardiomyopathy. *J Am Vet Med Assoc.* 1979;174:708-713.
- Liu SK, Tilley LP. Animal models of primary myocardial disease. *Yale J Biol Med.* 1980;53:191-211.
- Swindle MM, Huber AC, Kan JS, Starr FL 3rd, Samphilipo MA Jr. Mitral valve prolapse and hypertrophic cardiomyopathy in a pup. *J Am Vet Med Assoc.* 1984;184:1515-1517.
- Sisson DD. Fixed and dynamic subvalvular aortic stenosis in dogs. In: Kirk RW, Bonagura JD, eds. *Kirk's Current Veterinary Therapy XI.* Philadelphia: WB Saunders; 1992:760.
- Sisson D, Thomas WP. Dynamic subaortic stenosis in a dog with congenital heart disease. *J Am Anim Hosp Assoc.* 1984;20:657-664.
- Fox PR, Liu SK, Maron BJ. Echocardiographic assessment of spontaneously occurring feline hypertrophic cardiomyopathy. An animal model of human disease. *Circulation.* 1995;92:2645-2651.
- Liu SK, Roberts WC, Maron BJ. Comparison of morphologic findings in spontaneously occurring hypertrophic cardiomyopathy in humans, cats, and dogs. *Am J Cardiol.* 1993;72:944-951.
- Maron BJ, Epstein SE. Hypertrophic cardiomyopathy. Recent observations regarding the specificity of three hallmarks of the disease: asymmetric septal hypertrophy, septal disorganization, and systolic anterior motion of the anterior mitral valve leaflet. *Am J Cardiol.* 1980;45:141-154.
- Maron BJ, Maron MS. Hypertrophic cardiomyopathy. *Lancet.* 2013;381:242-255.
- Klues H, Roberts W, Maron B. Morphological determinants of echocardiographic patterns of mitral valve systolic anterior motion in obstructive hypertrophic cardiomyopathy. *Circulation.* 1993;87:1570-1579.
- Connolly DJ, Boswood A. Dynamic obstruction of the left ventricular outflow tract in four young dogs. *J Small Anim Pract.* 2003;44:319-325.
- Loureiro J, Smith S, Fonfara S, Swift S, James R, Dukes-McEwan J. Canine dynamic left ventricular outflow tract obstruction: assessment of myocardial function and clinical outcome. *J Small Anim Pract.* 2008;49:578-586.
- D'Agnolo G, Bussadori C, Borgarelli M, Santilli R. Cardiomiopatia ipertrofica ostruttiva e displasia della mitrale associate, in alcuni cani di razza dalmata. *Veterinaria.* 1998;12:5-11.
- Liu SK, Tilley LP. Malformation of the canine mitral valve complex. *J Am Vet Med Assoc.* 1975;167:465-471.
- Van Vleet JF, Ferrans VJ. Myocardial diseases of animals. *Am J Pathol.* 1986;124:98-178.
- Ommen SR, Mital S, Burke MA, et al. 2020 AHA/ACC guideline for the diagnosis and treatment of patients with hypertrophic cardiomyopathy. A report of the American College of Cardiology/American Heart Association Joint Committee on clinical practice guidelines. *Circulation.* 2020;142:e558-e631.
- Campbell FE, Kittleson MD. The effect of hydration status on the echocardiographic measurements of normal cats. *J Vet Intern Med.* 2007;21:1008-1015.
- Fine DM, Durham HE, Rossi NF, et al. Echocardiographic assessment of hemodynamic changes produced by two methods of inducing fluid deficit in dogs. *J Vet Intern Med.* 2010;24:348-353.
- Takano H, Kokubu A, Sugimoto K, Sunahara H, Aoki T, Fujii Y. Left ventricular structural and functional abnormalities in dogs with hyperadrenocorticism. *J Vet Cardiol.* 2015;17:173-181.
- Visser LC, Ciccozzi MM, Sintov DJ, Sharpe AN. Echocardiographic quantification of left heart size and function in 122 healthy dogs: a prospective study proposing reference intervals and addressing repeatability. *J Vet Intern Med.* 2019;33:1909-1920.
- Boon JA. Evaluation of size, function, and hemodynamics. In: Boon JA, ed. *Manual of Veterinary Echocardiography.* 2nd ed. Chichester: Wiley-Blackwell; 2011:153-156.
- Hägström J, Luis Fuentes V, Wess G. Screening for hypertrophic cardiomyopathy in cats. *J Vet Cardiol.* 2015;17(Suppl 1):S134-S149.
- Misbach C, Lefebvre HP, Concordet D, et al. Echocardiography and conventional Doppler examination in clinically healthy Cavalier King

- Charles Spaniels: effect of body weight, age, gender, and establishment of reference intervals. *J Vet Cardiol.* 2014;16:91-100.
34. Chetboul V, Athanassiadis N, Concordet D, et al. Observer-dependent variability of quantitative clinical endpoints: the example of canine echocardiography. *J Vet Pharmacol Ther.* 2004;27:49-56.
 35. Bland M. Clinical measurement. In: Bland M, ed. *An Introduction to Medical Statistics.* Oxford (England): Oxford University Press; 2000: 268-293.
 36. Grossman W, Jones D, McLaurin LP. Wall stress and patterns of hypertrophy in the human left ventricle. *J Clin Invest.* 1975;56:56-64.
 37. Borgarelli M, Tarducci A, Zanatta R, Haggstrom J. Decreased systolic function and inadequate hypertrophy in large and small breed dogs with chronic mitral insufficiency. *J Vet Intern Med.* 2007;21:61-67.
 38. Rishniw M, Erb HN. Evaluation of four 2-dimensional echocardiographic methods of assessing left atrial size in dogs. *J Vet Intern Med.* 2000;14:429-435.
 39. Schober KE, Baade H. Comparability of left ventricular M-mode echocardiography in dogs performed in long-axis and short-axis. *Vet Radiol Ultrasound.* 2000;41:543-549.
 40. Schober KE, Luis FV. Doppler echocardiographic assessment of left ventricular diastolic function in 74 boxer dogs with aortic stenosis. *J Vet Cardiol.* 2002;4:7-16.
 41. Schober KE, Luis Fuentes V. Effect of age, body weight, and heart rate on transmitral and pulmonary venous flow in clinically normal dogs. *Am J Vet Res.* 2001;62:1447-1454.
 42. Baade H, Schober K, Oechtering G. Echokardiographische Referenzwerte beim West Highland White terrier unter besonderer Berücksichtigung der Rechtsherzfunktion. *Tierärztl Prax.* 2002;30(K): 172-179.
 43. Luginbühl H, Detweiler DK. Cardiovascular lesions in dogs. *Ann N Y Acad Sci.* 1965;127:517-540.
 44. Sisson D, O'Grady MR, Calvert CA. Myocardial diseases of dogs. In: Fox PR, Sisson D, Moise NS, eds. *Textbook of Canine and Feline Cardiology. Principles and Clinical Practice.* 2nd ed. Philadelphia: WB Saunders; 1999:601-619.
 45. Fox PR, Keene BW, Lamb K, et al. International collaborative study to assess cardiovascular risk and evaluate long-term health in cats with preclinical hypertrophic cardiomyopathy and apparently healthy cats: the REVEAL study. *J Vet Intern Med.* 2018;32:930-943.
 46. Payne JR, Borgeat K, Brodbelt DC, Connolly DJ, Luis Fuentes V. Risk factors associated with sudden death vs. congestive heart failure or arterial thromboembolism in cats with hypertrophic cardiomyopathy. *J Vet Cardiol.* 2015;17:S318-S328.
 47. Kittleson MD, Meurs KM, Munro MJ, et al. Familial hypertrophic cardiomyopathy in Maine Coon cats: an animal model of human disease. *Circulation.* 1999;99:3172-3180.
 48. Epstein SE, Henry WL, Clark CE, et al. Asymmetric septal hypertrophy. *Ann Intern Med.* 1974;81:650-680.
 49. Schober KE, Savino SI, Yildiz V. Right ventricular involvement in feline hypertrophic cardiomyopathy. *J Vet Cardiol.* 2016;18:297-309.
 50. Maron MS, Hauser TH, Dubrow E, et al. Right ventricular involvement in hypertrophic cardiomyopathy. *Am J Cardiol.* 2007;100:1293-1298.
 51. Maron MS, Olivetto I, Zenovich AG, et al. Hypertrophic cardiomyopathy is predominantly a disease of left ventricular outflow tract obstruction. *Circulation.* 2006;114:2232-2239.
 52. Hammes K, Novo Matos J, Baron Toaldo M, Glaus T. Hypovolemia induced systolic anterior motion of the mitral valve in two dogs. *J Vet Cardiol.* 2016;18:367-371.
 53. Maron MS, Olivetto I, Harrigan C, et al. Mitral valve abnormalities identified by cardiovascular magnetic resonance represent a primary phenotypic expression of hypertrophic cardiomyopathy. *Circulation.* 2011;124:40-47.
 54. Appleton CP, Hatle LK, Popp RL. Relation of transmitral flow velocity patterns to left ventricular diastolic function: new insights from a combined hemodynamic and Doppler echocardiographic study. *J Am Coll Cardiol.* 1988;12:426-440.
 55. Linney CJ, Dukes-McEwan J, Stephenson HM, López-Alvarez J, Fonfara S. Left atrial size, atrial function and left ventricular diastolic function in cats with hypertrophic cardiomyopathy. *J Small Anim Pract.* 2014;55:198-206.
 56. Yang H, Woo A, Monakier D, et al. Enlarged left atrial volume in hypertrophic cardiomyopathy: a marker for disease severity. *J Am Soc Echocardiogr.* 2005;18:1074-1082.
 57. Duler L, Scollan KF, LeBlanc NL. Left atrial size and volume in cats with primary cardiomyopathy with and without congestive heart failure. *J Vet Cardiol.* 2019;24:36-47.
 58. Stern JA, Tobias JR, Keene BW. Complete atrioventricular block secondary to cardiac lymphoma in a dog. *J Vet Cardiol.* 2012;14: 537-539.
 59. Lee PW, Woo KS, Chow LTC, et al. Diffuse infiltration of lymphoma of the myocardium mimicking clinical hypertrophic cardiomyopathy. *Circulation.* 2006;113:e662-e664.
 60. Ruiz-Guerrero L, Barriaes-Villa R. Storage diseases with hypertrophic cardiomyopathy phenotype. *Glob Cardiol Sci Pract.* 2018;28:2-29.
 61. Pinamonti B, Alberti E, Cigalotto A, et al. Echocardiographic findings in myocarditis. *Am J Cardiol.* 1988;62:285-291.
 62. Schiller NB, Skioldebrand CG, Schiller EJ, et al. Canine left ventricular mass estimation by two-dimensional echocardiography. *Circulation.* 1983;68:210-216.
 63. Schober K, Todd A. Echocardiographic assessment of left ventricular geometry and the mitral valve apparatus in cats with hypertrophic cardiomyopathy. *J Vet Cardiol.* 2010;12:1-16.
 64. Klues HG, Maron BJ, Dolla AL, Roberts WC. Diversity of structural mitral valve alterations in hypertrophic cardiomyopathy. *Circulation.* 1992;85:1651-1660.

How to cite this article: Schober KE, Fox PR, Abbott J, et al. Retrospective evaluation of hypertrophic cardiomyopathy in 68 dogs. *J Vet Intern Med.* 2022;36(3):865-876. doi:10.1111/jvim.16402