

# Pathogenicity and innate response to *Avibacterium paragallinarum* in chickens

Mengjiao Guo,\* Donghui Liu,\* Xiufang Chen,\* Yantao Wu,\*<sup>†</sup> and Xiaorong Zhang \*<sup>1</sup>

\**Jiangsu Co-Innovation Center for Prevention of Animal Infectious Diseases and Zoonoses, College of Veterinary Medicine, Yangzhou University, Yangzhou, Jiangsu, China; and* <sup>†</sup>*Joint International Research Laboratory of Agriculture & Agri-Product Safety, Yangzhou University (JIRLAAPS), Yangzhou, Jiangsu, China*

**ABSTRACT** Infectious coryza (IC) is an acute infectious upper respiratory disease in chickens. Recently, the prevalence of IC has increased in China. In this study, to clarify the pathogenic mechanism and innate immune response of *Avibacterium paragallinarum* (*A. paragallinarum*), an infection experiment with *A. paragallinarum* was conducted. Our results showed that the whole course of IC was approximately 7 d. The clinical signs score was highest at 3 dpi and decreased from 5 dpi. A large amount of mucus and exudates was found in the infraorbital sinuses and nasal cavity. The *A. paragallinarum* contents in blood remained the highest, reaching  $9.16 \times 10^5$  CFU/g at 5 dpi, which indicated that *A. paragallinarum* could rapidly invade the host, replicate in the blood and cause bacteremia. *A. paragallinarum* targets the upper respiratory tract. The

infiltration of inflammatory cells, macrophages, and heterophilic granulocytes was only observed in the nasal cavity and infraorbital sinus. The *Tlr4* and *Nod1* pathways were activated and induced proinflammatory responses in chickens after infection with *A. paragallinarum*. The expression of *Il1 $\beta$*  and *Il6* in the nasal cavity was significantly higher than that in the spleen, and it was consistent with the gross lesions and pathological changes. In particular, the expression of *Il6* increased 229.07-fold at 1 dpi in the nasal cavity and increased 3.12-fold in the spleen. The high level of proinflammatory cytokines in the nasal cavity at an early stage of infection may be the main factor related to acute upper respiratory inflammation in chickens. These findings provide a reference for the occurrence and development of diseases mediated by *A. paragallinarum*.

**Key words:** *Avibacterium paragallinarum*, infectious coryza, pathogenicity, chicken, innate immunity

2022 Poultry Science 101:101523

<https://doi.org/10.1016/j.psj.2021.101523>

## INTRODUCTION

*Avibacterium paragallinarum* (*A. paragallinarum*) is a gram-negative bacterium that causes infectious coryza (IC), an acute infectious upper respiratory disease in chickens (Blackall and Soriano–Vargas, 2020). The clinical signs are nasal discharge, facial swelling, lacrimation, conjunctivitis, and anorexia. IC is a cosmopolitan disease and has major economic effects due to decreased egg production (10–80%), slowed growth, and increased mortality (2–10%) (Blackall et al., 2005). Generally, the clinical symptoms can last for 2 to 3 wk. However, as *A. paragallinarum* is a conditional pathogenic bacterium, the severity of clinical signs depends on age, breed, and factors such as poor feeding management, parasitism, and mixed infections. Morbidity and mortality are

exacerbated in infectious IC flocks by the presence of concomitant bacterial infections, such as *Mycoplasma synoviae*, *Mycoplasma gallisepticum*, *Ornithobacterium rhinotracheale*, *Pasteurella multocida*, and *Gallibacterium anatis* (Sandoval et al., 1994; Morales-Erasto et al., 2016; Paudel et al., 2017), and viral infections, including infectious bronchitis virus, infectious laryngotracheitis virus, and fowlpox virus (Welchman Dde et al., 2010; Gallardo et al., 2020). Severe and prolonged disease may develop into complex conditions characterized by chronic respiratory diseases, swollen head-like syndrome, airsacculitis, tarsal arthritis, and septicemia. Research has shown that coinfection of IC and fowl cholera could lead to 50% mortalities in layer flocks (Anjaneya et al., 2013; Blackall and Soriano–Vargas, 2020). Thus, the control of IC is an important issue in chicken farms.

IC is transmitted by horizontal transmission, including direct contact and aerosols. Birds and carriers with subclinical infection usually show no signs but may discharge *A. paragallinarum* intermittently through the respiratory tract. Therefore, subclinically infected birds and carriers play an important role in the transmission

© 2021 The Authors. Published by Elsevier Inc. on behalf of Poultry Science Association Inc. This is an open access article under the CC BY-NC-ND license (<http://creativecommons.org/licenses/by-nc-nd/4.0/>).

Received August 11, 2021.

Accepted September 24, 2021.

<sup>1</sup>Corresponding author: [zxrx@yzu.edu.cn](mailto:zxrx@yzu.edu.cn)

of IC (Blackall and Soriano-Vargas, 2020). The presence of IC has been reported in many countries, such as the UK, USA, India, and Indonesia, in recent years (Welchman Dde et al., 2010; Patil et al., 2017b; Crispo et al., 2018; Wahyuni et al., 2018). Until 2012, IC was relatively rare in commercial birds in China. However, IC occurred in Beijing, Anhui, and Shandong provinces in 2012. The occurrence of IC is mostly caused by cold stress due to improper ventilation. IC has also occurred in vaccinated flocks and chickens at the brooding stage. In recent years, researchers have established the virulence pattern of *A. paragallinarum*. The clinical signs caused by the isolates of *A. paragallinarum* were independent of serotype (Chukiatsiri et al., 2012). According to observations of the pathogenicity changes in field isolates, the prevalence of the strain has changed over time (Anjaneya et al., 2013; Patil et al., 2017a).

The innate immune system provides the first line of defense against invading pathogens. Research on systematic pathogenicity and the role of innate immunity in IC disease processes is scarce. The prevalence of IC has recently increased in China, including in early brooding stage chickens. To address this, we investigated the colonization of *A. paragallinarum*, pathological changes, clinical symptoms, and innate immune responses in 28-day-old chickens after being challenged with *A. paragallinarum*.

## MATERIALS AND METHODS

### Bacteria

The *A. paragallinarum* 2020/JS80 strain (serovar C) was isolated from a chicken farm with typical clinical signs of IC in Jiangsu Province, China. Diseased chickens showed facial swelling, blindness, and decreased egg production. For bacterial culture, we dipped the infraorbital sinus of chickens with a sterile cotton swab and cultured it on trypticase soy agar supplemented with 10% fetal bovine serum and 0.0025% reduced nicotinamide adenine dinucleotide. The bacteria were cultured at 37°C and 5% CO<sub>2</sub> for 24 to 36 h, and the suspected *A. paragallinarum* colonies were purified on trypticase soy agar twice. The isolates were identified by HPG-2 PCR, which is species-specific for *A. paragallinarum* (Chen et al., 1996). Then, the amplicons were sent to Sangon Biotech (Shanghai, China) Co., Ltd. for sequencing. The *A. paragallinarum* isolate was tested for catalase activity, carbohydrate fermentation, oxidase, motility, and urease.

The *A. paragallinarum* reference strain 221 was purchased from the China Veterinary Culture Collection Center.

### Animals and Experiment Design

The 28-day-old SPF white leghorn chickens used in this study were purchased from Sipsifu Poultry Farm (Jinan, China). The males and females were randomly selected. Fifty chickens were randomly divided into 2 groups with sufficient space, feed, and water. The challenge experiment was conducted by using infraorbital

**Table 1.** The standard of scoring of clinical signs.

Score	Clinical signs
0	No signs
1	Slight facial swelling and nasal discharge
2	Moderate facial swelling and nasal discharge
3	Severe facial swelling, abundant nasal discharge, and lacrimation

sinus inoculation with 0.2 mL of *A. paragallinarum* bacterial suspension (10<sup>7</sup> cfu/mL). Chickens of the control group were inoculated with 0.2 mL of tryptone soybean broth. The clinical symptoms were observed and recorded after challenge with *A. paragallinarum*. Five chickens were randomly selected and euthanized for each group. The nasal contents, blood, trachea, thymus, lung, and spleen were collected at 1, 3, 5, and 7 d postinfection (dpi). All experiments were approved by the Committee on the Ethics of Animal Experiments of Yangzhou University.

### Clinical Signs Scores

Clinical signs were scored according to the protocol, as previously reported (Bragg, 2002). 0: no clinical signs; 1: mild signs; 2: moderate signs; 3: severe signs (Table 1). The total disease score was recorded and calculated. From each group, 5 chickens were randomly chosen to provide data used to calculate the clinical signs scores. The mean daily disease score was calculated by dividing the daily disease score by the number of chickens.

### Histopathological Changes

Suborbital sinuses and trachea were fixed with 4% paraformaldehyde solution. Fixed samples were embedded in paraffin wax and sectioned into 5 μm slices using a microtome. Sections were stained with hematoxylin and eosin (H&E). Then the microscopic lesion was observed using a Leica microscope.

### A. paragallinarum Quantification

To investigate the colonization of *A. paragallinarum* in tissues and organs after challenge, the bacterial load was detected by quantitative real-time PCR (qRT-PCR). Total DNA was extracted from 1 g of chicken tissue using the Bacteria Genomic DNA kit (CWbio, Beijing, China). qRT-PCR was performed using TransStartR Tip Green qPCR SuperMix (Transgen Biotech Co., Ltd., Beijing, China). According to a previous study (Wen et al., 2016), the primer of the recN gene was designed for the detection of *A. paragallinarum* (Table 2). The qRT-PCR program consisted of 1 cycle of 94°C for 30 s, followed by 40 cycles of 94°C for 5 s and 60°C for 34 s and finally dissociation curves.

**Table 2.** Primers sequence used in this study.

Primer name	Sequence (5'-3')
HPG-2-F	TGAGGGTAGTCTTGCACGCGAAT
HPG-2-R	CAAGGTATCGATCGTCTCTACT
qrecN-F	AGCTTGCTCTACCGACAAT
qrecN-R	CTGGCTTCTTGCACCTGAAT
<i>Tlr4</i> -F	AGTCTGAAATTGCTGAGCTCAAAT
<i>Tlr4</i> -R	GCGACGTTAAGCCATGGAAG
<i>Nod1</i> -F	GCGATGCAGGAATTGGAAAA
<i>Nod1</i> -R	TGTGAAAAGAACCCTATGAGGGA
<i>Mhc II-α</i> -F	CTCGAGGTCATGATCAGCAA
<i>Mhc II-α</i> -R	TGTAACGCTCCCTTTGG
<i>Myd88</i> -F	TGATGCCTTACCTGCTACTG
<i>Myd88</i> -R	TCCCTCCGACACCTTCTTTCTA
<i>Il1β</i> -F	GTGAGGCTCAACATTGCGCTGTA
<i>Il1β</i> -R	TGTCCAGGCGGTAGAAGATGAAG
<i>Il8</i> -F	ATGAACGGCAAGCTTGGAGCTG
<i>Il8</i> -R	TCCAAGCACACCTCTCTTCCATCC
<i>Il6</i> -F	TCTGTTGCGCTTTCAGACCTA
<i>Il6</i> -R	GACCACCTCATCGGGATTAT
$\beta$ -actin-F	GAGAAATTGTGCGTGACATCA
$\beta$ -actin-R	CCTGAACCTCTCATTGCCA

### Innate Immune-related Genes

Total RNA was extracted from the nasal contents and spleen by TRIzol reagent RNA kit (CWbio, Beijing, China). First-strand cDNA synthesis was performed with TransScriptR one-step gDNA Removal and cDNA Synthesis SuperMix (Transgen Biotech Co., Ltd., Beijing, China). The mRNA levels of innate immune-related genes were detected by qRT-PCR. The primers for *Tlr4*, *Nod1*, *Il6*, *Mhc II-α*, and  $\beta$ -actin were referenced in previous studies (Iqbal et al., 2005; Liang et al., 2011; Tao et al., 2015; Li et al., 2018), and the remaining primers were designed using Primer Premier 6 software (Table 2). The internal control was the housekeeping  $\beta$ -actin gene. The relative mRNA expression levels of target genes were calculated using the  $2^{-\Delta\Delta Ct}$  method.

### Statistical Analysis

SPSS 23.0 software (SPSS Inc., Chicago, IL) was used for statistical analysis. Nonparametric Mann-Whitney U test was used to analyze the significant difference.  $P < 0.05$  was considered for significance.

## RESULTS

### Isolation and Identification of *A. paragallinarum*

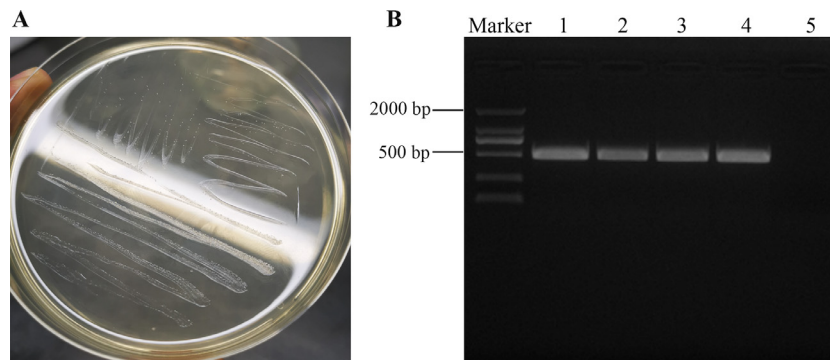
The *A. paragallinarum* colonies on trypticase soy agar are circular, transparent, and smooth dewdrops. Gram staining of *A. paragallinarum* showed that bacteria had coccobacilli morphology and were gram negative. The suspected *A. paragallinarum* colonies with morphological characteristics were recultured twice to obtain pure colonies (Figure 1A). Then, the field isolates were reconfirmed by HPG-2 PCR. The size of the amplified fragment was approximately 500 bp, which was consistent with the expected result (Figure 1B). The sequence was confirmed by running BLASTn.

### Clinical Symptoms and Scores


After challenge with *A. paragallinarum*, the chickens showed depression and decreased intake of food and water. At 1 dpi, 2/5 chickens showed slight facial swelling and nasal discharge (arrow on Figure 2A). All chickens exhibited clinical symptoms at 3 dpi. Two chickens showed severe facial swelling and abundant nasal discharge (arrow in Figure 2B). At 5 dpi, the facial swelling was relieved (arrow in Figure 2C). At 7 dpi, the intake of food and water gradually recovered (Figure 2D). No clinical symptoms were observed in the chickens of the control group (Figure 2E). As shown in Figure 2F, through the score statistics of clinical symptoms, we found that the clinical signs score was low at 1 dpi. The clinical signs score was highest at 3 dpi and decreased from 5 dpi.

### Gross Lesions

At 1 dpi, hemorrhage of the nasal mucosa was observed, and a large amount of mucus and exudates was found in the infraorbital sinuses (arrow in Figure 3A). At 3 dpi, chickens showed typical gross lesions. There was a yellow exudate clot in the infraorbital sinus (arrow in Figure 3B), which then turned into caseous exudate (arrow in Figure 3C and D). Diffuse hemorrhage of the trachea was apparent at 1 dpi (arrow



**Figure 1.** *A. paragallinarum* isolation. (A) Colony morphology of *A. paragallinarum* in trypticase soy agar. (B) Agarose gel electrophoresis of HPG-2 PCR products of *A. paragallinarum*. *A. paragallinarum* isolate (lines 1-3), reference strain 221 (line 4), and negative control (line 5).



**Figure 2.** Clinical symptoms of chickens infected with *A. paragallinarum*. Facial swelling at (A) 1 dpi, (B) 3 dpi, (C) 5 dpi, and (D) 7 dpi. (E) Represent the healthy chicken in the control group. (F) The clinical signs scores of chickens after challenge.

in Figure 3F). The hemorrhage of the annulus trachealis was most serious at 3 dpi (arrow in Figure 3G), relieved at 5 dpi (arrow in Figure 3H), and then returned to normal (Figure 3I). No gross lesions were observed in chickens of the control group (Figure 3E and J). Combined with the results of clinical symptoms, IC developed rapidly in a short time, and the course of the disease was short.

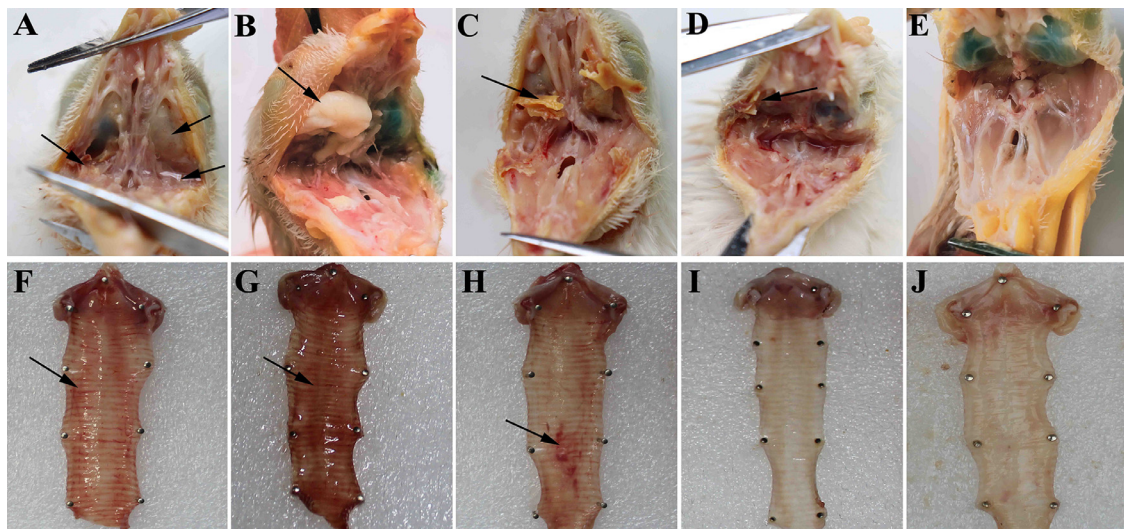
### Histopathological Analysis

Pathological changes were detected in the infraorbital sinus and trachea of the infected chickens. In the microstructural examination, the infraorbital sinus showed infiltration of macrophages and heterophilic granulocytes (Figure 4A and B). Severe edema, loosening, and hemorrhage were observed in the nasal cavity (arrow in

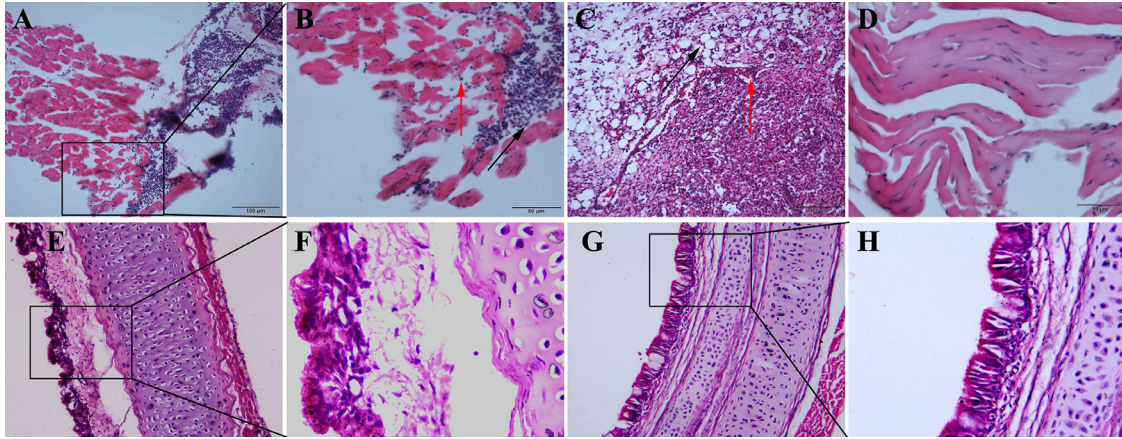
Figure 4C). The tracheae exhibited adhesion, lodging, and partial exfoliation of cilia. Inflammatory cell infiltration and mucosal edema in the lamina propria were observed (Figure 4E and F). No pathological changes were observed in the control group (Figure 4D, G, and H). Overall, our results indicated that *A. paragallinarum* targets the upper respiratory tract and causes pathological lesions.

### *A. paragallinarum* Content in Tissues of Infected Chickens

As shown in Figure 5A, the *A. paragallinarum* content in the nasal contents, trachea, thymus, spleen, lung, and blood of chickens was detected at 1, 3, 5, and 7 dpi. The bacterial contents were very low at



**Figure 3.** Gross lesions of chickens infected with *A. paragallinarum*. The gross lesions in nasal cavity and infraorbital sinus at (A) 1 dpi, (B) 3 dpi, (C) 5 dpi, and (D) 7 dpi. The gross lesions in trachea at (F) 1 dpi, (G) 3 dpi, (H) 5 dpi, and (I) 7 dpi. E and J represent the healthy chicken in the control group.

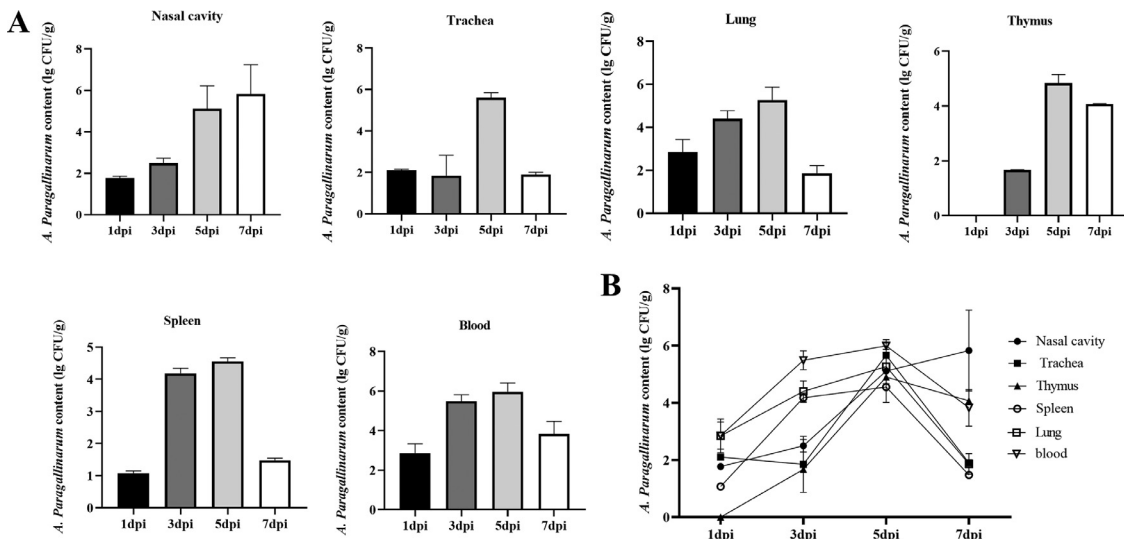


**Figure 4.** Pathological changes of chickens infected with *A. paragallinarum*. (A and B) The infiltration of macrophages (red arrow) and heterophilic granulocytes (black arrow) in infraorbital sinus at 3 dpi. Macrophage is large. The nucleus is large and can be scattered in the cytoplasm or in a horseshoe shape with stained deeply. The cytoplasmic is abundant. The nucleus of heterophils is lobed (usually 2 to 3). The cytoplasm of heterophilic granulocytes appears red and contains granules. (C) Edema, loose (black arrow), and hemorrhage (red arrow) in nasal cavity at 3 dpi. (E and F) Adhesion and partial exfoliation of cilia at 3 dpi. Inflammatory cell infiltration and mucosal edema in lamina propria. D, G, and H showed infraorbital sinus and trachea in the control group. The black box represents the area of the picture enlarged to 400×.

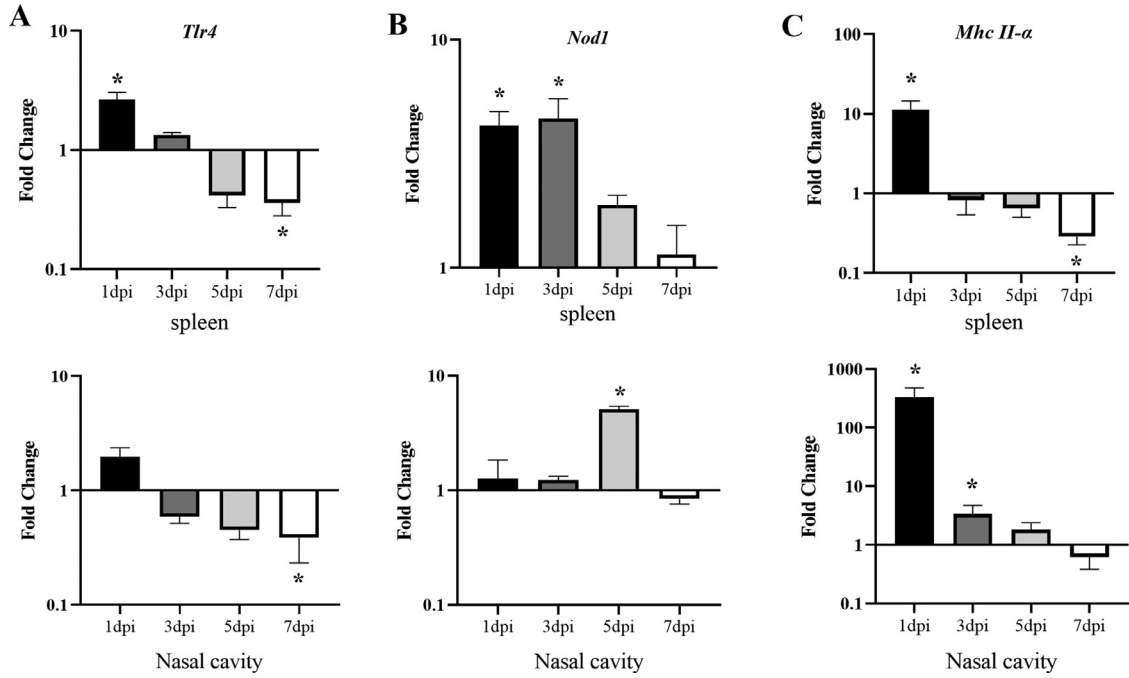
1 dpi, and no bacteria were detected in the thymus. *A. paragallinarum* was detected in all tissues at 3 dpi. The bacterial contents in the trachea reached a maximum at 5 dpi and then dramatically declined at 7 dpi (78.89 CFU/g). The change in bacterial load in the lung and spleen was similar to that in the trachea. In particular, the bacterial contents in blood remained the highest, reaching  $9.16 \times 10^5$  CFU/g at 5 dpi (Figure 5B). However, the bacterial content in the nasal cavity increased gradually from 1 to 7 dpi, reaching  $6.76 \times 10^5$  CFU/g at 7 dpi, which was the highest. Taken together, these results indicated that *A. paragallinarum* could rapidly invade the host, replicate in the blood, and cause bacteremia. Ultimately, *A. paragallinarum* colonized the upper respiratory tract.

### Expression of PRRs and MHC Class II Molecule mRNA in Infected Chickens

Innate immunity is a conservative host defense system that is activated through PRRs. To investigate the innate immune response induced by *A. paragallinarum*, 2 PRRs in the nasal contents and spleen were detected by qRT-PCR at 1, 3, 5, and 7 dpi. The relative expression level of the target genes was expressed as the expression level of the infected group compared with the control group. In the spleen, the expression of Toll-like receptor 4 (*Tlr4*) was significantly upregulated at 1 dpi and downregulated from 5 dpi. The expression of *Tlr4* had a similar pattern in the nasal cavity and was significantly downregulated by 0.39-fold at 7 dpi (*P* < 0.05). The expression of nucleotide-binding



**Figure 5.** The *A. paragallinarum* content in tissues of chickens after challenge. (A) *A. paragallinarum* content (log<sub>10</sub> CFU/g) in nasal cavity, trachea, lung, thymus, spleen, and blood of infected chickens. (B) Trend curve of *A. paragallinarum* content at 1, 3, 5, and 7 dpi. Bars represented the means ± SD (n = 5).



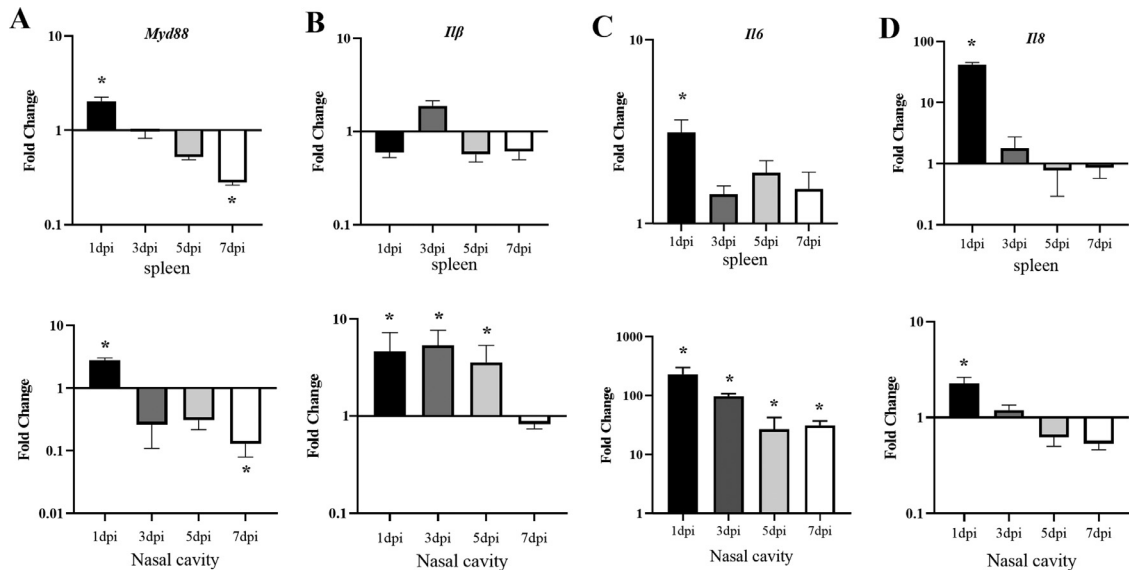
**Figure 6.** Expression of PRRs and MHC class II molecule in *A. paragallinarum*-infected chickens. The expression of (A) *Tlr4*, (B) *Nod1*, and (C) *Mhc II-α* in the spleen and nasal cavity at 1, 3, 5, and 7 dpi. Fold change was calculated from the gene expression of infected chickens compared with that of the control group. Bars represented the means  $\pm$  SDs (n = 5). Significant differences are indicated with a \*.

oligomerization domain 1 (*Nod1*) was significantly upregulated by 4.20-fold and 4.53-fold in the spleen at 1 and 3 dpi, respectively ( $P < 0.05$ ). However, *Nod1* was significantly upregulated by 5.12-fold in the nasal cavity at 5 dpi (Figure 6B). Our results suggested that the PRR pathways are tissue-dependent. The *Tlr4* and *Nod1* pathways may play a more significant role in the spleen than in the nasal cavity. As shown in Figure 6C, we also detected the expression of major histocompatibility complex (MHC) II- $\alpha$  in the nasal cavity and spleen. The expression of *Mhc II-α* was at the highest level at 1 dpi, decreased in the following 6 d, and was significantly

downregulated in the spleen at 7 dpi. In the nasal cavity, the expression of *Mhc II-α* followed a similar tendency but to a greater extent.

### Expression of Inflammatory Factors mRNA in Infected Chickens

Signal transduction upon engagement of PRRs is mediated through adaptor proteins. The adaptor protein of myeloid differentiation factor 88 (*Myd88*) was detected. As shown in Figure 7A, *Myd88* was significantly upregulated in the nasal cavity and spleen at 1



**Figure 7.** Expression of inflammatory factors in *A. paragallinarum*-infected chickens. The expression of (A) *Myd88*, (B) *Il1β*, (C) *Il6*, and (D) *Il8* in the spleen and nasal cavity at 1, 3, 5, and 7 dpi. Fold change was calculated from the gene expression of infected chickens compared with that of the control group. Bars represented the means  $\pm$  SDs (n = 5). Significant differences are indicated with a \*.

dpi. The results showed that the PRR pathways were activated after challenge. Upon PRR pathway activation, proinflammatory cytokines were induced. However, there was a remarkable difference between the spleen and nasal contents. The expression level of *Il1 $\beta$*  increased significantly in the nasal cavity at 1, 3, and 5 dpi, whereas it was basically unchanged in the spleen (Figure 7B). The expression of *Il6* was elevated in both spleen and the nasal cavity. At 1 dpi, the expression of *Il6* increased by 3.12-fold in the spleen and increased by 229.07-fold in the nasal cavity (Figure 7C). In contrast, the expression of *Il8* was significantly upregulated by 41.91-fold in the spleen and upregulated by 2.26-fold in the nasal cavity at 1 dpi (Figure 7D). On the other hand, our results showed that the inflammatory response is activated at an early stage of infection, and then quickly inhibited.

## DISCUSSION

In recent years, the morbidity of IC in intensive chicken farms has significantly risen, even in vaccinated flocks. IC usually infects laying hens, but now it also occurs in the early brooding stage. The pathogenicity of *A. paragallinarum* is determined by many factors, including the host immune response. In this study, we systematically investigated the clinical symptoms, histopathological changes, colonization and innate immune responses in *A. paragallinarum*-infected chickens. Twenty-eight-day-old chickens were challenged with *A. paragallinarum*. There are 2 main animal experimental infection models: an infraorbital sinus inoculation model and an “in-contact” model (Bragg, 2002; Xu et al., 2019). Both models are used to evaluate bacterial pathogenicity and have their own characteristics. Infraorbital sinus inoculation is a more severe challenge method than natural conditions of exposure (Matsumoto and Yamamoto, 1971). A previous study showed that all 35 strains produced clinical signs via infraorbital sinus inoculation. Eight strains cannot produce clinical signs of IC via the oral and nasal routes (Rimler, 1979). Bragg found that the scores of birds infected through the natural route of infection should be twice the scores obtained through direct infraorbital sinus inoculation (Bragg, 2002). In this study, we used rapid infraorbital sinus inoculation. Our results showed that all of the chickens exhibited clinical facial swelling and abundant nasal discharge at 3 dpi, and the whole course of the IC was approximately 7 d. The clinical symptoms and gross lesions were mainly in the upper respiratory tract, especially in the infraorbital sinus and trachea.

The pathogenicity of *A. paragallinarum* correlates directly with the distribution in the tissues of chickens. Our results showed that bacterial contents in all tested tissues reached a maximum at 5 dpi, except in the nasal cavity, and then had a dramatic decline at 7 dpi. The bacterial content in the nasal cavity increased gradually from 1 to 7 dpi, indicating that the nasal cavity is the

target organ of *A. paragallinarum*. These results indicated that *A. paragallinarum* could rapidly replicate in the blood and cause bacteremia. Finally, it was customized in the upper respiratory tract. High levels of bacteremia were the main cause of the acute inflammatory response in facial swelling chickens.

The innate immune system plays an essential role in the host's defense against pathogens during the early stage of infection. Gram-negative bacteria are sensed by TLRs and NLRs (Wilmanski et al., 2008; Brennan and Gilmore, 2018). LPS liberated from gram-negative bacteria associates with CD14 and is then transferred to *Tlr4*. After oligomerization, *Tlr4* recruits the canonical adaptor protein *Myd88*, triggering downstream signaling cascades and inducing proinflammatory cytokines and chemokines (Luo et al., 2020). *Nod1*, as an intracellular microbial recognition molecule, can recognize L-Ala- $\gamma$ -D-Glu-m-diaminopimelic acid, which is found in most gram-negative bacteria (Girardin et al., 2003). In this study, *Tlr4* was significantly upregulated at 1 dpi in the spleen. After activation of *Tlr4*, the adapter protein *Myd88* was significantly upregulated in the nasal cavity and spleen at 1 dpi, indicating that the *Tlr4* pathway was activated after *A. paragallinarum* challenge. Similarly, previous studies showed that the immune response was initiated by *Tlr4* after infection with *A. paragallinarum*, which in turn led to the Th2 response in nasal tissue (Boucher et al., 2014, 2015). The expression of *Nod1* was significantly upregulated in the spleen at 1 and 3 dpi. The expression of *Tlr4* and *Nod1* increased in the nasal cavity but was not significant. Our results suggested that the *Tlr4* and *Nod1* pathways may be more important in the spleen than in the nasal cavity, which suggested that the PRR pathways are tissue-dependent. The spleen is mainly composed of lymphocytes, which can quickly be involved in the innate immune response to *A. paragallinarum*.

PRRs recognize pathogen-associated molecular patterns and directly activate immune cells. Then, intracellular signaling cascades are activated and rapidly induce the production of proinflammatory cytokines, chemokines, and interferon involved in inflammatory and immune responses, which can reduce or inhibit the replication of the pathogen (Akira et al., 2006). In this study, the expression of *Il1 $\beta$*  and *Il6* in the nasal cavity was significantly higher than that in the spleen. This result consisted of gross lesions and pathological changes, in which the infiltration of inflammatory cells, macrophages, and heterophilic granulocytes was only observed in the nasal cavity and infraorbital sinus. Hyperinduction of cytokines, known as “cytokine storms,” may be relevant to severe pathological lesions and higher mortality in humans (Chan et al., 2005). A similar result was demonstrated in ducks challenged with the influenza H5N1 virus (Wei et al., 2013). On the other hand, our results showed that the inflammatory response is activated at the early stage of infection and then quickly inhibited. The trend was consistent with the changes over the whole course of IC, including clinical symptoms, gross

lesions, and *A. paragallinarum* content. We deduced that the high level of proinflammatory cytokines (*Il1 $\beta$* , *Il6*, and *Il8*) in the nasal cavity at an early stage of infection might be the main factor related to acute upper respiratory inflammation in chickens. In addition, several studies demonstrated that the interaction of *Salmonella* with *Tlr4* induces the expression of avian  $\beta$ -defensins, *Il1 $\beta$* , and *Il6* (Yoshimura et al., 2006), while some other TLRs interact with corresponding ligands to upregulate only *Il1 $\beta$*  and *Il6* (Abdel-Mageed et al., 2014). However, synthesized IL1 $\beta$  can induce  $\beta$ -defensins (Yoshimura, 2015). In this study, a high level of *Il1 $\beta$*  may promote the expression of  $\beta$ -defensins to remove *A. paragallinarum*. Moreover, antimicrobial peptides have diverse chemical properties and cell targets, and they are promising antimicrobial agents, especially against pathogens with poor vaccine protective efficacy or antibiotic resistance (Fjell et al., 2011; Mahlapuu et al., 2016; Lázár et al., 2018).

In conclusion, we systematically explored the whole disease process of IC and the innate immune responses induced by *A. paragallinarum*. The whole course of the IC was approximately 7 d. *A. paragallinarum* could rapidly invade the host, replicate in the blood, and cause bacteremia. The clinical symptoms and gross lesions were mainly in the upper respiratory tract, especially in the infraorbital sinus and trachea. The *Tlr4* and *Nod1* pathways were activated and induced proinflammatory responses after infection with *A. paragallinarum* in chickens. *Il1 $\beta$* , *Il6*, and *Il8* in the nasal cavity were significantly increased at the early stage of infection, which may be the main role related to acute upper respiratory inflammation in chickens. Moreover, a high level of *Il1 $\beta$*  may induce  $\beta$ -defensins to remove *A. paragallinarum*. Synthetic antimicrobial peptides or promoting the production of antimicrobial peptides in chickens is a novel strategy for prevention or control strategies for IC.

## ACKNOWLEDGMENTS

This work was supported by the Natural Science Foundation of the Jiangsu Higher Education Institutions of China (19KJB230002); the Earmarked Fund for Modern Agroindustry Technology Research System (CARS-40-K16) and a Project Funded by the Priority Academic Program Development of Jiangsu Higher Education Institutions (PAPD).

## DISCLOSURES

The authors declare that the research was conducted in the absence of any commercial or financial relationships that could be construed as a potential conflict of interest.

## REFERENCES

Abdel-Mageed, A. M., N. Isobe, and Y. Yoshimura. 2014. Effects of different TLR ligands on the expression of proinflammatory

cytokines and avian  $\beta$ -defensins in the uterine and vaginal tissues of laying hens. *Vet. Immunol. Immunopathol.* 162:132–141.

Akira, S., S. Uematsu, and O. Takeuchi. 2006. Pathogen recognition and innate immunity. *Cell.* 124:783–801.

Anjaneya Singh, S. D., K. Dhama, V. Gowthaman, and M. M. Chawak. 2013. Pathogenicity study of field isolates of *Avibacterium paragallinarum* in experimentally infected birds. *Indian J. Vet. Pathol.* 37:13–17.

Blackall, P. J., H. Christensen, T. Beckenham, L. L. Blackall, and M. Bisgaard. 2005. Reclassification of *Pasteurella gallinarum*, [*Haemophilus*] *paragallinarum*, *Pasteurella avium* and *Pasteurella volantium* as *Avibacterium gallinarum* gen. nov., comb. nov., *Avibacterium paragallinarum* comb. nov., *Avibacterium avium* comb. nov. and *Avibacterium volantium* comb. nov. *Int. J. Syst. Evol. Microbiol.* 55:353–362.

Blackall, P. J., and E. Soriano-Vargas. 2020. Infectious coryza and related bacterial infections. *Dis. Poult.* 890–906.

Boucher, C. E., C. W. Theron, A. C. Hitzeroth, and R. R. Bragg. 2015. Regulation of chicken immunity-related genes and host response profiles against *Avibacterium paragallinarum* pathogen challenge. *Vet. Immunol. Immunopathol.* 167:70–74.

Boucher, C. E., C. W. Theron, A. C. Jansen, and R. R. Bragg. 2014. Transcriptional profiling of chicken immunity-related genes during infection with *Avibacterium paragallinarum*. *Vet. Immunol. Immunopathol.* 158:135–142.

Bragg, R. R. 2002. Virulence of South African isolates of *Haemophilus paragallinarum*. Part 1: NAD-dependent field isolates. *Onderstepoort. J. Vet. Res.* 69:163–169.

Brennan, J. J., and T. D. Gilmore. 2018. Evolutionary origins of toll-like receptor signaling. *Mol. Biol. Evol.* 35:1576–1587.

Chan, M. C., C. Y. Cheung, W. H. Chui, S. W. Tsao, J. M. Nicholls, Y. O. Chan, R. W. Chan, H. T. Long, L. L. Poon, Y. Guan, and J. S. Peiris. 2005. Proinflammatory cytokine responses induced by influenza A (H5N1) viruses in primary human alveolar and bronchial epithelial cells. *Respir. Res.* 6:135.

Chen, X., J. K. Mifflin, P. Zhang, and P. J. Blackall. 1996. Development and application of DNA probes and PCR tests for *Haemophilus paragallinarum*. *Avian Dis.* 40:398–407.

Chukiatsiri, K., J. Sasipreeyajan, P. J. Blackall, S. Yuwatanichsampan, and N. Chansiripornchai. 2012. Serovar identification, antimicrobial sensitivity, and virulence of *Avibacterium paragallinarum* isolated from chickens in Thailand. *Avian Dis.* 56:359–364.

Crispo, M., C. G. Sentfes-Cué, G. L. Cooper, G. Mountainspring, C. Corsiglia, A. A. Bickford, and S. T. Stoute. 2018. Otitis and meningoencephalitis associated with infectious coryza (*Avibacterium paragallinarum*) in commercial broiler chickens. *J. Vet. Diagn. Invest.* 30:784–788.

Fjell, C. D., J. A. Hiss, R. E. Hancock, and G. Schneider. 2011. Designing antimicrobial peptides: form follows function. *Nat. Rev. Drug Discov.* 11:37–51.

Gallardo, R. A., A. P. Da Silva, S. Egaña-Labrin, S. Stoute, C. Kern, H. Zhou, G. Cutler, and C. Corsiglia. 2020. Infectious coryza: persistence, genotyping, and vaccine testing. *Avian Dis.* 64:157–165.

Girardin, S. E., L. H. Travassos, M. Hervé, D. Blanot, I. G. Boneca, D. J. Philpott, P. J. Sansonetti, and D. Mengin-Lecreulx. 2003. Peptidoglycan molecular requirements allowing detection by Nod1 and Nod2. *J. Biol. Chem.* 278:41702–41708.

Iqbal, M., V. J. Philbin, and A. L. Smith. 2005. Expression patterns of chicken Toll-like receptor mRNA in tissues, immune cell subsets and cell lines. *Vet. Immunol. Immunopathol.* 104:117–127.

Lázár, V., A. Martins, R. Spohn, L. Daruka, G. Grézal, G. Fekete, M. Számel, P. K. Jangir, B. Kintses, B. Csörgő, Á. Nyerges, Á. Györkei, A. Kincses, A. Dér, F. R. Walter, M. A. Deli, E. Urbán, Z. Hegedűs, G. Olajos, O. Méhi, B. Bálint, I. Nagy, T. A. Martinek, B. Papp, and C. Pál. 2018. Antibiotic-resistant bacteria show widespread collateral sensitivity to antimicrobial peptides. *Nat. Microbiol.* 3:718–731.

Li, R., G. Li, J. Lin, S. Han, X. Hou, H. Weng, M. Guo, Z. Lu, N. Li, Y. Shang, T. Chai, and L. Wei. 2018. Fowl adenovirus serotype 4 SD0828 infections causes high mortality rate and cytokine levels in specific pathogen-free chickens compared to ducks. *Front Immunol.* 9:49.

Liang, Q. L., J. Luo, K. Zhou, J. X. Dong, and H. X. He. 2011. Immune-related gene expression in response to H5N1 avian



- influenza virus infection in chicken and duck embryonic fibroblasts. *Mol. Immunol.* 48:924–930.
- Luo, L., R. M. Lucas, L. Liu, and J. L. Stow. 2020. Signalling, sorting and scaffolding adaptors for Toll-like receptors. *J. Cell Sci.* 133: jcs239194.
- Mahlapu, M., J. Håkansson, L. Ringstad, and C. Björn. 2016. Antimicrobial peptides: an emerging category of therapeutic agents. *Front Cell Infect. Microbiol.* 6:194.
- Matsumoto, M., and R. Yamamoto. 1971. A broth bacterin against infectious coryza: immunogenicity of various preparations. *Avian Dis.* 15:109–117.
- Morales-Erasto, V., F. Falconi-Agapito, G. A. Luna-Galaz, L. E. Saravia, A. Montalvan-Avalos, E. E. Soriano-Vargas, and M. Fernández-Díaz. 2016. Coinfection of *Avibacterium paragallinarum* and *Ornithobacterium rhinotracheale* in chickens from Peru. *Avian Dis.* 60:75–78.
- Patil, V., D. Mishra, and D. Mane. 2017a. Virulence pattern of *Avibacterium paragallinarum* isolates studied from Indian field condition. *Int. J. Livestock Res* 1:201–207.
- Patil, V. V., D. Mishra, and D. V. Mane. 2017b. 16S ribosomal RNA sequencing and molecular serotyping of *Avibacterium paragallinarum* isolated from Indian field conditions. *Vet. World* 10:1004–1007.
- Paudel, S., M. Hess, and C. Hess. 2017. Coinfection of *avibacterium paragallinarum* and *gallibacterium anatis* in specific-pathogen-free chickens complicates clinical signs of infectious coryza, which can be prevented by vaccination. *Avian Dis.* 61:55–63.
- Rimler, R. B. 1979. Studies of the pathogenic avian Haemophili. *Avian Dis.* 23:1006–1008.
- Sandoval, V. E., H. R. Terzolo, and P. J. Blackall. 1994. Complicated infectious coryza outbreaks in Argentina. *Avian Dis.* 38:672–678.
- Tao, Z. Y., C. H. Zhu, Z. H. Shi, C. Song, W. J. Xu, W. T. Song, J. M. Zou, and A. J. Qin. 2015. Molecular characterization, expression, and functional analysis of NOD1 in Qingyuan partridge chicken. *Genet. Mol. Res.* 14:2691–2701.
- Wahyuni, A., C. R. Tabbu, S. Artanto, D. C. B. Setiawan, and S. I. Rajaguguk. 2018. Isolation, identification, and serotyping of *Avibacterium paragallinarum* from quails in Indonesia with typical infectious coryza disease symptoms. *Vet. World* 11:519–524.
- Wei, L., P. Jiao, Y. Song, L. Cao, R. Yuan, L. Gong, J. Cui, S. Zhang, W. Qi, S. Yang, and M. Liao. 2013. Host immune responses of ducks infected with H5N1 highly pathogenic avian influenza viruses of different pathogenicities. *Vet. Microbiol.* 166:386–393.
- Welchman Dde, B., S. A. King, P. Wragg, A. M. Wood, R. M. Irvine, W. J. Pepper, R. Dijkman, and J. J. de Wit. 2010. Infectious coryza in chickens in Great Britain. *Vet. Rec.* 167:912–913.
- Wen, S., X. Chen, F. Xu, and H. Sun. 2016. Validation of reference genes for real-time quantitative PCR (qPCR) analysis of *Avibacterium paragallinarum*. *PLoS One* 11:e0167736.
- Wilmanski, J. M., T. Petnicki-Ocwieja, and K. S. Kobayashi. 2008. NLR proteins: integral members of innate immunity and mediators of inflammatory diseases. *J. Leukoc. Biol.* 83:13–30.
- Xu, Y., J. Cheng, X. Huang, M. Xu, J. Feng, C. Liu, and G. Zhang. 2019. Characterization of emergent *Avibacterium paragallinarum* strains and the protection conferred by infectious coryza vaccines against them in China. *Poult Sci.* 98:6463–6471.
- Yoshimura, Y. 2015. Avian  $\beta$ -defensins expression for the innate immune system in hen reproductive organs. *Poult Sci.* 94:804–809.
- Yoshimura, Y., H. Ohashi, K. Subedi, M. Nishibori, and N. Isobe. 2006. Effects of age, egg-laying activity, and *Salmonella*-inoculation on the expressions of gallinacin mRNA in the vagina of the hen oviduct. *J. Reprod. Dev.* 52:211–218.