



Double pouched, sigmoid gallbladder that can cause a diagnostic dilemma to radiologists: a case report

Satheesha B. Nayak, Ashwini P. Aithal, Abhinitha Padavinangadi, Gayathri Prabhu

Department of Anatomy, Melaka Manipal Medical College (Manipal Campus), Manipal Academy of Higher Education, Manipal, India

Abstract: Gallbladder shows frequent variations in position, shape, interior, and its duct system. These variations may go unnoticed lifelong; however, they may predispose it for cholecystitis and cholelithiasis. We observed a double pouched gallbladder in an adult male cadaver. The gallbladder was folded to have a sigmoid shape. It had two broad pouches: anterior and posterior and a narrow isthmus in between. Its anterior pouch was covered by peritoneum, whereas the posterior pouch was covered by extrahepatic connective tissue. We discuss the clinical and radiological importance of the case.

Key words: Gallbladder, Hepatic, Laparoscopy, Cholecystectomy, Cholelithiasis

Received October 28, 2017; Revised April 25, 2018; Accepted May 19, 2018

Introduction

Gallbladder is a pear-shaped organ that belongs to extrahepatic biliary apparatus. It is situated under the right lobe of the liver. It is involved in the storage, concentration, and ejection of the bile. Some of the reported variations of the gallbladder include its agenesis, duplication, the presence of phrygian cap, floating gallbladder with a mesentery and intrahepatic gallbladder. These variations have been reported from cadaveric dissections, autopsies, or surgical procedures. Most of the variations of gallbladder either hinder the biliary flow or predispose it to cholecystitis or cholelithiasis. These variations may also pose challenges to the diagnosing radiologist and operating surgeons. We report here, a unique variation of double pouched gallbladder that can lead to diagnostic

dilemmas. A similar case has not been reported yet in the literature.

Case Report

During dissection classes for medical undergraduates, we observed a double pouched sigmoid gallbladder in a male cadaver aged approximately 60–65 years. The gallbladder had two pouches; anterior and posterior. The anterior pouch was covered by peritoneum, but the posterior pouch was just covered by extrahepatic connective tissue. There was a narrow isthmus between the two pouches. At the constriction, the diameter of the gallbladder was 1 cm. It was folded at the constriction two times, thus getting a sigmoid shape. The posterior pouch was situated in a posterior extension of the fossa for gallbladder. When unfolded, it measured 13 cm. The cystic duct was short and straight and measured 2 cm in length. Due to the folding and pouching of the gallbladder, the quadrate lobe was narrow, and the porta hepatis was very congested. The interior of the bladder showed normal folds of the mucosa. There was no evidence of any inflammation or cholelithiasis. The variations are shown in Figs. 1 and 2.

Corresponding author:

Ashwini P. Aithal
Department of Anatomy, Melaka Manipal Medical College (Manipal Campus), Manipal Academy of Higher Education, Madhav Nagar, Manipal, Karnataka State 576104, India
Tel: +91-8095132879, Fax: +91-820-2571905,
E-mail: ashwini.anat@gmail.com

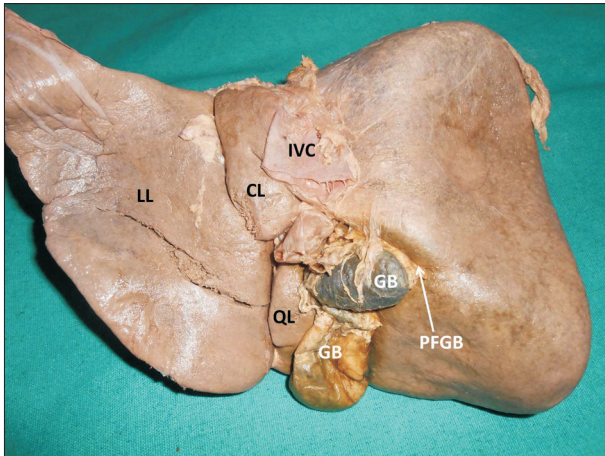


Fig. 1. Photograph of postero-inferior aspect of liver showing the double pouched, folded gallbladder. CL, caudate lobe; GB, gallbladder; IVC, inferior vena cava; LL, left lobe; PFGB, posterior fossa for gallbladder; QL, quadrate lobe.

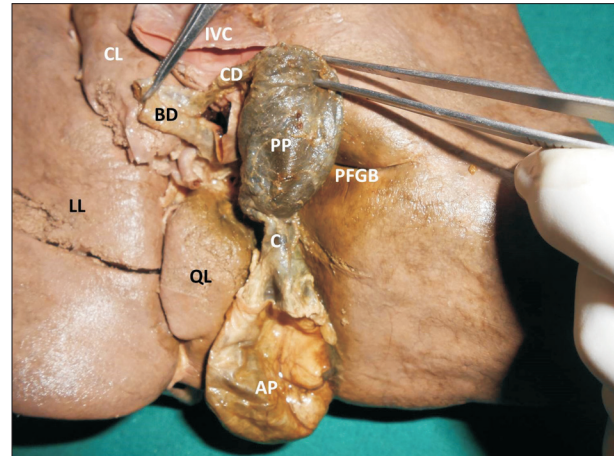


Fig. 2. Photograph of a closer view of the double pouched, folded gallbladder after unfolding it. AP, anterior pouch of gallbladder; BD, bile duct; C, middle constricted part (isthmus); CD, cystic duct; CL, caudate lobe; IVC, inferior vena cava; LL, left lobe; PFGB, posterior fossa for gallbladder; PP, posterior pouch of gallbladder; QL, quadrate lobe.

Discussion

Gallbladder develops from the foregut through the hepatic diverticulum. Many of its congenital anomalies are well known. In rare cases, the gallbladder undergoes atresia. It may be partially or completely duplicated [1, 2], or may be septate [3] or may possess a phrygian cap [4]. In rare cases, the gallbladder may be suprahepatic in position [5]. 'Left sided gallbladder' is another congenital anomaly of the gallbladder where the bladder is situated on the left side of the ligamentum teres [6]. In a condition called 'floating gallbladder', the gallbladder is suspended by mesentery and is free to move [7]. Most of these congenital anomalies may remain asymptomatic for some time and may be incidental findings. However, they may predispose the bladder for cholecystitis and cholelithiasis. They may also cause hindrance in the free flow of bile from in and out of the gallbladder.

The current case that we are presenting differed from all the previously presented congenital anomalies of gallbladder. The present case is not of duplication but a single gallbladder with two pouches. This type of variation has not been published before. Additionally, in all previous reported cases there were two cavities in gallbladder with a septum in between but in the present case the gallbladder did not have septum, just one cavity which was constricted in the middle. We presume that this case is also a congenital anomaly as there were no obvious signs of pathology in the walls or at the constriction. Also, there were no gall stones in the lumen. The constriction found in the gallbladder would have appeared early during

development of the cystic bud from the original hepatic diverticulum. The two pouches were located in two separate parts of gallbladder fossa and there was associated narrowing of the quadrate lobe.

Meticulous dissection of the callot's triangle or tubular structures in the subhepatic region, identification of anatomical details prior to surgery along with a high degree of awareness of gallbladder anomalies could possibly prevent catastrophic consequences [8]. Complete pre-operative evaluation of anatomy with special attention to the biliary ductal anatomy is must to avoid potential damage to the ductal system. This anatomical variation might lead to diagnostic dilemmas to the radiologists and might pose difficulties during the laparoscopic cholecystectomy. Hence, laparoscopic cholecystectomy with intraoperative cholangiography is the appropriate treatment in such conditions.

References

1. Koszman B. Gall-bladder duplication: case report. *Pol Przegl Chir* 2014;86:433-5.
2. Nayak SB, Shetty SD, Surendran S, Jetti R, Kumar N, Sirasana-gandla SR. Double gallbladder completely enclosed in a cystogastric fold of peritoneum. *Anat Cell Biol* 2014;47:132-4.
3. Esper E, Kaufman DB, Crary GS, Snover DC, Leonard AS. Septate gallbladder with cholelithiasis: a cause of chronic abdominal pain in a 6-year-old child. *J Pediatr Surg* 1992;27:1560-2.
4. van Kamp MJ, Bouman DE, Steenvoorde P, Klaase JM. A phrygian cap. *Case Rep Gastroenterol* 2013;7:347-51.

5. Hibbs H, Ahmad U. Inverted liver with suprahepatic, anteriorly displaced gallbladder. *J La State Med Soc* 2010;162:150-2.
6. Ishii H, Noguchi A, Onishi M, Takao K, Maruyama T, Taiyoh H, Araki Y, Shimizu T, Izumi H, Tani N, Yamaguchi M, Yamane T. True left-sided gallbladder with variations of bile duct and cholecystic vein. *World J Gastroenterol* 2015;21:6754-8.
7. Miyakura Y, Sadatomo A, Ohta M, Lefor AT, Sata N, Nishimura N, Sakatani T, Yasuda Y. Floating gallbladder strangulation caused by the lesser omentum: report of a case. *Surg Today* 2012;42:693-6.
8. Pillay Y. Gallbladder duplication. *Int J Surg Case Rep* 2015;11:18-20.