


Magnetic resonance imaging of avascular necrosis of the femoral head: predictive findings of total hip arthroplasty

Acta Radiologica Open
10(4) 1–7
© The Foundation Acta
Radiologica 2021
Article reuse guidelines:
sagepub.com/journals-permissions
DOI: 10.1177/20584601211008379
journals.sagepub.com/home/arr


Matti Väänänen^{1,2}, Osmo Tervonen^{1,2,3} and
Mika T Nevalainen^{1,2,3,4} 

Abstract

Background: Avascular osteonecrosis of the femoral head (AVNFH) is an ischemic condition which despite different treatments often leads to collapse of the femoral head and to total hip arthroplasty. However, the magnetic resonance imaging findings predisposing to disease progression and total hip arthroplasty are somewhat elusive.

Purpose: To evaluate the magnetic resonance imaging findings of AVNFH and to assess the patterns of findings which may predict total hip arthroplasty.

Materials and methods: A retrospective study was conducted with a total of 18 diagnosed AVNFH treated with core decompression combined with intraosseous stem cell treatment. After treatment, magnetic resonance imaging follow-ups were done at three-month and one-year follow-up or until total hip arthroplasty. Association Research Circulation Osseous classification and magnetic resonance imaging findings such as the size and the location of the AVNFH, bone marrow edema in femoral neck, effusion and subchondral fracture were evaluated.

Results: Hips advancing to total hip arthroplasty have more often bone marrow edema in femoral neck (90% vs. 0%), adjacent to necrotic lesion (100% vs. 43%) and in acetabulum (90% vs. 14%), but also subchondral fractures (70% vs. 0%), effusion (80% vs. 29%), and synovitis (80% vs. 14,3%). The greater size and the lateral weight-bearing location of the necrotic lesion also predicted future total hip arthroplasty.

Conclusion: Hips advancing to total hip arthroplasty have often a combination of pathognomonic AVNFH imaging findings compared to hips not advancing to total hip arthroplasty.

Keywords

Femur, hip, magnetic resonance imaging, osteonecrosis

Received 12 March 2021; accepted 19 March 2021

Introduction

Avascular osteonecrosis of the femoral head (AVNFH) is an ischemic condition characterized by local disruption of intraosseous blood supply affecting predominantly young and middle-aged adults.¹ The annual incidence rates of AVNFH are rather elusive: it is estimated that in Japan approximately 2500 new cases arise annually, whereas in the United States the corresponding number is 10,000 to 30,000.^{2,3} If left untreated, AVNFH often progresses and often leads to femoral head collapse, early osteoarthritis, and total hip arthroplasty (THA) at relatively young age; in the United States, AVNFH is the underlying cause in roughly 10% of all THAs.⁴ Most common predisposing factors for osteonecrosis are trauma,

corticosteroids, and alcoholism.^{1,3,5} The etiology of the ischemic process of the femoral head is still unclear, and different and multifactorial etiologies have been

¹Department of Diagnostic Radiology, Oulu University Hospital, Oulu, Finland

²Medical Research Center, Oulu University of Oulu, Oulu, Finland

³Research Unit of Medical Imaging, Physics and Technology Faculty of Medicine, University of Oulu, Oulu, Finland

⁴Department of Radiology, Central Finland Central Hospital, Jyväskylä, Finland

Corresponding author:

Mika Nevalainen, Oulun yliopistollinen sairaala PL 50, Oulu 90029, Finland.

Email: mika.nevalainen@oulu.fi



proposed such as traumatic vascular disruption of the vascular network of femoral head, intravascular occlusions, and increased intraosseous pressure caused by fatty infiltration of the bone marrow leading to vascular compression.⁶ Beyond the patient history and physical examination, various imaging techniques are applied to diagnose AVNFB:⁷ Conventional radiography is usually performed first, followed by magnetic resonance imaging (MRI), which is the gold standard of imaging with over 99% sensitivity and specificity for AVNFB.^{1,5} As distinguishing the subchondral fracture on MRI may be challenging, CT scan can provide resolution to this issue.^{8,9} Different pre-collapse treatment strategies have been suggested including pharmacological agents, such as bisphosphonates, but also biophysical and surgical treatments. Surgical treatments include core decompression with or without mesenchymal stem cell implantation, bone grafts or tantalum rods, and osteotomy.^{1,3,5} In post-collapse stage, the THA is treatment of choice. Although MRI is powerful imaging tool on AVNFB, the radiologic imaging appearances predisposing to the progression of the AVNFB and, ultimately to THA, remain vague. Thus, the purpose of this study was to characterize MR imaging patterns leading to disease progression and subsequent THA.

Material and Methods

Patients

Institutional review board approval was obtained and the requirement for informed consent was waived. This study was conducted according to the World Medical Association Declaration of Helsinki. A retrospective review of 15 consecutive patients (12 males, 3 females) aged 19 to 69 years (mean 54 years) undergoing MRI for AVNFB and treatment with core decompression combined with local intraosseous stem cell therapy between May 2015 and December 2017 was performed. Three patients had both hips affected, so in total 18 hips were included in this study. Accordingly, the MRI studies were reviewed by two radiologists with four and six years of experience: 18 initial MRI studies, 18 three-month follow-up studies, and 10 one-year follow-up studies were evaluated. During the follow-up lasting until November 2018, 10 patients received a THA and 1 patient did not have the one-year follow-up MRI performed.

Imaging technique and statistical analysis

All MRI examinations were performed on 1.5 Tesla MRI scanners (Optima and Signa, General Electric Medical Systems, Milwaukee, Wisconsin, USA) with dedicated coils and routine avascular necrosis protocol

including coronal T1- and STIR or T2-weighted fat-saturated, axial T2-weighted fat-saturated and sagittal T1-weighted sequences; additionally, roughly 50% of the MRI scans included an i.v. contrast coronal T1-weighted fat-saturated sequence. The size of the AVNFB lesion was evaluated in T1-weighted coronal plane (both the greatest length and the depth of the lesion, and the freehand drawn area), as well as in the T1-weighted sagittal plane (Fig. 1). The percentage of the volume of the AVNFB was calculated as follows: the areas of the necrotic lesion and the femoral head were freehand drawn from every image in coronal plane and then the sum of the area of the necrosis was divided by the sum of the area of femoral head (Fig. 2). Then, lesions were graded as small (less than 15%), moderate (15–30%), and large (more than 30%). Location of the necrotic lesion in the femoral head was estimated. Additionally, the extent of the necrotic lesion to the weight-bearing area of femoral head was estimated according to Japanese Investigation Committee (JIC) guidelines (Type A lesion occupying medial one-third or less of the weight-bearing portion of the femoral head, Type B lesion occupying medial two-thirds, Type C1 and C2 both occupying more than the two medial two-thirds; Type C2 extending laterally to the acetabular edge whereas Type C1 does not) (Fig. 3). Furthermore, double-line sign, bone marrow edema (BME) adjacent to the AVNFB, BME at femoral neck, subchondral fracture, effusion and synovitis in the hip joint, BME at the acetabulum, and the Association Research Circulation Osseous (ARCO) stage were collected and graded (Fig. 4). Initially, the effusion was graded as normal, small/minimal, moderate (fluid extending around the femoral neck), and severe (bulging of joint capsule), and on the statistical analyses only moderate and severe were treated as significant effusion. Synovitis was considered present if synovial enhancement was seen with i.v. contrast sequence or if clear synovial hypertrophy was present within the joint capsule. Routine anteroposterior and lateral view hip radiographs were also available on all patients; on radiographs, the findings suggestive of AVNFB – crescent sign, femoral head lucency, or distinct necrotic lesion – were evaluated and applied to the ARCO classification, which is a four-tiered grading system for AVNFB: in stage I radiographs are normal, but either MRI or bone scan is positive; in stage II radiographs are abnormal (subtle trabecular bone changes) without any evidence of subchondral fracture, or femoral head deformity. Accordingly, MRI findings are characteristic with BME, double-line sign, and necrotic lesion; in stage III fracture in the subchondral or necrotic zone is present on radiographs or MRI, but the joint space is still preserved; in stage IV features of secondary osteoarthritis with

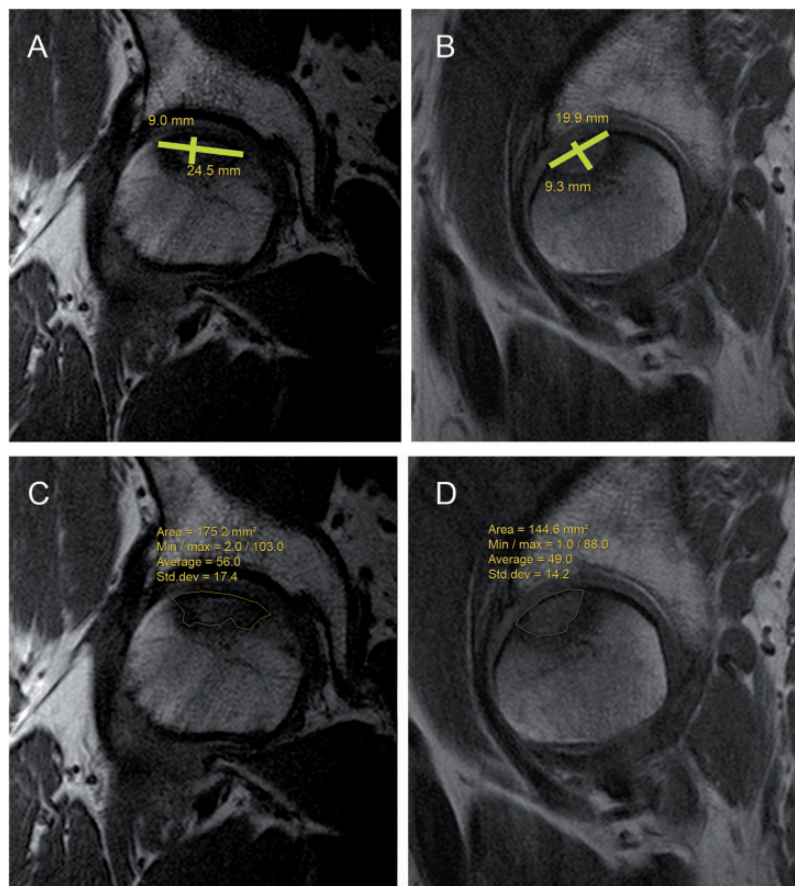


Fig. 1. Maximal measures and area (yellow lines) of the avascular necrosis of the femoral head (AVNFH) were measured from coronal (a, c) and sagittal planes in T1-weighted images (b, d). The surrounding edema was not included.

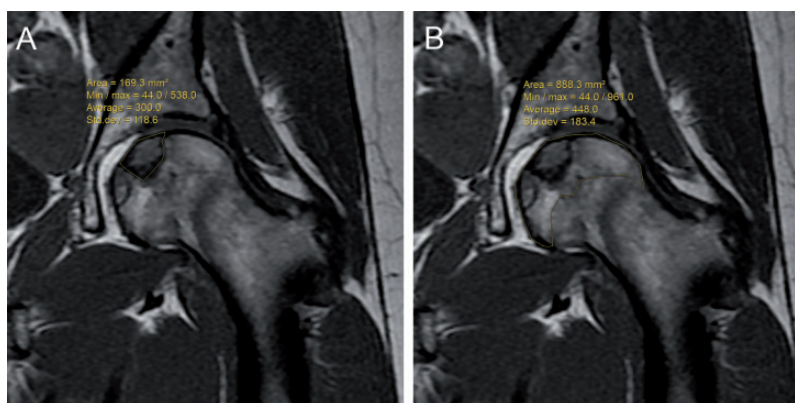


Fig. 2. Avascular necrosis lesion and femoral head (yellow lines) (a, b) were measured from every coronal plane to calculate the percentage of the volume of the necrosis. Femoral head volume was measured along the epiphyseal line.

associated femoral head deformity, acetabular changes, and joint destruction are present.¹⁰

For statistical analyses, paired Student's T-test was applied to test statistical significance between the groups. Statistical software (SPSS Inc., version 24.0, Chicago, IL) was used for the analysis.

Results

Two groups were formed of the hips advancing and not advancing to THA. The group advancing to THA consisted of seven hips undergoing THA after three-month follow-up and three hips undergoing THA after

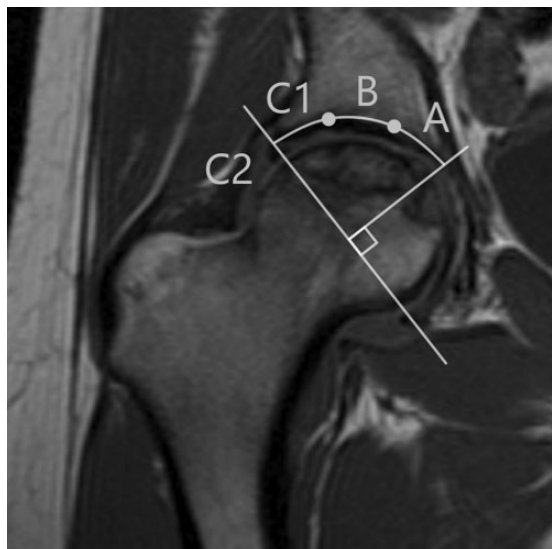


Fig. 3. The extent of the avascular necrosis of the femoral head (AVNFH) to the weight-bearing region of the femoral head was evaluated according to Japanese Investigation Committee (JIC) classification. This shown AVNFH extends to lateral third of the weight-bearing area representing JIC type C1 lesion.

one-year follow-up. From THA the MRI findings were separately evaluated retrogradely and then combined forming findings in the two last MRI scans before THA. Another group (8 hips) which did not advance to THA had initial, three-month and one-year follow-up MRI findings evaluated as a control. One ARCO stage I hip was lost after three-month follow-up for patient being completely symptomless and subsequent one-year follow-up MRI was not performed.

Most of the lesion size and area measurements showed minor growth in both groups, but most statistically significant increases in size were seen in the group advancing to THA. Also, the size and area measurements of the AVNFH lesion were generally greater in the group advancing to THA (Table 1). In the group not advancing to THA the volume of most AVNFH was less than 15% of the femoral head, whereas in the group advancing to THA most AVNFH were greater than 15% (Table 2). There was not apparent difference in the location of the necrotic lesion. In the group advancing to THA 70% and in the group not advancing to THA 75% of the necrotic lesions located in the central and anterolateral portion of the weight-bearing femoral head. Instead, the extent of the lesions differed between the groups. In the group advancing to THA 90% of the AVNFHs extended more laterally than medial two-thirds of the weight-bearing femoral head (JIC types C1 and C2). In the group not advancing to THA the extent to weight-bearing femoral head of the lesions was more varied (Table 3).

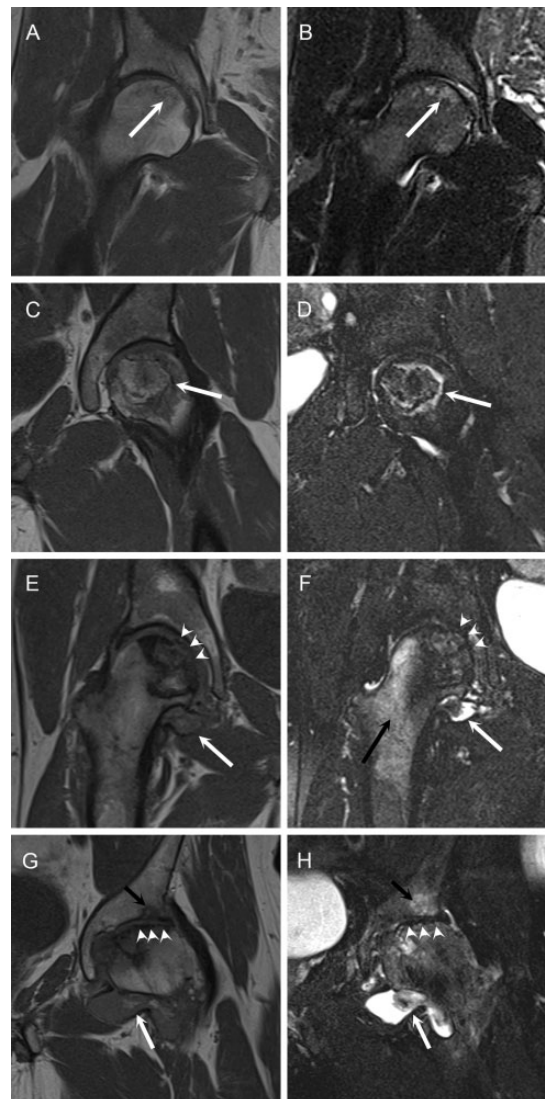


Fig. 4. The different ARCO stages on coronal T1-weighted (a, c, e, g) and T2-weighted fat-saturated (b, d, f, h) MR images. The ARCO I stage avascular necrosis of the femoral head (AVNFH) shows only subtle bone marrow edema in the subchondral bone (white arrow) (a, b), while plain radiograph findings are still normal (not shown). The ARCO II stage AVNFH demonstrates characteristic double-line sign (white arrows) surrounding the lesion (c, d). Plain radiographs show subtle changes but no findings of subchondral fracture (not shown). The ARCO III stage AVNFH depicts subchondral fracture i.e. irregularity of the bony contour (white arrowheads), effusion with synovitis (white arrows) and bone marrow edema (black arrow) spanning to the neck of the femur (e, f). The ARCO IV stage AVNFH shows deformity of the femoral head paired with full-thickness cartilage loss (white arrowheads), acetabular bone marrow edema (black arrows) and effusion with synovitis implying secondary osteoarthritis.

In the group advancing to THA, eventually every hip had BME adjacent to the AVNFH. Nearly all (80–90%) had BME in the femoral neck, effusion, and synovitis. Out of the 10 hips, the presence of

Table 1. AVNFH lesions of hips advancing to THA are generally larger.

	Non-THA group		THA group	
	Initial	12 month	2nd last MRI	Last MRI
TI cor width (mm)	22.4	26.4*	28.2	30.2
TI cor depth (mm)	13.7	14.9	13.2	13.8
TI cor area (mm ²)	246.7	277.9	265.5	297.5*
TI sag length (mm)	28.2	27.6	29.1	32.8*
TI sag depth (mm)	11.4	13.6	12.9	14.3*
TI sag area (mm ²)	248.0	286.0	276.5	347.0*
Volume of femoral head (%)	17.4	19.5	18.4	21.3*

MRI: magnetic resonance imaging; cor: coronal; sag: sagittal; THA: total hip arthroplasty.

*Statistically significant change ($p < 0.05$).

Table 2. Volumes of AVNFH in hips advancing and not advancing to THA.

	Non-THA group (N = 8)	THA group (N = 10)
Volume		
Small (less than 15%)	6	3
Moderate (15–30%)	0	4
Large (more than 30%)	2	3

THA: total hip arthroplasty.

Table 3. The extent to weight-bearing femoral head of AVNFH in hips advancing and not advancing to THA (according to JIC guidelines).

	Non-THA group (N = 8)	THA group (N = 10)
Type		
A	2	0
B	3	1
C1 and C2	3	9 ^a

THA: total hip arthroplasty.

^aOnly one type C2 lesion existed in the study.

Table 4. The prevalence of MRI findings in hips advancing and not advancing to THA.

	Non-THA group (N = 8)			THA group (N = 10)	
	Initial	3 month	12 month (N = 7 ^a)	2nd last MRI	Last MRI
Double-line sign	7 (87.5%)	6 (75%)	5 (71.4%)	5 (50%)	3 (30%)
BME AVN lesion	3 (37.5%)	5 (62.5%)	3 (42.9%)	9 (90%)	10 (100%)
BME femoral neck	0	2 (25%)	0	9 (90%)	9 (90%)
Subchondral fracture	0	0	0	5 (50%)	7 (70%)
BME acetabulum	0	1 (12.5%)	1 (14.3%)	6 (60%)	9 (90%)
Effusion	4 (50%)	1 (12.5%)	2 (28.6%)	8 (80%)	8 (80%)
Synovitis	1 (12.5%)	1 (12.5%)	1 (14.3%)	9 (90%)	8 (80%)

THA: total hip arthroplasty; MRI: magnetic resonance imaging; BME: bone marrow edema; ARCO: Association Research Circulation Osseous; AVN: avascular necrosis.

^aOne ARCO stage I hip was lost during follow-up for being symptomless and one-year MRI was not done.

acetabular BME increased from six to nine and the presence of subchondral fracture from five to seven. Interestingly, the pathognomonic double-line sign was seen in 5 hips out of 10 in the second last MRI scan and it was seen only in three in the last MRI scan before the hips advanced to THA.

Hips not advancing to THA had at three-month follow-up increased BME adjacent to necrotic lesion and in femoral neck, but at one-year follow-up BME on both regions had decreased. Also, initially the presence of BME was less common than in hips advancing to THA. In contrast to hips advancing to THA there were not any subchondral fractures and almost no acetabular BME. At the initial MRI scan, four out of eight hips had effusion, and at one-year follow-up only two of the hips presented effusion. In hips not advancing to THA, the presence of double-line sign also became rarer. Table 4 summarizes the MRI findings in both groups.

ARCO classification was initially more severe and showed clear progression in hips advancing to THA. All ARCO stage III and IV hips and total of three stage II hips eventually underwent THA during the follow-up. In hips not advancing to THA, the ARCO classification was less severe and only one hip progressed from stage I to stage II (Table 5).

Discussion

In this study we show that a cavalcade of typical MRI findings exists on hips where the AVNFH tends to progress. Earlier it has been represented that the band-like pattern is the initial finding of the necrotic lesion¹¹ and later the developing BME in the femoral head and neck is associated with the onset of the symptoms and considered a marker for potential progression of the AVNFH and collapse of the femoral head.¹² Several studies have also found an association between the BME and AVNFH – however, it must be noted that BME is not pathognomonic for AVNFH.^{13–15}

Table 5. ARCO classification of hips advancing and not advancing to THA.

ARCO	Non-THA group (N = 8)			THA group (N = 10)		
	Initial	3 month	12 month (N = 7 ^a)	Initial	3 month	12 month (N = 3 ^b)
Stage I	2	1 ^a	0	2	0	0
Stage II	6	7	7	3	3	1
Stage III	0	0	0	4	4	1
Stage IV	0	0	0	1	3	1

THA: total hip arthroplasty; ARCO: Association Research Circulation Osseous.

^aOne ARCO stage I hip was lost during follow-up for being symptomless and one-year MRI was not done.

^bSeven hips advanced to THA after 3-month follow-up; two stage II, two stage III and three stage IV hips.

Also, lately it was reported that BME adjacent to necrotic lesion indicates a subchondral fracture, which may not be visible on MRI.¹⁶ Our study favors this finding as nearly every hip advancing to THA had initially BME adjacent to necrotic lesion and 7 out of 10 hips also in the femoral neck. In hips not advancing to THA, the presence of BME in femoral neck and adjacent to the AVN lesion was less common. Initially, subchondral fracture was present in five hips and during follow-up two new subchondral fractures became visible. In these five hips and in hips with not visible subchondral fracture before THA, there were nearly always BME but also effusion, synovitis and secondary BME in the acetabulum suggestive of intra-articular pathology.

Similar with BME, majority of patients with AVNFB have shown present with a hip effusion.^{15,17–19} Iida et al.¹² mention that in the presence of BME, 92% of the symptomatic hips also had joint effusion and most of these hips showed progression of the AVNFB. In another study it was demonstrated that BME associates with pain and the effect of BME was enhanced in the presence of effusion; accordingly, the findings were most pronounced in ARCO stage III hips – i.e. in hips with subchondral fractures. In the same study effusion was seen in 72% of hips with AVNFB compared to 10% of healthy controls and effusion was seen most in ARCO stage III disease (92%) and less in lower stages than in more advanced necrotic lesions.¹² In our study joint effusion was strongly associated with hips with more advanced AVNFB lesions as in the group advancing to THA effusion was seen initially in 80% of the hips.

In our study, AVNFB lesions kept slightly increasing in size. Most size increases were very minor, which could be included also in measurement bias. However, most of the statistically significant increases in size were in the group advancing to THA. According to the previous literature, the collapse commonly occurs within two years in 32%–79% of patients having symptomatic AVNFB,²⁰ and untreated asymptomatic AVNFB progresses to symptomatic disease or collapse in

approximately 60% during a maximal 20-year follow-up.²¹ On MRI, it has been demonstrated that the greater size and the weight-bearing location of the AVNFB is a risk factor for further collapse of the femoral head.^{22–24} Our study indicates similar results as hips advancing to THA had greater mean size and volume of the AVNFB compared to cases not advancing to THA. Similarly, the lateral weight-bearing location of the AVNFB seemed to predict future THA. On the contrary, medial location of AVNFB seemed to be a protective factor as none of these hips underwent THA; similar results were recently suggested by Takashima et al.²⁵ Previously, Ito et al.²⁶ demonstrated that large necrotic volume of 30% or more of the femoral head may predict worsening of hip pain and the BME was strongly associated with the volume. In our study, 15% seemed to be the crucial volume of the AVNFB to predict future THA.

Our study has several limitations. First, the sample size in our study is too small and follow-up time rather short to draw solid conclusions. There was not histopathological confirmation of osteonecrosis and diagnoses of avascular necrosis were only dependent on clinical symptoms and specific imaging findings. There was no sub-grouping of hips according to known risk factors of AVNFB. Moreover, an isotropic 3D MRI sequence would have been useful to assess the integrity of the articular surface of the femoral head. Lastly, on one patient the one-year follow-up MRI scan was not done for patient being symptomless.

In conclusion, our study suggests hips advancing to THA have a combination of pathognomonic MRI findings such as BME adjacent to necrotic lesion and in femoral neck but also subchondral fracture, effusion, synovitis, and secondary acetabular edema. Also, the greater size and the lateral location of the AVNFB seem to be predictive factors for THA.


Declaration of Conflicting Interests

The author(s) declared no potential conflicts of interest with respect to the research, authorship, and/or publication of this article.

Funding

The author(s) received no financial support for the research, authorship, and/or publication of this article.

ORCID iD

Mika T Nevalainen  <https://orcid.org/0000-0002-9483-7690>

References

1. Lespasio MJ, Sodhi N, Mont MA. Osteonecrosis of the hip: a primer. *Perm J* 2019;23:18–100.
2. Ikeuchi K, Hasegawa Y, Seki T, et al. Epidemiology of nontraumatic osteonecrosis of the femoral head in Japan. *Mod Rheumatol* 2015;25:278–281.
3. Moya-Angeler J, Gianakos AL, Villa JC, et al. Current concepts on osteonecrosis of the femoral head. *World J Orthop* 2015;6:590–601.
4. Mankin HJ. Nontraumatic necrosis of bone (osteonecrosis). *N Engl J Med* 1992;326:1473–1479.
5. Murphey MD, Foreman KL, Klassen-Fischer MK, et al. From the radiologic pathology archives imaging of osteonecrosis: radiologic-pathologic correlation. *Radiographics* 2014;34:1003–1028.
6. Shah KN, Racine J, Jones LC, et al. Pathophysiology and risk factors for osteonecrosis. *Curr Rev Musculoskelet Med* 2015;8:201–209.
7. Pierce TP, Jauregui JJ, Cherian JJ, et al. Imaging evaluation of patients with osteonecrosis of the femoral head. *Curr Rev Musculoskelet Med* 2015;8:221–227.
8. Yeh LR, Chen CK, Huang YL, et al. Diagnostic performance of MR imaging in the assessment of subchondral fractures in avascular necrosis of the femoral head. *Skelet Radiol* 2009;38:559.
9. Stevens K, Tao C, Lee SU, et al. Subchondral fractures in osteonecrosis of the femoral head: comparison of radiography, CT, and MR imaging. *AJR Am J Roentgenol* 2003;180:363.
10. Yoon BH, Mont MA, Koo KH, et al. The 2019 Revised version of Association Research Circulation Osseous staging system of osteonecrosis of the femoral head. *J Arthroplasty* 2019;19:31101–31105.
11. Fujioka M, Kubo T, Nakamura F, et al. Initial changes of non-traumatic osteonecrosis of femoral head in fat suppression images: bone marrow edema was not found before the appearance of band patterns. *Magn Reson Imaging* 2001;19:985–991.
12. Iida S, Harada Y, Shimizu K, et al. Correlation between bone marrow edema and collapse of the femoral head in steroid-induced osteonecrosis. *AJR Am J Roentgenol* 2000;174:735–743.
13. Koo KH, Ahn IO, Kim R, et al. Bone marrow edema and associated pain in early stage osteonecrosis of the femoral head: prospective study with serial MR images. *Radiology* 1999;213:715–722.
14. Ragab Y, Emad Y, Abou-Zeid A. Bone marrow edema syndromes of the hip: MRI features in different hip disorders. *Clin Rheumatol* 2008;27:475.
15. Huang GS, Chan WP, Chang YC, et al. MR imaging of bone marrow edema and joint effusion in patients with osteonecrosis of the femoral head: relationship to pain. *AJR Am J Roentgenol* 2003;181:545–549.
16. Meier R, Kraus TM, Schaeffeler C, et al. Bone marrow oedema on MR imaging indicates ARCO stage 3 disease in patients with AVN of the femoral head. *Eur Radiol* 2014;24:2271–2278.
17. Mitchell DG, Rao V, Dalinka M, et al. MRI of joint fluid in the normal and ischemic hip. *AJR Am J Roentgenol* 1986;146:1215.
18. Bluemke DA, Zerhouni EA. MRI of avascular necrosis of bone. *Top Magn Reson Imaging* 1996;8:231.
19. Liu B, Yi H, Zhang Z, et al. Association of hip joint effusion volume with early osteonecrosis of the femoral head. *Hip Int: J Clin Exp Res Hip Pathol Ther* 2012;22:179.
20. Banerjee S, Kapadia BH, Jauregui JJ. Natural history of osteonecrosis. In: Koo KH, Mont MA, Jones LC (eds) *Osteonecrosis*. 2nd ed. Heidelberg, Germany: Springer; 2014, pp. 240–273.
21. Mont MA, Zywiol MG, Marker DR, et al. The natural history of untreated asymptomatic osteonecrosis of the femoral head: a systematic literature review. *J Bone Joint Surg Am* 2010;92:2165–2170.
22. Shimizu K, Moriya H, Akita T, et al. Prediction of collapse with magnetic resonance imaging of avascular necrosis of the femoral head. *J Bone Joint Surg Am* 1994;76:215–223.
23. Nishii T, Sugano N, Ohzono K, et al. Significance of lesion size and location in the prediction of collapse of osteonecrosis of the femoral head: a new three-dimensional quantification using magnetic resonance imaging. *J Orthop Res* 2002;20:130–136.
24. Ha YC, Jung WH, Kim JR, et al. Prediction of collapse in femoral head osteonecrosis: a modified Kerboul method with use of magnetic resonance images. *J Bone Joint Surg Am* 2006;88:35–40.
25. Takashima K, Sakai T, Hamada H, et al. Which classification system is most useful for classifying osteonecrosis of the femoral head? *Clin Orthop Relat Res* 2018;476:1240–1249.
26. Ito H, Matsuno T, Minami A. Relationship between bone marrow edema and development of symptoms in patients with osteonecrosis of the femoral head. *AJR Am J Roentgenol* 2006;186:1761–1770.