



# Periodontal surgery using rhFGF-2 with deproteinized bovine bone mineral or rhFGF-2 alone: 2-year follow-up of a randomized controlled trial

Hideto Aoki<sup>1,2</sup> | Takahiro Bizenjima<sup>3</sup> | Fumi Seshima<sup>1</sup> | Masahiro Sato<sup>1</sup> |  
Daisuke Irokawa<sup>1</sup> | Kouki Yoshikawa<sup>1</sup> | Wataru Yoshida<sup>1</sup> | Kentaro Imamura<sup>1,2</sup> |  
Daisuke Matsugami<sup>1,2</sup> | Yurie Kitamura<sup>1</sup> | Daichi Kita<sup>1,2</sup> | Hiroki Sugito<sup>4</sup>  |  
Sachiyo Tomita<sup>1</sup> | Atsushi Saito<sup>1,2</sup> 

<sup>1</sup>Department of Periodontology, Tokyo Dental College, Tokyo, Japan

<sup>2</sup>Oral Health Science Center, Tokyo Dental College, Tokyo, Japan

<sup>3</sup>Tokyo Dental College Chiba Dental Center, Chiba, Japan

<sup>4</sup>Department of Dental Hygiene, Tokyo Dental Junior College, Tokyo, Japan

## Correspondence

Atsushi Saito, Department of Periodontology, Tokyo Dental College, 2-9-18 Kanda-Misakicho, Chiyoda-ku, Tokyo 101-0061, Japan.  
Email: atsaito@tdc.ac.jp

## Funding information

Supported by a grant from the Multidisciplinary Research Center for Jaw Disease (MRCJD), Tokyo Dental College (a MEXT Private University Research Branding Project) and an Osteology Foundation Advanced Researcher Grant (No.17-136).

## Abstract

**Aim:** To compare outcomes of rhFGF-2 + DBBM therapy with rhFGF-2 alone in the treatment of intrabony defects. This study provides 2-year follow-up results from the previous randomized controlled trial.

**Materials and Methods:** Defects were randomly allocated to receive rhFGF-2 + DBBM (test) or rhFGF-2 (control). Treated sites were re-evaluated at 2 years postoperatively, using original clinical and patient-centred measures.

**Results:** Thirty-eight sites were available for re-evaluation. At 2 years, both groups showed a significant improvement in clinical attachment level (CAL) from baseline. A gain in CAL of  $3.4 \pm 1.3$  mm in the test group and  $3.1 \pm 1.5$  mm in the control group was found. No significant inter-group difference was noted. Both groups showed a progressive increase in radiographic bone fill (RBF). The test treatment yielded greater RBF (56%) compared with the control group (41%). The control treatment performed better in contained defects in terms of CAL and RBF. There was no significant difference in patient-reported outcomes between groups.

**Conclusions:** At 2-year follow-up, the test and control treatments were similarly effective in improving CAL, whereas the test treatment achieved a significantly greater RBF. In both treatments, favourable clinical, radiographic, and patient-reported outcomes can be sustained for at least 2 years.

**Trial registration:** The University Hospital Medical Information Network-Clinical Trials Registry (UMIN-CTR) 000025257.

## KEYWORDS

bone graft, deproteinized bovine bone mineral (DBBM), FGF-2, intrabony defects, patient-reported outcome, periodontal regenerative therapy, periodontitis

## 1 | INTRODUCTION

In the treatment of periodontitis, the regeneration of lost tissues is one ultimate goal. Signalling molecules such as growth factors play a critical role in periodontal regeneration (Lin et al., 2015; Murakami, 2011). Recombinant human platelet-derived growth factor (rhPDGF)-BB and enamel matrix derivative (EMD) have been clinically used with various degrees of success (Khoshkam et al., 2015; Li et al., 2017; Lin et al., 2015; Sculean et al., 2015). Among the biological agents, basic fibroblast growth factor (FGF-2) has received particular interests, due to its potent ability to induce proliferation and angiogenesis in undifferentiated cells (Murakami, 2011). Based on the large body of evidence from basic research, extensive clinical trials were conducted in Japan, and the results indicated that the use of recombinant human FGF-2 (rhFGF-2) in surgical periodontal treatment is safe and clinically effective (Kitamura et al., 2008, 2011, 2016; Murakami, 2011). Since 2016, rhFGF-2 has been used as a novel periodontal regenerative therapy in Japan (Saito et al., 2019).

In some cases, such as those with non-contained intrabony defects, the use of biological agents alone may not be sufficient, due to their inability to maintain appropriate space for periodontal regeneration (Iorio-Siciliano et al., 2011; Reynolds et al., 2015). To further expand their clinical applicability, the effectiveness of combination therapy with bone graft materials has been explored (Hoffmann et al., 2016; Iorio-Siciliano et al., 2014; Matarasso et al., 2015; Nevins et al., 2013; Zucchelli et al., 2003). In a systematic review, it has been reported that EMD plus bone grafts may yield enhanced clinical outcomes compared to the use of EMD alone (Matarasso et al., 2015).

Deproteinized bovine bone mineral (DBBM) has been widely used as a scaffold material in periodontal treatment (Camargo et al., 2000; Stavropoulos & Karring, 2010). It is often used with a collagen barrier as a guided tissue regeneration (GTR) method. Studies by our group and others showed clinical effectiveness of the combination GTR (Irokawa, Okubo, et al., 2017; Irokawa, Takeuchi, et al., 2017; Sculean et al., 2008; Stavropoulos & Karring, 2010; Tonetti et al., 2004). However, no information was available how the combined use of rhFGF-2 with DBBM performs in periodontal healing. We hypothesized that enhanced regenerative outcome would be achieved by such combination therapy. Therefore, we set out to conduct a randomized controlled trial (RCT) comparing the use of rhFGF-2 plus DBBM and rhFGF-2 alone to treat intrabony defects (Saito et al., 2019). In this earlier RCT, we reported that both treatments yielded significant improvements in periodontal parameters at 6 months. Although no significant difference in clinical attachment level (CAL) gain between groups was noted, the combination therapy showed a greater bone fill. Given these results from the short-term study, we thought it important to evaluate the longevity of effects of the combination therapy.

The objective of this follow-up study was to evaluate 2-year outcomes of the combination therapy using rhFGF-2 and DBBM in comparison with rhFGF-2 alone in the treatment of intrabony defects.

### Clinical Relevance

*Scientific rationale for the study:* It is important to evaluate the longevity of effects of combination periodontal regenerative therapy. This follow-up study aimed to evaluate 2-year outcomes of the combination therapy using rhFGF-2 with DBBM in the treatment of intrabony periodontal defects.

*Principal findings:* At 2-year follow-up, no significant difference in clinical attachment level gains was noted between the use of rhFGF-2 alone and rhFGF-2 + DBBM. At any time point, the combination therapy showed enhanced radiographic bone fill. There was no significant difference in scores on oral health-related quality of life between groups.

*Practical implications:* With both surgical interventions, favourable clinical and patient-reported outcomes can be sustained for at least 2 years.

## 2 | MATERIALS AND METHODS

### 2.1 | Study design

A 2-year follow-up was undertaken in an RCT (Saito et al., 2019) conducted at Tokyo Dental College Suidobashi Hospital (Tokyo, Japan) and Chiba Dental Center (Chiba, Japan), which had involved evaluation of healing at up to 6 months postoperatively. In the original study, a two-centre, single-blind, randomized, controlled design was used. The study was conducted in accordance with the Declaration of Helsinki and approved by the institutional review board at Tokyo Dental College (No. 747).

### 2.2 | Participants

In the previous RCT (Saito et al., 2019), 32 patients with moderate to severe chronic periodontitis (Armitage, 1999; Page & Eke, 2007) were included (recruited between January 2017 and February 2018). A total of 44 intrabony defects were randomized into two groups (Figure S1 flowchart).

The initial inclusion criteria were as follows: presence of an intrabony defect depth of  $\geq 3$  mm in inter-proximal areas of teeth, sites with probing pocket depth (PPD)  $\geq 4$  mm, and an adequate level of plaque control. Detailed information on the inclusion and exclusion criteria, initial sample size estimation, randomization, allocation concealment, and blinding can be found in the previously published paper (Saito et al., 2019).

### 2.3 | Clinical and radiographic examinations

CAL, PPD, gingival recession (GR), bleeding on probing (BOP), and tooth mobility (TM) were evaluated at baseline (post-initial

periodontal therapy; IP), 6 months (Saito et al., 2019), 1 year, and 2 years postoperatively by calibrated examiners.

Standardized periapical radiographs were taken, and radiographic bone fill (RBF; %) was calculated as described previously (Seshima et al., 2017).

## 2.4 | Patient-reported outcome measure

At each evaluation time point, participants were asked to rate the perception of oral health, using an oral health-related quality of life (QoL) instrument, OHRQL-J (Saito et al., 2010, 2011). In this study, total OHRQL-J score from the 22 items was used for analysis.

## 2.5 | Surgical procedures

Details for surgical intervention have been provided in the previous paper (Saito et al., 2019). Briefly, full-thickness flaps were raised following infiltration anaesthesia. After debridement, scaling and root planing, and rinsing, the test sites received 0.3% rhFGF-2 (REGROTH® Dental Kit, Kaken Pharmaceutical) with DBBM (Geistlich Bio-Oss®, Geistlich Pharma AG). Defects in the control group received only rhFGF-2 formulation. The flaps were closed with interrupted sutures and modified vertical mattress sutures.

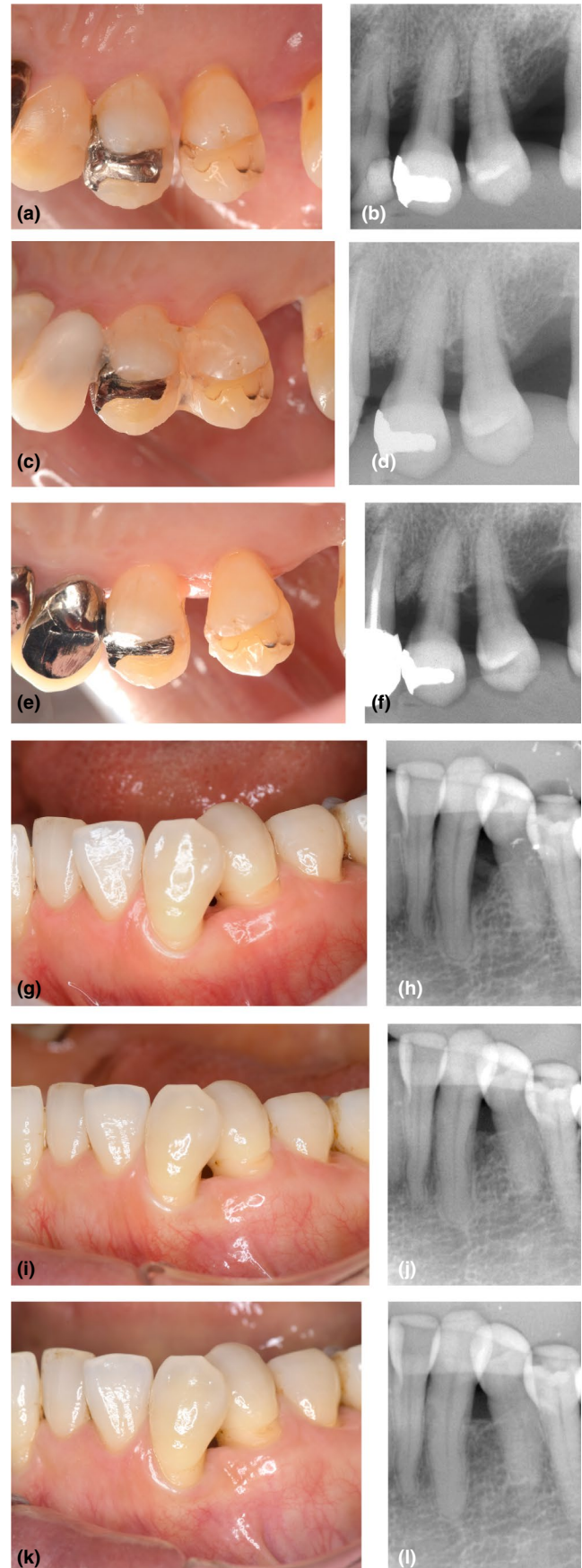Detailed information on postsurgical and maintenance care can be found elsewhere (Saito et al., 2019).

Representative clinical cases are shown in Figure 1.

## 2.6 | Statistical analysis

Clinical data from the two centres were pooled for analysis. The primary endpoint was the CAL gain at 2 years postoperatively. Fisher's exact test was employed to analyse categorical variables. Difference between two groups was sought by the Mann-Whitney *U* test. The Friedman test with Dunn post hoc test was used to compare intra-group data over time.

Correlations between CAL gains and baseline parameters were assessed by Spearman's rank correlation. Multiple regression analysis was used to evaluate the relationship of PPD, BOP, defect depth,



**FIGURE 1** Clinical cases. (a–f) 60-year-old woman; received rhFGF-2 + DBBM (test group). (a) Baseline (palatal). The mesial aspect of #24 showed PPD of 7 mm. (b) Preoperative radiograph. Defect depth was 3 mm, width 5 mm (confirmed during surgery). (c) 1-year follow-up view. (d) 1-year radiograph. (e) 2-year follow-up view; PPD = 2 mm. (f) 2-year radiograph. (g–l) 53-year-old woman; received rhFGF-2 (control group). (g) Baseline. PPD at the distal aspect of #33 was 7 mm. (h) Preoperative radiograph. Defect depth was 5 mm, width 3 mm (confirmed during surgery). (i) 1-year follow-up view. (j) 1-year radiograph. (k) 2-year follow-up. PPD = 2 mm. (l) 2-year radiograph

TABLE 1 Defect locations and configurations

Intrabony defect	rhFGF-2 (control, n = 18)	rhFGF-2 + DBBM (test, n = 20)
Position [n (%)]		
Maxilla	6 (33.3)	9 (45.0)
Mandible	12 (66.7)	11 (55.0)
Anterior teeth	5 (27.8)	2 (10.0)
Premolars	4 (22.2)	5 (25.0)
Molars	9 (50.0)	13 (65.0)
Morphology [n (%)]		
1-wall	3 (16.7)	2 (10.0)
2-wall	4 (22.2)	5 (25.0)
3-wall	6 (33.3)	5 (25.0)
Combination	5 (27.8)	8 (40.0)
Depth (mm; mean ± SD)	4.81 ± 1.86 (range, 3.0–11.0)	4.70 ± 1.08 (range, 3.0–6.5)
Width (mm; mean ± SD)	2.89 ± 0.78 (range, 2.0–5.0)	3.83 ± 1.83* (range, 2.0–10.0)

Note: Mann–Whitney *U* test, two-tailed.

\**p* = 0.0403.

and defect width at baseline with CAL gain from baseline to 2 years postoperatively (dependent variable). Statistical software packages (InStat 3.10 and Prism 7.05, GraphPad Software) were used. A *p* value of 0.05 was considered statistically significant.

### 3 | RESULTS

#### 3.1 | Participants and clinical parameters

In the base study (Saito et al., 2019), 32 patients participated and contributed 44 sites. The progress made during the study is shown in Figure S1. At 2-year follow-up, a total of 38 sites [20 belonging to the test group (rhFGF-2+DBBM) and 18 to the control group (rhFGF-2 alone)] in 30 patients were re-evaluated. Accidental death, serious injury, and no shows accounted for the missing scores.

The participant demographics and baseline full-mouth clinical parameters can be found in the previous paper (Saito et al., 2019).

#### 3.2 | Clinical outcomes

Postoperative healing occurred without significant problems. Characteristics of intrabony defects are shown in Table 1. Between groups, there were no significant differences in maxillary and mandibular defects, tooth type, defect configuration, or defect depth. The test group had significantly wider defects than the control group.

At 1 and 2 years postoperatively, significant improvements in CAL and PPD were found in both groups (Table 2). In both treatment groups, the level of improvement found at 6 months has been sustained over a 2-year period (Figure 2a). At 2 years, the test group showed a mean CAL gain of  $3.35 \pm 1.28$  mm, while the control group

showed a gain of  $3.11 \pm 1.46$  mm. No significant difference was noted between groups at any time point.

At 2 years, 25.0% of sites (*n* = 5) in the test group achieved CAL gains of >4 mm from baseline, while 33.3% (*n* = 6) in the control group showed such value (Table S1).

The values of PPD reductions from baseline were  $3.58 \pm 1.21$  mm in the test group and  $3.58 \pm 1.53$  mm in the control group; no significant inter-group difference was noted.

Regarding GR and TM, no significant intra- or intergroup differences were found (Table 2). In both groups, the values of BOP positive (%) were significantly reduced at 6 months and thereafter, when compared to baseline, while no significant difference between groups was found at any time point.

#### 3.3 | Relationship between CAL gain and variables at baseline

Next, relationships between 2-year CAL gains and baseline data were sought. Postoperative CAL gain and baseline CAL or PPD showed a significant positive correlation in both groups (Table S2). A significant positive correlation was found between CAL gain and baseline defect depth in the test group.

The results of multiple regression analyses are shown in Tables S3 and S4. There was no multicollinearity among the variables. In the control group, the baseline PPD showed a significant relationship with the postoperative CAL gain at 2 years (Table S3). In the test group, the defect depth at baseline showed a significant association with the postoperative CAL gain (Table S4).

#### 3.4 | Radiographic evaluation

In both groups, there was a progressive increase in RBF (Table 2, Figure 2b). At 2 years postoperatively, the mean value for RBF in the test group (56.2%) was significantly greater compared to the control group (40.8%).

#### 3.5 | Comparison of CAL gains and radiographic outcomes between different defect configurations

In the control group, 3-wall defects yielded significantly greater CAL gains and RBF than 1-2 wall defects (Table 3). In contrast, no significant difference in those values between different defect configurations was found in the test group. In 1-2-wall defects, the test group showed greater RBF than the control group.

#### 3.6 | Changes in scores on OHRQL-J

No significant change in the mean total OHRQL-J scores over time was found in either group (Figure 3). There was no significant inter-group difference at any time point.

TABLE 2 Clinical and radiographic outcomes of treated sites (Total  $n = 38$  sites)

Variable/Group	Baseline (post-IP)	6 months	1 year	2 years
<b>CAL (mm)</b>				
rhFGF-2 (control)	7.19 ± 1.66 (6.5; 6.00–8.25)	4.42 ± 1.43 <sup>***</sup> (4; 3.38–5.25)	4.14 ± 1.50 <sup>***</sup> (4; 2.88–5.50)	4.08 ± 1.33 <sup>***</sup> (4; 2.88–5.00)
rhFGF-2 + DBBM (test)	7.67 ± 1.68 (7; 6.25–8.88)	4.53 ± 1.42 <sup>***</sup> (4; 4.00–5.50)	4.50 ± 1.28 <sup>***</sup> (4.5; 4.00–5.00)	4.28 ± 1.30 <sup>***</sup> (4; 3.50–5.00)
Diff. between groups	N.S.	N.S.	N.S.	N.S.
<b>PPD (mm)</b>				
rhFGF-2	6.19 ± 1.41 (5; 5.00–7.00)	2.83 ± 0.87 <sup>***</sup> (3; 2.00–3.00)	2.67 ± 0.84 <sup>***</sup> (3; 2.00–3.00)	2.61 ± 0.87 <sup>***</sup> (2; 2.00–3.25)
rhFGF-2 + DBBM	6.30 ± 1.30 (6.5; 5.00–7.00)	2.80 ± 0.73 <sup>***</sup> (3; 2.00–3.38)	2.83 ± 0.54 <sup>***</sup> (3; 2.25–3.00)	2.73 ± 0.55 <sup>***</sup> (3; 2.00–3.00)
Diff. between groups	N.S.	N.S.	N.S.	N.S.
<b>GR (mm)</b>				
rhFGF-2	0.94 ± 1.16 (1; 0.00–1.25)	1.36 ± 1.46 (1; 0.00–2.00)	1.47 ± 1.22 (1.5; 0.38–2.00)	1.47 ± 1.30 (1.25; 0.38–2.00)
rhFGF-2 + DBBM	1.33 ± 1.42 (1; 0.00–2.75)	1.73 ± 1.36 (1.75; 1.00–2.00)	1.63 ± 1.21 (1.75; 1.00–2.00)	1.48 ± 1.21 (1.75; 0.50–2.00)
Diff. between groups	N.S.	N.S.	N.S.	N.S.
<b>BOP positive (%)</b>				
rhFGF-2	66.7	11.1 <sup>***</sup>	5.6 <sup>***</sup>	0.0 <sup>***</sup>
rhFGF-2 + DBBM	75.0	5.0 <sup>***</sup>	0.0 <sup>***</sup>	0.0 <sup>***</sup>
Diff. between groups <sup>a</sup>	N.S.	N.S.	N.S.	N.S.
<b>TM</b>				
rhFGF-2	0.11 ± 0.32 (0; 0.00–0.00)	0.06 ± 0.24 (0; 0.00–0.00)	0.06 ± 0.24 (0; 0.00–0.00)	0.11 ± 0.32 (0; 0.00–0.00)
rhFGF-2 + DBBM	0.20 ± 0.41 (0; 0.00–0.00)	0.05 ± 0.22 (0; 0.00–0.00)	0.05 ± 0.22 (0; 0.00–0.00)	0.05 ± 0.22 (0; 0.00–0.00)
Diff. between groups	N.S.	N.S.	N.S.	N.S.
<b>RBF (%)</b>				
rhFGF-2	–	31.2 ± 13.3 (30; 20.6–40.4)	36.7 ± 15.2 (34.9; 25.8–50.0)	40.8 ± 17.2 <sup>a</sup> (38.2; 27.2–54.7)
rhFGF-2 + DBBM	–	47.7 ± 16.8 (47.2; 36.4–63.3)	54.6 ± 17.7 (62.6; 41.1–68.3)	56.2 ± 18.0 <sup>†</sup> (62.6; 45.8–69.2)
Diff. between groups		<b><math>p = 0.004</math></b>	<b><math>p = 0.003</math></b>	<b><math>p = 0.013</math></b>

Note: Data shown as mean ± standard deviation (median; interquartile range), except for BOP. Difference between groups at each time point was assessed by Mann–Whitney  $U$  test. Intra-group difference over time was assessed by Friedman test with Dunn post-test.

Abbreviations: BOP, bleeding on probing; CAL, clinical attachment level; GR, gingival recession; IP, initial periodontal therapy; PPD, probing pocket depth; RBF, radiographic bone fill; TM, tooth mobility.

<sup>a</sup>Categorical data were assessed by Fisher's exact test.

<sup>\*\*\*</sup> $p < 0.001$ , compared to baseline; <sup>†</sup> $p < 0.05$ , <sup>††</sup> $p < 0.01$ , compared to 6 M.

## 4 | DISCUSSION

Most RCTs are relatively short term and, due to various reasons, they are seldom re-visited or extended (Davies et al., 2018). Obviously, there is no guarantee that treatment effects remain unchanged beyond the initial study. In the present study, we evaluated 2-year follow-up outcomes from our previous 6-month RCT (Saito et al., 2019). At 2 years postoperatively, the mean values of CAL gain, the primary endpoint, were 3.4 and 3.1 mm in the

test and control groups, respectively. These values were comparable to the 2-year value of 3.3 mm from our previous study using EMD alone, with similar baseline CAL measurements (Seshima et al., 2017). As for the CAL gain following the use of rhFGF-2, the 9-month value of 2.2 mm was reported in a multicentre RCT using rhFGF-2 alone (Kitamura et al., 2016) and 6-month value of 3.0 mm in another RCT using rhFGF-2 with beta-tricalcium phosphate ( $\beta$ -TCP; Cochran et al., 2016). The finding that no significant difference existed between groups is in line with the controlled studies using EMD alone or in combination with alloplastic materials

(Bokan et al., 2006; Jepsen et al., 2008; Sculean et al., 2007). Our 2-year results can be interpreted that both modalities were similarly effective in the treatment of intrabony defects existed in the participants. This is remarkable considering the viscous nature of the rhFGF-2 formulation, which does not particularly have space-making property.

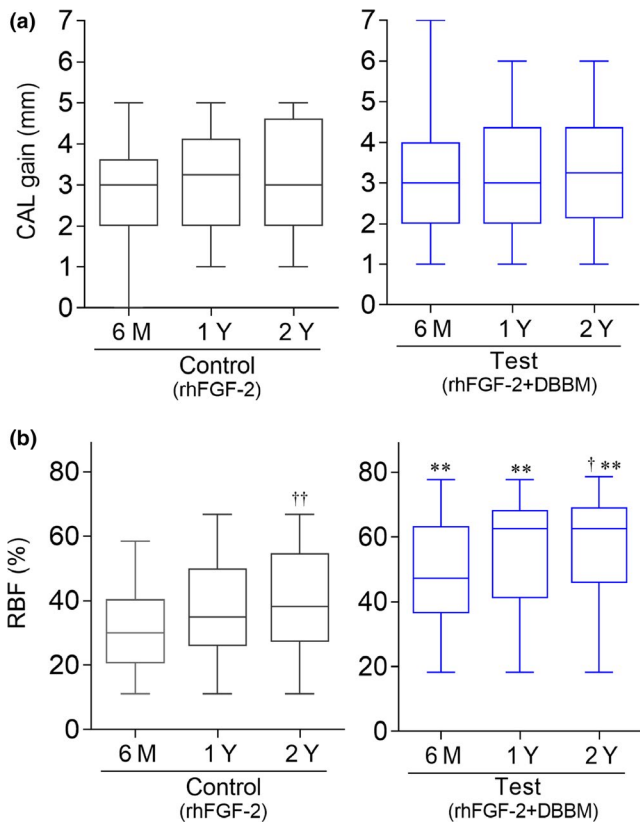
In the present study, CAL gains were significantly associated with baseline PPD in the control group (correlation and multiple regression analyses) and in the test group (correlation analysis). This was expected because studies have shown that generally, more CAL gain can be expected following the regenerative treatment of

deeper pockets (Seshima et al., 2017; Tonetti et al., 2002; Zucchelli et al., 2002). These findings indicate that caution must be taken when comparing postoperative CAL values from different studies.

Recently, Trombelli et al. (2020) proposed a novel composite outcome measure (COM) for periodontal regenerative therapy. COM is consisted of clinically relevant CAL gain of  $\geq 3$  mm and postoperative PD  $\leq 4$  mm (pocket closure). In the present study, both treatment groups showed a CAL gain of  $\geq 3$  mm and PD of  $< 3$  mm at 2 years, which can be regarded as "successful," according to COM. One should keep in mind that, at baseline, the test group had significantly wider defects (3.8 mm) than the control group (2.9 mm). Although the linear correlation and multiple regression analyses showed no significant association between CAL gain at 2 years and defect width at baseline, the difference in baseline defect width may partially account for no significant inter-group difference in CAL gain.

Bone level is another important outcome measure for periodontal regenerative therapy. Cochran et al. (2016) stated that combining outcome measures for soft and hard tissues is preferable to assess the clinical performance of a biological agent with effects on both tissue types. At 2 years postoperatively, the mean value of RBF was significantly greater in the test group (56%) compared with the control group (41%). It can be argued that the test sites should show a greater RBF value, because radiopaque material was used with rhFGF-2 to fill the defect. It is, however, important to note that RBF values in the test sites also showed a progressive increase, which suggests bone formation.

It has been reported that clinical results of the treatment of intrabony defects may be difficult to predict based on their characteristics (Renvert, Garrett, et al., 1985). In our analysis, the defect depth at baseline was positively correlated with the CAL gains at 2 years in the test group. In the multiple regression analysis, the defect depth could predict the level of CAL gain at 2-year follow-up. When values of CAL gain and RBF at 2-year follow-up were compared between different defect configurations at baseline, the treatment with rhFGF-2 yielded significantly greater CAL gains and RBF in 3-wall defects than 1- to 2-wall defects. This was expected because 3-wall defects provide favourable environment for blood clot formation and cell migration from the remaining periodontal tissues (Polson & Heul, 1978; Renvert, Nilvéus, et al., 1985). It has been suggested that the extent and location of tissue resources, cells, and vascularity surrounding the defect have an effect on the

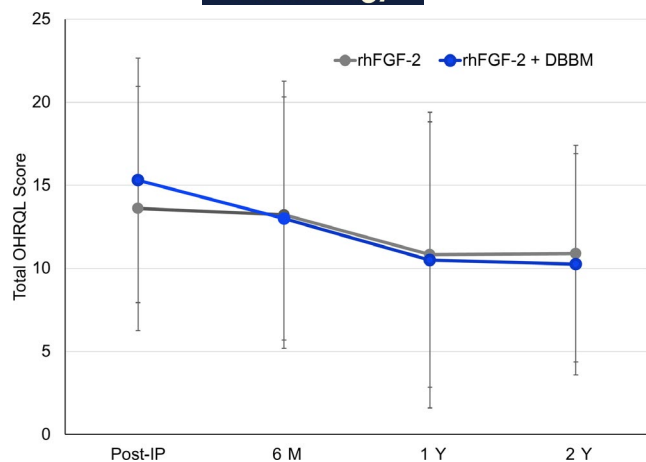


**FIGURE 2** Clinical attachment level (CAL) gain (a) and radiographic bone fill (RBF) (b). Box-and-whiskers plot showing minimum, maximum, median, and 25th and 75th percentiles. \*\* $p < 0.01$ , compared to control group; Mann-Whitney  $U$  test. † $p < 0.05$ , †† $p < 0.01$ , compared to 6 M; Friedman test with Dunn post-test

**TABLE 3** Comparison of clinical attachment level (CAL) gain and radiographic bone fill (RBF) at 2 years postoperatively between different defect configurations

	Defect	rhFGF-2 (control)	Difference	rhFGF-2 + DBBM (test)	Difference
CAL gain (mm)	3-wall	3.64 $\pm$ 1.21 (3.50; 2.50 - 5.00)	$p = 0.037$	3.50 $\pm$ 1.24 (3.25; 2.50 - 4.38)	N.S.
	1-2-wall	2.29 $\pm$ 1.52 (2.00; 1.00 - 3.50)		3.13 $\pm$ 1.38 (3.25; 2.00 - 4.38)	
RBF (%)	3-wall	52.1 $\pm$ 8.1 (50.0; 47.5 - 60.6)	$p = 0.034$	51.3 $\pm$ 21.4 (50.0; 30.7 - 72.5)	N.S.
	1-2-wall	34.3 $\pm$ 18.1 (28.7; 22.7 - 48.0)		57.8 $\pm$ 17.3* (63.6; 50.0 - 66.7)	

Note: Data shown as mean  $\pm$  standard deviation (median; interquartile range). Difference between different defect configurations within group or difference between groups within the same defect configuration was assessed by Mann-Whitney  $U$  test (\* $p = 0.036$ , compared to the control group).



**FIGURE 3** Change in total OHRQL-J scores. Data shown as mean  $\pm$  standard deviation. IP, initial periodontal therapy

regenerative potential (Kim et al., 2004). In case of non-contained defects, regenerative therapy in combination with bone substitutes is indicated (Cortellini & Tonetti, 2000). When the use of EMD with DBBM was compared to collagen barrier with DBBM in an RCT of the treatment of deep non-contained intrabony defects, comparable clinical outcomes were noted after 12 months (Iorio-Siciliano et al., 2014). In the present study, the test treatment showed similar CAL gains in 1- to 2-wall and 3-wall defects at 2 years. In contrast, the control treatment yielded significantly greater CAL gains and RBF in 3-wall defects. Within 1-2-wall defects, the test treatment yielded significantly greater RBF compared to the control. These results may indicate that: (1) in the treatment of 3-wall defects, the sole use of rhFGF-2 may be sufficient; (2) a greater level of healing can be expected by adding DBBM in more challenging cases such as deeper defects or 1- to 2-wall defects. In some studies, no additional benefits in clinical outcomes were found regarding the use of EMD with bone substitutes (Hoffmann et al., 2016; Kao et al., 2015; Troiano et al., 2017). Potential benefits of adding various bone substitutes to rhFGF-2 therapy and indications need to be verified by further studies.

There are limitations to this study. Due to the study design and relatively small sample size, this study was underpowered to assess the effect of the number of residual bony walls in detail. Two-year follow-up is still a relatively short-term observation. A longer observation period will be necessary. Moreover, regarding the regenerative capability of rhFGF-2, further studies evaluating human histologic evidence are needed. Despite the limitations, we believe that this follow-up study provides relevant implications for the use of rhFGF-2 therapy.

## 5 | CONCLUSIONS

In the treatment of intrabony defects, no significant difference in CAL gains was found between the use of rhFGF-2 alone and rhFGF-2

with DBBM at 2-year follow-up. The combination therapy achieved a significantly greater RBF. In both treatment groups, favourable clinical and patient-centred outcomes can be sustained for at least 2 years.

## ACKNOWLEDGEMENTS

The authors thank Eiichi Suzuki, DDS, PhD, Takahiro Takeuchi, DDS, PhD, Asako Makino-Oi, DDS, PhD, Katsuya Noda, DDS, PhD, and Haruka Koga, DDS for clinical treatment. The authors are also grateful to Risa Kobayashi, RDH and the dental hygienists at Tokyo Dental College Suidobashi Hospital, for their patient care.

## CONFLICT OF INTEREST

There are no conflicts of interest regarding this article.

## ORCID

Hiroki Sugito  <https://orcid.org/0000-0001-9405-4197>

Atsushi Saito  <https://orcid.org/0000-0002-0065-2207>

## REFERENCES

- Armitage, G. C. (1999). Development of a classification system for periodontal diseases and conditions. *Annals of Periodontology*, 4, 1–6. <https://doi.org/10.1902/annals.1999.4.1.1>
- Bokan, I., Bill, J. S., & Schlagenhauf, U. (2006). Primary flap closure combined with Emdogain® alone or Emdogain® and Cerasorb® in the treatment of intra-bony defects. *Journal of Clinical Periodontology*, 33, 885–893. <https://doi.org/10.1111/j.1600-051X.2006.01010.x>
- Camargo, P. M., Lekovic, V., Weinlaender, M., Nedic, M., Vasilic, N., Wolinsky, L. E., & Kenney, E. B. (2000). A controlled re-entry study on the effectiveness of bovine porous bone mineral used in combination with a collagen membrane of porcine origin in the treatment of intrabony defects in humans. *Journal of Clinical Periodontology*, 27, 889–896. <https://doi.org/10.1034/j.1600-051x.2000.027012889.x>
- Cochran, D. L., Oh, T.-J., Mills, M. P., Clem, D. S., McClain, P. K., Schallhorn, R. A., McGuire, M. K., Scheyer, E. T., Giannobile, W. V., Reddy, M. S., Abou-Arrej, R. V., Vassilopoulos, P. J., Genco, R. J., Geurs, N. C., & Takemura, A. (2016). A randomized clinical trial evaluating rhFGF-2/ $\beta$ -TCP in periodontal defects. *Journal of Dental Research*, 95, 523–530. <https://doi.org/10.1177/0022034516632497>
- Cortellini, P., & Tonetti, M. S. (2000). Focus on intrabony defects: guided tissue regeneration. *Periodontology* 2000, 22, 104–132. <https://doi.org/10.1034/j.1600-0757.2000.2220108.x>
- Davies, G., Jordan, S., Brooks, C. J., Thayer, D., Storey, M., Morgan, G., Allen, S., Garaiova, I., Plummer, S., & Gravenor, M. (2018). Long term extension of a randomised controlled trial of probiotics using electronic health records. *Scientific Reports*, 8, 7668. <https://doi.org/10.1038/s41598-018-25954-z>
- Hoffmann, T., Al-Machot, E., Meyle, J., Jervøe-Storm, P. M., & Jepsen, S. (2016). Three-year results following regenerative periodontal surgery of advanced intrabony defects with enamel matrix derivative alone or combined with a synthetic bone graft. *Clinical Oral Investigations*, 20, 357–364. <https://doi.org/10.1007/s00784-015-1522-4>
- Iorio-Siciliano, V. I., Andreuccetti, G., Blasi, A., Matarasso, M., Sculean, A., & Salvi, G. E. (2014). Clinical outcomes following regenerative therapy of non-contained intrabony defects using a deproteinized bovine bone mineral combined with either enamel matrix derivative or collagen membrane. *Journal of Periodontology*, 85, 1342–1350. <https://doi.org/10.1902/jop.2014.130420>

- Iorio-Siciliano, V. I., Andreuccetti, G., Iorio-Siciliano, A., Blasi, A., Sculean, A., & Salvi, G. E. (2011). Clinical outcomes after treatment of non-contained intrabony defects with enamel matrix derivative or guided tissue regeneration: A 12-month randomized controlled clinical trial. *Journal of Periodontology*, *82*, 62–71. <https://doi.org/10.1902/jop.2010.100144>
- Irokawa, D., Okubo, N., Nikaido, M., Shimizu, H., Konobu, N., Matsui, T., Fujita, T., Goto, H., Takeuchi, T., Ishii, Y., & Saito, A. (2017). Periodontal regenerative therapy of intrabony defects using deproteinized bovine bone mineral in combination with collagen barrier membrane: A multicenter prospective case-series study. *International Journal of Periodontics & Restorative Dentistry*, *37*, 393–401. <https://doi.org/10.11607/prd.2888>
- Irokawa, D., Takeuchi, T., Noda, K., Goto, H., Egawa, M., Tomita, S., Sugito, H., Nikaido, M., & Saito, A. (2017). Clinical outcome of periodontal regenerative therapy using collagen membrane and deproteinized bovine bone mineral: a 2.5-year follow-up study. *BMC Research Notes*, *10*, 102. <https://doi.org/10.1186/s13104-017-2426-y>
- Jepsen, S., Topoll, H., Rengers, H., Heinz, B., Teich, M., Hoffmann, T., Al-Machot, E., Meyle, J., & Jervøe-Storm, P.-M. (2008). Clinical outcomes after treatment of intra-bony defects with an EMD/synthetic bone graft or EMD alone: A multicentre randomized-controlled clinical trial. *Journal of Clinical Periodontology*, *35*, 420–428. <https://doi.org/10.1111/j.1600-051X.2008.01217.x>
- Kao, R. T., Nares, S., & Reynolds, M. A. (2015). Periodontal regeneration – Intrabony defects: a systematic review from the AAP Regeneration Workshop. *Journal of Periodontology*, *86*(2 Suppl), S77–S104. <https://doi.org/10.1902/jop.2015.130685>
- Khoshkam, V., Chan, H. L., Lin, G. H., Mailoa, J., Giannobile, W. V., Wang, H. L., & Oh, T. J. (2015). Outcomes of regenerative treatment with rh PDGF-BB and rh FGF-2 for periodontal intra-bony defects: a systematic review and meta-analysis. *Journal of Clinical Periodontology*, *42*, 272–280. <https://doi.org/10.1111/jcpe.12354>
- Kim, C. S., Choi, S. H., Chai, J. K., Cho, K. S., Moon, I. S., Wikesjö, U. M., & Kim, C. K. (2004). Periodontal repair in surgically created intrabony defects in dogs: influence of the number of bone walls on healing response. *Journal of Periodontology*, *75*, 229–235. <https://doi.org/10.1902/jop.2004.75.2.229>
- Kitamura, M., Akamatsu, M., Kawanami, M., Furuichi, Y., Fujii, T., Mori, M., Kunimatsu, K., Shimauchi, H., Ogata, Y., Yamamoto, M., Nakagawa, T., Sato, S., Ito, K., Ogasawara, T., Izumi, Y., Gomi, K., Yamazaki, K., Yoshie, H., Fukuda, M., ... Murakami, S. (2016). Randomized placebo-controlled and controlled non-inferiority Phase III trials comparing trafermin, a recombinant human fibroblast growth factor 2, and enamel matrix derivative in periodontal regeneration in intrabony defects. *Journal of Bone and Mineral Research*, *31*, 806–814. <https://doi.org/10.1002/jbmr.2738>
- Kitamura, M., Akamatsu, M., Machigashira, M., Hara, Y., Sakagami, R., Hirofujii, T., Hamachi, T., Maeda, K., Yokota, M., Kido, J., Nagata, T., Kurihara, H., Takashiba, S., Sibutani, T., Fukuda, M., Noguchi, T., Yamazaki, K., Yoshie, H., Ioroi, K., ... Murakami, S. (2011). FGF-2 stimulates periodontal regeneration: results of a multi-center randomized clinical trial. *Journal of Dental Research*, *90*, 35–40. <https://doi.org/10.1177/0022034510384616>
- Kitamura, M., Nakashima, K., Kowashi, Y., Fujii, T., Shimauchi, H., Sasano, T., Furuuchi, T., Fukuda, M., Noguchi, T., Shibutani, T., Iwayama, Y., Takashiba, S., Kurihara, H., Ninomiya, M., Kido, J., Nagata, T., Hamachi, T., Maeda, K., Hara, Y., ... Murakami, S. (2008). Periodontal tissue regeneration using fibroblast growth factor-2: Randomized controlled phase II clinical trial. *PLoS One*, *3*, e2611. <https://doi.org/10.1371/journal.pone.0002611>
- Li, F., Yu, F., Xu, X., Li, C., Huang, D., Zhou, X., Ye, L., & Zheng, L. (2017). Evaluation of recombinant human FGF-2 and PDGF-BB in periodontal regeneration: A systematic review and meta-analysis. *Scientific Reports*, *7*, 1–10. <https://doi.org/10.1038/s41598-017-00113-y>
- Lin, Z., Rios, H. F., & Cochran, D. L. (2015). Emerging regenerative approaches for periodontal reconstruction: A systematic review from the AAP Regeneration Workshop. *Journal of Periodontology*, *86*(2 Suppl), S134–S152. <https://doi.org/10.1902/jop.2015.130689>
- Matarasso, M., Iorio-Siciliano, V., Blasi, A., Ramaglia, L., Salvi, G. E., & Sculean, A. (2015). Enamel matrix derivative and bone grafts for periodontal regeneration of intrabony defects. A systematic review and meta-analysis. *Clinical Oral Investigations*, *19*, 1581–1593. <https://doi.org/10.1007/s00784-015-1491-7>
- Murakami, S. (2011). Periodontal tissue regeneration by signaling molecule (s): What role does basic fibroblast growth factor (FGF-2) have in periodontal therapy? *Periodontology 2000*, *56*, 188–208. <https://doi.org/10.1111/j.1600-0757.2010.00365.x>
- Nevins, M., Kao, R. T., McGuire, M. K., McClain, P. K., Hinrichs, J. E., McAllister, B. S., Reddy, M. S., Nevins, M. L., Genco, R. J., Lynch, S. E., & Giannobile, W. V. (2013). Platelet-derived growth factor promotes periodontal regeneration in localized osseous defects: 36-month extension results from a randomized, controlled, double-masked clinical trial. *Journal of Periodontology*, *84*, 456–464. <https://doi.org/10.1902/jop.2012.120141>
- Page, R. C., & Eke, P. I. (2007). Case definitions for use in population-based surveillance of periodontitis. *Journal of Periodontology*, *78*, 1387–1399. <https://doi.org/10.1902/jop.2007.060264>
- Polson, A. M., & Heul, L. C. (1978). Osseous repair in infrabony periodontal defects. *Journal of Clinical Periodontology*, *5*, 13–23. <https://doi.org/10.1111/j.1600-051X.1978.tb01902.x>
- Renvert, S., Garrett, S., Nilvéus, R., Chamberlain, A. D. H., & Egelberg, J. (1985). Healing after treatment of periodontal intraosseous defects: VI. Factors influencing the healing response. *Journal of Clinical Periodontology*, *12*, 707–715. <https://doi.org/10.1111/j.1600-051X.1985.tb01396.x>
- Renvert, S., Nilvéus, R., & Egelberg, J. (1985). Healing after treatment of periodontal intraosseous defects: V. Effect of root planing versus flap surgery. *Journal of Clinical Periodontology*, *12*, 619–629. <https://doi.org/10.1111/j.1600-051X.1985.tb00933.x>
- Reynolds, M. A., Kao, R. T., Nares, S., Camargo, P. M., Caton, J. G., Clem, D. S., Fiorellini, J. P., Geisinger, M. L., Mills, M. P., Nevins, M. L., & Rosen, P. S. (2015). Periodontal regeneration – Intrabony defects: practical applications from the AAP regeneration workshop. *Clinical Advances in Periodontics*, *5*, 21–29. <https://doi.org/10.1902/cap.2015.140062>
- Saito, A., Bizenjima, T., Takeuchi, T., Suzuki, E., Sato, M., Yoshikawa, K., Kitamura, Y., Matsugami, D., Aoki, H., Kita, D., Imamura, K., Irokawa, D., Seshima, F. & Tomita, S. (2019). Treatment of intrabony periodontal defects using rhFGF-2 in combination with deproteinized bovine bone mineral or rh FGF-2 alone: A 6-month randomized controlled trial. *Journal of Clinical Periodontology*, *46*, 332–341. <https://doi.org/10.1111/jcpe.13086>
- Saito, A., Hosaka, Y., Kikuchi, M., Akamatsu, M., Fukaya, C., Matsumoto, S., Ueshima, F., Hayakawa, H., Fujinami, K., & Nakagawa, T. (2010). Effect of initial periodontal therapy on oral health-related quality of life in patients with periodontitis in Japan. *Journal of Periodontology*, *81*, 1001–1009. <https://doi.org/10.1902/jop.2010.090663>
- Saito, A., Ota, K., Hosaka, Y., Akamatsu, M., Hayakawa, H., Fukaya, C., Ida, A., Fujinami, K., Sugito, H., & Nakagawa, T. (2011). Potential impact of surgical periodontal therapy on oral health-related quality of life in patients with periodontitis: a pilot study. *Journal of Clinical Periodontology*, *38*, 1115–1121. <https://doi.org/10.1111/j.1600-051X.2011.01796.x>
- Sculean, A., Nikolidakis, D., Nikou, G., Ivanovic, A., Chapple, I. L. C., & Stavropoulos, A. (2015). Biomaterials for promoting periodontal regeneration in human intrabony defects: a systematic review. *Periodontology 2000*, *68*, 182–216. <https://doi.org/10.1111/prd.12086>



- Sculean, A., Nikolidakis, D., & Schwarz, F. (2008). Regeneration of periodontal tissues: combinations of barrier membranes and grafting materials—biological foundation and preclinical evidence: a systematic review. *Journal of Clinical Periodontology*, 35, 106–116. <https://doi.org/10.1111/j.1600-051X.2008.01263.x>
- Sculean, A., Pietruska, M., Arweiler, N. B., Auschill, T. M., & Nemcovsky, C. (2007). Four-year results of a prospective controlled clinical study evaluating healing of intrabony defects following treatment with an enamel matrix protein derivative alone or combined with a bioactive glass. *Journal of Clinical Periodontology*, 34, 507–513. <https://doi.org/10.1111/j.1600-051X.2007.01084.x>
- Seshima, F., Aoki, H., Takeuchi, T., Suzuki, E., Irokawa, D., Makino-Oi, A., Sugito, H., Tomita, S., & Saito, A. (2017). Periodontal regenerative therapy with enamel matrix derivative in the treatment of intrabony defects: a prospective 2-year study. *BMC Research Notes*, 10, 256. <https://doi.org/10.1186/s13104-017-2572-2>
- Stavropoulos, A., & Karring, T. (2010). Guided tissue regeneration combined with a deproteinized bovine bone mineral (Bio-Oss®) in the treatment of intrabony periodontal defects: 6-year results from a randomized-controlled clinical trial. *Journal of Clinical Periodontology*, 37, 200–210. <https://doi.org/10.1111/j.1600-051X.2009.01520.x>
- Tonetti, M. S., Cortellini, P., Lang, N. P., Suvan, J. E., Adriaens, P., Dubravec, D., & Zyburt, M. (2004). Clinical outcomes following treatment of human intrabony defects with GTR/bone replacement material or access flap alone. *Journal of Clinical Periodontology*, 31, 770–776. <https://doi.org/10.1111/j.1600-051X.2004.00562.x>
- Tonetti, M. S., Lang, N. P., Cortellini, P., Suvan, J. E., Adriaens, P., Dubravec, D., Fonzar, A., Fourmouis, I., Mayfield, L., Rossi, R., Silvestri, M., Tiedemann, C., Topoll, H., Vangsted, T., & Wallkamm, B. (2002). Enamel matrix proteins in the regenerative therapy of deep intrabony defects: a multicenter randomized controlled clinical trial. *Journal of Clinical Periodontology*, 29, 317–325. <https://doi.org/10.1034/j.1600-051X.2002.290407.x>
- Troiano, G., Laino, L., Zhurakivska, K., Cicciù, M., Lo Muzio, L., & Lo Russo, L. (2017). Addition of enamel matrix derivatives to bone substitutes for the treatment of intrabony defects: A systematic review, meta-analysis and trial sequential analysis. *Journal of Clinical Periodontology*, 44, 729–738. <https://doi.org/10.1111/jcpe.12742>
- Trombelli, L., Farina, R., Vecchiatini, R., Maietti, E., & Simonelli, A. (2020). A simplified composite outcome measure to assess the effect of periodontal regenerative treatment in intraosseous defects. *Journal of Periodontology*, 91, 723–731. <https://doi.org/10.1002/JPER.19-0127>
- Zucchelli, G., Amore, C., Montebugnoli, L., & De Sanctis, M. (2003). Enamel matrix proteins and bovine porous bone mineral in the treatment of intrabony defects: a comparative controlled clinical trial. *Journal of Periodontology*, 74, 1725–1735. <https://doi.org/10.1902/jop.2003.74.12.1725>
- Zucchelli, G., Bernardi, F., Montebugnoli, L., & De Sanctis, M. (2002). Enamel matrix proteins and guided tissue regeneration with titanium-reinforced expanded polytetrafluoroethylene membranes in the treatment of infrabony defects: a comparative controlled clinical trial. *Journal of Periodontology*, 73, 3–12. <https://doi.org/10.1902/jop.2002.73.1.3>

## SUPPORTING INFORMATION

Additional supporting information may be found online in the Supporting Information section.

**How to cite this article:** Aoki H, Bizenjima T, Seshima F, et al. Periodontal surgery using rhFGF-2 with deproteinized bovine bone mineral or rhFGF-2 alone: 2-year follow-up of a randomized controlled trial. *J Clin Periodontol*. 2021;48:92–100. <https://doi.org/10.1111/jcpe.13385>