

# Giant Pulmonary Artery Aneurysm Secondary To Patent Ductus Arteriosus: A Case Report

Tahir Bezgin\*, Hacer C. Demircan and Cihangir Kaymaz

\*Kartal Koşuyolu Heart&Research Hospital, Cardiology Clinic, 34846 Istanbul, Turkey

**Abstract:** Aneurysms involving the main pulmonary artery and its branches are rare. Clinical experience is limited, and their management is not well established. We present the case of a 35-year-old male patient with dyspnea and hemoptysis in whom subsequent imaging studies revealed a giant pulmonary artery aneurysm associated with an uncorrected patent ductus arteriosus and Eisenmenger's syndrome. We chose to treat the patient conservatively with medical management due to the development of Eisenmenger's physiology while waiting for heart-lung transplantation.

**Keywords:** Aneurysms, dyspnea, hemoptysis, pulmonary artery.

## CASE REPORT

A 35-year-old male patient was presented at our outpatient clinic with dyspnea and hemoptysis. His medical history included a cardiac defect diagnosed fifteen years earlier. He did well since then. He had been lost to follow-up until recently, and no imaging study was performed for the patient until he presented with complaints. He remained active and had an acceptable quality of life. He had a history of progressive dyspnea and hemoptysis for 2 years. His physical examination revealed central cyanosis and clubbing, and there was loudness in P2 on auscultation. O2 saturation on room air was 84%. An electrocardiogram showed sinus rhythm with right bundle branch block (Fig. 1). Chest radiography revealed cardiomegaly, severe dilation of the main pulmonary artery, and dilation of the pulmonary branch arteries (Fig. 2). His functional capacity was NYHA class III. Hemoglobin, hematocrit and BNP values were 19 gr/dl, 58% and 986 pg/ml, respectively. Other laboratory parameters were all within normal limits.

Transthoracic echocardiography showed an aneurysm of the main pulmonary artery of approximately 7.4 cm, dilation in left and right pulmonary arteries, and a turbulent flow between the pulmonary artery and descending aorta with color Doppler (Fig. 3A-B). Enlargement of right heart chambers and moderate tricuspid regurgitation were detected. Estimated pulmonary arterial systolic pressure was 110 mmHg. Pulmonary valve, in parasternal long axis, was seen as it were tricuspid aortic valve that was classically observed in parasternal short axis view (Fig. 4A-B).

Contrast-enhanced, multislice computed tomography (CT) with 3 dimensional reconstruction of the patient's chest revealed a giant aneurysm of the pulmonary trunk with a maximum diameter of 79 mm and a patent ductus arteriosus

(PDA) (Fig. 5A-B). Systolic and mean pulmonary arterial pressures measured during catheterization were 140 and 95 mmHg, respectively. Vasoreactivity testing with adenosine was negative.

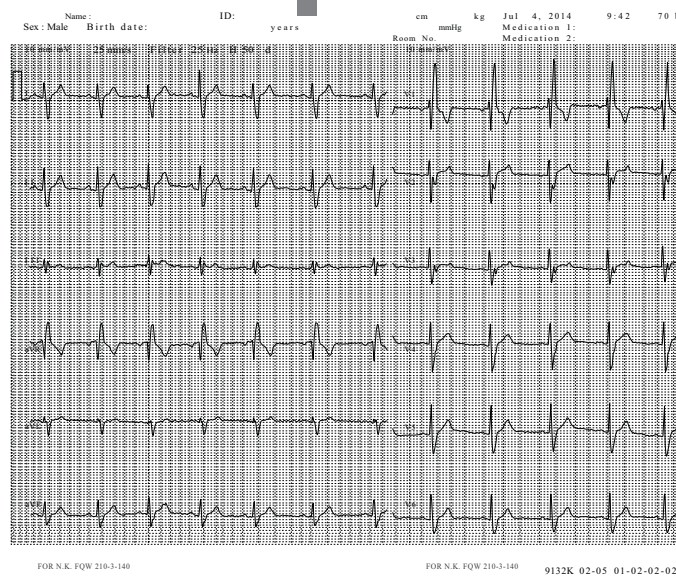
## DISCUSSION

Pulmonary artery aneurysm (PAA) is an uncommon disease of the pulmonary vasculature. The underlying causes include congenital heart diseases, pulmonary embolism, trauma, connective tissue disorders (Marfan's syndrome, Ehler-Danlos syndrome), systemic vasculitis, and pulmonary hypertension [1-3]. PDA is the most frequently associated congenital anomaly, followed by ventricular and atrial septal defects [4, 5]. Behçet's disease is the most common vasculitic cause of PAA [6].

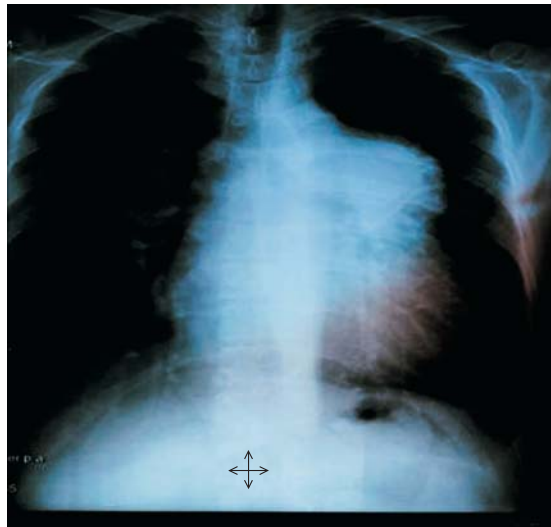Our patient had a giant main PAA and Eisenmenger's syndrome secondary to PDA. PAAs have high morbidity and mortality due to the thinning of the arterial wall related to increased wall stress and eventual rupture. The formation of an aneurysm in the presence of marked pulmonary artery hypertension suggests that the mechanical stress on the vascular wall which elevates intraluminal pressures outweighs the protective deposition of connective tissue proteins, and the medial smooth muscle cell hypertrophy observed in pulmonary hypertension [1]. The low pressure condition is much more benign, with low risk of arterial dissection and rupture even for large dilations, which may have diameters of up to 16 cm [7, 8]. Although the relationship between aneurysm size and risk of rupture in low-pressure pulmonary artery aneurysms is not well defined, decades without rupture have been observed in some cases [9, 10]. In contrast, PAAs secondary to pulmonary arterial hypertension pose a significant risk for the patient; and according to Laplace's law, the size of these aneurysms is an important determinant of progression and rupture [11, 12].

Unfortunately, clear guidelines regarding medical vs surgical management are lacking. Treatment of the low-pressure condition is based more on right ventricular function and

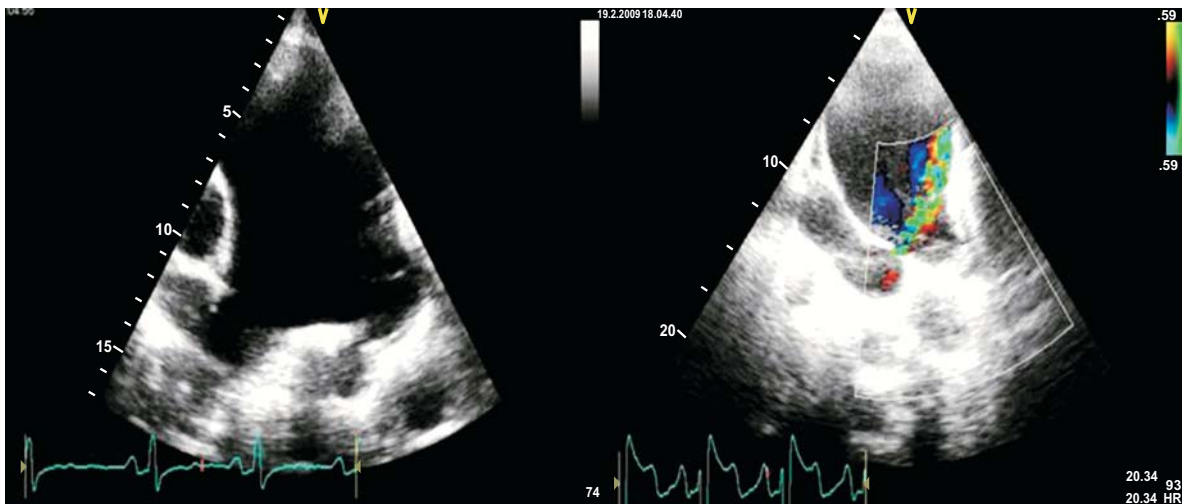\*Address correspondence to this author at the Kartal Koşuyolu Heart Research Hospital, Deniz Cad. 34846 Cevizli Kartal-İstanbul, Turkey; Tel: +90 505 442 47 12; Fax: +90 216 459 63 21; E-mail: bezgintahir3@yahoo.com



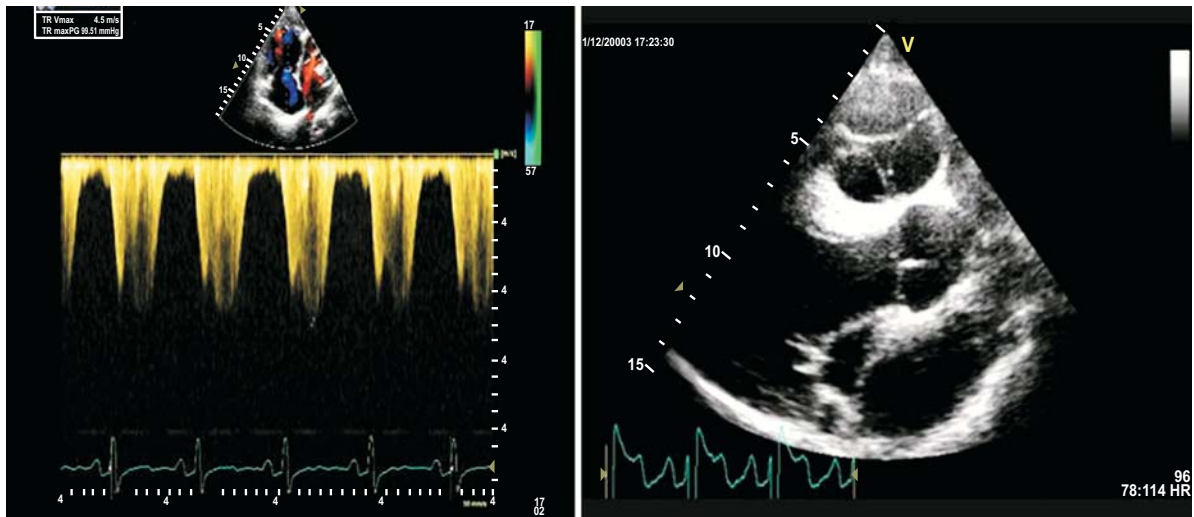
**Fig. (1).** Electrocardiogram showing sinus rhythm, right bundle branch block.



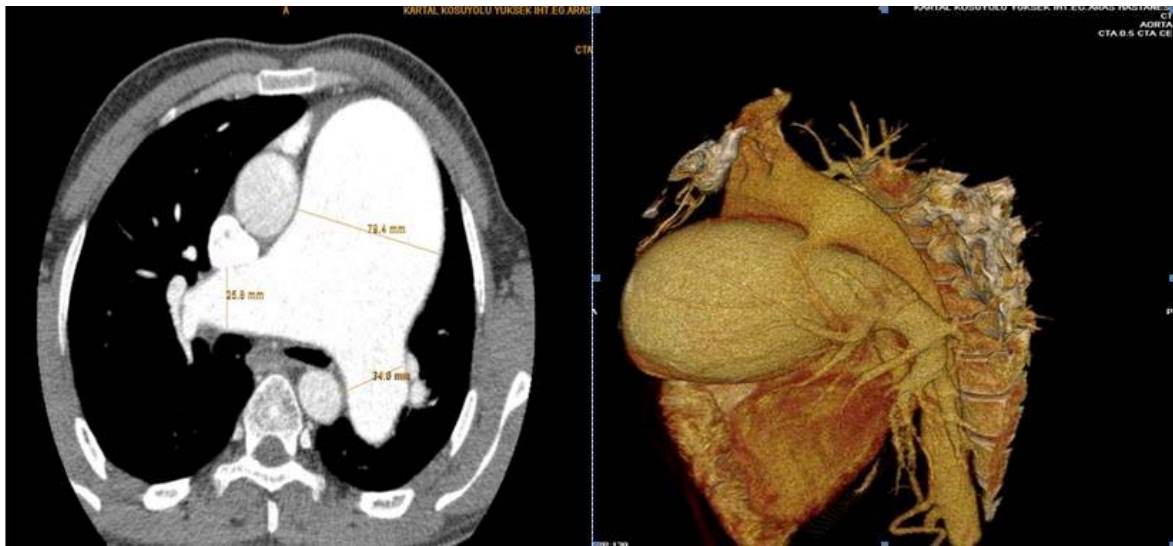
**Fig. (2).** Chest radiograph shows cardiomegaly, dilated main and left pulmonary artery with peripheral pruning.



**Fig. (3).** (A) An huge pulmonary artery aneurysm seen in parasternal short axis. (B) A shunt between pulmonary artery and descending aorta seen with color Doppler.



**Fig. (4).** (A) Moderate degree tricuspid regurgitation with pulmonary arterial systolic pressure 110 mmHg and dilatation in right heart chambers. (B) Pulmonary valve with three cusps in the parasternal long axis.



**Fig. (5).** (A) Contrast enhanced multislice chest CT (B) three-dimensional reconstruction of it revealing diffuse aneurysmal dilatation of the pulmonary artery and patent ductus arteriosus.

associated pulmonary valve stenosis or regurgitation rather than the size of the aneurysm. It is treated primarily by aneurysmorrhaphy or by allograft implantation with or without pulmonary valve replacement [7, 13]. However, if significant pulmonary arterial hypertension or connective tissue disease is present, which increases the risk of rupture, surgical treatment must be considered, particularly in patients with symptoms or progressive changes [9]. Although a heart-lung transplant is rarely the treatment of choice, it appears to be necessary in the present case with Eisenmenger's syndrome. Conservative treatment is advocated for asymptomatic patients without a causative cardiac lesion and pulmonary hypertension [14, 15]. The disadvantage of conservative treatment, however, is the potential for dissection.

There are many other factors to consider during the treatment decision, including the patient's age, life expectancy, symptoms and functional status. Minimizing the risks

for rupture (i.e. pulmonary hypertension) and annual imaging studies, including CT scans, are required to watch for dilation or rupture in asymptomatic subjects. In addition, serial echocardiograms may help to monitor cardiac function and changes in pulmonary hypertension pressures [16]. However, one must be vigilant about symptoms that portend a possible dissection and emergent surgical intervention.

Our patient had a known prior diagnosis of a cardiac defect, but duration of the pulmonary artery dilation was unknown. A large PAA can cause local compressive symptoms. In many patients a chest radiograph is obtained for unrelated symptoms, which reveals vascular dilation or a hilar/mediastinal mass; and a definitive diagnosis usually requires further radiological evaluation [17]. Echocardiogram is a reasonable tool for initial investigation due to its ease of use, low cost and convenient accessibility [18]. Further non-invasive imaging studies such as CT angiography

can be used if echocardiography fails to detect an intimal flap, or to provide information related to dissection [1, 18].

In conclusion, we present an adult patient with a giant pulmonary artery aneurysm secondary to untreated PDA leading to Eisenmenger's syndrome. The high risk of acute pulmonary artery dissection and rupture resulting from the progressive enlargement of the aneurysm with concomitant pulmonary artery thrombosis in the setting of Eisenmenger's syndrome dictates treatment by heart-lung transplant, which, our patient currently awaits. While waiting for the heart-lung transplantation, we initiated treatment with bosentan according to the current guidelines to improve symptoms.

### CONFLICT OF INTEREST

The authors confirm that this article content has no conflict of interest.

### ACKNOWLEDGEMENTS

Declared none.

### REFERENCES

- [1] Lopez-Candales A, Kleiger RE, Aleman-Gomez J, Kouchoukos NT, Botney MD. Pulmonary artery aneurysm: review and case report. *Clin Cardiol* 1995; 18: 738-40.
- [2] Durieux P, Bletry O, Huchon G, Wechsler B, Chretien J, Godeau P. Multiple pulmonary arterial aneurysms in Behcet's disease and Hughes-Stovin syndrome. *Am J Med* 1981; 71: 736-41.
- [3] Mastroroberto P, Chello M, Zofrea S, Del Negro G, De Francesca F, Maltese G. Pulmonary artery aneurysm. *Ann Thorac Surg* 1997; 64: 585-6.
- [4] Coard KC, Martin MP. Rupture saccular pulmonary artery aneurysm associated with persistent ductus arteriosus. *Arch Pathol Lab Med* 1992; 116: 159-61.
- [5] Butto F, Lucas RV Jr, Edwards JE. Pulmonary arterial aneurysm. A pathologic study of five cases. *Chest* 1987; 91: 237-41.
- [6] Hammad AM, Al-Qahtani SM, Al-Zahrani MA. Huge pulmonary artery aneurysm. *Can Respir J* 2009; 16(3): 93-5.
- [7] Veldtman GR, Dearani JA, Warnes CA. Low pressure giant pulmonary artery aneurysms in the adult: natural history and management strategies. *Heart* 2003; 89: 1067-70.
- [8] Chen YF, Chiu CC, Lee CS. Giant aneurysm of main pulmonary artery. *Ann Thorac Surg* 1996; 62(1): 272-4.
- [9] Imazio M, Cecchi E, Giammaria M, *et al.* Main pulmonary artery aneurysm: a case report and review of the literature. *Ital Heart J* 2004; 5(3): 232-7.
- [10] Chung CW, Doherty JU, Kotler R, *et al.* Pulmonary artery aneurysm presenting as a lung mass. *Chest* 1995; 108(4): 1164-6.
- [11] Senbaklavaci O, Kaneko Y, Bartunek A, *et al.* Rupture and dissection in pulmonary artery aneurysms: incidence, cause, and treatment: review and case report. *J Thorac Cardiovasc Surg* 2001; 121: 1006-8.
- [12] Deterling RA, Clagett T. Aneurysm of the pulmonary artery: review of the literature and report of a case. *Am Heart J* 1947; 34: 471-99.
- [13] Kuwaki K, Morishita K, Sato H, *et al.* Surgical repair of the pulmonary trunk aneurysm. *Eur J Cardiothorac Surg* 2000; 18(5): 535-9.
- [14] Vural AH, Turk T, Ata Y, Goncu T, Ozyazicioglu A. Idiopathic asymptomatic main pulmonary artery aneurysm: surgery or conservative management? A case report. *Heart Surg Form* 2007; 10: E273-5.
- [15] van Rens MT, Westermann CJ, Postmus PE, Schramel FM. Untreated idiopathic aneurysm of the pulmonary artery; long-term follow-up. *Respir Med* 2000; 94: 404-5.
- [16] Arnaoutakis G, Nwakanma L, Conte J. Idiopathic pulmonary artery aneurysm treated with surgical correction and concomitant coronary artery bypass grafting. *Ann Thorac Surg* 2009; 88: 273-5.
- [17] Deb SJ, Zehr KJ, Shields RC. Idiopathic pulmonary artery aneurysm. *Ann Thorac Surg* 2005; 80: 1500-2.
- [18] Khattar RS, Fox DJ, Alty JE, Arora A. Pulmonary artery dissection: an emerging cardiovascular complication in surviving patients with chronic pulmonary hypertension. *Heart* 2005; 91: 142-5.