

Received: 2018.06.01  
Accepted: 2018.08.01  
Published: 2018.11.30

# Radiological Variabilities in Subcoracoid Impingement: Coracoid Morphology, Coracohumeral Distance, Coracoglenoid Angle, and Coracohumeral Angle

Authors' Contribution:  
Study Design A  
Data Collection B  
Statistical Analysis C  
Data Interpretation D  
Manuscript Preparation E  
Literature Search F  
Funds Collection G

ABCDEF G **Neşe Asal**  
ABCDEF G **Mehmet Hamdi Şahan**

Department of Radiology, Kirikkale University School of Medicine, Kirikkale, Turkey

**Corresponding Author:** Neşe Asal, e-mail: nese\_asal@yahoo.com.tr  
**Source of support:** Departmental sources

**Background:** The aim of this study was to investigate the effects of coracoid morphology, coracohumeral distance, coracoglenoid angle, and coracohumeral angle variabilities on subcoracoid impingement development using magnetic resonance imaging (MRI).

**Material/Methods:** A total of 200 patients (87 males with mean age of 51.1±15.2 years and 113 females with mean age of 52.6±10.7 years) undergoing shoulder MRI were included in this retrospective study. All MRI studies were performed with standard positioning. Coracoid morphology and subscapularis tendon were evaluated. Coracohumeral distance, coracoglenoid angle and coracohumeral angle were measured in all subjects. One-way ANOVA was used to assess the difference between the groups. For binary comparisons, Tukey post hoc analysis was done. Pearson correlation analysis was performed between variables.

**Results:** Type C coracoid was more frequent in the tendinosis and tendon tear groups. There was a significant difference between type C coracoid and the other coracoid types for coracohumeral distance values (P=0.016). There was a statistically significant decrease in coracoglenoid angle values and coracohumeral distance in patients with subscapularis tendon pathologies (P=0.000). A statistically insignificant increase in coracohumeral angle values was found in the subscapularis tendon pathologies. There was a positive correlation between coracohumeral distance and coracoglenoid angle (R=0.749 P=0.000). There was a negative correlation between coracohumeral distance and coracohumeral angle (R=-0.668 P=0.000) and between coracoglenoid angle and coracohumeral angle (R=-0.605 P=0.000).

**Conclusions:** In subscapularis tendon pathologies, decrease in coracohumeral distance and coracoglenoid angle was observed. A new approach uses coracohumeral angle to evaluate subcoracoid impingement. A statistically insignificant increase in coracohumeral angle was noted.

**MeSH Keywords:** **Magnetic Resonance Imaging • Rotator Cuff • Shoulder Impingement Syndrome**

**Full-text PDF:** <https://www.medscimonit.com/abstract/index/idArt/911470>



2393



4



4



24



## Background

Subcoracoid impingement, characterized by narrowing of the space between the coracoid process and the humerus, is a rarely recognized cause of shoulder pain [1]. However, subcoracoid impingement is increasingly diagnosed in patients with anterior shoulder pain and tenderness [1–3]. The mechanism is increased with activities involving adduction, internal rotation, and forward flexion because the position decreases coracohumeral distance and impinges the intervening soft-tissue structures [4–6]. The compression of the soft tissue between the lesser tuberosity of the humerus and the coracoid tip is defined as the “roller-wringer effect” and was reported to cause progressive degeneration and injury to the rotator cuff, especially subscapularis tendon tears [1,6–8]. The coracohumeral distance may be narrowed due to anatomic variations of the humerus and scapula, specifically lesser tuberosity protrusion and coracoid shape [7,9].

Tears of the subscapularis tendon constitute 31–37% of all repaired rotator cuff tendons [10–12]. The role of local anatomy in the etiology of tears of the subscapularis tendon is very important. Numerous authors have described the frequency of the subscapularis tears to be higher than previously thought, so subscapularis tears have lately become a focus of clinical practice and research [5,13–15]. Several authors have used roentgen, computed tomography (CT), or MRI to evaluate coracoid morphology, coracohumeral distance, and coracoglenoid angle [1,3,7,10,16]. MRI appears to be more sensitive than CT for diagnosis of coracoid impingement [17].

In the development of subcoracoid impingement, studies on the variabilities of coracoid morphology, coracohumeral distance, and coracoglenoid angle have been published [1,3–7,9,10]. However, to the best of our knowledge, there is no study evaluating the relationship between the coracohumeral angle and subcoracoid impingement. The present study used MRI to evaluate the effects of coracoid morphology, coracohumeral distance, coracoglenoid angle, and coracohumeral angle variabilities on subcoracoid impingement development.

## Material and Methods

### Patients

A total of 200 shoulder MRIs in adult over age 18 years were examined retrospectively between January 2017 and March 2018 from a digital radiology database at Kirikkale University. All patients who were selected in this study were having shoulder MRI. In subscapularis normal tendon subjects, orthopedic examination results were selected from those with no evidence of subcoracoid impingement. Otherwise, findings of

subcoracoid impingement such as shoulder pain, subscapularis tear, shoulder impingement, and limitation of movement were present in the registered orthopedic examination findings in subscapularis tendon pathologies subjects.

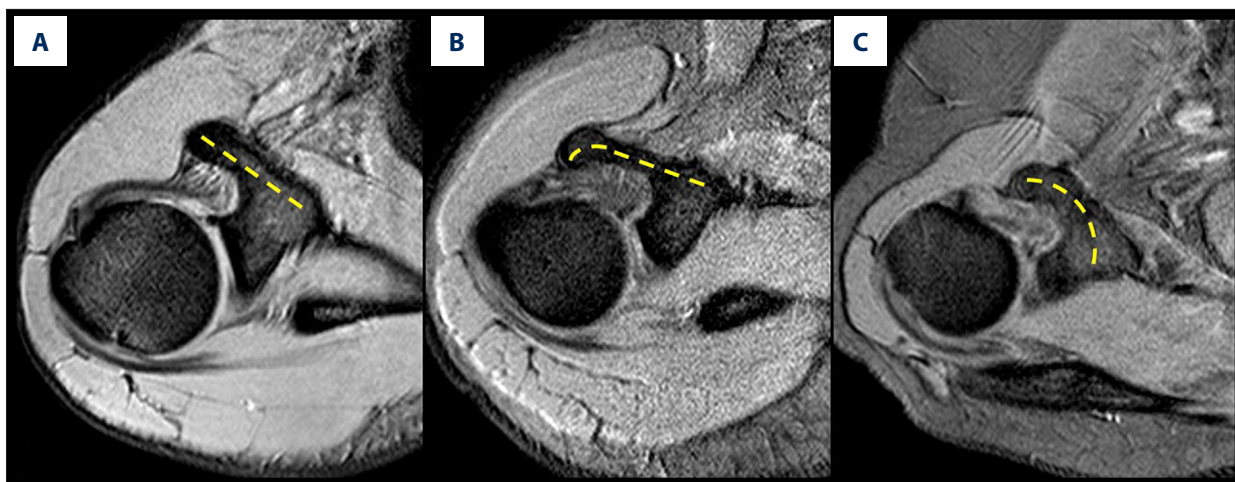
Clinical conditions that may cause changes in measurements of shoulder joints, such as tumors, shoulder surgery, osteoarthritis, inflammatory joint disease, hemophilic arthritis, pyrophosphate disease, and significant trauma (including fractures, dislocations and falling down), were excluded from the study. Ethics Committee approval was obtained from Kirikkale University Faculty of Medicine (date: 08.05.2018, number: 10/02).

### MRI technique and measurements

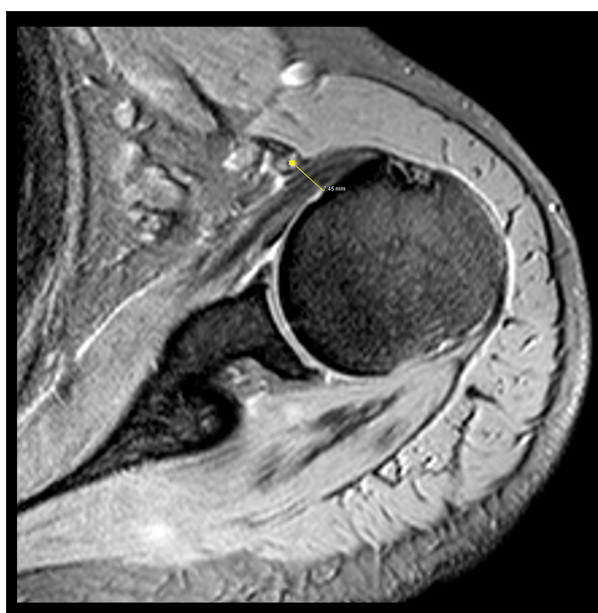All MRI examinations were performed using surface coils by 1.5 Tesla (T) MRI systems (Philips MRI Systems, Achiava Release 3,2 Level 2013-10-21, Philips Medical Systems Nederland B.V.). The routine shoulder MRI protocol for the 1.5-T MR machine at Kirikkale University Hospital was as follows: T2-weighted FFE images in axial plane (TR/TE interval, 2600–3000/20–30 ms), T2-weighted SPAIR images in sagittal plane (TR/TE interval, 2600–3000/20–30 ms), and T2-weighted images fat-suppressed proton density-weighted images in coronal oblique plane (TR/TE interval, 2600–3000/20–30 ms). Imaging parameters were as follows: field of view, 18–20 cm; matrix, 256×182 pixels; slice thickness, 4 mm; section gap, 0.3 mm. Each patient was examined in the supine position, with slight external rotation position of the arm. If the patient’s palm is placed below the outer part of the gluteal muscle on the same side, the movement factor may also be inhibited. All MRI studies were static and used no special patient positioning technique.

All measurements were calculated T2-weighted FFE-weighted sequences on axial plane by an expert musculoskeletal radiologist with at least 10 years of experience (NA). Coracoid morphology and subscapularis tendon were evaluated; coracohumeral distance, coracoglenoid angle, and coracohumeral angle were measured in all subjects.

For coracoid morphology, the shape of the coracoid was determined according to whether it was straight or not, any osteophyte included, and whether it was curved. For the flat coracoid, the axis of the coracoid was generally straight from base to tip [9] (Figure 1A). The osteophyte at the end of the coracoid was defined as a more focused osteophyte at the distal end of the coracoid [9] (Figure 1B). For the hooked coracoid, the axis of the coracoid deviated posteriorly a few centimeters lateral to the base of the coracoid [9] (Figure 1C). Group categorization was performed according to coracoid morphology: type A was flat coracoid, type B was osteophyte at the tip of the coracoid, and type C was hooked coracoid.



**Figure 1.** (A) Flat coracoid. (B) Osteophyte at the tip of the coracoid. (C) Hooked coracoid in axial T2-weighted FFE images.

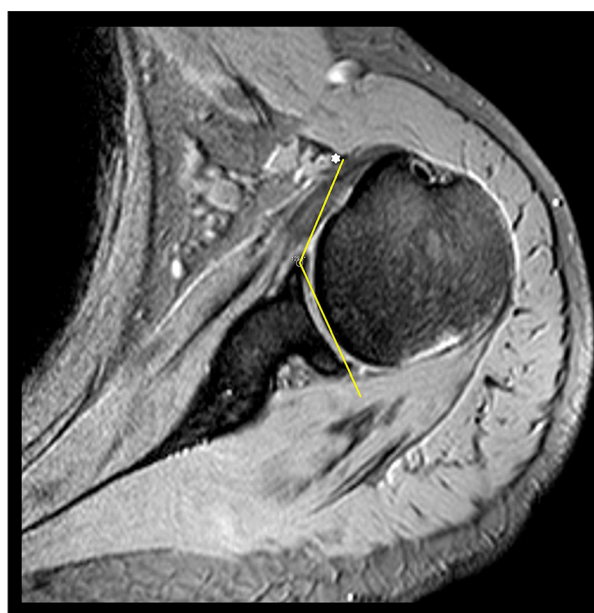

**Figure 2.** Coracohumeral distance, in axial T2-weighted FFE images (yellow\*; coracoid distal tip).

The coracohumeral distance was measured at the narrowest point between the coracoid and the humerus on the axial images [10] (Figure 2).

The coracoglenoid angle was measured as an angle between a line along the plane of the glenoid face and a line projecting from the anterior edge of the glenoid to the lateral edge of the coracoid on the axial images [10] (Figure 3).

The coracohumeral angle was measured as an angle between the line tangential to the lateral surface of the humerus head from the coracoid tip and the line tangential to the medial surface of the humerus head from coracoid tip on the axial images (Figure 4).

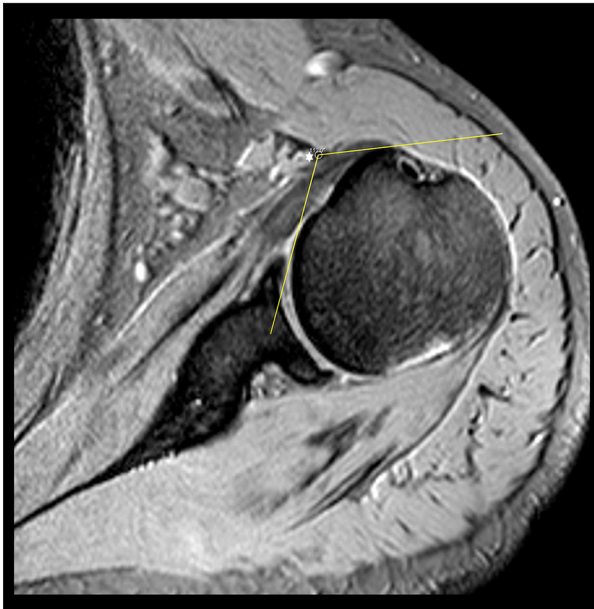

**Figure 3.** Coracoglenoid angle, in axial T2-weighted FFE images (white\*; coracoid distal tip).

The subscapularis tendon was evaluated as normal, tendinosis, or tear in the 3 groups.

### Statistical analysis

Statistical analyses were performed using SPSS version 20 software (SPSS, Chicago, IL, U.S.A). Data are expressed as mean  $\pm$  standard deviation (SD) or median (range). Categorical variables such as sex were compared between groups with the chi-square test. The groups showed normal distribution and the variances were homogeneous. One-way ANOVA was used to assess differences between the groups. For binary comparisons, Tukey post hoc analysis was done. Pearson correlation analysis was performed for coracohumeral distance and



**Figure 4.** Coracohumeral angle, in axial T2- weighted FFE images (white\*; coracoid distal tip).

coracoglenoid angle, coracohumeral distance and coracohumeral angle, and coracoglenoid angle and coracohumeral angle.  $P < 0.05$  was considered statistically significant.

## Results

There were 87 males with a mean age of  $51.1 \pm 15.2$  years (range, 18–80 years) and 113 females with a mean age of  $52.6 \pm 10.7$  years (range, 23–74 years) in the study group.

The results of the rates of coracoid types in subscapularis tendon pathologies are shown in Table 1. There was a statistically significant difference between coracoid types and subscapularis tendon pathologies ( $P=0.02$ ). In the subscapularis tendon pathologies, 198 of the tears (99%) were partial tears and there were only 2 full-thickness tears. Type A coracoid was the most frequent type, and type C coracoid was less frequent in the normal tendon group. Type C coracoid was seen more frequently in the tendinosis and tear groups.

The results of measurement of coracohumeral distance, coracoglenoid angle, and coracohumeral angle in the coracoid types are shown in Table 2. There was a statistically significant difference in coracohumeral distance ( $P=0.016$ ), but there was no significant difference in coracoglenoid angle ( $P=0.08$ ) or coracohumeral angle ( $P=0.2$ ). The results of measurement of coracohumeral distance, coracoglenoid angle, and coracohumeral angle in the subscapularis tendon pathologies are shown in Table 3. There was a statistically significant difference in coracohumeral distance ( $P=0.000$ ) and coracoglenoid

**Table 1.** The results of the rates of coracoid types in subscapularis tendon pathologies.

	Coracoid type			
	Type A (flat) n (%)	Tip B (osteophytic) n (%)	Tip C (hooked) n (%)	Total n (%)
Subscapularis tendon				
Normal n (%)	29 (37.5)	25 (32.5)	23 (29.9)	77 (38.5)
Tendinosis n (%)	3 (13.0)	5 (21.7)	15 (65.2)	23 (11)
Tear n (%)	25 (25)	27 (27)	48 (48)	100 (50)
Total n (%)	57 (28.5)	57 (28.5)	86 (43)	200

$P$  value=0.02 according to chi square analysis.

**Table 2.** The results measurement of coracohumeral distance, coracoglenoid angle and coracohumeral angle in the coracoid types.

Coracoid type	Type A (n=57)	Type B (n=57)	Type C (n=86)	P values
CHD Mean $\pm$ SD (mm)	7.3 $\pm$ 2	6.8 $\pm$ 1.9	6.3 $\pm$ 2.1*	0.016
CGA Mean $\pm$ SD ( $^{\circ}$ )	133.4 $\pm$ 5.6	133.2 $\pm$ 6.9	131 $\pm$ 6	0.08
CHA Mean $\pm$ SD ( $^{\circ}$ )	108.8 $\pm$ 7.8	110.3 $\pm$ 8.8	111 $\pm$ 8.6	0.2

\* Symbolizes the difference between type A to C according to post hoc Tukey test. The results are expressed as mean $\pm$ standard deviation (SD); CHD – coracohumeral distance; CGA – coracoglenoid angle; CHA – coracohumeral angle.



**Table 3.** The results measurement of coracohumeral distance, coracoglenoid angle and coracohumeral angle in the subscapularis tendon pathologies.

Subscapularis tendon	Normal (n=77)	Tendinosis (n=23)	Tear (n=100)	P values
CHD Mean ±SD (mm)	7.8±2.1 <sup>1</sup>	6.5±2.1 <sup>2</sup>	6±1.8 <sup>2</sup>	0.000
CGA Mean ±SD (°)	135.4±6.6 <sup>1</sup>	131±5.1 <sup>2</sup>	130.4±5.3 <sup>2</sup>	0.000
CHA Mean ±SD (°)	108.3±8.6	112.6±8.6	111±8	0.06

<sup>1</sup> The superscript numbers were used according to post hoc Tukey test. The difference symbolizes the significant difference for P value.

<sup>2</sup> The results are expressed as mean±standard deviation (SD); CHD – coracohumeral distance; CGA – coracoglenoid angle; CHA – Coracohumeral angle

angle (P=0.000), but there was no significant difference in coracohumeral angle (P=0.06).

Coracohumeral distance, coracoglenoid angle, and coracohumeral angle values were compared with post hoc Tukey test among the types of coracoids. There was a significant difference between type A and C coracoid for coracohumeral distance values (P=0.012), but no significant difference was found between other coracoid groups (P>0.05). There was no statistically significant difference among coracoid types for coracoglenoid angle or coracohumeral angle values (P>0.05).

Coracohumeral distance, coracoglenoid angle, and coracohumeral angle values were compared with post hoc Tukey test among the subscapularis tendon pathologies. There was a significant difference between normal and tendinosis groups (P=0.021) and between normal and tear groups (P=0.000) for coracohumeral distance values. There was a significant difference between normal and tendinosis groups (P=0.006) and between normal and tear groups (P=0.000) for coracoglenoid angle values. There was no significant difference between tendinosis and tear groups for coracohumeral distance and coracoglenoid angle values (P>0.05). There was no statistically significant difference between the values of the coracohumeral angle and the changes in the subscapularis tendon pathologies (P>0.05), but we observed higher coracohumeral angle values of tendinosis and tear pathologies (P=0.074 and P=0.073, respectively).

We found a positive correlation between coracohumeral distance and coracoglenoid angle (R=0.749 P=0.000). There was a negative correlation between coracohumeral distance and coracohumeral angle (R=-0.668 P=0.000) and between coracoglenoid angle and coracohumeral angle (R=-0.605 P=0.000). The results of correlation analysis of coracohumeral distance, coracoglenoid angle, and coracohumeral angle are shown in Table 4.

**Table 4.** Correlation analysis among coracohumeral distance, coracoglenoid angle and coracohumeral angle.

Parameter	R values	P values
CHD to CGA	0.749	0.000
CHD to CHA	-0.668	0.000
CGA to CHA	-0.605	0.000

CHD – coracohumeral distance; CGA – coracoglenoid angle; CHA – coracohumeral angle.

## Discussion

For subscapularis tendinosis and tear pathologies in the normal tendon of cases, we observed a narrowed coracohumeral distance and a decreased coracoglenoid angle, as well as an increase in coracohumeral angle.

Subcoracoid impingement syndrome is the cause of anterior shoulder pain, first reported by Gerber et al. [16]. In subcoracoid impingement, etiology, idiopathic, iatrogenic, anatomic, and traumatic factors are involved [10,18–21]. Angled or elongated coracoid type and calcification of the subscapularis tendon are among the idiopathic causes [17]. Small changes in the subcoracoid space may result in compression of subscapularis bursa and tendon [10]. Determining the coracoid type is important for subcoracoid impingement due to the narrowing of the coracohumeral space [1,6,9,10]. Gerber et al. [16] described an increased subcoracoid area after decompression surgery in symptomatic patients. In the present study, narrowed coracohumeral distance, decreased coracoglenoid angle, and increased coracohumeral angle were observed in type B and C coracoid, especially in type C coracoid. While the variability in the coracohumeral distance values between coracoid types was more prominent, there was no statistically significant difference due to less variability for coracoglenoid angle and coracohumeral angle values. In the present study, was observed a statistically significant difference between coracoid types and

subscapularis tendon pathologies. In our study, type A coracoid was the most frequent type, and type C coracoid was less frequent in the normal tendon group; type C coracoid was seen more frequently in the tendinosis and tear groups. Our results suggest that type C coracoid is an especially important predisposing factor in subcoracoid impingement development.

There are studies in the literature that evaluated the effect of dynamic imaging on the subcoracoid impingement [5,6,8,10,22]. Brukhorst et al. [1] found that the coracohumeral distance decreased by 16% during internal rotation, and they also suggested evaluating internal rotation in terms of subcoracoid impingement [1]. Friedman et al. [4] used dynamic MRI to evaluate coracohumeral distance, reporting an 11-mm mean coracohumeral distance in asymptomatic patients and 5.5 mm in symptomatic patients [4]. Giaroli et al. [6] reported that the measurement of coracohumeral distance had poor predictive value for subcoracoid impingement diagnosis. In contrast, Richards et al. [23] found a significant relationship between narrowed coracohumeral distance and subscapularis tendon pathologies. Hekimoglu et al. [24] found a direct correlation between a narrowed coracohumeral distance and symptoms of subcoracoid impingement. These results may vary depending on the different imaging methods and patient positioning used in the studies [6]. In many studies, a coracohumeral distance below 6 mm is considered to be significant for subcoracoid impingement in partial and full-thickness tears of subscapularis tendon [8]. In this study, MRI was performed in the standard position; therefore, the inter-value angle variability was decreased. Coracohumeral distance values were 2–13.5 mm. In the subscapularis tendon tears, the coracohumeral distance narrowed and the mean value was 6 mm. However, there was no statistically significant difference between tendinosis and tear groups due to less than 1 mm difference in coracohumeral distance values.

Watson et al. [10] used a coracoglenoid angle measurement on different planes and found a positive correlation between the coracohumeral distance and the coracoglenoid angle. In their study, there was a decrease of axial coracoglenoid angle values in subscapularis tendon tears [10]. There was no significant difference between the coracoid types and coracoglenoid angle values in our study. Coracoglenoid angle values decreased in type C coracoid but the variability was not more than 2° and no statistically significant difference was observed. Coracoglenoid angle values also decreased in the subscapularis tendon tendinosis and tear groups. However, there was only a difference of less than 1° between the tendinosis and the tear groups in the angle values and no statistically significant difference was detected. In contrast, there was a significant

difference in coracoglenoid angle between the tendinosis-tear pathologies and the tendon normal groups. In our study, the narrowed coracohumeral distance was accompanied by decreased coracoglenoid angle and there was a positive correlation, similar to the report by Watson et al. [10]. The low significance of differences in the values in the subscapularis tendinosis and tear pathologies may be due to the similarity in the process of formation of these pathologies and the fact that the imaging was performed in the standard position.

There is no study on coracohumeral angle measurement in the literature. In our study, there was a significant difference only between type A and C coracoid in coracoid types for coracohumeral angle. There was no significant difference among subscapularis tendon groups for coracohumeral angle. The coracohumeral angle values increased, especially in type C coracoid, but the variability for coracohumeral angle values in coracoid and subscapularis tendon groups was less than 2° and no statistically significant difference was detected. However, the increased coracohumeral angle was accompanied a narrowed coracohumeral distance and a decreased coracoglenoid angle.

Limitations of the study are as follow. First, there was no dynamic imaging involving provocative maneuvers. Second, no radiological comparison of results with measurements in different plans was performed. Third, no correlation analysis was performed regarding MR arthrography of tendon tears. Fourth, interobserver variability could not be determined because the measurements were performed by a single radiologist. Nevertheless, the results of our study are meaningful. Additional comprehensive studies are required that involve evaluations on different plans and that include dynamic imaging and correlation of MRI arthrography.

## Conclusions

In this study, a new approach used the coracohumeral angle to evaluate subcoracoid impingement. The most valuable data of this study was the narrowed coracohumeral distance measurement. However, variabilities of coracoglenoid angle and coracohumeral angle between coracoid and subscapularis tendon groups are valuable for future studies. We predict that type C coracoid from coracoid types is an especially effective factor in subcoracoid impingement.

## Conflict of interest

None.

## References:

1. Brunkhorst JP, Giphart JE, LaPrade RF, Millett PJ: Coracohumeral distances and correlation to arm rotation: An *in vivo* 3-dimensional biplane fluoroscopy study. *Orthop J Sports Med*, 2013; 1(2): 2325967113496059
2. Osti L, Soldati F, Del Buono A, Massari L: Subcoracoid impingement and subscapularis tendon: is there any truth? *Muscles Ligaments Tendons J*, 2013; 3(2): 101–5
3. Kleist KD, Freehill MQ, Hamilton L et al: Computed tomography analysis of the coracoid process and anatomic structures of the shoulder after arthroscopic coracoid decompression: a cadaveric study. *J Shoulder Elbow Surg*, 2007; 16(2): 245–50
4. Friedman RJ, Bonutti PM, Genz B: Cine magnetic resonance imaging of the subcoracoid region. *Orthopedics*, 1998; 21(5): 545–48
5. Ashoor MMA, Hamed WM, Alfarsi HM et al: Relation between narrowed coracohumeral distance and subscapularis tears. *The Egyptian Journal of Hospital Medicine*, 2018; 70(7): 1164–68
6. Giaroli EL, Major NM, Lemley DE, Lee J: Coracohumeral interval imaging in subcoracoid impingement syndrome on MRI. *Am J Roentgenol*, 2006; 186(1): 242–46
7. Okoro T, Reddy VR, Pimpelnarkar A: Coracoid impingement syndrome: A literature review. *Curr Rev Musculoskelet Med*, 2009; 2(1): 51–55
8. Nair AV, Rao SN, Kumaran CK, Kochukunju BV: Clinico-radiological correlation of subcoracoid impingement with reduced coracohumeral interval and its relation to subscapularis tears in Indian patients. *J Clin Diagn Res*, 2016; 10(9): RC17–20
9. Dugarte AJ, Davis RJ, Lynch TS et al: Anatomic study of subcoracoid morphology in 418 shoulders: Potential implications for subcoracoid impingement. *Orthop J Sports Med*, 2017; 5(10): 2325967117731996
10. Watson AC, Jamieson RP, Mattin AC, Page RS: Magnetic resonance imaging based coracoid morphology and its associations with subscapularis tears: A new index. *Shoulder & Elbow*, 2017; 1758573217744170
11. Garavaglia G, Ufenast H, Taverna E: The frequency of subscapularis tears in arthroscopic rotator cuff repairs: A retrospective study comparing magnetic resonance imaging and arthroscopic findings. *Int J Shoulder Surg*, 2011; 5(4): 90–94
12. Narasimhan R, Shamse K, Nash C et al: Prevalence of subscapularis tears and accuracy of shoulder ultrasound in pre-operative diagnosis. *Int Orthop*, 2016; 40(5): 975–79
13. Radas CB, Pieper HG: The coracoid impingement of the subscapularis tendon: A cadaver study. *J Shoulder Elbow Surg*, 2004; 13(2): 154–59
14. Bennett WF: Subscapularis medial and lateral head coracohumeral ligament insertion anatomy: Arthroscopic appearance and incidence of “hidden” rotator interval lesions. *Arthroscopy*, 2001; 17(2): 173–80
15. Kim TK, Rauh PB, McFarland EG: Partial tears of the subscapularis tendon found during arthroscopic procedures on the shoulder: A statistical analysis of sixty cases. *Am J Sports Med*, 2003; 31(5): 744–50
16. Gerber C, Terrier F, Ganz R: The role of the coracoid process in the chronic impingement syndrome. *J Bone Joint Surg Br*, 1985; 67(5): 703–8
17. Freehill MQ: Coracoid impingement: Diagnosis and treatment. *J Am Acad Orthop Surg*, 2011; 19(4): 191–97
18. Garofalo R, Conti M, Massazza G et al: Subcoracoid impingement syndrome: A painful shoulder condition related to different pathologic factors. *Musculoskelet Surg*, 2011; 5(Suppl. 1): S25–29
19. Kragh J Jr., Doukas WC, Basamania CJ: Primary coracoid impingement syndrome. *Am J Orthop*, 2004; 33(5): 229–32
20. Arrigoni P, Brady PC, Burkhart SS: Calcific tendonitis of the subscapularis tendon causing subcoracoid stenosis and coracoid impingement. *Arthroscopy*, 2006; 22(10): 1139.e1131–33
21. Franceschi F, Longo UG, Ruzzino L et al: Arthroscopic management of calcific tendinitis of the subscapularis tendon. *Knee Surg Sports Traumatol Arthrosc*, 2007; 15(12): 1482–85
22. Oh JH, Song BW, Choi JA et al: Measurement of coracohumeral distance in 3 shoulder positions using dynamic ultrasonography: Correlation with subscapularis tear. *Arthroscopy*, 2016; 32(8): 1502–8
23. Richards DP, Burkhart SS, Campbell SE: Relationship between narrowed coracohumeral distance and subscapularis tears. *Arthroscopy*, 2005; 21(10): 1223–28
24. Hekimoglu B, Aydın H, Kızılgöz V et al: Quantitative measurement of humero-acromial, humero-coracoid, and coracoclavicular intervals for the diagnosis of subacromial and subcoracoid impingement of shoulder joint. *Clin Imaging*, 2013; 37(2): 201–10