

# A Novel Endoscopic Technique to Diagnose Gastric Cancer in Excluded Stomach after Roux-en-Y Gastric Bypass

Rashmi Kumar, MD, and Teodor C. Pitea, MD

*Division of Gastroenterology and Hepatology, University of Arizona College of Medicine/Banner University Medical Center, Phoenix, AZ*

## ABSTRACT

Access to the bypassed portion of the stomach after Roux-en-Y gastric bypass remains a challenge. We present a case of 64-year-old woman who presented with gastric outlet obstruction. We used a novel endoscopic technique to access the bypassed stomach by creating a jejunogastrostomy using a specialized stent, which allowed the insertion of a pediatric gastroscope to examine the bypassed portion of the stomach. Stomach biopsies revealed poorly differentiated adenocarcinoma with signet cell features.

## INTRODUCTION

Access to the bypassed portion of the stomach after Roux-en-Y gastric bypass (RYGB) can be a challenge using a conventional endoscopy method. In the literature, surgical exploration, retrograde endoscopy, percutaneous endoscopy by way of gastrostomy with a combined radiologic and endoscopic technique, and double-balloon enteroscopy (DBE) have been described as methods to access the bypassed portion of the stomach. A less-invasive technique is needed to access this portion of the stomach with a greater success rate.

## CASE REPORT

A 64-year-old woman presented to our hospital and reported 3 weeks of nausea and vomiting and 1 day of epigastric abdominal pain. She had undergone RYGB for morbid obesity 16 years ago. Computed tomography (CT) of the abdomen and pelvis with intravenous contrast revealed transmural thickening in the distal stomach and proximal duodenum, which caused a fluid-filled isolated gastric pouch. Esophagogastroduodenoscopy with endoscopic ultrasound (EUS) revealed a dilated and fluid-filled excluded stomach, which was suggestive of pyloric or duodenal obstruction. This raised a suspicion for gastric cancer. After a detailed discussion with the patient, we opted to use a novel endoscopic technique to perform a jejunogastrostomy under endosonographic guidance to access the excluded stomach as an alternative to surgical evaluation.

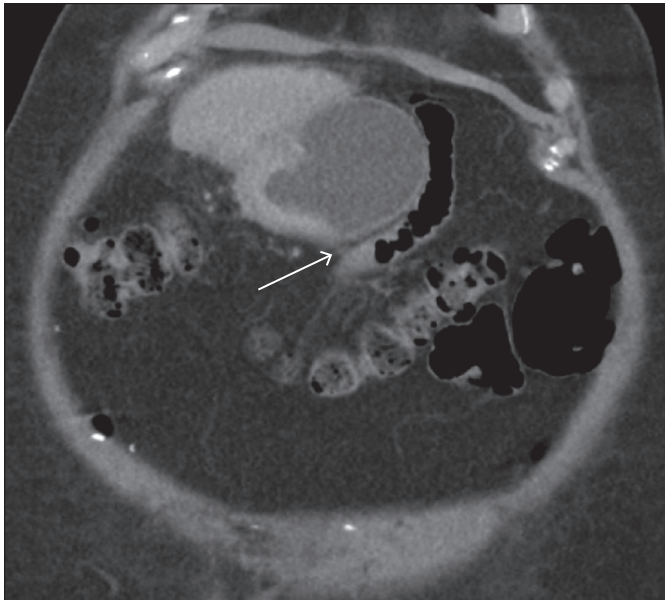
The jejunal loop was located close to the excluded stomach in the abdominal/pelvic CT (Figure 1). This site was chosen for jejunogastrostomy. The EUS scope was inserted in the jejunum, and the excluded stomach was visualized under endosonographic guidance. A jejunogastrostomy was created by placing a 15 mm fully covered metallic Axios stent using Axios electrocautery enhanced delivery system (Boston Scientific, Marlborough, MA; Figure 2). Fluid was aspirated from excluded stomach. The jejunogastrostomy was dilated to 10 mm using a Fusion Titan biliary dilation balloon (Cook Medical, Bloomington, IN). The scope was then replaced with a pediatric gastroscope, which was advanced through the Axios stent into the excluded stomach. A deep ulcer was found in the pylorus, in addition to pyloric stenosis and superficial ulcerations in the pre-pyloric region of the stomach (Figure 3). Biopsies taken from the margin of the superficial ulcerations in

ACG Case Rep J 2017;4:e36. doi:10.14309/crj.2017.36. Published online: March 15, 2017.

Correspondence: Rashmi Kumar, MD, Banner University Medical Center, 111 E McDowell Road, Phoenix, AZ 85006 (drkumar.rashmi@gmail.com).



Copyright: © 2017 Kumar et al. This work is licensed under a Creative Commons Attribution-NonCommercial-NoDerivatives 4.0 International License. To view a copy of this license, visit <http://creativecommons.org/licenses/by-nc-nd/4.0>.



**Figure 1.** Coronal abdominal/pelvic CT showing the jejunal loop close to the distended excluded stomach. This is the site chosen for jejunogastrostomy.

the pre-pyloric area revealed poorly differentiated adenocarcinoma with signet cell features. The procedure was performed in 16 minutes. Once the histologic diagnosis was made, the patient was referred for surgical evaluation.

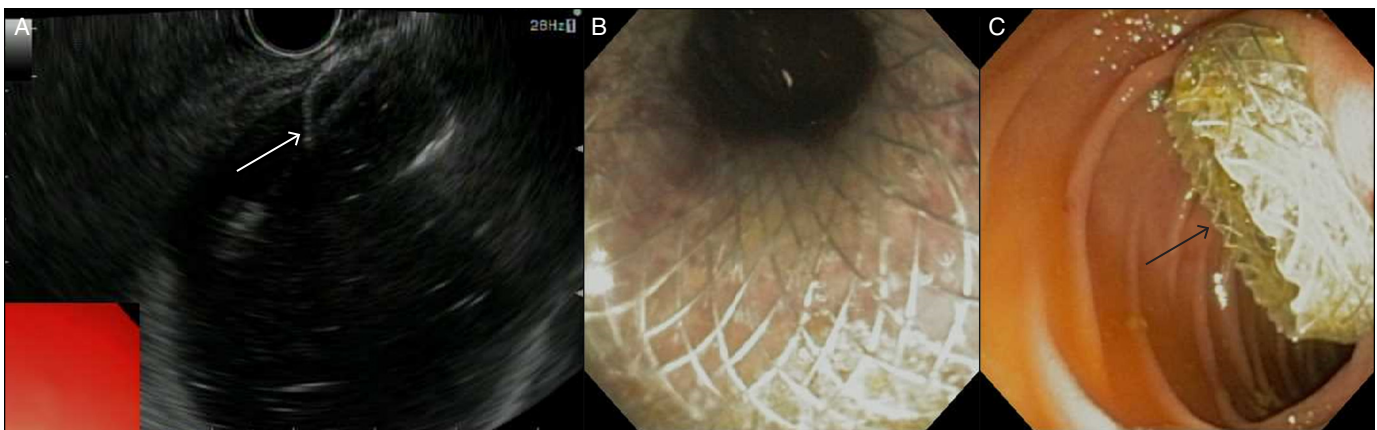
## DISCUSSION

According to data collected for the National Health and Nutrition Examination Survey (NHANES) between 2011 and 2012, the measured prevalence of obesity in adults in the United States is 34.9%.<sup>1</sup> The age-adjusted prevalence of morbid obesity (body mass index  $\geq 40$  kg/m<sup>2</sup>) was 6.3% in 2009 to 2010.<sup>2</sup> RYGB remains the most commonly performed bariatric procedure.<sup>3</sup> Although it is effective in reducing mortality

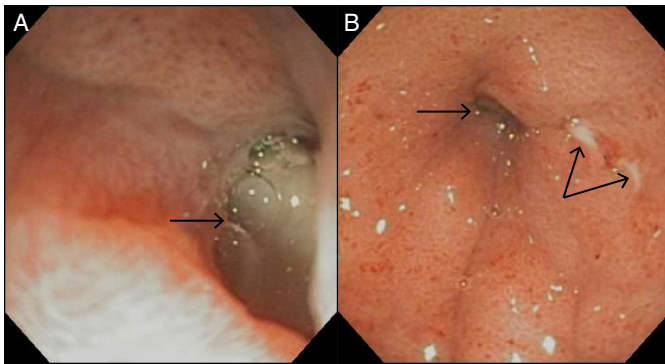
and morbidity related to morbid obesity, it creates a challenge for gastroenterologists in terms of endoscopic evaluation of the excluded duodenum, proximal jejunum, biliary tree, and stomach. Several techniques have been described to access the bypassed portion of the stomach, including surgical exploration, retrograde endoscopy, percutaneous endoscopy by way of gastrostomy with a combined radiologic and endoscopic technique, and DBE.<sup>4-9</sup>

Surgical exploration is invasive and comes with a risk of surgical complications. Retrograde endoscopy is cumbersome and time consuming, and it also has a low success rate. In two studies, retrograde endoscopy for the excluded stomach using a pediatric colonoscope had a success rate of 65–68%.<sup>10,11</sup> The low success rate is attributed to either the gastrojejunostomy being too narrow to insert the endoscope or an inability to advance the scope beyond the angulations of the jejunojejunostomy or ligament of Treitz. DBE has been used to reach the excluded stomach after RYGB, with success in 5 of 6 patients (83.3%).<sup>12</sup> The average time required to reach the excluded stomach was 38 min (range 18–60 min).<sup>12</sup> This procedure requires a use of an overtube, which may cause bowel injury during insertion. In addition, it demands the presence of assistant to manipulate the overtube. Percutaneous endoscopy with CT or US requires gastrostomy and may call for serial dilation before the endoscope can be introduced, which means this method cannot be used for immediate treatment of critical conditions like gastrointestinal bleeding. There is also a risk of postoperative pain and wound infection associated with this procedure.

We propose a novel endoscopic technique of creating a jejunogastrostomy using Axios electrocautery enhanced system to gain access to the excluded stomach after RYGB. This technique is less invasive than other methods, and can be completed in less time. This technique can also be used to facilitate difficult post-gastric bypass endoscopic retrograde



**Figure 2.** (A) EUS showing the inner flange of an Axios stent. Endoscopic view of the outer flange of the Axios stent (B) after deployment and (C) in the jejunum.



**Figure 3.** Endoscopic view of (A) a deep ulcer in pylorus and (B) superficial ulcerations and pyloric stenosis.

cholangiopancreatography (ERCP). So far, we have performed two successful ERCPs for choledocholithiasis using this novel technique. It appears to be safe, is less time consuming, and can be performed in an outpatient setting.

## DISCLOSURES

Author contributions: R. Kumar wrote the manuscript. TC Pitea reviewed the manuscript and is the article guarantor.

Financial disclosure: None to report.

Informed consent was obtained for this case report.

Received May 28, 2016; Accepted December 6, 2016

## REFERENCES

- Ogden CL, Carroll MD, Kit BK, Flegal KM. Prevalence of childhood and adult obesity in the United States, 2011–2012. *JAMA*. 2014;311:806.
- Flegal KM, Carroll MD, Kit BK, Ogden CL. Prevalence of obesity and trends in the distribution of body mass index among US adults, 1999–2010. *JAMA*. 2012;307:491.
- Samuel I, Mason EE, Renquist KE, Huang YH, Zimmerman MB, Jamal M. Bariatric surgery trends: An 18-year report from the International Bariatric Surgery Registry. *Am J Surg*. 2006;192(5):657–62.
- Gill KR, McKinney JM, Stark ME, Bouras EP. Investigation of the excluded stomach after Roux-en-Y gastric bypass: The role of percutaneous endoscopy. *World J Gastroenterol*. 2008;14(12):1946–8.
- Sundbom M, Nyman R, Hedenström H, Gustavsson S. Investigation of the excluded stomach after Roux-en-Y gastric bypass. *Obes Surg*. 2001;11(1):25–7.
- Tinoco A, Gottardi LF, Boechat ED. Gastric cancer in the excluded stomach 10 years after gastric bypass. *Case Rep Surg*. 2015;2015:468293. Epub 2015 Jul 1.
- Ceppa FA, Gagné DJ, Pappasavvas PK, Caushaj PF. Laparoscopic trans-gastric endoscopy after Roux-en-Y gastric bypass. *Surg Obes Relat Dis*. 2007;3(1):21–4.
- Fobi MA, Chicola K, Lee H. Access to the bypassed stomach after gastric bypass. *Obes Surg*. 1998;8(3):289–95.
- Tagaya N, Kasama K, Inamine S, et al. Evaluation of the excluded stomach by double-balloon endoscopy after laparoscopic Roux-en-Y gastric bypass. *Obes Surg*. 2007;17(9):1165–70.
- Sinar DR, Flickinger EG, Park HK, Sloss RR. Retrograde endoscopy of the bypassed stomach segment after gastric bypass surgery: Unexpected lesions. *South Med J*. 1985;78:255–8.
- Flickinger EG, Sinar DR, Pories WJ, Sloss RR, Park HK, Gibson JH. The bypassed stomach. *Am J Surg*. 1985;149:151–6.
- Sakai E, Kuga R, Safatle-Ribeiro AV, et al. Is it feasible to reach the bypassed stomach after Roux-en-Y gastric bypass for morbid obesity? The use of the double-balloon enteroscope. *Endoscopy*. 2005;37:566–9.