



Since January 2020 Elsevier has created a COVID-19 resource centre with free information in English and Mandarin on the novel coronavirus COVID-19. The COVID-19 resource centre is hosted on Elsevier Connect, the company's public news and information website.

Elsevier hereby grants permission to make all its COVID-19-related research that is available on the COVID-19 resource centre - including this research content - immediately available in PubMed Central and other publicly funded repositories, such as the WHO COVID database with rights for unrestricted research re-use and analyses in any form or by any means with acknowledgement of the original source. These permissions are granted for free by Elsevier for as long as the COVID-19 resource centre remains active.

*Corresponding author at: Department of Pathology, Wake Forest University, Atrium Health Wake Forest Baptist, Medical Center Boulevard, 27157 Winston-Salem, NC, USA.
E-mail address: akilic@wakehealth.edu (A. Kilic)

Received 25 October 2021

Accepted 10 December 2021

Available online 17 December 2021

<https://doi.org/10.1016/j.idnow.2021.12.006>

2666-9919 © 2021 Elsevier Masson SAS. All rights reserved.

Remarkable resolution of COVID-19-associated cerebral vasculitis with methylprednisolone



ARTICLE INFO

Keywords:
COVID-19
Vasculitis
Central nervous system

Although coronavirus disease 2019 (COVID-19) primarily manifests as a respiratory tract disease, reports of neurological complications are increasing [1,2]. The pathophysiology of central nervous system (CNS) injuries remains unclear. Data available suggest that endothelial lesions, coagulation disorders, and excessive inflammation are the primary mechanisms responsible for CNS manifestations. SARS-CoV-2 has limited potential for neuroinvasion, and immune complex-mediated mechanisms do not play a major role in the disease pathophysiology [3–5]. As a consequence, the management of COVID-19-related CNS manifestations is poorly defined. We report a case of CNS vasculitis in a critically ill patient with COVID-19, who dramatically improved with high-dose corticosteroids.

A 74-year-old man with no medical history presented with a 6-day history of fever, cough, and confusion. Breath sounds were diminished in the left lung with bilateral basilar crackles. Neurological examination was normal.

A nasopharyngeal swab for SARS-CoV-2 testing was positive by PCR. Chest computed tomography (CT) showed bilateral diffused ground-glass opacities. Brain CT was normal.

On day 4 after admission, he was transferred to the intensive care unit (ICU) because of acute respiratory distress syndrome (ARDS). He required invasive mechanical ventilation, sedation with midazolam and morphine for 7 days, neuromuscular blockade for 3 days, preventive anticoagulation with low molecular weight heparin, and antimicrobial treatment with cefotaxime and voriconazole. ARDS resolved, but the patient remained comatose for more than 48 hours following discontinuation of all sedative agents. Contrast-enhanced brain magnetic resonance imaging (MRI) revealed several acute ischemic strokes affecting different vascular territories, right sulcal acute subarachnoid hemorrhage, and multiple bilateral microbleeds (Fig. 1), highly suggestive of CNS vasculitis. Cerebrospinal fluid analysis showed white blood cell count of $9/\text{mm}^3$ and red blood cell count of $905/\text{mm}^3$; glucose level was 4.6 mmol/L (plasma glucose level, 6.2 mmol/L), and protein level was 0.24 g/L. No organism was observed on Gram stain and the culture was negative. PCR tests for SARS-CoV-2, herpes simplex virus, and varicella-zoster virus were negative.

There were no clinical arguments for systemic vasculitis. Renal and hepatic functions were preserved. Antinuclear antibodies, antineutrophil cytoplasmic antibodies, rheumatoid factor, angiotensin-converting enzyme, and blood cultures were negative. A slight alteration of lupus anticoagulant was detected but without anti-beta-2-glycoprotein or anti-cardiolipin, suggesting a false positivity not uncommon in critical care patients.

Intravenous methylprednisolone was started on day 14 (1 g/day for 3 days, and then 1 mg/kg/day). Twelve hours after methylprednisolone was initiated, the patient woke up and could be extubated. He was discharged from the ICU on day 24 on oral systemic corticosteroids. Neurological examination returned to normal on day 28 and was still unremarkable after 6 months.

This observation of COVID-19-associated CNS vasculitis is remarkable by the early and total recovery of neurological functions following initiation of high-dose corticosteroids. Of note, the patient was admitted before the benefit of dexamethasone was documented by the RECOVERY trial [6]. He therefore did not receive any corticosteroids before developing CNS vasculitis. Interestingly, Timmons et al. reported the only case of biopsy-confirmed CNS vasculitis that shortly followed a possible COVID-19 infection [7]. However, the authors were unable to confirm the infection because SARS-CoV-2 PCR testing was unavailable during the initial episode. The patient was treated with high-dose intravenous corticosteroids and improved. Several viruses may induce vascular inflammation or occlusion by immune complex-mediated mechanisms [8].

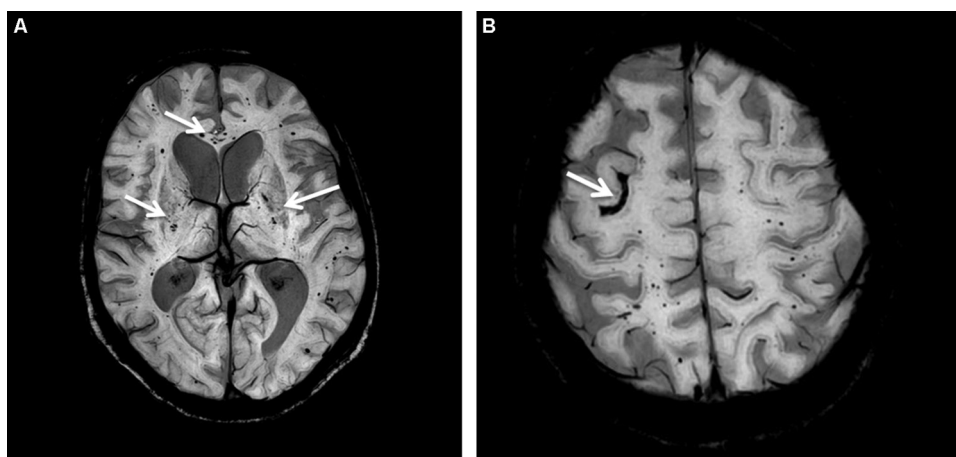


Fig. 1. Man, 74 years old. A. Axial susceptibility-weighted imaging: multiple bilateral microbleeds (arrows). B. Axial susceptibility-weighted imaging: right sulcal acute subarachnoid hemorrhage (arrow).

SARS-CoV-2-mediated disease is largely driven by immunological and inflammation processes, the primary drivers of morbidity and mortality. [3]. In children, SARS-CoV-2 has been associated with Kawasaki-like disease, a multisystem inflammatory syndrome, mostly related to extensive vasculitis of medium-caliber vessels [9]. Although less documented, similar mechanisms may explain CNS vasculitis in adult patients [10].

In the observation reported herein, introduction of high-dose corticosteroids was followed by remarkable recovery of the neurological function, which strengthens the hypothesis of an immune-mediated mechanism. Furthermore, the temporal sequence in our report and the absence of arguments for systemic vasculitis suggest that COVID-19 was the causal factor of CNS vasculitis. The non-specific neurological manifestations, especially in the ICU setting, highlight the importance of brain imaging to diagnose complications and to select an appropriate treatment. Corticosteroids might be the treatment of choice in patients with COVID-19-associated CNS vasculitis. Physicians should be aware of this severe complication associated with COVID-19 and of the potential benefit of high-dose corticosteroids.

Ethics approval and consent to participate

The patient gave his informed consent.

Consent to publish

The patient gave his informed consent.

Availability of data and materials

Not applicable.

Disclosure of interests

The authors declare that they have no competing interests.

Funding

This research did not receive any specific grant from funding agencies in the public, commercial, or not-for-profit sectors.

Authors' contributions

Soraya Benguerfi, Florian Reizine, Pierre Tattevin, and Adel Maamar conceived the study. François Eugène analyzed the MRI results

and selected Figure 1. All authors discussed the results and contributed to the final manuscript.

References

- [1] Meppiel E, Peiffer-Smadja N, Maury A, Bekri I, Delorme C, Desestret V, et al. Neurologic manifestations associated with COVID-19: a multicentre registry. *Clin Microbiol Infect* 2021;27(3):458–66.
- [2] Frontera JA, Sabadia S, Lalchan R, Fang T, Flusty B, Millar-Verneti P, et al. A Prospective study of neurologic disorders in hospitalized patients with COVID-19 in New York City. *Neurology* 2021;96(4):e575–86.
- [3] Ye Q, Wang B, Mao J. The pathogenesis and treatment of the 'Cytokine Storm' in COVID-19. *J Infect* 2020;80(6):607–13.
- [4] Solomon T. Neurological infection with SARS-CoV-2 - the story so far. *Nat Rev Neurol* 2021;17(2):65–6.
- [5] Thakur KT, Miller EH, Glendinning MD, Al-Dalahmah O, Banu MA, Boehme AK, et al. COVID-19 neuropathology at Columbia University Irving Medical Center/New York Presbyterian Hospital. *Brain* 2021;144(9):2696–708.
- [6] Col*itive Group RECOVERY, Horby P, Lim WS, Emberson JR, Mafham M, Bell JL, et al. Dexamethasone in hospitalized patients with Covid-19. *N Engl J Med* 2021;38(8):693–704.
- [7] Timmons GM, Rempe T, Bevins EA, Goodwill V, Miner A, Kavanaugh A, et al. CNS lymphocytic vasculitis in a young woman with COVID-19 infection. *Neuro Immunol Neuroinflamm* 2021;8(5):e1048.
- [8] Moore PM. Immune mechanisms in the primary and secondary vasculitides. *J Neurol Sci* 1989;93(2–3):129–45.
- [9] Verdoni L, Mazza A, Gervasoni A, Martelli L, Ruggeri M, Ciuffreda M, et al. An outbreak of severe Kawasaki-like disease at the Italian epicentre of the SARS-CoV-2 epidemic: an observational cohort study. *Lancet* 2020;395(10239):1771–8.
- [10] Younger DS, Coyle PK. Central nervous system vasculitis due to infection. *Neurol Clin* 2019;37(2):441–63.

S. Benguerfi^{a,*}
F. Reizine^a
F. Eugène^b
P. Tattevin^a
A. Maamar^a

^a CHU Rennes, Service de Maladies Infectieuses et Réanimation Médicale, Hôpital Pontchaillou, Université de Rennes 1, 2, rue Henri Le Guilloux, 35033 Rennes cedex 9, France

^b CHU Rennes, Service de Radiologie, Hôpital Pontchaillou, Université de Rennes 1, 2, rue Henri Le Guilloux, 35033 Rennes cedex 9, France

* Corresponding author.

E-mail address: soraya.benguerfi@gmail.com
(S. Benguerfi)

Available online 13 February 2022

<https://doi.org/10.1016/j.idnow.2021.12.006>

2666-9919 © 2022 Elsevier Masson SAS. All rights reserved.