

Lithotripsy in the Laparoscopic Era

Emanuele Lo Menzo, MD, PhD, Robert Schnall, MD, David Von Rueden, MD

ABSTRACT

Objectives: The overall prevalence of gallstones in the United States is between 10% and 15%. Eighty-five percent of common bile duct (CBD) stones can be removed by endoscopic sphincterotomy with basket or balloon extraction, or both. The introduction of mechanical lithotripsy improved the results up to 90%. We present one case of retained CBD stone after 2 failed endoscopic sphincterotomies and balloon/basket extraction treated by electrohydraulic lithotripsy (EHL).

Methods: A fifty-year-old man underwent ERCP for suppurative cholangitis. Because of the failure of stone extraction, he was taken to the operating room for an open cholecystectomy and CBD exploration. The intraoperative cholangiogram showed contrast flowing into the duodenum. Seven weeks later, the patient presented with mild pancreatitis, and a T-tube cholangiogram revealed a stone impacted in the distal CBD. Percutaneous balloon extraction was again unsuccessful.

Results: The patient underwent a single 2.5-hour session of EHL via the T-tube tract. Mild pulmonary edema occurred intraoperatively. Complete clearance of the CBD was obtained without the need for additional ERCP.

Conclusions: EHL is a valid and effective option for difficult retained common bile duct stones after failed ERCP.

Key Words: Lithotripsy, Retained common bile duct stones, Failed endoscopic retrograde cholangiopancreatography.

INTRODUCTION

The overall prevalence of common bile duct (CBD) stones in the United States is between 10% and 15%. Only 10% are primary common bile duct (CBD) stones, the rest being secondary to cholelithiasis.

The management of these CBD stones has changed significantly in the past 10 years. A major contribution to the change was the advent of laparoscopic CBD exploration. Many studies in the literature argue about the algorithm to follow for the diagnosis and treatment of CBD stones. Although some disagreement exists on the timing of endoscopic retrograde cholangiopancreatography (ERCP), there is no doubt that endoscopic sphincterotomy has a central role in the therapeutic process. When ERCP fails, other nonsurgical modalities are available, lithotripsy being one of them.

Moving from the presentation of 1 case of difficult retained CBD stone treated with electrohydraulic lithotripsy (EHL), we review the indications and complications of lithotripsy in the era of laparoscopic surgery.

METHODS

A fifty-year-old man was initially treated by ERCP for suppurative cholangitis. During the ERCP session, the patient became agitated, and the procedure was aborted after a simple sphincterotomy. A repeat session with the patient under general anesthesia was unsuccessful in removing the distal CBD stone (approximately 1 cm in size) because of the inability to manipulate and crush the stone. The following day, the patient underwent a laparoscopic exploration that had to be converted to open cholecystectomy due to the unclear anatomy. During the open procedure, the CBD was explored and 1 stone was extracted. The intraoperative cholangiogram revealed a retained stone in the distal CBD but flow of contrast in the duodenum (**Figure 1**). The patient was discharged with a T-tube in place. Seven weeks later, the patient presented with mild acute pancreatitis. The T-tube cholangiogram showed at least 1 stone impacted in the distal CBD (**Figure 2**). A percutaneous approach under fluoroscopy was at this point attempted, but it failed due to the inability to grasp the stone. A 16 Fr drain was left in the T-tube tract.

Lankenau Hospital, Wynnewood, Pennsylvania, USA (all authors).

Address reprint requests to: Emanuele Lo Menzo, MD, PhD, Cleveland Clinic Florida, Department of Surgery, 2950 Cleveland Clinic Blvd, Weston, FL 33331, USA. Telephone: 954 659 5508, Fax: 954 349 7661, E-mail: ELoMenzo@hotmail.com

© 2005 by JSLS, *Journal of the Society of Laparoendoscopic Surgeons*. Published by the Society of Laparoendoscopic Surgeons, Inc.

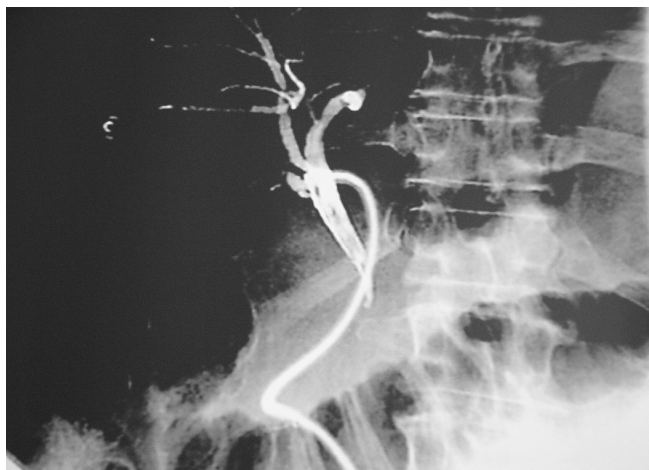

Figure 1. Intraoperative cholangiogram showing the flow of contrast into the duodenum.



Figure 2. The T-tube cholangiogram demonstrates the presence of at least 1 gallstone in the common bile duct.

At this point, the patient was taken to the operating room with the intention to perform EHL via the T-tube tract.

With the patient under conscious sedation, 2 wires were inserted through the T-tube tract under fluoroscopic guidance. The retained stone was confirmed to be approximately 2 cm above the ampulla. A flexible cholangioscope was introduced over the guidewire. Basket extraction was again attempted under direct vision. With some manipulation, the stone was freed from the bile duct wall. Subsequently, a 3 Fr EHL probe was passed through the working channel of the choledochoscope. Utilizing 80 W current, adequate fragmentation of the stone was obtained. During the process of stone fragment extraction,

the patient became agitated and hypoxic with signs of pulmonary edema and hence endotracheally intubated. A few more fragments were removed, and a cholangiogram revealed contrast flowing into the duodenum (**Figure 3**).

The patient was kept intubated overnight. At a 3-year follow-up, the patient was asymptomatic without evidence of recurrence.

DISCUSSION

One million new cases of choledocholithiasis are diagnosed every year in the United States. Contrary to what occurs in Asian countries, in the United States, the vast majority is secondary to cholelithiasis. Since the advent of laparoscopy and the improvement of the technique and the instruments for laparoscopic CBD exploration, the timing of ERCP has been debated.¹⁻³ Although the most experienced laparoscopist would reserve the ERCP for the few failed cases of laparoscopic CBD explorations, the surgeons not familiar with advanced laparoscopic techniques utilize ERCP preoperatively.

ERCP and sphincterotomy, introduced in 1974⁴ has been reported to be very successful (85%).⁵ The addition of mechanical lithotripsy in 1982 by Riemann⁶ improved the results to 90%. The failures are mostly due to the size of the stone and of the CBD and the anatomic conditions.

The options for retained CBD stones after failed ERCP include laparoscopic or open CBD exploration and lithotripsy. The results of chemical lithotripsy have been controversial and the technique is indigenous.⁷

Mondet⁸ introduced the concept of mechanical lithotripsy

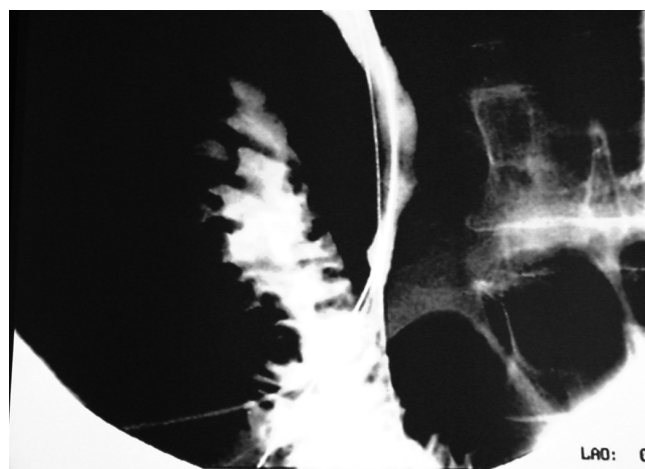


Figure 3. The T-tube cholangiogram after the lithotriptic session shows free flow into the duodenum and no residual calculi.

in 1962 when he described the extraction of a retained CBD stone via a T-tube tract with forceps. Thereafter, in 1972 Burhenne⁹ utilized fluoroscopy and a Dormia basket. It was not until 1975 that Sherman¹⁰ used a bronchoscope to remove a retained stone, starting the application of endoscopy to the biliary tract.

ESWL was first introduced for the treatment of nephrolithiasis.¹¹ Currently, ESWL in the biliary tract is mostly utilized for intrahepatic stones. The overall success for extrahepatic stones has been reported as high as 88% in the Sauerbruch¹² series.

The disadvantages include the high cost, the need for multiple sessions, and the need for anesthesia.

EHL was first introduced 15 years ago¹³ and is based on a waveform generated by electrical impulses between 2 poles of a probe. The energy usually required varies between 60 W and 100 W. A maximum number of impulses can be administered during each session, and the number derives from the lifespan of the probe (ie, 1000 impulses). After adequate fragmentation of the stone has been achieved, mechanical extraction of the bigger fragments follows. To get adequate results and to avoid damage to the bile ducts, a direct contact between the probe and the stone is necessary. For this reason, it is imperative to visualize the stone directly or by fluoroscopy. The continuous irrigation with saline solution enhances the effectiveness of the waves. Some of the irrigation solution is systemically absorbed and could result in fluid overload and pulmonary edema. Different access routes to the biliary tree can be utilized for the lithotriptic treatment: Perorally (duodenoscopic-assisted cholangioscopy with a mother-baby endoscope system), via a T-tube tract or via a percutaneous transhepatic approach.

The peroral technique is less invasive and does not require a complicated preparation, but necessitates 2 experienced endoscopists and it is technically challenging. Downsides of this technique are the durability of the instrument and the small caliber of the cholangioscope working port (5 Fr).

Both the transhepatic and T-tube tract techniques require a few weeks of progressive tract dilatation up to 16 Fr with all the potential complications associated with it (pain, bleeding, longstanding fistula). The overall success for EHL for retained CBD stones has been reported between 95% and 100%.^{14,15}

The youngest of the lithotripsy techniques, laser induced shock-wave lithotripsy (LISL), was introduced in 1986.¹⁶ It is based on the same principle as EHL with the difference

that the wave is produced by a laser (light amplification of stimulated emission of radiation) source. Over time, different types of laser light have been utilized. Initially, a continuous-wave laser (Nd:YAG) was used. It was soon noticed that this type tended to cause drilling in the stones instead of fragmentation. Currently, only pulsed laser systems are utilized. Two classes of lasers belong to this category: Pulsed solid-state¹⁷⁻¹⁹ (q-switched Nd:YAG, holmium:YAG) and flashlamp-pumped pulsed dye²⁰ (coumarin green 504 nm and rhodamine-6G 595 nm). The overall success rate with LISL has been reported between 80% and 95%.²⁰⁻²⁵ The recent introduction of the stone tissue detection system in Germany has made the direct extrahepatic stones visualization unnecessary. The system is based on the different fluorescence of the bile and the stone induced by a small amount of the laser energy. The recognition of such difference regulates an on-off mechanism on the laser pulse generator. The access routes for LISL are the same as for EHL (ie, peroral, transhepatic, via T-tube tract). The major drawback of LISL is the high cost.

In the case here reported, we used a single session of EHL after failure of ERCP extraction and retained stone after open CBD exploration.

The presence of a T-tube offered convenient access to the biliary tree. The above-mentioned tract had to be progressively dilated up to 16 Fr. This process was uneventful. Under direct cholangioscopic vision, the application of 80 W current via an EHL probe was sufficient to break the large stone into small fragments. Unfortunately, during the mechanical removal of the fragments, the patient developed pulmonary edema and had to be endotracheally intubated. This is a well-known complication of EHL and is due to the necessary continuous saline irrigation of the biliary tree to avoid thermal injury to the mucosa^{26,27} and to intensify the lithotriptic power.²⁸

CONCLUSIONS

Laparoscopic CBD exploration is becoming a popular procedure, but because of its technical complexity, it is not available to many experienced surgeons. Cases of difficult retained CBD stones after failed ERCP can still be treated with one of the lithotriptic modalities. The advent of a stone tissue detection system has made the laser lithotripsy safer.

References:

1. Chang L. Preoperative versus postoperative endoscopic retrograde cholangiopancreatography in mild to moderate gall-

- stone pancreatitis: a prospective randomized trial. *Ann Surg.* 2000;231(1):82–87.
2. Masci E. Selection criteria for pre-operative endoscopic retrograde cholangiography and endoscopic-laparoscopic treatment of biliary stones. *Eur J Gastroenterol Hepatol.* 1999;11(7):781–784.
 3. Bergamaschi R. Selective endoscopic retrograde cholangiography prior to laparoscopic cholecystectomy for gallstones. *Am J Surg.* 1999;178(1):46–49.
 4. Kawai K. Endoscopic sphincterotomy of the ampulla of Vater. *Gastrointest Endosc.* 1974;20(4):148–151.
 5. Ponsky JL. Endoscopic management of common bile duct stones. *World J Surg.* 1992;16:1060–1065.
 6. Riemann JF, Seuberth K, Demling L. Mechanical lithotripsy through the intact papilla of vater. *Endoscopy.* 1983;15(3):111–113.
 7. Thistle JL, May GR, Bender CE, et al. Dissolution of cholesterol gallstones by methyl-ter-butyl ether administered by percutaneous transhepatic catheter. *N Engl J Med.* 1989;320:633.
 8. Mondet A. Técnica de la extracción incruenta de los calculos en la litiasis residual del coledoco [abstract]. *Bol Soc B Air.* 1962;48:278–290.
 9. Burhenne HJ. Nonoperative retained biliary stone extraction. *Am J Roentgenol.* 1973;117:388–390.
 10. Sherman HI, Margeson RC, Davis RC Jr. Postoperative retained choledocholithiasis: percutaneous endoscopic extraction. *Gastroenterology.* 1975;68:1024.
 11. Chaussy C, Brendel W, Schmiedt E. Extracorporeally induced destruction of kidney stones by shock waves. *Lancet.* 1980;ii:1265–1268.
 12. Sauerbruch T, Stern M. Fragmentation of bile duct stone by extracorporeal shock waves. *Gastroenterology.* 1989;96:146–151.
 13. Sievert CE, Silvis SE. Evaluation of electrohydraulic lithotripsy as a mean of gallstone fragmentation in a canine model. *Gastrointest Endosc.* 1987;33:233–235.
 14. Binmoeller KF, Bruckner M, Thonke F, Soehendr N. Treatment of difficult bile duct stones using mechanical, electrohydraulic and extracorporeal shock wave lithotripsy. *Endoscopy.* 1993;25(3):201–206.
 15. Siegel JH, Ben-Zvi JS, Pullano WE. Endoscopic electrohydraulic lithotripsy. *Gastrointest Endosc.* 1990;36:134–136.
 16. Ell C, Wondrazek F, Frank F. Laser-induced shock wave lithotripsy of gallstones. *Endoscopy.* 1986;18:95–96.
 17. Hochberger J, Gruber E, Wirtz P. Lithotripsy of gallstones by means of a quality-switched giant-pulse neodymium:yttrium-aluminum-garnet laser. Basic in vitro studies using a highly flexible fiber system. *Gastroenterology.* 1991;101:1391–1398.
 18. Blomley MJ, Nicholson DA, Bartal G, et al. Holmium-YAG laser for gallstone fragmentation: An endoscopic tool. *Gut.* 1995;36:442–445.
 19. Neuhaus H, Hoffmann W, Zillinger C, Classen M. Laser lithotripsy of difficult bile duct stones under direct visual control. *Gut.* 1993;34:415–421.
 20. Ell C, Hochberger J, May A. Laser lithotripsy of difficult bile ducts stones by means of a Rhodamine 6G-laser and an integrated automatic stone-tissue detection system. *Gastrointest Endosc.* 1993;39:755–762.
 21. Jakobs R, Maier M, Kohler B, Riemann JF. Peroral laser lithotripsy of difficult intrahepatic and extrahepatic bile duct stones: laser effectiveness using an automatic stone-tissue discrimination system. *Am J Gastroenterol.* 1996;91(3):468–473.
 22. Kozarek RA, Low DE, Ball TJ. Tunable dye laser lithotripsy: in vitro studies and in vivo treatment of choledocholithiasis. *Gastrointest Endosc.* 1988;5:418–421.
 23. Ell C, Hochberger J, Miller D. Laser lithotripsy for common bile duct stones. *Gut.* 1988;29:746–751.
 24. Martin LG, Ambrose SS, Elias DL. Extracorporeal shock wave lithotripsy of intrahepatic stones. *Am Surg.* 1988;54:311–314.
 25. Bland KI, Jones RS, Maher JW. Extracorporeal shock-wave lithotripsy of the bile duct calculi: an interim report of the Dornier U.S. Bile Duct Lithotripsy Prospective Study. *Ann Surg.* 1989;209:743–745.
 26. Harrison J, Morris DL, Haynes J. Electrohydraulic lithotripsy of gallstones in vitro and animal studies. *Gut.* 1987;28:267–271.
 27. Sievert CE, Silvis SE. Evaluation of electrohydraulic lithotripsy on human gallstones. *Am J Gastroenterol.* 1985;80:854.
 28. Siegel JH, Ben-Zvi JS, Pullano WE. Mechanical lithotripsy of common duct stones. *Gastrointest Endosc.* 1990;36:351–356.