

Simultaneous lead extraction and vacuum-assisted vegetation removal



Ziad F. Issa, MD, FHRS, Nilesh J. Goswami, MD

From the Prairie Heart Institute, Springfield, Illinois.

Introduction

The incidence of infection associated with cardiac implantable electronic devices (CIEDs) is rising at a rate faster than that of the number of implants.¹ CIED infections typically require complete device and lead removal. The prevalence of vegetations is high in patients with infective indications who are referred for lead extraction.² Because of the risk of hemodynamically significant pulmonary embolism associated with percutaneous lead extraction techniques, management of those with large lead vegetations continues to be challenging. Often, patients with vegetations larger than 20 mm in diameter are referred for consideration of open surgical lead extraction and debridement.^{2–6}

We report a case of a patient with large lead vegetations in whom percutaneous lead extraction was performed with concomitant percutaneous removal of the vegetations using the AngioVac aspiration system (AngioDynamics Inc, Latham, NY).

Case report

An 81-year-old woman with a history of severe nonischemic dilated cardiomyopathy, paroxysmal atrial fibrillation, ventricular tachycardia, and implantation of single-chamber ventricular implantable cardioverter-defibrillator (ICD) (St Jude Medical Ellipse VR 1311-36Q; right ventricular lead: St Jude Medical Riata 1580, St Paul, MN) more than 10 years ago and upgrade to a biventricular ICD (St Jude Medical Unify CD3231-40Q; left ventricular lead: St Jude Medical Quickflex1258T; right atrial lead: St Jude Medical Tendril 1888TC) 4 years ago presented with a 1-week history of flu-like symptoms, fever, and chills. She was found to have persistent *Streptococcus bovis* bacteremia. Transesophageal echocardiography showed a large, mobile mass measuring 46 × 25 mm attached to the ICD right ventricular lead at the level of the tricuspid valve (Figure 1). Open surgical

lead extraction was expected to be associated with prohibitively high operative risk. Therefore, percutaneous lead extraction was planned with concurrent debulking and aspiration of the vegetations using the AngioVac aspiration system.

The procedure was performed in a hybrid cardiac catheterization laboratory under general anesthesia. A 26F sheath (Check-Flo Sheath; W.L. Gore & Associates, Flagstaff, AZ) was placed in the right femoral vein, and a 16F reinfusion cannula was inserted percutaneously in the right internal jugular vein for the return venous cannula. The AngioVac cannula (Vortex Medical, Norwell, MA) was advanced via the femoral vein into the right atrium over a stiff guide wire, and a standard balloon inflation device was used to open the balloon-actuated funnel tip. Intravenous unfractionated heparin was administered to maintain activated coagulation time at 300–400 seconds. Using the EN Snare endovascular snare system (Merit Medical, South Jordan, UT), a large vegetation was removed under transesophageal echocardiography guidance (Figure 2; Movie 1, available online) and then pulled back to the AngioVac device, where it was successfully suctioned off and removed and trapped in the filter (Figure 3).

Then, the ICD right ventricular lead was unscrewed from the myocardium and a long locking stylet was passed into this lead. A laser-powered sheath (SLS II Excimer Laser Sheath; Spectranetics, Colorado Springs, CO) was advanced over the lead under fluoroscopy guidance. As the laser sheath neared the superior vena cava, the lead tip was freed with countertraction. Subsequently, a 20 mm gooseneck snare was advanced (from the femoral vein) around the freed end of the ventricular lead and as far as it could reach up the body of the lead. The snare was then tightened on the lead and moved toward the lead tip to “strip” the lead from attached vegetations (Figure 2B; Movie 2, available online). Lead extraction was performed while AngioVac suction was active. The same procedure was repeated for the atrial and left ventricular leads.

The patient’s symptoms resolved within 24 hours. She had no clinical evidence of pulmonary embolism, and she was discharged from the hospital within a few days with a wearable external defibrillator. A new biventricular ICD system was implanted on the opposite side after completion

KEYWORDS Lead infection; Vegetation aspiration; Lead extraction

ABBREVIATIONS CIED = cardiac implantable electronic device; ICD = implantable cardioverter-defibrillator (Heart Rhythm Case Reports 2016;2:17–19)

Address reprint requests and correspondence: Ziad Issa, Prairie Cardiovascular Consultants, 619 East Mason St, Springfield, IL 62701. E-mail address: zissa@prairieheart.com.

KEY TEACHING POINTS

- Lead vegetations are common in patients with infected cardiac devices.
- Large lead vegetations can prohibit percutaneous lead extraction owing to high risk of severe pulmonary embolism.
- Use of the AngioVac aspiration system performed simultaneously with percutaneous lead extraction can present an acceptable alternative to open surgical lead extraction in these patients.

of antibiotic therapy and confirmation of complete resolution of infection. Colonoscopy revealed precancerous colonic polyps.

Discussion

The rate of CIED utilization has been rising over the past decade, and the incidence of CIED-related infections has been increasing at an even faster rate.¹ Complete device and lead removal is recommended (class IA) in patients with definite CIED infection. Those patients usually have a high prevalence of lead vegetations. While percutaneous lead extraction techniques are generally safe and feasible in patients with small vegetations,⁶ the risk of massive, hemodynamically significant pulmonary embolism in those with large vegetations is usually prohibitive for the percutaneous techniques and requires referral for open surgical lead extraction and debridement.²⁻⁴

The AngioVac aspiration system is a catheter-based technique that allows suction, filtering, and reinfusion of blood, and has been used for removal of unwanted intravascular material, such as central venous thrombi and

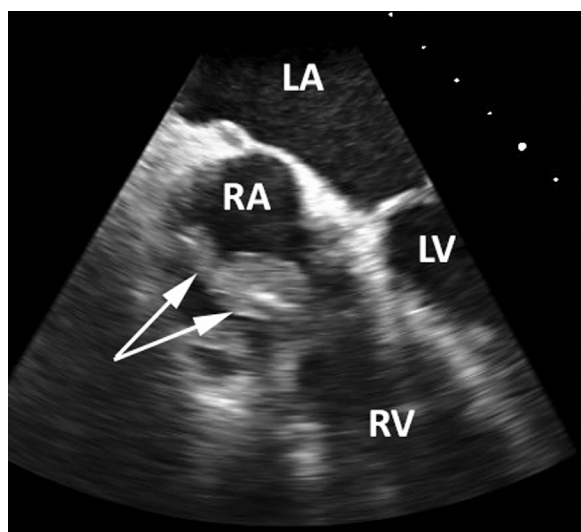


Figure 1 Transesophageal echocardiography showing a large vegetation (arrows) measuring 46 25 mm attached to the implantable cardioverter-defibrillator right ventricular lead at the level of the tricuspid valve. LA = left atrium; LV = left ventricle; RA = right atrium; RV = right ventricle.

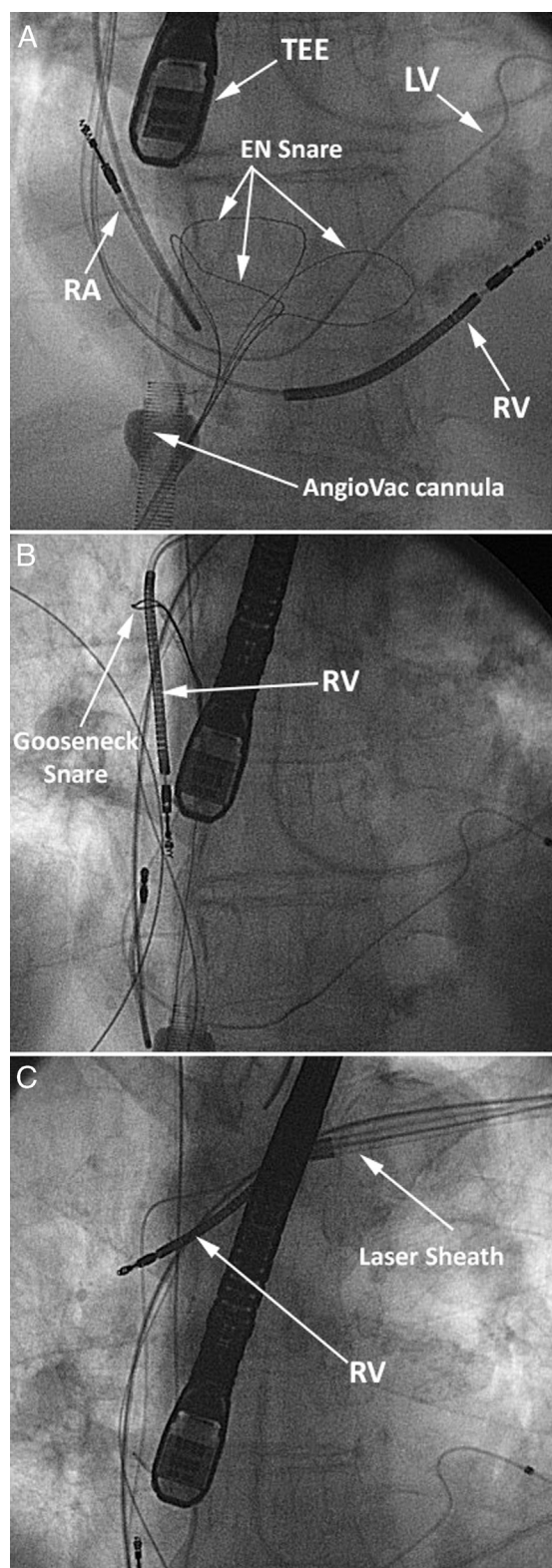


Figure 2 Fluoroscopy images (anteroposterior view) during simultaneous vegetation removal and lead extraction. **A:** The AngioVac cannula is positioned at the low right atrium (RA). The EN Snare is used to debulk the vegetation off the right ventricular implantable cardioverter-defibrillator lead (RV), under transesophageal echocardiography (TEE) guidance. **B:** Once the RV lead tip is freed with countertraction during laser extraction, a 20 mm gooseneck snare is used to "strip" the lead from attached vegetations. **C:** Lead extraction was completed while AngioVac suction was active. LV = left ventricular lead.

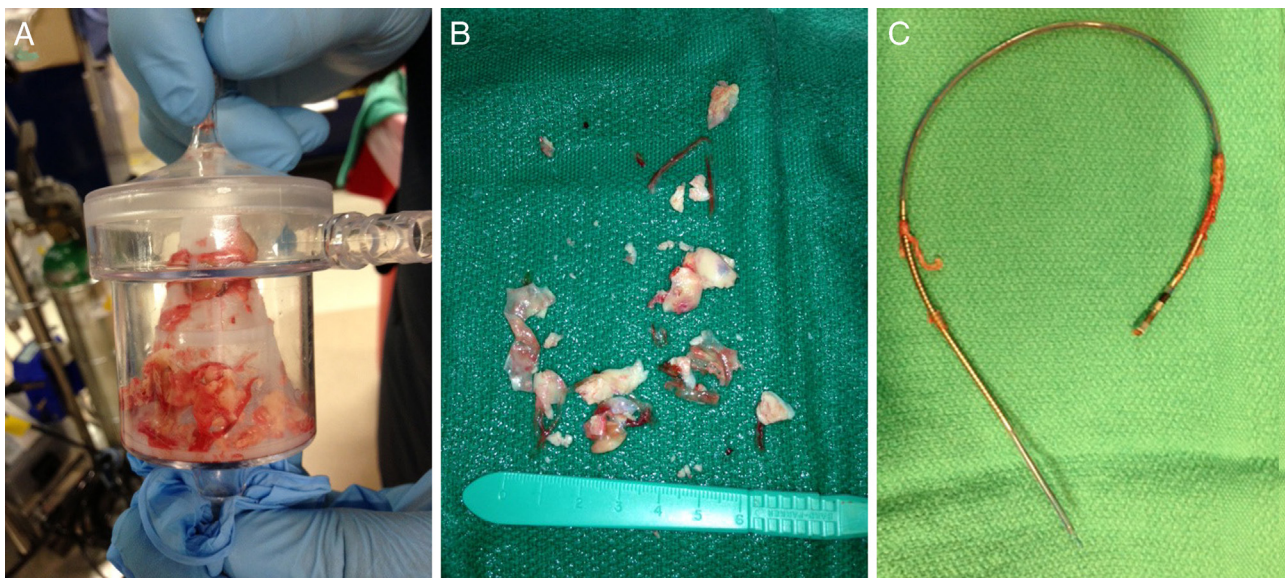


Figure 3 A: AngioVac filter filled with pieces of the vegetations suctioned via the AngioVac cannula. B: Vegetation removed from the AngioVac filter. C: The extracted implantable cardioverter-defibrillator right ventricular lead.

vegetations. The AngioVac circuit consists of a centrifugal pump and console, standard extracorporeal bypass tubing, and a filter. The inflow component of the circuit is connected to the proximal end of the AngioVac cannula, while the outflow component is connected to a reinfusion venous cannula. The AngioVac cannula has a balloon-actuated, funnel-shaped distal tip. Adjustable suction is applied to the tip of the AngioVac cannula, to facilitate venous drainage and removal of unwanted intravascular material. The blood is filtered during extracorporeal bypass (thereby removing unwanted intravascular material) and is then returned to the venous system via the reinfusion cannula.

To our knowledge, there has been no case reported in the literature regarding concomitant percutaneous lead extraction and AngioVac removal of large vegetations. Patel et al⁷ reported the successful use of the AngioVac cannula for the removal of large lead vegetations as a bridge to allow for percutaneous lead extraction in a separate session. In contrast, in our case, both vegetation removal and lead extraction were performed simultaneously. We believe our approach can further enhance procedural efficacy in removal of unwanted debris and reduce the risk of pulmonary embolism at the time of lead extraction.

Appendix

Supplementary data

Supplementary material cited in this article is available online at <http://dx.doi.org/10.1016/j.hrcr.2015.08.008>.

References

1. Cabell CH, Heidenreich PA, Chu VH, Moore CM, Stryjewski ME, Corey GR, Fowler VG. Increasing rates of cardiac device infections among Medicare beneficiaries: 1990-1999. *Am Heart J* 2004;147:582-586.
2. Golzio PG, Fanelli AL, Vinci M, Pelissero E, Morello M, Grosso Marra W, Gaita F. Lead vegetations in patients with local and systemic cardiac device infections: prevalence, risk factors, and therapeutic effects. *Europace* 2013;15:89-100.
3. Jones SO, Eckart RE, Albert CM, Epstein LM. Large, single-center, single-operator experience with transvenous lead extraction: outcomes and changing indications. *Heart Rhythm* 2008;5:520-525.
4. Hamid S, Arujuna A, Ginks M, McPhail M, Patel N, Bucknall C, Rinaldi C. Pacemaker and defibrillator lead extraction: predictors of mortality during follow-up. *Pacing Clin Electrophysiol* 2010;33:209-216.
5. Wilkoff BL, Love CJ, Byrd CL, Bongiorni MG, Carrillo RG, Crossley GH, Epstein LM, Friedman RA, Kennergren CEH, Mitkowski P, Schaerf RHM, Wazni OM. Transvenous lead extraction: Heart Rhythm Society expert consensus on facilities, training, indications, and patient management: this document was endorsed by the American Heart Association (AHA). *Heart Rhythm* 2009;6:1085-1104.
6. Birgersdotter-Green UM, Pretorius VG. Lead extractions: indications, procedural aspects, and outcomes. *Cardiol Clin* 2014;32:201-210.
7. Patel N, Azemi T, Zaem F, Underhill D, Gallagher R, Hagberg R, Sadiq I. Vacuum assisted vegetation extraction for the management of large lead vegetations. *J Card Surg* 2013;28:321-324.