

Free Medial Plantar Flap Connection with a Posterior Tibial Artery Flap in Reconstruction of Fore–Mid Foot Skin Defect

Hao Wu, MD
Jia-Gen Sheng, MD
Chang-Qing Zhang, MD, PhD

Background: Although there are many surgical treatments for covering the skin defect of the fore–mid foot, how to reconstruct the weight-bearing region remains a challenge. The weight-bearing region of the sole needs to withstand the pressure and shearing stresses of walking, so the plantar skin is anatomically different from other skins in the areas of texture, thickness, subcutaneous tissue, etc. Medial plantar flaps that are harvested from the instep region are regarded as the first choice for weight-bearing region reconstruction because of their excellent functional and aesthetic long-term result. However, when facing an extensive skin defect on a weight-bearing area such as a fore–mid foot avulsion, the application of this flap is limited because if we put the flap in a weight-bearing area of the forefoot, the set of vessels will be exposed to outside.

Methods: We suggest 2 connected free flaps (posterior tibial artery flap and medial plantar flap) pedicled with 1 set of vessels. The medial plantar flap was used to cover the skin defect of the weight-bearing area in the forefoot. The dorsal skin defect of the injured foot was covered with a posterior tibial artery flap and supplied the medial plantar flap with the posterior tibial vessel. The midfoot skin defect was repaired by a full-skin grafting.

Results: Long-term follow-up results showed that the shape and function of the injured limbs recovered almost entirely.

Conclusion: This method of connected flaps is suitable for repairing large skin defects of the fore–mid foot. (*Plast Reconstr Surg Glob Open* 2016;4:e1091; doi: 10.1097/GOX.0000000000001091; Published online 28 November 2016.)

Skin loss of the fore–mid foot is rare in clinical practice. It causes a large raw surface from dorsum to planta pedis and presents a technical challenge to the reconstructive surgeon. Reconstruction of a weight-bearing region remains a challenge: skin grafting cannot provide permanent coverage of the weight-bearing region, so it is not an optimal choice. Flaps are usually used to cover such a large wound. There are many kinds of flaps to choose, and meanwhile, there are many controversies on the prognosis of the weight-bearing region.^{1–6} Nevertheless, the flap harvested from the instep region of the

foot is regarded as the first choice for weight-bearing region reconstruction. However, as this flap is developed to repair moderate-sized defects of the plantar region, even the free-flap skill is difficult to use in such large, traumatic defects.^{7–10}

We designed a free posterior tibial artery flap connected with the medial plantar artery flap for repairing such large skin defects. The curative effects are satisfactory.

ANATOMIC BASIS (FLAP DESIGN)

The posterior tibial artery goes down along the spatum intermusculare between the flexor digitorum longus muscle and soleus muscle distally. At this level, it gives off several cutaneous perforators for nourishing the medial skin of the shank. The posterior tibial artery divides into the medial and lateral plantar artery branches before entering the tarsal tunnel. The medial plantar artery travels between the abductor hallucis and flexor digitorum brevis, continues along the medial border of the foot, and

From the Department of Orthopedics, Shanghai Jiao Tong University Affiliated Sixth People's Hospital, Shanghai, China.

Received for publication August 2, 2016; accepted August 29, 2016.

Copyright © 2016 The Authors. Published by Wolters Kluwer Health, Inc. on behalf of The American Society of Plastic Surgeons. All rights reserved. This is an open-access article distributed under the terms of the Creative Commons Attribution-Non Commercial-No Derivatives License 4.0 (CCBY-NC-ND), where it is permissible to download and share the work provided it is properly cited. The work cannot be changed in any way or used commercially without permission from the journal.

DOI: 10.1097/GOX.0000000000001091

Disclosure: The authors have no financial interest to declare in relation to the content of this article. The Article Processing Charge was paid for by the authors.

then anastomoses with the first plantar metatarsal artery. Perforating branches from the medial plantar artery run through the spatium between the abductor hallucis muscle and the plantar aponeurosis and provide cutaneous blood supply to the instep region. The medial plantar nerve runs laterally to the isonym vessel, giving off cutaneous branches to dominate the skin around the medial planta and toes. The esthesia of the medial tarsus area is mainly dominated by branches of the saphenous nerve.

OPERATIVE TECHNIQUE

Preparation of the Recipient Site

Debridement was carried out carefully to protect the synovial membrane around the extensor digitorum muscle for the purpose of later skin grafting. The distal parts of the phalangeal bones were amputated at the level of the proximal interphalangeal joint. The residual end of flexor digitorum longus was sutured to its sheath. The dorsal pedal artery and the great saphenous vein should be found and marked at the proximal end of the raw surface. The first and fourth digit nerves should be separated carefully at the base of the plantar for further use.

Flap Design and Harvest

The contralateral limb was used as the donor site. The medial plantar flap was designed in the instep area. The length of the flap was approximately the same as the width of the forefoot plate of the healthy foot. The posterior tibial artery flap was designed along the axial ray, and the width ranged from the medial border of the tibia to the posterior midline of the shank.

The Posterior Tibial Artery Flap Should Be Harvested First

The flap should be lifted from forward to backward along the posterior border of the tibia, and then, the posterior tibial artery and its cutaneous branches could be found at the intermuscular spatium between the flexor digitorum longus and soleus; then, the flap should be set free from backward to forward. The great saphenous vein should be dissected carefully, and its branches for the use of repairing the severed posterior tibial artery trunk laterally should be ligated. It is recommended to ligate the great saphenous vein from the medial malleolus to the popliteal fossa. Usually, a suitable branch could be found at the popliteal fossa level, so its inner diameter matches well with the lateral plantar artery. The saphenous nerve should be kept in the middle of the flap.

Instep Flap

The flap should be lifted at its medial border first. The branches of the saphenous nerve should be searched, which are implanted in the flap around the tubercle of the scaphoid bone; then, the nerve toward the proximal end should be separated and cut it off. Dissecting of the flap to the lateral margin of the abductor hallucis should be continued. Then, the flap from the lateral border should be dissected and lifted along the deep layer of the plantar aponeurosis. Superficial branches of the medial artery and

the medial plantar nerve lie in the space between the aponeurosis and the abductor hallucis. Branches of the medial plantar nerve should be separated and severed at their proximal end for later use. The neuromuscular branches of the abductor hallucis should be protected carefully. The medial plantar artery should be separated continuously proximally; the ankle tunnel along the course of posterior the tibial artery should be opened; and lateral plantar artery and accompanying veins, the deep branch of the medial plantar artery and accompanying veins, and other small branches of posterior tibial artery and accompanying veins should be ligated. This section of posterior tibial vessels is treated as a bridge connecting instep flap with a medial flap of lower leg. The medial plantar nerve, the lateral plantar nerve, and the medial heel nerve should be preserved carefully. Then, the posterior tibial artery and its accompanying vein should be set free from the distal to the proximal end. The in-lined posterior tibial artery flap and medial plantar flap should be harvested. The pedicle should be cut it off, and the connected flap should be set free when reviewing the hemoperfusion well. Then, the graft at the proximal end of the posterior tibial artery to the proximal end of the lateral plantar artery should be bridged with the overturned great saphenous vein.

Flap Transplant

The in-lined flap should be moved to the recipient site. The medial plantar flap should be arranged across the forefoot and fixed to metatarsophalangeal joints. The internal vascular pedicle goes through the web space to the dorsum of the foot. The posterior tibial artery flap should be adjusted, its distal part with the medial plantar flap should be sutured, and the internal vascular pedicle should be covered. The posterior tibial artery and the accompanying veins to the dorsal vessels of the foot end to end with a 9-0 silk suture should be anastomosed.

Repair the Nerve

The medial cutaneous nerve of the plantar flap was anastomosed with the first proper digital nerve; the distal cutaneous branch of the saphenous nerve was anastomosed with fourth proper digital nerve; the saphenous nerve on the posterior tibial artery flap was anastomosed with the intermediate dorsal cutaneous nerve of the foot.

The wound surface of the middle plantar and the donor site should be covered with skin grafting.

CLASSIC CASE

A 43-year-old patient suffered a severe traffic accident in 2009. The skin of the fore-mid foot was avulsed with tendon exposure. One week following the debridement of the wound and continuous negative pressure drainage, the raw surface was repaired with a posterior tibial artery flap connected with a medial plantar flap under epidural anesthesia. The flap survived very well. A 7-year follow-up showed an ideal outlook, soft texture, good weight-bearing capacity, and S3+ sensation. The flap was well integrated into the plantar surface of the forefoot, and the donor site showed a stable skin cover. The patient walks 5

km for work every day without any discomfort, even when the temperature is around -20° in the winter (Figs. 1–4).

Gait analysis of plantar pressure distribution was performed 7 years after surgery with the Footscan balance system (RSscan, Paal, Belgium). The patient walked over the platform at his normal walking speed; the peak pressure, maximum force, and gait cycle were recorded for both feet. Static plantar pressure measurement revealed less pressure distribution at the reconstructed foot, which means that the patient is unconsciously protecting the injured limb. Dynamic plantar pressure distribution measurement shows the same walking speed and contact time, which means there are no differences in the gait pattern. The elevated peak pressures at the forefoot reflected residual deformities of the injured foot, which indirectly proved that the reconstructed foot was full weight bearing (Figs. 5 and 6).

DISCUSSION

Characteristics and Repairing Methods of Fore–Mid Foot Skin Defects

The skin defect of the fore–mid foot is usually caused by degloved avulsion. This severe injury often makes an extensive skin defect; the skeleton brace is usually intact, whereas nerve, tendon, and blood vessels are always exposed.

One treatment method for this wound is to amputate the forefoot, turn the raw soft tissue of planta over to cover the dorsum part of the residual foot, and then perform a skin transplantation. The main drawback of this tech-

nique is that it may easily lead to a skin ulcer of the plantar. One important factor for weight-bearing repair is it must have protective sensation; the other is that it should have the proper amount of soft tissue to buffer stress. Skin grafting in a weight-bearing region cannot fit the above requirements. Flap transplantation can help to save the length of the wounded foot and reconstruct the protective sensation of the plantar. Microrepairing for this kind of injury can be separated into 2 categories: one is repairing the plantar part with a flap while the dorsum of the foot was covered with skin grafting, and the other is to use a large scale flap or double flaps to cover the whole raw surface. No matter what kind of operation program is used, repairing the raw surface of a weight-bearing area with a neurosensory flap is widely accepted by the surgeons.

Flap Selection

Many kinds of flaps can be selected to repair a fore–mid foot skin defect. When choosing the flap, the following points should be considered: (1) the flap should be large enough to cover the wound that is not suitable for skin grafting; (2) the flap should contain sensory nerves for protective sensation; (3) the flap for repairing the plantar part should have the proper amount of soft tissue but not clumsy, and (4) the donor site should have less damage.

The more adjacent to the anatomy region, the more similar characteristic of the skin will be achieved. Among the various kinds of flaps for repairing a weight-bearing region, the medial plantar flap, also known as the instep flap, is regarded as the first choice for weight-bearing area reconstruction. It is limited by the finite size, the severity

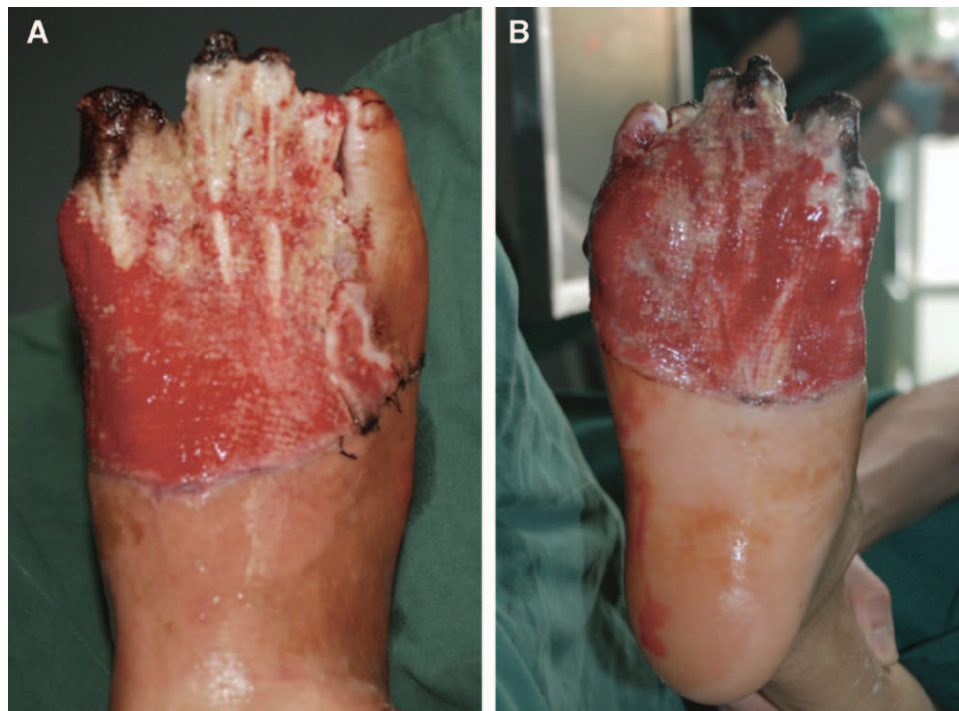


Fig. 1. One week after debridement, soft tissue of the fore–mid foot defect, the granulation tissue on the wound was fresh and flat. Dorsal view (A) and plantar view (B).

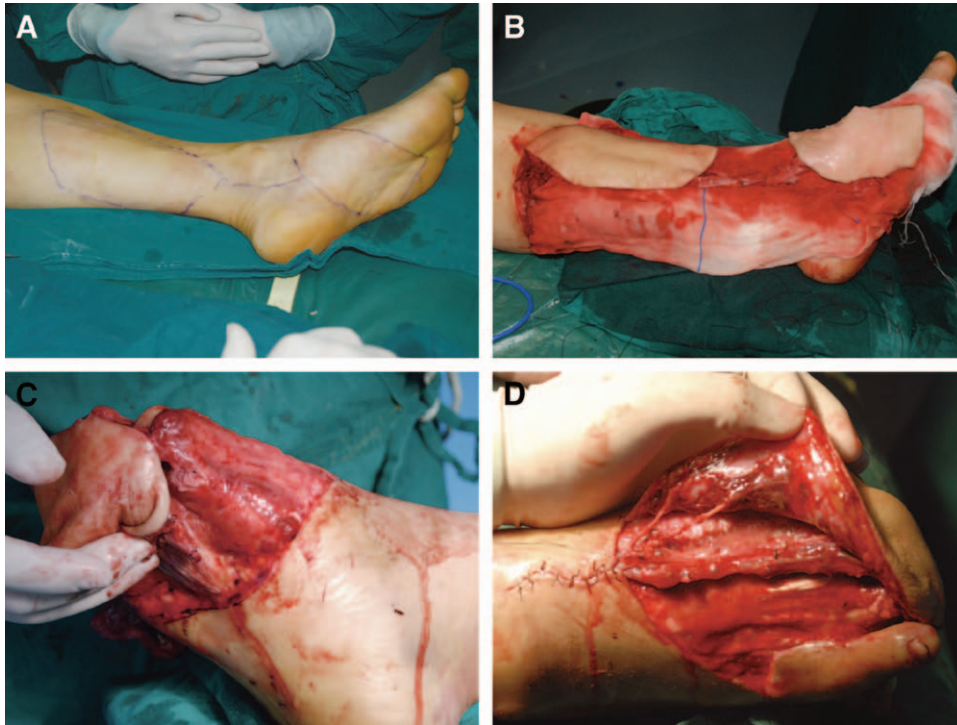


Fig. 2. Free medial plantar flap connect with posterior tibial artery flap harvest and transfer. Flap design (A), flap harvest (B), anastomosis of plantar flap nerves (C), and anastomosis of dorsal flap vessels and nerves (D).

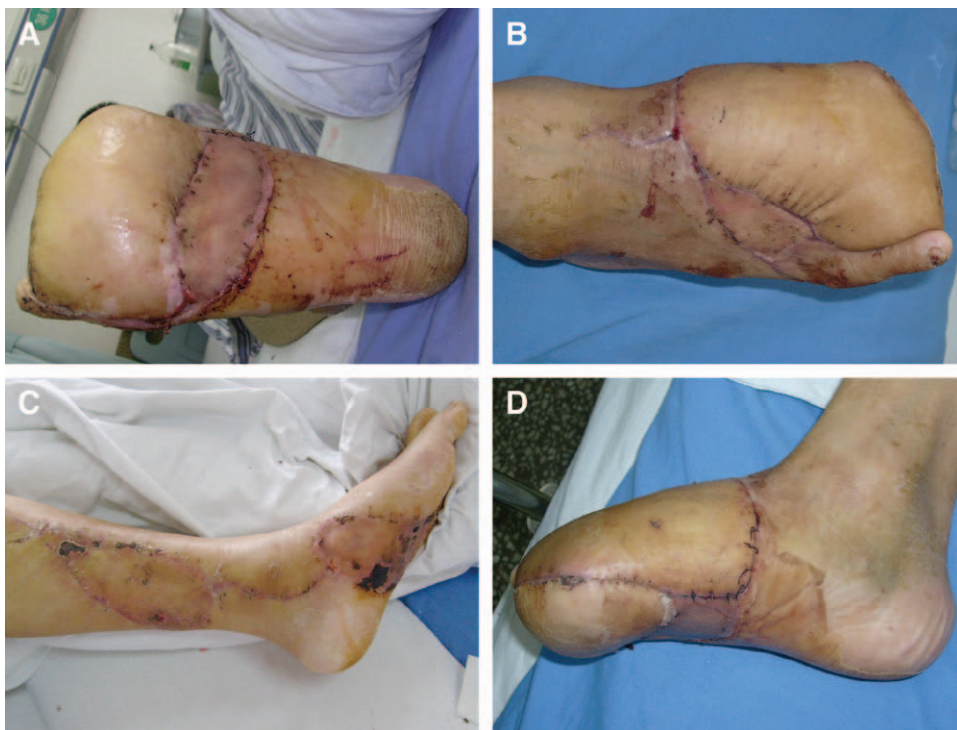

Fig. 3. Two weeks after operation. Plantar view (A), dorsal view (B), donor site (C), and lateral view (D).

of trauma, and the peripheral vessel condition.¹⁰⁻¹² When facing large skin defects such as a raw surface from the forefoot to the midfoot, it can only cover the fore plan-

tar. In such a case, the use of this option may be given up. Surgeons usually choose a supramaximal flap or skin grafting instead.

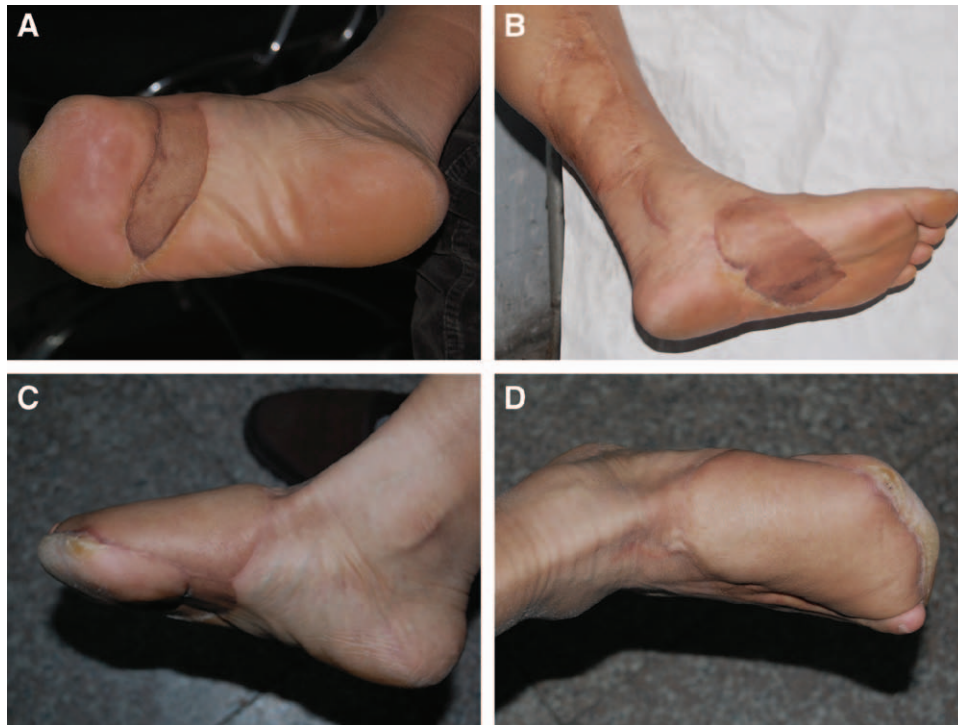


Fig. 4. Seven years after operation. Plantar view (A), donor site (B), lateral view (C), and dorsal view (D).

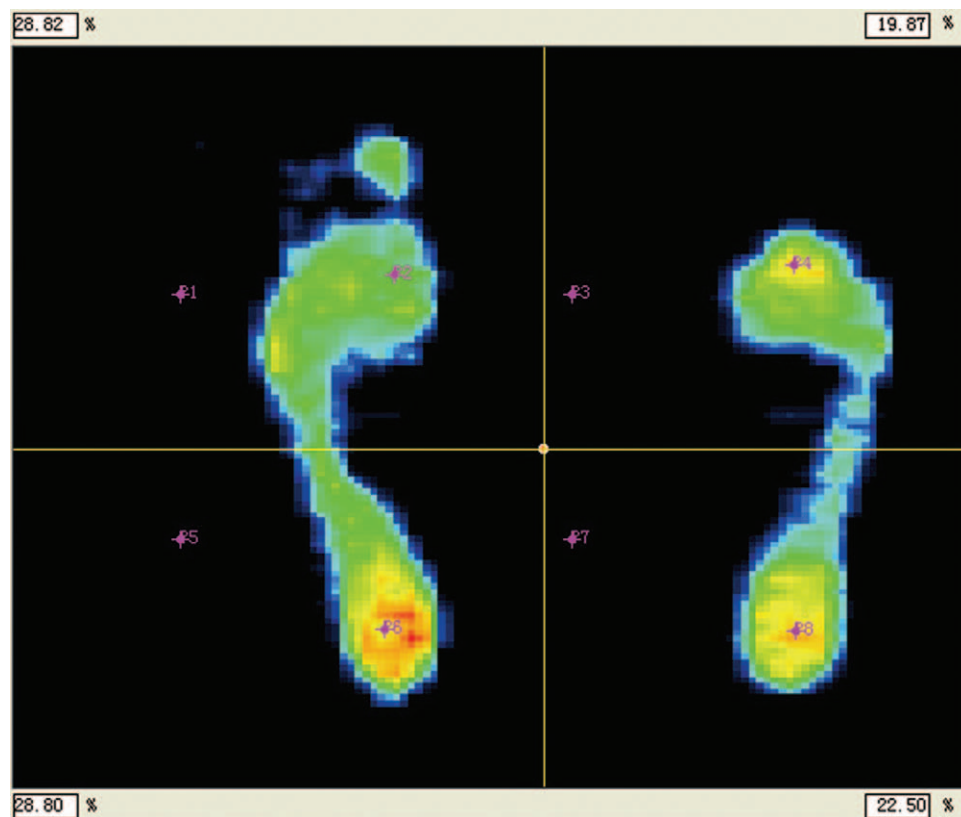


Fig. 5. Static plantar pressure distribution measurements.

Supramaximal flaps are often lifted from the trunk or thigh. These donor sites have the advantages of being a large region, in an obscure location, and have less func-

tion damage. However, the adipose layers of these sites are usually thick and loose. In addition, the borders of these supramaximal flaps are always lacking innervations, and

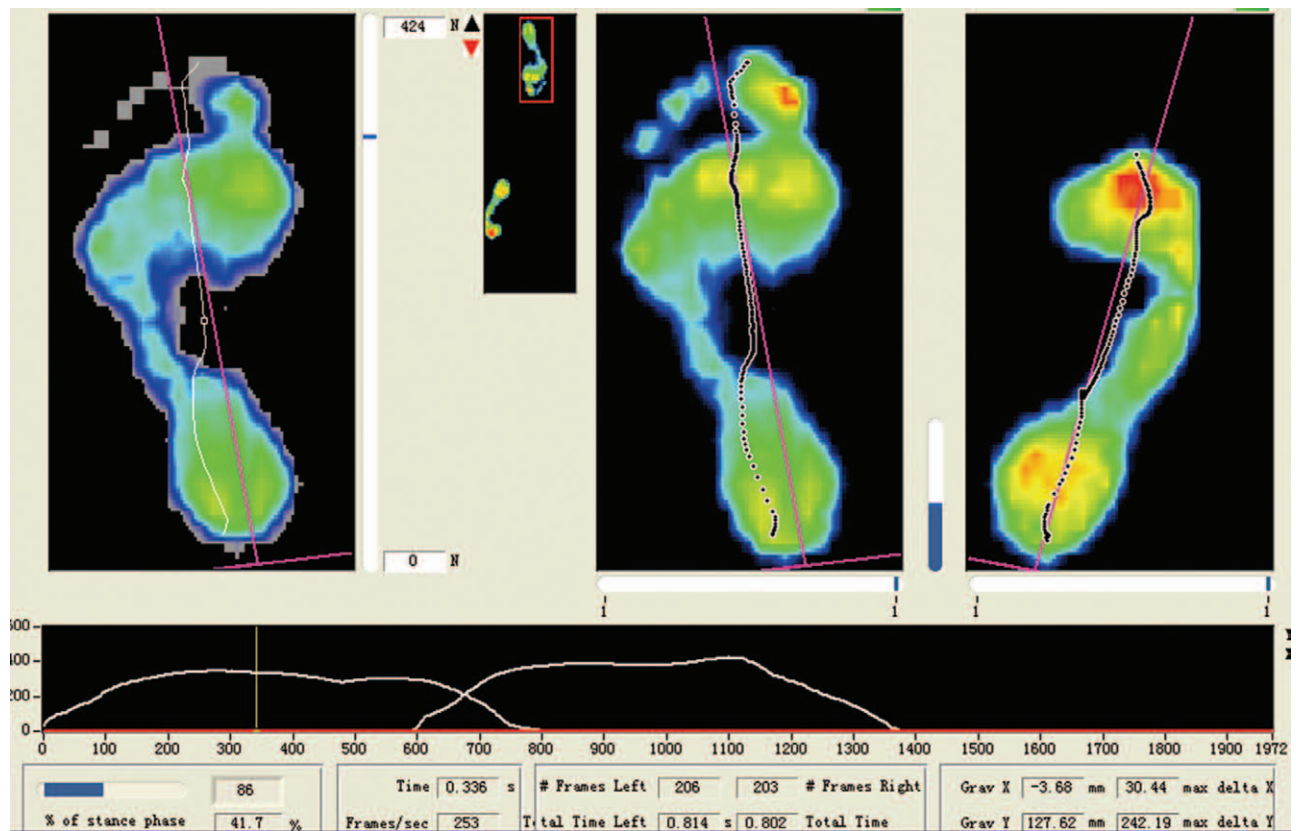


Fig. 6. Dynamic plantar pressure distribution measurements.

probably, the tiny sensory nerves in the flap may be shaved on the second-stage flap debulking operation.

The connected flap brings more choices for clinicians. Here, we choose the posterior tibial artery flap as the flow-through flap for blood supply to the medial pedal flap. In flap designing, the long axis of the medial plantar flap should be equal to the width of the fore foot. The width of the flap should be a little longer than the distance from the neck of the metatarsal bones to the head of the proximal phalangeal bone. The posterior tibial artery flap does not need to cover the whole raw surface of the dorsal foot, but it must cover the exposed blood vessels and tendons. The residual raw surface can be covered by skin grafting.

Advantages and Disadvantages of the Posterior Tibial Artery Flap Connected with a Medial Plantar Flap

Although we can choose other flow-through flaps as blood supply and reconstruct the dorsal wound, we preferred 1 pedicled double free flap. One pedicled double free-flap transplantation only has 1 set of vessels to anastomose, which has a lower risk than 2 free flaps. This surgical procedure has significant value in the repairing injury of a fore-mid foot avulsion.

The advantages of the posterior tibial artery flap connected with a medial plantar flap are as follows: (1) there are named sensory nerves both in the distal and proximal parts of the medial plantar flap, which can ensure better feeling in the weight-bearing region of the forefoot. (2)

The thickness of the flap is appropriate, and the shape is close to that of origin plantar skin. (3) The medial plantar flap should be harvested along the deep layer of plantar aponeurosis; thus, the flap will not easily slide when walking. (4) The posterior tibial artery and medial plantar artery share 1 flow-through vessel, and this can ensure a high survival rate. (5) The posterior tibial artery flap has similar characteristics to the dorsum foot. It has ideal appearance in repairing the dorsal raw surface of the foot without a second-stage rebulking operation; thus, the sensory recovery will be more reliable. (6) The great saphenous vein should be used to reconstruct the blood supply of the donor site.

The disadvantages of the posterior tibial artery flap connected with a medial plantar flap are as follows: the donor site of the medial plantar flap is limited, so the distal and middle toes need to be amputated. Although the loss of distal toes almost has no effect on walking gait, the plantar pressure distribution may change. The invasion of a donor limb seems serious, comparatively. The donor limb may develop edema at the early stage of postoperation.

Chang-Qing Zhang, MD, PhD

Department of Orthopedics

Shanghai Jiao Tong University Affiliated Sixth People's Hospital

Shanghai Jiaotong University

600 Yishan Road

Shanghai 200233, China

E-mail: zhangcq@sjtu.edu.cn

REFERENCES

1. Rausky J, Binder JP, Mazouz-Dorval S, et al. Perforator-based chimaeric thoracodorsal flap for foot reconstruction. *J Plast Reconstr Aesthet Surg*. 2013;66:1798–1800.
2. Gravvanis A, Deliconstantinou I, Tsoutsos D. Reconstruction of the weight-bearing surface of the foot with integra-grafted latissimus dorsi muscle flap. *Microsurgery* 2011;31:162–163.
3. Lu S, Chai Y. [Clinical application of sural fasciomyocutaneous perforator flap in repair of soft tissue defect in weight-bearing area of foot]. *Zhongguo Xiu Fu Chong Jian Wai Ke Za Zhi*. 2014;28:1494–1497.
4. Sen SK, Fitzgerald O'Connor E, Tare M. The free instep flap for palmar and digital resurfacing. *J Plast Reconstr Aesthet Surg*. 2015;68:1191–1198.
5. El-Shazly M, Yassin O, Kamal A, et al. Soft tissue defects of the heel: a surgical reconstruction algorithm based on a retrospective cohort study. *J Foot Ankle Surg*. 2008;47:145–152.
6. Pappalardo M, Jeng SF, Sadigh PL, et al. Versatility of the free anterolateral thigh flap in the reconstruction of large defects of the weight-bearing foot: a single-center experience with 20 consecutive cases. *J Reconstr Microsurg*. 2016;32:562–570.
7. Jing-Chun Z, Kai S, Jia-Ao Y, et al. Large heel soft tissue defects managed successfully with reverse medial crural fasciocutaneous flap: a 7-year single-center experience with 21 consecutive cases. *J Plast Reconstr Aesthet Surg*. 2015;68:40–48.
8. Siddiqi MA, Hafeez K, Cheema TA, et al. The medial plantar artery flap: a series of cases over 14 years. *J Foot Ankle Surg*. 2012;51:790–794.
9. Oh SJ, Moon M, Cha J, et al. plantar reconstruction using versatile medial plantar weight-bearing sensate flap. *J Plast Reconstr Aesthet Surg*. 2011;64:248–254.
10. Scheufler O, Kalbermatten D, Pierer G. Instep free flap for plantar soft tissue reconstruction: indications and options. *Microsurgery* 2007;27:174–180.
11. Morrison WA, Crabb DM, O'Brien BM, et al. The instep of the foot as a fasciocutaneous island and as a free flap for heel defects. *Plast Reconstr Surg*. 1983;72:56–65.
12. Miyamoto Y, Ikuta Y, Shigeki S, et al. Current concepts of instep island flap. *Ann Plast Surg*. 1987;19:97–102.