

Is there room for stereotactic radiosurgery as an option for third ventricular colloid cysts in patients refusing surgery? A case report and some therapeutic considerations

Leonardo Lustgarten^{1,2,3}

Departments of ¹Neurosurgery, ²Radiation Oncology, Hospital Clinicas Caracas, and ³Gammaknife Unit, CDD Las Mercedes, Caracas, Venezuela

E-mail: *Leonardo Lustgarten - leolust@gmail.com

*Corresponding author

Received: 22 March 15 Accepted: 28 July 15 Published: 28 September 15

Abstract

Background: Colloid cysts of the third ventricle are epithelium-lined mucus-filled cysts usually occurring in the anterosuperior third ventricle. They are benign, slow-growing lesions but with the risk of sudden death. Treatment alternatives for symptomatic cysts include stereotactic aspiration, microsurgical or endoscopic approaches, and shunts for hydrocephalus.

Case Description: The current case describes a patient presenting with hydrocephalus and a colloid cyst. A ventriculoperitoneal shunt was placed as the patient refused a definitive surgical procedure for the removal of the cyst, and stereotactic radiosurgery was then performed.

Conclusions: Stereotactic radiosurgery may be a reasonable alternative with minimal risks in those patients harboring a third ventricle colloid cyst refusing a definitive surgical procedure for resection of the cyst.

Key Words: Colloid cysts, gamma knife, hydrocephalus, stereotactic radiosurgery

Access this article online

Website:

www.surgicalneurologyint.com

DOI:

10.4103/2152-7806.166175

Quick Response Code:



INTRODUCTION

Colloid cysts are very uncommon lesions representing approximately 0.3–2% of all brain tumors.^[15] The term colloid or “glue like” essentially describes the cyst contents. They typically occur in the third ventricle (although other locations have been reported) and there is still disagreement regarding the embryologic origin of these cysts. They are considered congenital lesions and can present at any age. The most common presentation of a colloid cyst is a headache, and they can present clinically even when they are relatively small owing to the early obstruction of both the foramina of Monro.^[14] Even though a rare event, sudden death is a well-described phenomenon of colloid cysts and is the result of the bilateral foramen of Monro obstruction and acute hydrocephalus.^[3,20] Stereotactic radiosurgery has been rarely used to treat third ventricular colloid cysts and no written experience has been published so far in the literature. The case of a 39-year-old woman with a

typical colloid cyst of the third ventricle treated with gamma knife stereotactic radiosurgery is presented.

CASE REPORT

This 39-year-old right-handed woman presented with symptoms more of normal pressure hydrocephalus than intracranial hypertension. She presented with a 3-week history of headache, gait disturbances, and urinary

This is an open access article distributed under the terms of the Creative Commons Attribution-NonCommercial-ShareAlike 3.0 License, which allows others to remix, tweak, and build upon the work non-commercially, as long as the author is credited and the new creations are licensed under the identical terms.

For reprints contact: reprints@medknow.com

How to cite this article: Lustgarten L. Is there room for stereotactic radiosurgery as an option for third ventricular colloid cysts in patients refusing surgery? A case report and some therapeutic considerations. *Surg Neurol Int* 2015;6:S402-5. <http://surgicalneurologyint.com/Is-there-room-for-stereotactic-radiosurgery-as-an-option-for-third-ventricular-colloid-cysts-in-patients-refusing-surgery?-A-case-report-and-some-therapeutic-considerations/>

incontinence without any higher mental function deterioration. When initially assessed, her speech was completely fluent and coherent, and she was fully oriented in time, space, and person. There was neither cranial nerve nor focal motor deficit. Her gait was wide based, with slow steps and unsteadiness.

A cerebral magnetic resonance imaging showed significant hydrocephalus with a third ventricular small lesion suggestive of a colloid cyst [Figure 1a and b].

Definitive therapeutic options were discussed with her (craniotomy and endoscopic approaches) and she refused a definitive surgical approach to the cyst, so we proceeded with the insertion of a programmable ventriculoperitoneal (VP) shunt (Strata II system-Medtronic). Surgery went uneventful and she was discharged shortly after. Her symptoms improved dramatically in her postoperative course and had completely disappeared at her 2-week follow-up consultation.

After thoroughly discussing with her the lack of published evidence in the literature, regarding any experience using stereotactic radiosurgery for colloid cysts, she decided to undergo Gamma knife radiosurgical treatment (Leksell Gammaknife Model 4c Elekta Systems) 3 months later. It prescribed 13 Gy to the 65% isodose line [Figure 2]. The procedure went uneventful, and she was discharged immediately with a recommended visit schedule.

At the time of this report, she has been followed up for almost 5 years without any complications and the tumor has remained essentially unchanged in her cerebral images (no evidence of growth) [Figure 3].

DISCUSSION

Third ventricular colloid cysts pose a management challenge to neurosurgeons. They are benign tumors harboring a probably slow, but unknown growth rate and in a rather difficult location within the brain and the ventricles. Fortunately enough, neurosurgeons have always been able to reinvent themselves with new approaches and techniques overcoming complicated lesions. However, this has been achieved over many years and not without risks and complications, and in many instances with some degree of “collateral damage.”

Different options have been available for the treatment of colloid cysts including observation, craniotomy for microsurgical resection, neuroendoscopic removal, stereotactic aspiration, and cerebrospinal fluid (CSF) diversion with VP shunting.^[4,5,7,10,11,13,16,21] The goal of any procedure is complete resection of the lesion to avoid potential long-term recurrence^[17] with the restoration of CSF pathways, trying to achieve as minimal morbidity

and mortality as possible.

This has been traditionally achieved by either microsurgical or endoscopic approaches, both having robust amount of evidence supporting them, however, also dragging a long-standing debate between them. The final decision thus seems to boil down to the surgeon’s experience and preference.

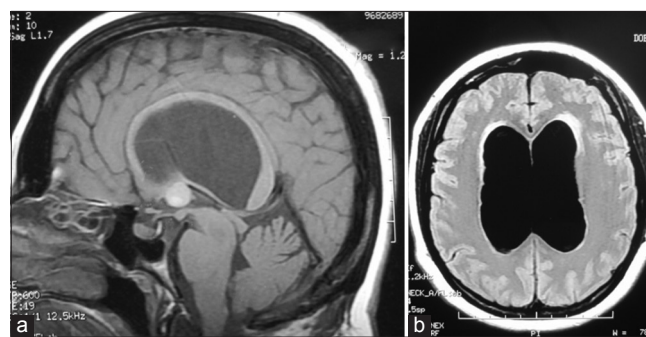


Figure 1: Preoperative magnetic resonance imaging views of the patient (a) Sagittal T1-weighted cerebral magnetic resonance imaging showing a third ventricular colloid cyst and significant hydrocephalus with ballooning of the corpus callosum. (b) Axial T1 view of the same patient

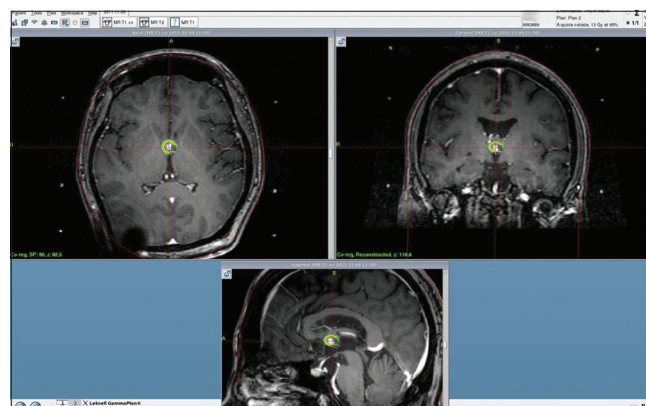

Figure 2: Gammaknife plan summary showing axial, coronal and sagittal T1 weighted with contrast MRI views. 13 Gy at 65% was prescribed

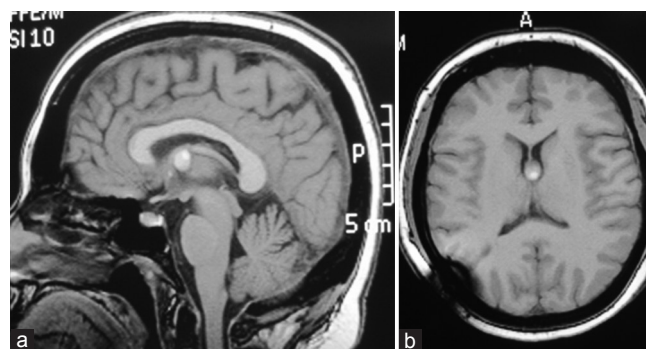


Figure 3: 43 months Postoperative and Postradiosurgical Gammaknife treatment MRI views (a) Sagittal T1 weighted cerebral MRI showing that the third ventricular colloid cyst has remained essentially the same with complete resolution of the hydrocephalus. Corpus callosum with normal thickness. (b) Axial T1 views of the same patient

Endoscopic removal or fenestration has the advantages of being minimally invasive, is usually performed through a smaller incision and no craniotomy, the lack of need for an opening in the corpus callosum, and possibly a shorter hospital stay. A disadvantage is the learning curve to master the technique, the surgeon's limited options when dealing with intraoperative bleeding. Complete removal is perhaps less likely to be achieved by using an endoscopic approach, and some series reporting neuroendoscopic excision of colloid cysts have shown higher residual cyst rates (43–80%), in comparison with microsurgical resection in which there is almost always complete excision.^[4,10,12] Dense fornix adhesion of the colloid cyst has made neurosurgeons abandon the endoscopic route for a craniotomy and microsurgical resection.^[8] Needless to say, in the hands of an experienced endoscopic surgeon, this is an excellent option and the efficacy of a purely endoscopic technique to achieve gross total colloid cyst excision has been well documented.^[1,6,8,10,21,22]

From a microsurgical point of view, colloid cysts can be reached via a transcortical or transcallosal approach. They both have advantages and disadvantages. The transcallosal route avoids an opening into the cortex minimizing the risks of postoperative seizures, while providing an excellent view of the third ventricle and foramen of Monro. The surgeon also has the advantage of surgically managing the lesion with two hands, bleeding is more readily controlled, and larger cysts can be removed more easily. Furthermore, it also seems to avoid the need for a permanent shunt as provides an opportunity of opening the septum pellucidum should a shunt be needed. The downside to this approach is access to the origin of the cyst. They tend to be attached to the roof of the third ventricle, and coming from above makes it rather difficult to see its attachment. Coagulation of the contralateral choroid plexus is difficult unless a septum pellucidotomy is performed.^[9]

Both endoscopic and microsurgical techniques are associated with possible memory impairment, fortunately, it is usually transient.

Management of these cases is a reminder of the potential difficulty in treating and making the correct decision when faced with patients harboring colloid cysts. Data reported by Pollock *et al.*^[18,19] on the natural history showed that the incidences of patient symptomatic progression related to the colloid cyst were 0%, 0%, and 8% at 2, 5, and 10 years, respectively. This information may perhaps support the option of observation and serial neuroimaging in asymptomatic patients,^[2,19] however, it becomes a risky in symptomatic patients because of the concern of acute neurological decline and sudden death.^[2,3,20]

Despite our well refined microsurgical techniques, skills, and sophisticated neuroendoscopes, I am certain

we all have seen and witnessed the morbidity left by these procedures and the fact that some patients are programmed for minimally invasive procedures such as stereotactic aspiration or an endoscopic approach only to end up with a complex surgery, in some cases not even being able to remove the lesion completely, left with the potential of a probable future approach at some point in their life.

Both, microsurgical and endoscopic routes have been developed and improved while achieving, at the same time, satisfactory cure rates. However, the reality is that the majority of practicing neurosurgeons around the world only see very few (or none) colloid cyst, during their professional careers and given the rarity of the lesions, never achieve the necessary surgical expertise to attain the results published by high profile neurosurgical centers.

So, when faced with a patient having a colloid cyst we need to offer the best available therapeutic alternatives. When discussing management options with patients and relatives, we commonly tend to quote “complications and success rates” usually derived from published literature (and mainly coming from highly specialized centers), which does not necessarily reflect our personal experience and may only create false expectations in these patients. Furthermore, few patients have access to these surgically sophisticated centers.

Then, what alternatives do we have with the actual patient who refuses surgery for the removal of these tumors? Is there room for stereotactic radiosurgery? Stereotactic radiosurgery could become a reasonable alternative for these patients under this particular scenario. Other cystic tumors in the brain have been and are currently treated with stereotactic radiosurgery (craniopharyngiomas, hemangioblastomas, cystic schwannomas, metastases, etc.) and even rare lesions such as Rathke's cleft cysts using the dose of 13 Gy as we prescribed to our colloid cyst. This dose has proven to be safe when treating lesions close to eloquent structures in the brain.^[23]

There is no relevant published data to support the use of stereotactic radiosurgery for treatment of colloid cysts as all published series refer to endoscopic or microsurgical approaches. Considering that these tumors are usually very small, rounded, well defined, and mainly surrounded by water (CSF), they do seem to become ideal targets for excellent conformal treatment plans making stereotactic radiosurgery an excellent alternative. Besides, given their histology (cystic epithelium lining) their slow growth rate (low alpha/beta tissue) and therefore, the potential for long-term growth control, it makes sense from a radiobiological standpoint to use this modality of treatment, provided that the life threatening hydrocephalus has been dealt with.

Future evidence will be needed before we can add

stereotactic radiosurgery as part of a proven treatment for these patients, however, we should start somewhere.

CONCLUSIONS

Stereotactic radiosurgery may be a reasonable option with minimal risks in patients with third ventricle colloid cyst refusing a definitive surgical procedure for resection. The minimally invasiveness and precise conformity achieved by radiosurgery and the potential for long-term tumor growth control, turns it into a very attractive alternative to consider, especially when hydrocephalus has been treated.

Financial support and sponsorship

Nil.

Conflicts of interest

There are no conflicts of interest.

REFERENCES

- Caemaert J, Abdullah J. Endoscopic management of colloid cysts. *Tech Neurosurg* 1996;1:185-200.
- Chan RC, Thompson GB. Third ventricular colloid cysts presenting with acute neurological deterioration. *Surg Neurol* 1983;19:358-62.
- de Witt Hamer PC, Verstegen MJ, De Haan RJ, Vandertop W, Thomeer RT, Mooij JJ, et al. High risk of acute deterioration in patients harboring symptomatic colloid cysts of the third ventricle. *J Neurosurg* 2002;96:1041-5.
- Decq P, Le Guerinel C, Brugières P, Djindjian M, Silva D, Kéravel Y, et al. Endoscopic management of colloid cysts. *Neurosurgery* 1998;42:1288-94.
- Desai KI, Nadkarni TD, Muzumdar DP, Goel AH. Surgical management of colloid cyst of the third ventricle – A study of 105 cases. *Surg Neurol* 2002;57:295-302.
- Gaab MR, Schroeder HW. Neuroendoscopic approach to intraventricular lesions. *J Neurosurg* 1998;88:496-505.
- Gökalp HZ, Yüceer N, Arasil E, Erdogan A, Dincer C, Baskaya M. Colloid cyst of the third ventricle. Evaluation of 28 cases of colloid cyst of the third ventricle operated on by transcortical transventricular (25 cases) and transcallosal/transventricular (3 cases) approaches. *Acta Neurochir (Wien)* 1996;138:45-9.
- Greenlee JD, Teo C, Ghahreman A, Kwok B. Purely endoscopic resection of colloid cysts. *Neurosurgery* 2008;62 3 Suppl 1:S51-5.
- Hadjipanayis CG, Schuette AJ, Boulis N, Hao C, Barrow DL, Teo C. Full scope of options. *Neurosurgery* 2010;67:197-203.
- Hellwig D, Bauer BL, Schulte M, Gatscher S, Riegel T, Bertalanffy H. Neuroendoscopic treatment for colloid cysts of the third ventricle: The experience of a decade. *Neurosurgery* 2003;52:525-33.
- Hernesniemi J, Leivo S. Management outcome in third ventricular colloid cysts in a defined population: A series of 40 patients treated mainly by transcallosal microsurgery. *Surg Neurol* 1996;45:2-14.
- Horn EM, Feiz-Erfan I, Bristol RE, Lekovic GP, Goslar PW, Smith KA, et al. Treatment options for third ventricular colloid cysts: Comparison of open microsurgical versus endoscopic resection. *Neurosurgery* 2007;60:613-8.
- Kondziolka D, Lunsford LD. Stereotactic management of colloid cysts: Factors predicting success. *J Neurosurg* 1991;75:45-51.
- Kumar V, Behari S, Kumar Singh R, Jain M, Jaiswal AK, Jain VK. Pediatric colloid cysts of the third ventricle: Management considerations. *Acta Neurochir (Wien)* 2010;152:451-61.
- Little JR, MacCarty CS. Colloid cysts of the third ventricle. *J Neurosurg* 1974;40:230-5.
- Mathiesen T, Grane P, Lindgren L, Lindquist C. Third ventricle colloid cysts: A consecutive 12-year series. *J Neurosurg* 1997;86:5-12.
- Mathiesen T, Grane P, Lindquist C, von Holst H. High recurrence rate following aspiration of colloid cysts in the third ventricle. *J Neurosurg* 1993;78:748-52.
- Pollock BE, Huston J 3rd. Natural history of asymptomatic colloid cysts of the third ventricle. *J Neurosurg* 1999;91:364-9.
- Pollock BE, Schreiner SA, Huston J 3rd. A theory on the natural history of colloid cysts of the third ventricle. *Neurosurgery* 2000;46:1077-81.
- Ryder JW, Kleinschmidt-DeMasters BK, Keller TS. Sudden deterioration and death in patients with benign tumors of the third ventricle area. *J Neurosurg* 1986;64:216-23.
- Schroeder HW, Gaab MR. Endoscopic resection of colloid cysts. *Neurosurgery* 2002;51:1441-4.
- Teo C. Complete endoscopic removal of colloid cysts: Issues of safety and efficacy. *Neurosurg Focus* 1999;6:e9.
- Yu X, Huang R, Qian W, Fang J, Wu C, Liu S. Stereotactic radiosurgery to treat presumed Rathke's cleft cysts. *Int J Radiat Oncol Biol Phys* 2013;85:667-71.