

# Comparison of Transforaminal Lumbar Interbody Fusion Using the Boomerang-Shaped Cage with Traditional Posterior Lumbar Interbody Fusion for Lumbar Spondylolisthesis

Yohei Ishihara<sup>1)</sup>, Masutaro Morishita<sup>1)</sup>, Jiro Miyaki<sup>1)</sup>, Koji Kanzaki<sup>2)</sup> and Tomoaki Toyone<sup>3)</sup>

1) *Asao General Hospital Spine Center, Kanagawa, Japan*

2) *Department of Orthopedic Surgery, Showa University Fujigaoka Hospital, Kanagawa, Japan*

3) *Department of Orthopaedic Surgery, School of Medicine, Showa University, Tokyo, Japan*

## Abstract:

**Introduction:** This study aimed to compare the clinical and radiological results of transforaminal lumbar interbody fusion (TLIF) with a boomerang-shaped cage and traditional posterior lumbar interbody fusion (PLIF) according to fused level and elucidate whether TLIF could replace PLIF at all lumbar levels.

**Methods:** The study investigated 128 patients with lumbar spondylolisthesis who underwent a single-level TLIF or traditional PLIF. Intraoperative blood loss, operative time, and recovery rate were analyzed. Percent slip, disc height, and local lordosis at the fused level were measured using X-ray images from preoperation to the final follow-up.

**Results:** No significant differences in recovery rate were observed at any level. The operative time and intraoperative blood loss were significantly less in the TLIF group at the L4/5 and L5/S1 levels. There were no significant differences in disc height or local lordosis at the L3/4 and L4/5 levels, and a satisfactory level of maintenance after the operation was achieved in both groups. However, at the L5/S1 level, postoperative maintenance after TLIF could not be achieved, and the obtained disc height and local lordosis in TLIF significantly decreased.

**Conclusions:** Compared with traditional PLIF, TLIF was a less invasive procedure with a shorter operative time and lesser blood loss. TLIF could obtain similar local lordosis and disc height as PLIF at the L3/4 and L4/5 levels. At the L5/S1 level, the postoperative maintenance of local lordosis and disc height after TLIF was inferior to that after PLIF. On the basis of our results, we do not recommend performing TLIF at only the L5/S1 level.

## Keywords:

lumbar spondylolisthesis, transforaminal lumbar interbody fusion, posterior lumbar interbody fusion, boomerang-shaped cage, fused lumbar levels

Spine Surg Relat Res 2019; 3(1): 71-78  
dx.doi.org/10.22603/ssrr.2018-0022

## Introduction

Posterior lumbar interbody fusion (PLIF), which involves the insertion of two cages through a bilateral approach, has been the standard surgical technique for lumbar spondylolisthesis. PLIF can provide a stable three-column fixation with 360° fusion only by the posterior approach<sup>1-3)</sup>. However, retraction of the thecal sac, which increases the risks of durotomy and nerve root injury, is required during the procedure in the disc space. Transforaminal lumbar interbody fusion (TLIF) is a modification of PLIF. After sufficient discectomy, it can achieve interbody fusion with the insertion of


cages only by the unilateral approach with less dural retraction compared with that in traditional PLIF. Some previous studies evaluated the clinical results obtained after TLIF and PLIF and reported less invasiveness and greater safety with TLIF compared with PLIF<sup>3-6)</sup>. De Kunder et al.<sup>4)</sup> performed a systematic review of the previous literature and a meta-analysis of the effectiveness of these procedures and concluded that TLIF has advantages over PLIF in terms of blood loss, operative time, and the rates of complications such as dural tear and nerve root damage.

Surgical complications associated with the unilaterally inserted cages used in TLIF have also been reported<sup>7-9)</sup>. Since

Corresponding author: Yohei Ishihara, youyuka627@yahoo.co.jp

Received: April 23, 2018, Accepted: June 28, 2018, Advance Publication: July 25, 2018

Copyright © 2019 The Japanese Society for Spine Surgery and Related Research



**Figure 1.** Procedure of cage placement.

(a) Insertion of cage into the intervertebral space.

(b) Placement of the cage in the anterior region of the end plate, changing the angle between the cage and inserter.

(c) Final adjustment of cage location.

2007, the new type of boomerang-shaped cage with a special inserter has been used at our hospital (Asao General Hospital)<sup>10</sup>. The beneficial characteristics of this new cage are its ability to change the angle between the cage and inserter during the cage insertion into the disc and its easy removal if the cage is not optimally in place (Fig. 1)<sup>10</sup>. In our hospital, TLIF for lumbar spondylolisthesis using this cage instead of PLIF has already been adopted.

However, to the best of our best knowledge, there are no detailed reports comparing the surgical results, including radiological evaluation according to the fused level, of TLIF and PLIF. Our hypothesis before the study was that TLIF would be less invasive than traditional PLIF and there would be no significant difference between the two procedures in radiological evaluation at all lumbar levels. Based on these hypotheses, we expected that TLIF would be able to replace PLIF in lumbar operations.

The aim of this study was to compare the surgical results of TLIF using a boomerang-shaped cage with those of traditional PLIF by clinical and radiological evaluation according to the fused level and elucidate whether TLIF could replace PLIF at all lumbar levels.

## Materials and Methods

This is a retrospective study approved by the Institutional Review Board of our hospital, and informed consent was obtained from all patients.

### 1. Patient population

We report 128 patients (men, 48; women, 80) with lumbar spondylolisthesis who underwent single-level TLIF or traditional PLIF (Table 1). All patients were followed up for >2 years (mean, 40.6 months; range, 24-96 months). Before 2007, all patients were treated by PLIF. After 2007, the patient selected TLIF or PLIF as their treatment choice after sufficient informed consent, including the clinical and radiological outcomes in both procedures, had been obtained. Patients with trauma, reoperation, and decompression that involve the fused and other levels were excluded from this study.

### 2. Clinical and radiological evaluation

The analyzed clinical outcomes included intraoperative blood loss, operative time, and recovery rate calculated us-

**Table 1.** Demographic Data at the Time of Operation (n=128).

	L3/4 level	L4/5 level	L5/S1 level
Number of patients	12	65	51
Sex			
{ Male	3 patients	17 patients	28 patients
{ Female	9 patients	48 patients	23 patients
Age	65.3 years (48-80)	65.1 years (44-83)	61.7 years (35-80)
Operative procedure			
{ TLIF	8 cases	47 cases	26 cases
{ PLIF	4 cases	18 cases	25 cases
Diagnosis			
{ Degenerative spondylolisthesis	12 cases	62 cases	7 cases
{ Spondylolytic spondylolisthesis	0 case	3 cases	44 cases
Mayerding classification for spondylolisthesis			
{ Grade I	5 cases	21 cases	36 cases
{ Grade II	7 cases	42 cases	12 cases
{ Grade III	0 case	2 cases	3 cases

**Table 2.** Clinical Outcomes of Transforaminal Lumbar Interbody Fusion (TLIF) and Posterior Lumbar Interbody Fusion (PLIF).

Recovery rate (%)			
Lumbar level	TLIF	PLIF	P-value*
L3/4	68.7±14.1	70.2±20.6	0.851
L4/5	69.3±20.3	66.5±19.1	0.731
L5/S1	67.7±18.1	71.4±22.1	0.562
Operative time (min)			
Lumbar level	TLIF	PLIF	P-value*
L3/4	169.2±70.5	177.5±61.3	0.107
L4/5	143.0±59.2	172.8±65.4	0.025*
L5/S1	165.3±67.3	189.8±70.9	0.031*
Blood loss (mL)			
Lumbar level	TLIF	PLIF	P-value*
L3/4	322.6±292.3	350.7±298.5	0.096
L4/5	258.4±224.2	326.6±278.3	0.001*
L5/S1	337.1±298.1	413.7±313.5	0.015*

\*P&lt;0.05

ing Japanese Orthopedic Association scores<sup>11,12</sup>).

Using X-ray images, percent slip, correction disc height (anterior or posterior disc height/anteroposterior diameter of upper vertebral body × 100%), and local lordosis at the fused level were measured preoperation, immediately postoperation, 1 year postoperation, and at the final follow-up. The postoperative increase in the disc height and local lordosis (postoperative measurement value-preoperative measurement value) were compared between the TLIF and PLIF groups for each fused level. Additionally, sagittal parameters measured on lateral standing radiograph of the entire spine (lumbar lordosis, pelvic incidence, pelvic tilt, sacral slope, and sagittal vertical axis) were also evaluated from preoperation to postoperation. Bone union was evaluated using sagittal reconstruction images of CT, and the rigid fusion was defined as the formation of osseous continuity between the upper and lower vertebral body.

### 3. Surgical procedure

TLIF and PLIF were performed by an open procedure, not by a minimally invasive procedure, by exposing the spinal posterior elements through a posterior midline incision.

#### TLIF

After adequate decompression by laminectomy and unilateral facetectomy on the dominant side of the neurological symptoms, pedicle screws were inserted. Facetectomy on the contralateral side was also performed as it was essential for decompression. Discectomy was performed by a unilateral approach with less traction of neurological elements, and a boomerang-shaped cage packed with autogenous bone was placed in the anterior region of the end plate while the location was checked by fluoroscopy. Autogenous bone grafting was also performed into the intervertebral space behind the cage. The screws from the cranial to caudal sides were con-

nected by rods. Lastly, local lordosis was formed by the application of posterior compression force by the pedicle screw.

#### PLIF

For all PLIF cases, an anterior expandable cage was used. Adequate decompression was performed with laminectomy, and facetectomy was also performed depending on the situation of each case. After the insertion of the pedicle screw, discectomy was performed through the bilateral approach. After autogenous bone grafting was performed in the anterior region of the endplate, two cages packed with autografts were bilaterally inserted into the end plate. The cages were expanded from the anterior element until adequate local lordosis had formed and stability between the cage and end plate was attained with the use of fluoroscopy. Lastly, the screws were connected by rods, and autogenous bone grafting was also performed behind the cages.

### 4. Statistical analysis

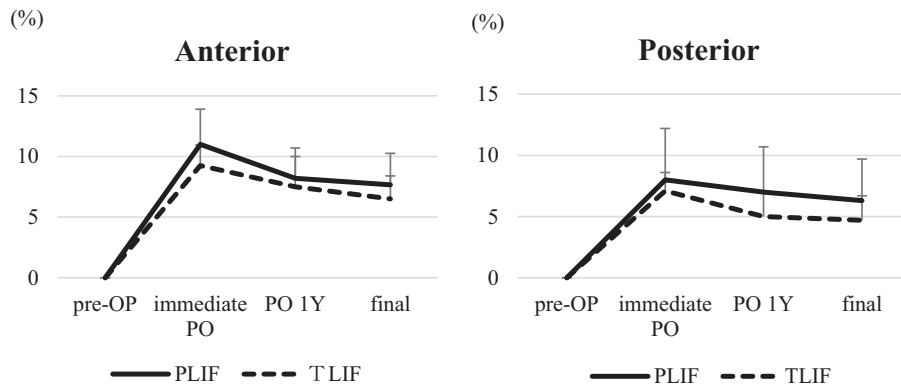
The statistical significance of the differences between the groups was evaluated by the Mann-Whitney U test. A P-value < 0.05 was considered statistically significant. All analyses were performed using JMP 13 software (SAS Institute Inc., Cary, NC, USA).

## Results

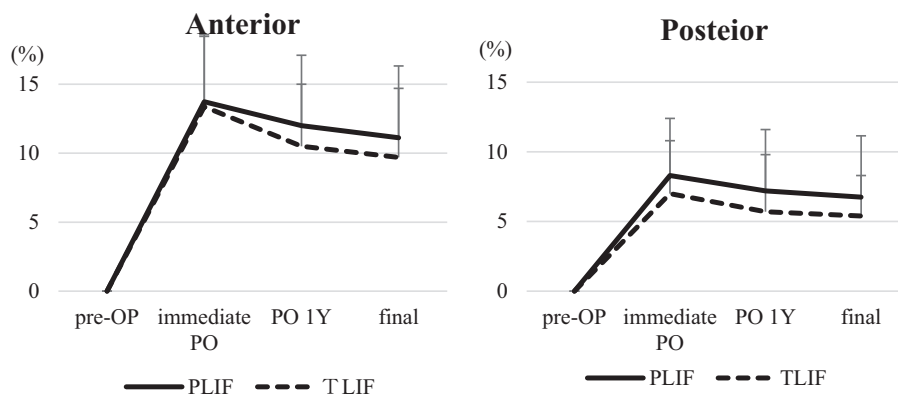
### 1. Clinical outcomes and complications

Two cases of dural tear developed in each of the groups, which were intraoperatively repaired. There were no serious intraoperative or postoperative complications, and rigid bone union was found in all cases within 1 year postoperation.

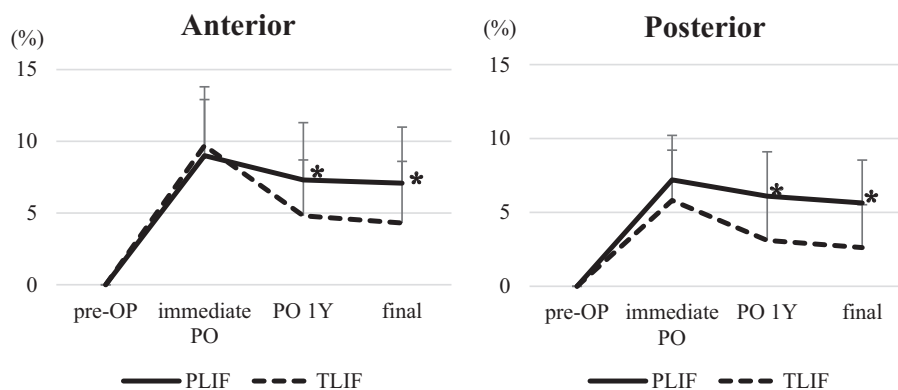
**(a) L3/4**



**(b) L4/5**



**(c) L5/S1**



**Figure 2.** Increase in disc height from preoperation to final follow-up (%).

(a) L3/4 level: No significant difference in both procedures.

(b) L4/5 level: No significant difference in both procedures.

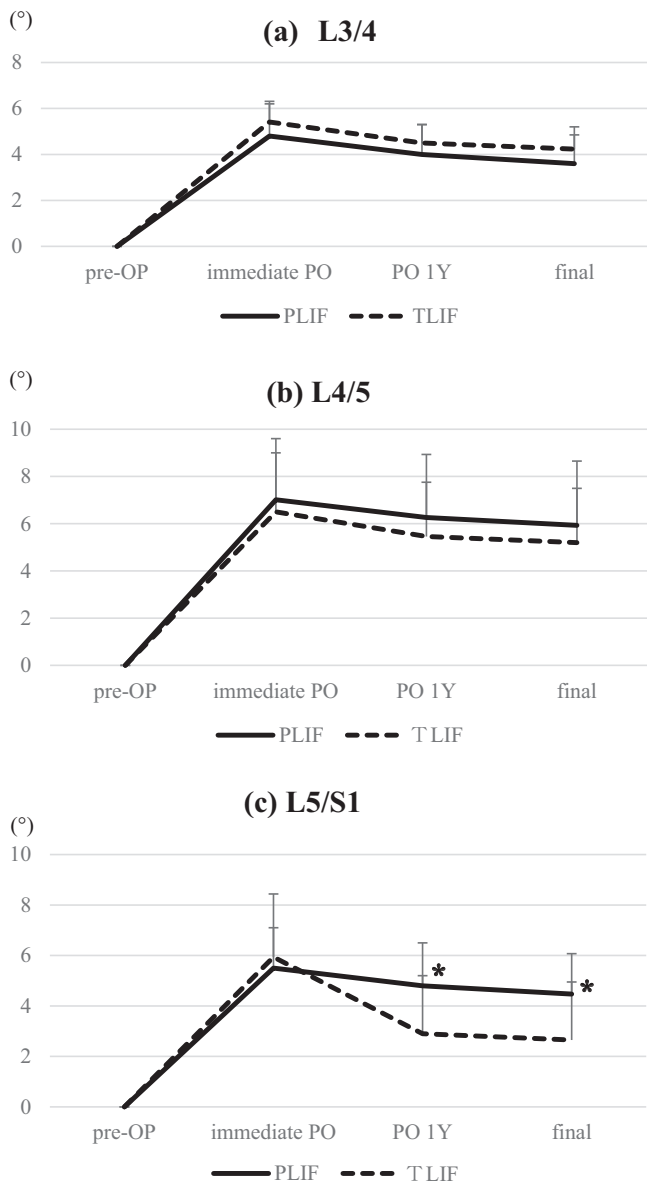
(c) L5/S1 level: Disc height after TLIF significantly decreased compared with that after PLIF.

\*,  $P < 0.05$ ; OP, operation; PO, postoperation; TLIF, transforaminal lumbar interbody fusion; PLIF, posterior lumbar interbody fusion

There were no significant differences in the recovery rates between the groups at any level. The operative time and intraoperative blood loss were significantly less in the TLIF group than those in the PLIF group at the L4/5 and L5/S1 levels ( $p < 0.05$ ) (Table 2).

**2. Radiological outcomes**

On radiographic evaluation, no significant differences were observed between the groups in any of the preoperative measurements or the postoperative percent slip. There were no significant differences between the groups in terms



**Figure 3.** Increase in local lordosis from preoperation to final follow-up (°).

- (a) L3/4 level: No significant difference in both procedures.
- (b) L4/5 level: No significant difference in both procedures.
- (c) L5/S1 level: Local lordosis after TLIF significantly decreased compared with that after PLIF.

\*,  $P < 0.05$ ; OP, operation; PO, postoperation; TLIF, transforaminal lumbar interbody fusion; PLIF, posterior lumbar interbody fusion

of the increase in disc height or local lordosis at the L3/4 and L4/5 levels, and a satisfactory postoperative maintenance of disc height and local lordosis was obtained in both groups at the final follow-up. There were no significant differences between the groups in terms of an immediate postoperative increase in the disc height and local lordosis at the L5/S1 level. The postoperative maintenance was not obtained post-TLIF, and it significantly decreased compared with that in the PLIF group ( $p < 0.05$ ) (Fig. 2, 3). There was no significant difference in sagittal parameters measured

on lateral standing radiograph of the entire spine after undergoing both procedures.

### 3. Representative cases of TLIF for the L4/5 and L5/S1 levels

#### Case 1 (L4/5)

TLIF at the L4/5 level was performed on a 70-year-old woman with degenerative spondylolisthesis. Adequate local lordosis and disc height had formed, and serious subsidence of the cage was not observed postoperation. Sufficient postoperative maintenance was obtained until the final follow-up (Fig. 4)<sup>10</sup>.

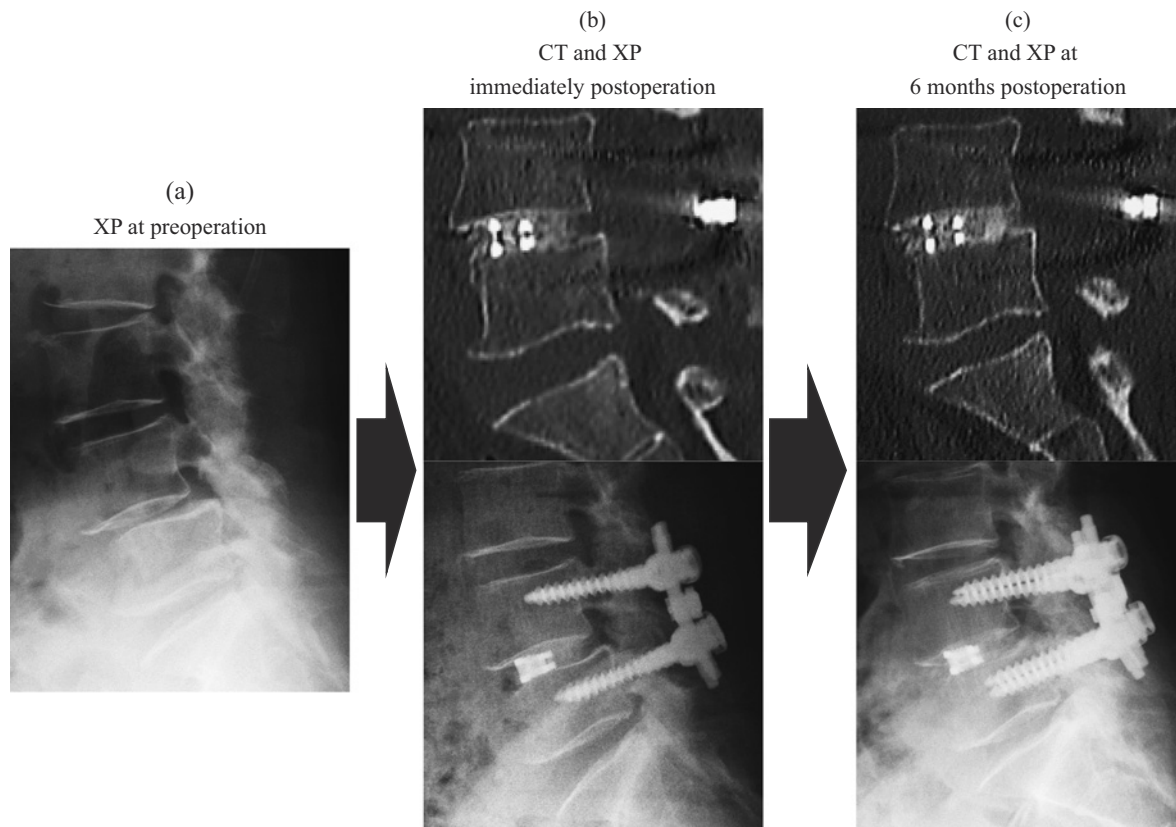
#### Case 2 (L5/S1)

TLIF at the L5/S1 level was performed on a 55-year-old woman with spondylolytic spondylolisthesis. Although a boomerang-shaped cage was placed in the anterior region of the end plate, postoperative subsidence was found with loss of disc height and local lordosis (Fig. 5).

## Discussion

TLIF was first described by Harms in 1982<sup>13</sup> as an alternative technique to PLIF. Previous reports showed that TLIF with a unilateral approach via the intervertebral foramen had several advantages with fewer intraoperative complications than the traditional PLIF procedure<sup>3-6</sup>. Similarly, our results indicated that TLIF comparatively was a less invasive procedure with shorter operative time and lesser blood loss than traditional PLIF.

Additionally, by applying posterior compression force across the pedicle screws after placing the boomerang-shaped cage in the anterior region of the end plate, sufficient local lordosis was obtained with the modified TLIF procedure<sup>14</sup>. In a biomechanical study, Kettler et al.<sup>15</sup> showed that primary stability achieved with one boomerang-shaped cage implanted by a unilateral approach was not significantly different from that achieved with two PLIF cages implanted by a bilateral approach. In the unilateral TLIF procedure, the cage position is an important factor for postoperative cage subsidence, which is related to the loss of lumbar lordosis and disc height. Biomechanically, the central portion is the weakest part of the end plate of the vertebral body, owing to its thin cortex<sup>16</sup>. To efficiently form local lordosis and prevent postoperative cage subsidence, the boomerang-shaped cage should be located in the anterior region of the end plate after sufficient discectomy was performed carefully not to damage the bony end plate. However, the technique of boomerang-shaped cage insertion is more complex than that for other types of cages, and the cage placement in the anterior region of the end plate is sometimes difficult to control. Fukuda et al.<sup>8</sup> investigated the position of 82 cages, which were similar to our cages that were unilaterally implanted in TLIF. In this study, 16 cages were located in the center of the intervertebral space, and 66 were anteriorly located, and



**Figure 4.** TLIF at the L4/5 level (70-year-old woman with degenerative spondylolisthesis).

(a) XP at preoperation: L4/5 level degenerative spondylolisthesis, Mayerding grade I.

(b) CT and XP immediately postoperation: The cage was placed in the anterior region, and adequate disc height and local lordosis were obtained.

(c) CT and XP at 6 months postoperation: Bone union with sufficient postoperative maintenance was obtained.

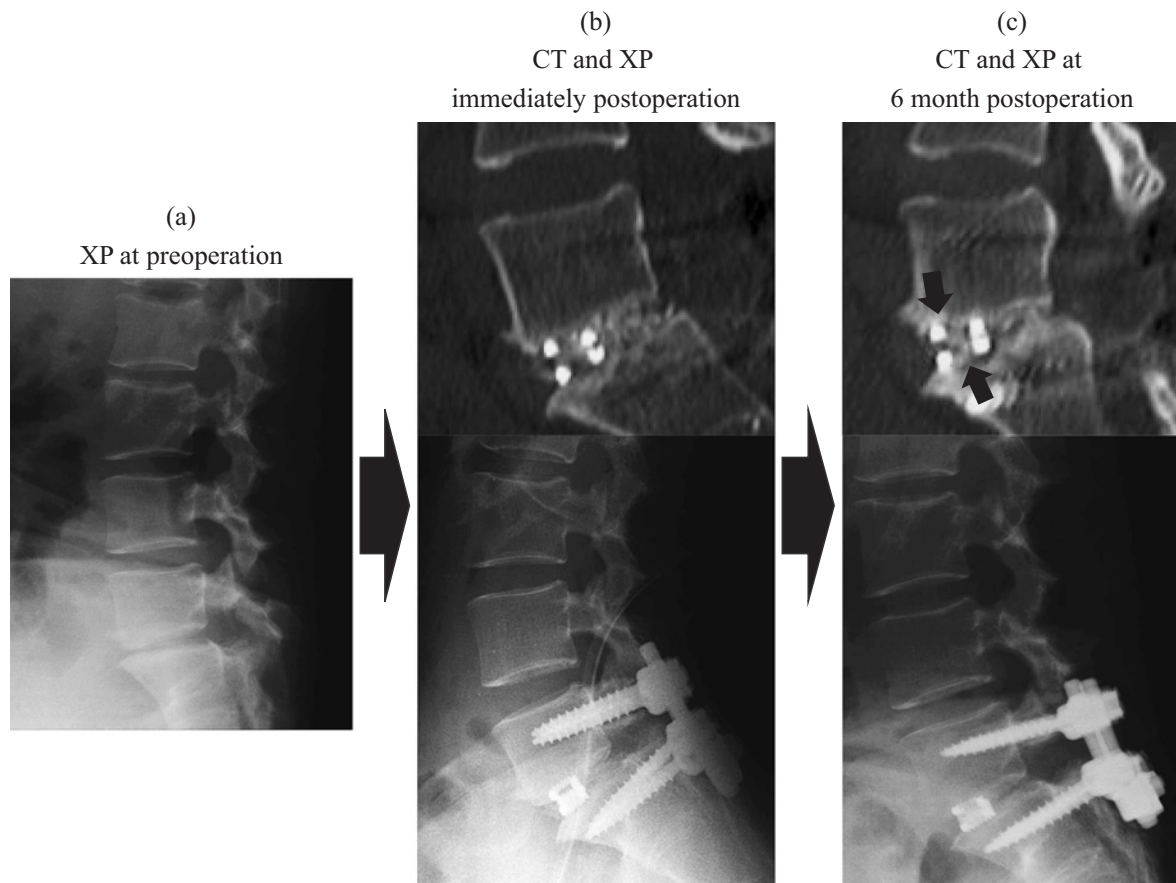
subsidence of the cages placed in the center was significantly greater than that of the cages anteriorly placed. In our study, all of the boomerang-shaped cages could be easily placed in the anterior region, owing to the special inserters connected to the cages. Our results showed that TLIF with the placement of boomerang-shaped cage in the anterior region of the end plate could obtain similar local lordosis and disc height, including postoperative maintenance at the L3/4 and L4/5 levels, as traditional PLIF despite its shorter operative time and lesser blood loss.

In contrast, in our results for the L5/S1 level, the postoperative maintenance of local lordosis and disc height after TLIF was inferior to that after PLIF, which is unlike that for the L3/4 and L4/5 levels. Closkey et al.<sup>17)</sup> suggested in a biomechanical study that the size of the contact area between the cage and end plate has a significant relationship with cage subsidence. The morphology of the end plate at the L5/S1 level characteristically differs from that at other lumbar levels; the lumbar vertebral end plate gradually changes into a more oval shape from the L1/2 to the L5/S1 disc with a decrease in circularity<sup>18)</sup>. Additionally, the L5/S1 level has the largest lordotic angle, importantly contributing to lumbar sagittal alignment compared with other levels<sup>19)</sup>. Lordotic angle of boomerang-shaped cage used in this study was 7°, which might be not enough to obtain the adequate

contact area involving solid fixation between the cage and end plate at the L5/S1 level even if the cage was placed in the anterior region of the end plate. Although TLIF using the unilateral boomerang-shaped cage would be an alternative procedure to traditional PLIF at the L3/4 and L4/5 levels, we do not recommend performing TLIF only at the L5/S1 level.

Some previous studies also reported that the risk of cage retropulsion and pseudarthrosis at the L5/S1 level was higher even after two cages were bilaterally inserted in the PLIF procedure<sup>20,21)</sup>. In our study, an anterior expandable cage was used in traditional PLIF, which enabled the lordotic angle to be intraoperatively adjusted for adequate fitting to the end plate. The anterior expandable cage would be a useful option with a larger contact area and better stabilization than other types of cages including the boomerang-shaped cage at the L5/S1 level.

Although there are several types of cages for TLIF and PLIF, the types of cages used in our study were limited to the anterior expandable cage (PLIF) and boomerang-shaped cage (TLIF). For the accurate comparison of surgical results after TLIF and PLIF, evaluation in both procedures using other types of cages might be necessary. In particular, if anterior expandable TLIF cage was used at L5/S level, postoperative cage subsidence after TLIF might be prevented. Ad-



**Figure 5.** TLIF at the L5/S1 level (55-year-old woman with spondylolytic spondylolisthesis).

(a) XP at preoperation: L5/S1 level spondylolytic spondylolisthesis, Mayerding grade I.

(b) CT and XP at immediately postoperation: The cage was placed in the anterior region, and adequate disc height and local lordosis were obtained.

(c) CT and XP at 6 months postoperation: Postoperative subsidence (arrows) was found with loss of disc height and local lordosis.

ditionally, the cases were limited to a single-level fusion in our study. By comparing several level fusions, the benefits of TLIF would be emphasized, such as in elderly patients who require correction surgery for degenerative scoliosis using the multilevel interbody fusion that the low invasiveness of surgery including the decrease of blood loss and operative time would be essential to avoid the serious perioperative complication that affects the general condition<sup>22,23</sup>. The boomerang-shaped cages could be used for not only long fusion surgery but also minimally invasive surgery (MIS), which has recently been noticed as the new less invasive technique<sup>24,25</sup>. In our future study, comparison of surgical results between MIS technique and open procedure would be investigated for the further application of TLIF.

### Conclusion

TLIF with a boomerang-shaped cage could obtain similar local lordosis and disc height including the postoperative maintenance as PLIF at the L3/4 and L4/5 levels, except the L5/S1 level, despite the shorter operative time and lesser blood loss. Based on our results, although TLIF using the

unilateral boomerang-shaped cage would be an alternative procedure to traditional PLIF at the L3/4 and L4/5 levels, we do not recommend performing TLIF only at the L5/S1 level.

**Conflicts of Interest:** The authors declare that there are no relevant conflicts of interest.

**Author Contributions:** Yohei Ishihara wrote and prepared the manuscript, and all of the authors participated in the study design. All authors have read, reviewed, and approved the article.

### References

1. Lian XF, Hou TS, Xu JG, et al. Single segment of posterior lumbar interbody fusion for adult isthmic spondylolisthesis: reduction or fusion in situ. *Eur Spine J.* 2014;23(1):172-9.
2. Mobbs RJ, Phan K, Malham G, et al. Lumbar interbody fusion: techniques, indications and comparison of interbody fusion options including PLIF, TLIF, MI-TLIF, OLIF/ATP, LLIF and ALIF. *J Spine Surg.* 2015;1(1):2-18.
3. Zhang Q, Yuan Z, Zhou M, et al. A comparison of posterior lum-

- bar interbody fusion and transforaminal lumbar interbody fusion: a literature review and meta-analysis. *BMC Musculoskelet Disord.* 2014;15(1):367.
4. de Kunder SL, van Kuijk SMJ, Rijkers K, et al. Transforaminal lumbar interbody fusion (TLIF) versus posterior lumbar interbody fusion (PLIF) in lumbar spondylolisthesis: a systematic review and meta-analysis. *Spine J.* 2017;17(11):1712-21.
  5. Humphreys SC, Hodges SD, Patwardhan AG, et al. Comparison of posterior and transforaminal approaches to lumbar interbody fusion. *Spine.* 2001;26(5):567-71.
  6. Mura PP, Costaglioli M, Piredda M, et al. TLIF for symptomatic disc degeneration: a retrospective study of 100 patients. *Eur Spine J.* 2011;20(1):57-60.
  7. Aoki Y, Yamagata M, Nakajima F, et al. Examining risk factors for posterior migration of fusion cages following transforaminal lumbar interbody fusion: a possible limitation of unilateral pedicle screw fixation. *J Neurosurg Spine.* 2010;13(3):381-7.
  8. Fukuda S, Miyamoto K, Hosoe H, et al. Kidney-type intervertebral spacers should be located anteriorly in cantilever transforaminal lumbar interbody fusion. *J Spinal Disord Tech.* 2011;24(3):189-95.
  9. Oh HS, Lee SH, Hong SW. Anterior dislodgement of a fusion cage after transforaminal lumbar interbody fusion for the treatment of isthmic spondylolisthesis. *J Korean Neurosurg Soc.* 2013;54(2):128-31.
  10. Ishihara Y, Morishita M, Miyaki J, et al. Surgical results of transforaminal lumbar interbody fusion using the new boomerang-shaped cage. *J Spine Res.* 2016;7(10):1457-61.
  11. Inoue S. Assessment of treatment for low back pain. *J Jpn Orthop Assoc.* 1986;60:391-4.
  12. Okuda S, Oda T, Miyauchi A, et al. Surgical outcomes of posterior lumbar interbody fusion in elderly patients. *J Bone Joint Surg Am.* 2006;88(12):2714-20.
  13. Harms J, Rolinger H. A one-stager procedure in operative treatment of spondylolistheses: dorsal traction-reposition and anterior fusion. *Z Orthop Ihre Grenzgeb.* 1982;120(3):343-7.
  14. Kida K, Tadokoro N, Kumon M, et al. Can cantilever transforaminal lumbar interbody fusion maintain segmental lordosis for degenerative spondylolisthesis on a long-term basis? *Arch Orthop Trauma Surg.* 2014;134(3):311-5.
  15. Kettler A, Schmoelz W, Kast E, et al. In vivo stabilizing effect of a transforaminal compared with two posterior lumbar interbody fusion cages. *Spine.* 2005;30(22):665-70.
  16. Lowe TG, Hashim S, Wilson LA, et al. A biomechanical study of regional end plate strength and cage morphology as it relates to structural interbody support. *Spine.* 2004;29(21):2389-94.
  17. Closkey RF, Parsons JR, Lee CK, et al. Mechanics of interbody spinal fusion. Analysis of critical bone graft area. *Spine.* 1993;18(8):1011-5.
  18. Wang Y, Battié MC, Videman T. A morphological study of lumbar vertebral endplates: radiographic, visual and digital measurements. *Eur Spine J.* 2012;21(11):2316-23.
  19. Damasceno LHF, Catarin SRG, Campos AD, et al. Lumbar lordosis: a study of angle values and of vertebral bodies and intervertebral disc role. *Acta Ortop Bras.* 2006;14(4):193-8.
  20. Han SH, Hyun SJ, Jahng TA, et al. A comparative radiographic analysis of fusion rate between L4-5 and L5-S1 in a single level posterior lumbar interbody fusion. *Korean J Spine.* 2015;12(2):60-7.
  21. Kimura H, Shikata J, Odate S, et al. Risk factors for cage retro-pulsion after posterior lumbar interbody fusion. *Spine.* 2012;37(13):1164-9.
  22. Simon MJK, Halm HFH, Quante M. Perioperative complications after surgical treatment in degenerative adult de novo scoliosis. *BMC Musculoskelet Disord.* 2018;19(1):10.
  23. Yamato Y, Matsuyama Y, Hasegawa K, et al. A Japanese nationwide multicenter survey on perioperative complications of corrective fusion for elderly patients with adult spinal deformity. *J Orthop Sci.* 2017;22(2):237-42.
  24. Choi WS, Kim JS, Hur JW, et al. Minimally invasive transforaminal lumbar interbody fusion using banana-shaped and straight cages: radiological and clinical results from a prospective randomized clinical trial. *Neurosurgery.* 2018;82(3):289-98.
  25. Narain AS, Hijji FY, Markowitz JS, et al. Minimally invasive techniques for lumbar decompressions and fusions. *Curr Rev Musculoskelet Med.* 2017;10(4):559-66.

Spine Surgery and Related Research is an Open Access journal distributed under the Creative Commons Attribution-NonCommercial-NoDerivatives 4.0 International License. To view the details of this license, please visit (<https://creativecommons.org/licenses/by-nc-nd/4.0/>).