

Contents lists available at [ScienceDirect](http://www.sciencedirect.com)

# American Journal of Ophthalmology Case Reports

journal homepage: <http://www.ajocasereports.com/>

## Case report

# Juvenile X-linked retinoschisis responsive to intravitreal corticosteroids



Waseem H. Ansari\*, Andrew W. Browne, Rishi P. Singh

Cleveland Clinic Foundation, Cole Eye Institute, 9500 Euclid Avenue Mail Code i13, Cleveland, OH 44195, United States

## ARTICLE INFO

### Article history:

Received 6 July 2016  
Received in revised form  
17 November 2016  
Accepted 1 December 2016  
Available online 3 December 2016

### Keywords:

Juvenile X-linked retinoschisis  
Corticosteroids  
Macular edema

## ABSTRACT

**Purpose:** To report the case of an adult male with X-linked retinoschisis (XLRS) who presented with cystoid macular edema (CME) that responded consistently to treatment with intravitreal steroids.

**Observations:** A 39 year old male with unilateral presentation of CME after repair of a retinal detachment secondary to XLRS responded initially to an injection of intravitreal triamcinolone acetonide (IVTA). Central subfield thickness on OCT was reduced. Three months later, the CME recurred and he was unresponsive to topical treatment so repeat IVTA was given, and the CME once again was reduced dramatically. After the next recurrence, intravitreal dexamethasone implant treatment was initiated and successful at treating recurrences in 3 month intervals for 5 additional injections. Finally, an intravitreal fluocinolone acetonide implant was surgically placed with control of CME.

**Conclusions and importance:** Corticosteroids have never been reported to be effective in CME related to XLRS. Here, we document a case of a man who successfully had decrease of intraretinal fluid and schisis with treatment of intravitreal corticosteroids as demonstrated by spectral domain optical coherence tomography.

© 2016 Published by Elsevier Inc. This is an open access article under the CC BY-NC-ND license (<http://creativecommons.org/licenses/by-nc-nd/4.0/>).

## 1. Introduction

X-linked retinoschisis (XLRS) is an early onset genetic macular degeneration generally characterized by bilateral foveal and peripheral schisis at the layer of the nerve fiber layer. Abnormalities in the gene XLRS1, which codes for a protein retinoschisin, is thought to be important in cell adhesion and cause for the XLRS phenotype.<sup>1</sup> Patients can present with mild to severe visual impairment which correlates with the variable degree of schisis seen on clinical examination and optical coherence tomography (OCT).<sup>2</sup> Currently there is no approved treatment for XLRS and management involves treating complications, which commonly include vitreous hemorrhage and retinal detachments. Here we describe a case of unilateral progressive XLRS in a patient who underwent retinal detachment repair and was stabilized using intravitreal corticosteroids.

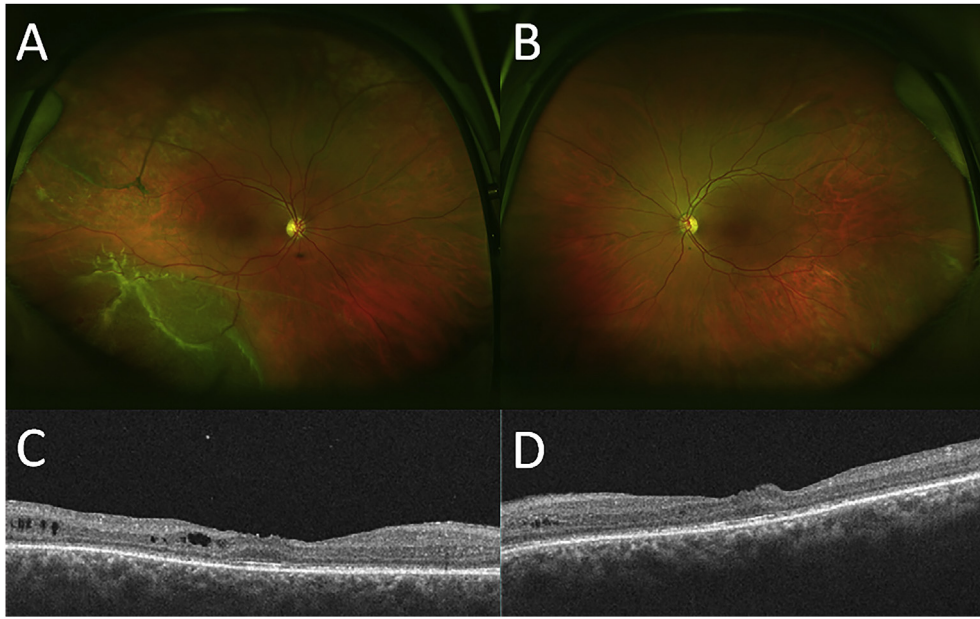## 2. Case report

The patient is a 39 year old male who presented to us with a retinal detachment in the right eye diagnosed by an outside facility. He has a family history of juvenile x-linked retinoschisis (XLRS). His mother was tested positive for the gene, and he has several cousins with XLRS. His visual acuity (VA) was 20/60-2 in the right eye, and 20/80 in the left eye. Exam of the right eye demonstrated macular schisis with chronic appearing inferior retinal detachment with atrophic holes and proliferative vitreoretinopathy. Left eye displayed an inferior area of retinoschisis. OCT confirmed chronic changes consistent with XLRS (Fig. 1). He underwent surgical repair of the right eye with scleral buckle and pars plana vitrectomy.

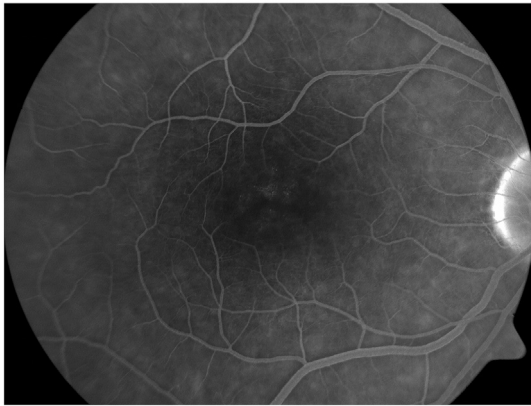At 2 months follow up, the retina was attached, however OCT in the right eye demonstrated increased macular edema and visual acuity decreased to 20/100 in both eyes. It was unknown if this was cystoid macular edema (CME) or schisis, however, fluorescein angiography was normal with no leakage (Fig. 2) The patient was observed for resolution of macular edema and one month later the edema had worsened with stable VA. The patient was treated with IVTA and two days later, he developed vitreous hemorrhage. Three days later there was resolution of hemorrhage and substantial reduction in macular thickness on OCT with VA improved to 20/80.

\* Corresponding author.

E-mail address: [Ansariw@ccf.org](mailto:Ansariw@ccf.org) (W.H. Ansari).



**Fig. 1.** Initial fundus photo of the right eye (A) showing inferior retinal detachment with vitreous stranding. Normal fundus photo of the left eye (B). Initial optical coherence tomography of the right eye (C) and the left eye (D) demonstrating flat macula with chronic changes of x-linked retinoschisis with minimal atrophy.



**Fig. 2.** Fluorescein angiography of the right eye demonstrating absence of petalloid leakage. The optical coherence tomography correlation is the horizontal scan found in Fig. 3A.

Two months later, the edema recurred with stable VA. He was observed. Next month, his VA was stable at 20/80, however there was progression of the intraretinal fluid with a typical schizoid appearance of vertically elongated columns in the retina. He was started on ketorolac and prednisolone. Six weeks later, there was no change in the OCT on topical treatment so was retreated with IVTA and the intraretinal fluid improved one month later. (Figs. 3 and 4).

Again after 2 months following the second IVTA, the edema recurred and he was given intravitreal dexamethasone implant (IVDI). Two months later, the edema had improved and the effect was sustained. Four months after the IVDI, the edema recurred and he was retreated with an IVDI. IOP increased to 28 a few days later, and the patient was started on glaucoma drops (brimonidine, timolol, dorzolamide). The IOP improved and the drops were discontinued.

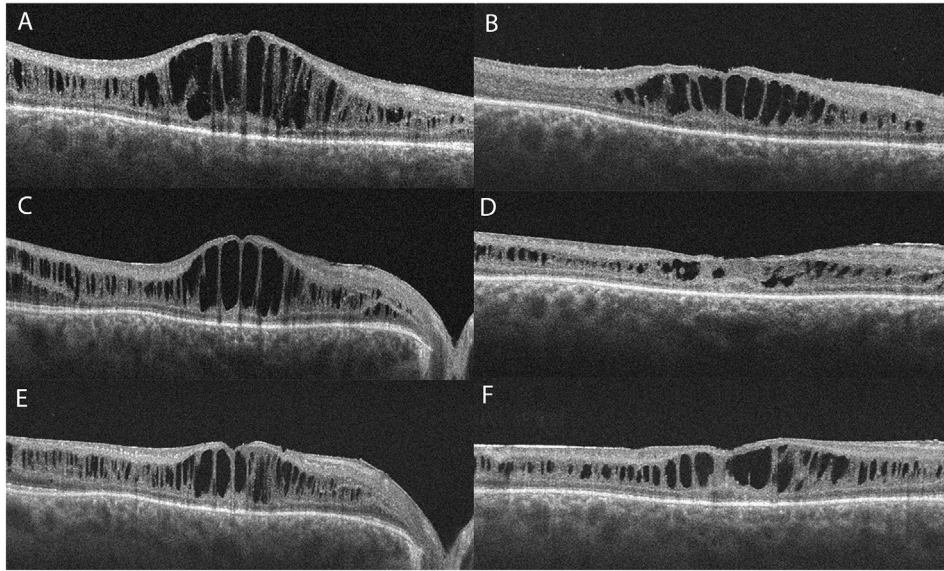
Two months after the second IVDI, he was diagnosed with 1 + posterior subcapsular cataract and underwent cataract

extraction with implantation of intraocular lens successfully. One month after the CEIOL he was injected with his third IVDI for increased edema and had subsequent improvement at follow up. This 3 month cycle of worsening and improvement was continued for 2 more injections a total of 5 IVDIs. Three months following the 5th IVDI, he underwent intravitreal fluocinolone implant implantation, and again demonstrated improvement in his postoperative OCT and stable VA at 20/80.

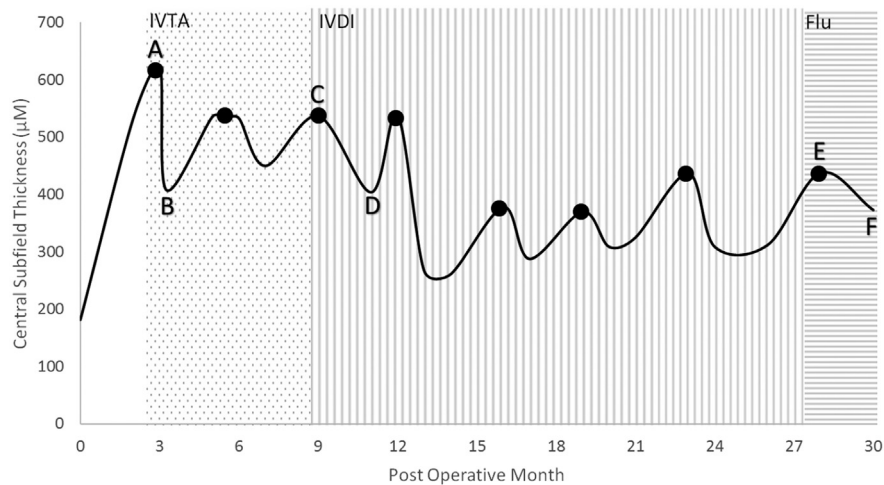
### 3. Discussion

XLRS was first described in 1898 by Gass and since then many advancements in genetics, diagnosis, and imaging characterization of XLRS have been made. However, there are still no approved and proven treatment options. Management at this time can include topical dorzolamide<sup>3</sup> or acetazolamide<sup>4</sup> for CME, low vision aids, and treatment of complications. Our patient demonstrated consistent improvement with intravitreal corticosteroid but failed topical therapy.

One theoretical mechanism of macular edema involves intracytoplasmic edema of Muller cells,<sup>5</sup> which may stem from an initial microvascular insult.<sup>6</sup> This same process may occur in XLRS, where abnormal retinoschisin accumulation causes dysfunctional Muller cells. Our patient may have worsening of retinoschisis acutely due to surgical trauma superimposed on an already compromised cellular architecture. Corticosteroids may decrease the amount of edema in the macula by reducing inflammatory leakage from microvascular injury.<sup>7</sup> The possibility of macular edema following intraocular surgery in the context of underlying XLRS was dispelled by an absence of petalloid leakage on fluorescein angiography. Furthermore, the fluid does not appear to be cystoid on OCT, and rather it has the appearance of schisis with vertically elongated “columns” of stretched middle retinal anatomy. The atypical appearance of this CME on FA and OCT suggest these cystoid changes are due to intrinsic XLRS disease itself rather than post-operative inflammatory changes. In addition, unlike many cases of post-surgical CME which resolve with topical treatment,<sup>8</sup> we observed CME requiring intravitreal steroid treatment which is not



**Fig. 3.** Horizontal optical coherence tomography scans of the right eye demonstrating improvement in retinoschisis and edema before (A) and after (B) intravitreal triamcinolone acetate, intravitreal dexamethasone implant (C,D), and intravitreal fluocinolone implant (E,F). See Figure 3 for correlation of images to postoperative dates.



**Fig. 4.** Decrease in central subfield thickness on optical coherence tomography (OCT) correlating to the use of intravitreal triamcinolone acetate (dotted region), intravitreal dexamethasone implant (vertical lined region), and intravitreal fluocinolone implant (horizontal lined region). The dots on the line represent respective injections corresponding to the shaded region, and the letters correspond to the OCT images seen in Fig. 2. IVTA = intravitreal triamcinolone acetate, IVDI = intravitreal dexamethasone implant, Flu = fluocinolone implant.

typically required in inflammatory CME post-surgically. Wang et al. previously reported a case of a patient with XLRS who developed CME after cataract extraction which failed topical therapy and only resolved after sub-tenon injection of corticosteroids.<sup>9</sup> Although there was great anatomical variation after treatment, visual acuity seemed to remain relatively stable throughout the treatment periods. This may reflect irreversible damage that has occurred which would not improve with treatment. The natural history of XLRS can demonstrate a gradual decline in visual acuity,<sup>10</sup> and a protective effect from the corticosteroids preventing further vision loss cannot be ruled out in our case. A larger controlled study comparing treatment with intravitreal steroids versus sham would need to be performed to determine if there is a functional outcome that correlates with the anatomical outcome observed in this patient.

The natural history of X-linked retinoschisis shows a retinal detachment rate of 11%,<sup>11</sup> however no publications have addressed

the postoperative complications of retinal detachment repair in X-linked retinoschisis. In addition, no reliable treatments currently exist for X-linked retinoschisis. This case report demonstrates an unusual case of X-linked foveal retinoschisis with progressive CME, retinal detachment repair and requiring repeat intravitreal corticosteroids for management of CME. An expanded cohort of XLRS patients with CME treated with intravitreal steroids will further help guide management of vision loss in this condition. To date our patient's CME remains controlled with improved vision after intravitreal fluocinolone implant.

#### 4. Patient consent

Consent to publish the case report was not obtained. This report does not contain any personal information that could lead to the identification of the patient.

**Funding**

No funding or grant support.

**Conflict of interest**

The following authors have no financial disclosures: WHA, RPS, AWB.

**Authorship**

All authors attest that they meet the current ICMJE criteria for Authorship.

**Acknowledgements**

None.

**References**

1. Tantri A, Vrabec TR, Cu-Unjieng A, Frost A, Annesley Jr WH, Donoso LA. X-linked retinoschisis: a clinical and molecular genetic review. *Surv Ophthalmol.* 2004;49(2):214–230.
2. Gregori NZ, Berrocal AM, Gregori G, et al. Macular spectral-domain optical coherence tomography in patients with X linked retinoschisis. *Br J Ophthalmol.* 2009;93:373–378.
3. Genead MA, Fishman GA, Walia S. Efficacy of sustained topical dorzolamide therapy for cystic macular lesions in patients with x-linked retinoschisis. *Arch Ophthalmol.* 2010;128(2):190–197.
4. Ghajarnia M, Gorin MB. Acetazolamide in the treatment of x-linked retinoschisis maculopathy. *Arch Ophthalmol.* 2007;125:571–573.
5. Yanoff M, Fine BS, Brucker AJ, Eagle Jr RC. Pathology of human cystoid macular edema. *Surv Ophthalmol.* 1984;28(suppl):505–511.
6. Mooy CM, Ingeborgh L, Baarsma S, Paridaens DA, Kraaijenbrink T, Bergen A, Weber BH. Hereditary x-linked juvenile retinoschisis: a review of the role of müller cells. *Arch Ophthalmol.* 2002;120(7):979–984.
7. Wang K, Wang Y, Gao L, Li X, Li M, Guo J. Dexamethasone inhibits leukocyte accumulation and vascular permeability in retina of streptozotocin-induced diabetic rats via reducing vascular endothelial growth factor and intercellular adhesion molecule-1 expression. *Biol Pharm Bull.* 2008;31(8):1541–1546.
8. Loewenstein A, Zur D. Postsurgical cystoid macular edema. *Dev Ophthalmol.* 2010;47:148–159.
9. Wang JK, Lin WC. Posterior subtenon injection of triamcinolone acetonide after phacoemulsification in a patient with x-linked retinoschisis. *Optom. Vis Sci.* 2013;90(10):274–277.
10. Roesch MT, Ewing CC, Gibson AE, Weber BH. The natural history of X-linked retinoschisis. *Can J Ophthalmol.* 1998;33(3):149–158.
11. Kellner U, BrümmerMichael SH, Wessing F. X-linked congenital retinoschisis. *Graefe's Archiv. Clin Exp Ophthalmol.* 1990;228:432–437.