



# Safety and Efficacy of Genicular Artery Embolization for the Treatment of Knee Pain Secondary to Osteoarthritis—Initial Indian Experience

Ujjwal Gorsl<sup>1</sup> Damandeep Singh<sup>1</sup> Mandeep Kang<sup>1</sup> Vishal Kumar<sup>2</sup> Mahesh Prakash<sup>1</sup>  
Sreedhara B.C.<sup>1</sup>

<sup>1</sup> Department of Radiodiagnosis and Imaging, Postgraduate Institute of Medical Education and Research, Chandigarh, India

<sup>2</sup> Department of Orthopaedics, Postgraduate Institute of Medical Education and Research, Chandigarh, India

Address for correspondence Mandeep Kang, MD, Department of Radiodiagnosis and Imaging, Postgraduate Institute of Medical Education and Research, Chandigarh 160012, India (e-mail: drmkang@gmail.com).

Indian J Radiol Imaging 2024;34:37–43.

## Abstract

**Background** Osteoarthritis (OA) is the commonest form of arthritis with pain and disability as hallmark symptoms. Despite various nonpharmacologic, pharmacologic, and surgical approaches, pain control may be hard to achieve. Over the last few years, few studies have been conducted on managing knee OA using novel endovascular genicular artery embolization (GAE) with varied outcomes. No such study has been reported in India yet to the best of our knowledge.

**Purpose** The main aim of this article was to evaluate the efficacy and safety of transcatheter GAE in relieving knee pain in patients with mild-to-moderate OA.

**Materials and Methods** Ten patients with radiographic knee OA and moderate-to-severe pain refractory to conservative therapy were enrolled in a prospective observational study. GAE was performed with 100 to 300- $\mu$ m spherical particles. Patients were assessed with magnetic resonance imaging at the baseline. Visual analog scale (VAS) and Western Ontario and McMaster Universities Osteoarthritis Index (WOMAC) were used to assess pain and disability respectively at the baseline, 1 month, and 3 months. Clinical success was asserted by the downstaging of VAS and WOMAC scores. Adverse events were recorded at all-time points. Descriptive and inferential statistics have been performed using SPSS. A *p*-Value less than 0.05 was considered statistically significant.

**Results** Embolization of at least 1 genicular artery was achieved in all the patients (100%). Clinical success was demonstrated in 08 (80%) of the patients. Median VAS reduced from 07 at baseline to 3.5 at 3-month follow-up ( $p < 0.001$ ). Median WOMAC score improved from 53 to 23.50 at 3-month follow-up ( $p < 0.001$ ). Minor complications were seen in two patients in the form of puncture site hematoma and mild petechial spots over the knee.

**Conclusion** Our pilot study demonstrates GAE as a safe and efficacious procedure to treat knee pain secondary to OA. Further randomized comparative studies with a larger sample size are needed to determine the true treatment effect versus the placebo effect.

## Keywords

- ▶ embolization
- ▶ genicular artery embolization
- ▶ osteoarthritis
- ▶ knee pain

article published online  
August 16, 2023

DOI <https://doi.org/10.1055/s-0043-1771159>.  
ISSN 0971-3026.

© 2023. Indian Radiological Association. All rights reserved.  
This is an open access article published by Thieme under the terms of the Creative Commons Attribution-NonDerivative-NonCommercial-License, permitting copying and reproduction so long as the original work is given appropriate credit. Contents may not be used for commercial purposes, or adapted, remixed, transformed or built upon. (<https://creativecommons.org/licenses/by-nc-nd/4.0/>)  
Thieme Medical and Scientific Publishers Pvt. Ltd., A-12, 2nd Floor, Sector 2, Noida-201301 UP, India

## Introduction

Osteoarthritis (OA) is the commonest form of arthritis with pain and disability as the main symptoms. Knee pain secondary to OA is seen in around 40% of the population over 55 years, and around 10% of the population experience knee OA symptoms that are incapacitating.<sup>1</sup> It is a complex, multifactorial disease for which no definite nonsurgical treatment exists.<sup>2,3</sup> Main focus of treatment in OA is pain relief.<sup>4,5</sup>

Patients with mild-to-moderate OA are often treated with medication and intra-articular injections. However, its management is challenging among patients who do not respond to oral medications or intra-articular injections.<sup>5</sup> Long-term use of analgesics has its complications, while the efficacy of intra-articular injections of hyaluronic acid and steroids has inconclusive evidence in the literature.<sup>6</sup>

The majority of the patients with OA are associated with chronic inflammation and synovial angiogenesis.<sup>7,8</sup> It is believed that angiogenesis, in conjunction with sensory nerve growth, plays a crucial role in the development of inflammation, pain, and architectural bone and cartilage damage.<sup>9</sup> Additionally, bone osteophytes and the articular osteochondral junction exhibit increased angiogenesis.<sup>10,11</sup> Hence, a possible treatment for abnormal angiogenesis and accompanying perivascular nerve growth is warranted.

Embolization of these newly formed blood arteries with various embolic agents has proven to be a successful alternative treatment for OA. The use of imipenem/cilastatin sodium, or Embozene microspheres in previous research has reduced pain perception scores in patients with mild-to-moderate knee OA.<sup>5</sup> Furthermore, endovascular genicular artery embolization (GAE) for managing knee OA has been conducted in different parts of the world.<sup>12-15</sup> These studies are very few with limited small sample size and their results need validation. There is paucity of literature and data regarding GAE within India.

The purpose of this study was to explore the role of GAE as a treatment modality to treat mild-to-moderate OA. The primary objective of the study was to evaluate the safety and efficacy of transcatheter GAE in relieving knee pain in a patient with mild and moderate OA. The secondary objectives were to evaluate the vascular pattern around the OA knee joint and correlate with the site of pain and to explore the preprocedure magnetic resonance imaging (MRI) features and correlate with response to GAE.

## Materials and Methods

This hospital-based prospective observational study was performed in the Department of Radiodiagnosis and Orthopedics at Postgraduate Institute of Medical Education and Research, Chandigarh. Ethical approval was obtained from Institutional Ethical Committee. The patient information sheet was provided to the patients and written informed consent was obtained from them. All the procedures were conducted according to the principles of the Declaration of Helsinki. It was conducted for one and half years approxi-

mately. The patients were enrolled from February 2021 to March 2022 and follow-up completed by June 2022. Training and calibration of the investigators were done before the start of the study.

### Inclusion and Exclusion Criteria

All included patients had moderate to severe knee pain (visual analog scale [VAS] >5, Western Ontario and McMaster University Osteoarthritis Index [WOMAC] score >48) and were resistant to at least 3 months of conservative therapies (anti-inflammatory drugs, physical therapy, muscle strengthening, and intra-articular injection of hyaluronic acid). Other criteria's included Kellgren-Lawrence [K-L] grade 1 to 3, normal renal function, as studied by estimated glomerular filtration rate (calculated from serum creatinine), and no contraindications to embolization agents and iodinated contrast agents (previous episodes of severe anaphylaxis).

Patients were excluded if they had a local infection at the knee joint, systemic malignancy, critical limb ischemia, rheumatoid arthritis, prior knee surgery, presence of osteonecrosis on preprocedure MRI, and refusal to participate in the study.

### Data Collection

The study involved the recording of detailed clinical history along with radiological and biochemical investigations. The patient's clinical history included assessment of knee pain and its severity, disability, duration of symptoms, duration, and details of pharmacologic management, other minimally invasive procedures (intra-articular steroid injections), and physiotherapy. Pain severity was assessed using the VAS on a scale of 0 to 10 (a score of 0-3 was categorized as mild, 4-6 as moderate, and 6-10 as severe pain). Disability was measured by using the WOMAC questionnaire, which includes 24 questions on daily activities. The WOMAC scoring system consists of three subscale scores for pain, physical function, and joint stiffness. Clinical examination for the site, the severity of tenderness, and range of movements in the knee joint were performed by an orthopaedic surgeon.

Radiological investigations like X-ray knee anterior-posterior and lateral view were performed. K-L grade was assigned depending upon the X-ray findings. MRI assessment was performed within 1 week before treatment. MRI examination was performed at 3tesla MRI. It included multiplanar pre- and postcontrast T1-weighted images, T2-weighted images as well as proton density fat-saturated and multiplanar short tau inversion recovery sequences. Images were interpreted by a musculoskeletal radiologist and features of OA were evaluated. Images were analyzed for the presence and degree of cartilaginous defect, osteophyte formation, subchondral cyst, and bone marrow lesions. In addition, meniscal injury, joint effusion, and synovitis were also assessed. Blood biochemistry investigations such as kidney function tests (blood urea and serum creatinine) and coagulogram (platelet count and international normalized ratio) were obtained at baseline before embolization.

### Embolization Technique

Under regional site anesthesia, guided percutaneous femoral vascular access was achieved via a 5F introducer sheath. The common femoral artery was accessed using an ipsilateral anterograde approach in all the patients. After intravenous administration of 2,500 IU heparin, a 5F catheter was advanced into the popliteal artery. Digital subtraction angiography was performed by injecting 6 to 8 mL of low molecular weight iodinated water-soluble contrast medium using optimum uniform hand pressure at an approximate flow rate of 4 mL/s. Precise depiction of the descending genicular artery, superior and inferior medial genicular arteries, superior and inferior lateral genicular arteries, median genicular artery, and recurrent genicular artery was done. After identifying abnormal neovascularity and correlating them with a site of pain, a microcatheter was selectively advanced into the targeted arteries, and nitroglycerin diluted with saline was injected into each artery to prevent spasms of these small caliber arteries. After that particulate spherical particle (100–300 microns) diluted with contrast was injected until abnormal neovascularity was eliminated. Postprocedural hemostasis of the femoral puncture site was achieved using hand-assisted manual firm compression for at least 10 minutes and limb immobilization for 8 hours after sheath removal. The subjects were observed for 12 hours before discharge. The end-points of the procedure ascertained were embolization of at least one genicular artery with the elimination of abnormal neovascularity or reporting of any adverse events. All procedures were performed by an interventional radiologist.

### Measurement of Clinical Success

The clinical evaluation was performed by orthopaedic surgeons at baseline, immediate postprocedure, 1 month, and 3 months after the procedure. The parameters for clinical success were asserted by the downstaging of VAS and WOMAC scores. The primary end-point established was more than or equal to 2 scale reduction in pain score as evaluated by VAS and more than or equal to 30% improvement in WOMAC pain score. The secondary end-point was more than or equal to 50% downstaging in WOMAC total score.

### Safety of the Treatment

This was assessed by observing for local adverse effects (related to the site of injection and arterial access) or systemic effects on the kidney or liver. Postprocedural complications in form of necrosis, skin ulcer, knee tendon/ligament injury, loco regional peripheral paresthesia, and other complications were reviewed. Major complications are the ones that result in prolonged hospitalization, the unplanned requirement of medical attention, irreversible damage, or death.

### Statistical Analysis

Statistical analyses were performed using IBM SPSS Statistics for Windows, Version 25.0. IBM Corp, Armonk, New York, United States. Results on continuous measurement are pre-

sented as mean and standard deviation, median, interquartile range, and categorical as frequency and percentage. Inferential statistics like Friedman's test were used to compare values over three different periods. Posthoc analysis was performed using Wilcoxon signed-rank tests. A *p*-value less than 0.05 was considered statistically significant. Bonferroni adjustment was done for the posthoc test resulting in a *p*-Value of 0.017 (0.05/3).

### Results

A total of 10 patients (males = 02, females = 08) were enrolled in the study. The mean age of the study participants was  $55.9 \pm 7.65$  years. The majority of the patients were overweight with a mean body mass index (BMI) of  $28.15 \text{ kg/m}^2$ . Four patients reported pain in the medial and the patellofemoral compartment. Bilateral knee discomfort and restricted motion at the knee joint were reported by 50% of the patients. The duration of pain was more than 12 months in 50% of the patients. All patients had received nonsteroidal anti-inflammatory drugs (NSAIDs) as baseline pharmacological therapy, with 40% of the cohort reporting having received it for over 6 months. None of the patients reported taking opioids for their pain. In addition, 60% of the patients reported having taken some form of physiotherapy, and 10% had received intra-articular steroid injection. None of the 10 patients reported receiving nerve blocks; nor did any patient undergo prior knee surgery (► **Table 1**).

Radiographs showed mild OA in one patient (grade 1), and moderate knee OA in nine patients (grade 3/4). On MRI evaluation, the cartilaginous defect was noted in 60% of the cases, while marrow edema could be picked up in 90% of the patients. The meniscal injury was present in 03 patients (grade 1 injury in two patients and grade 2 injury in the third patient). Joint effusion and abnormal synovial hypervascularity could be appreciated in all patients (► **Figs. 1** and **2**). An abnormal vascular blush (consistent with neo angiogenesis) could be seen in all 10 patients (► **Table 1**).

Technical success was attained in 100% of the cases. In 80% of the cases, the embolization could be performed with less than 2 mL of the embolizing solution. The mean number of arteries successfully embolized per subject was 03. The target arteries were identified, and their frequencies have been summarized in ► **Table 2**. No major complications were encountered in any of the patients. Minor complications were seen in two patients in the form of puncture site hematoma in one patient and mild petechial spots over the knee in one patient. Both resolved spontaneously on follow-up. No subsequent embolization procedures were required in the study.

Both primary and secondary end-point clinical success was achieved in eight (80%) patients. The comparison of VAS score, pain WOMAC, and total WOMAC score is presented in ► **Tables 3** and **4**. All three parameters reduced significantly from baseline to 3 months ( $p < 0.05$ ). In the post-embolization assessment, 60% of patients stopped taking NSAIDs for pain and only two (20%) patients out of six continued to receive physiotherapy for pain management.

**Table 1** Baseline characteristics

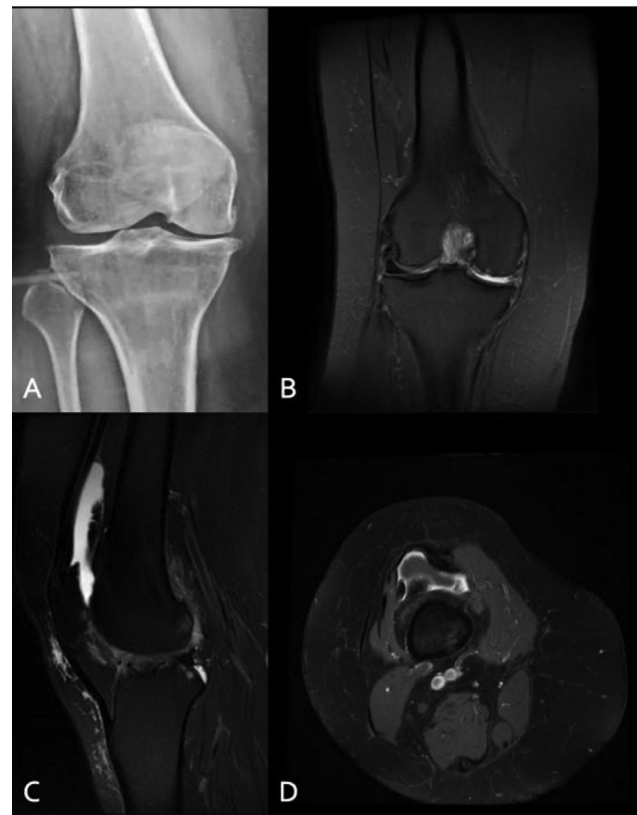Age	Mean $\pm$ SD (range)	55.9 $\pm$ 7.65 years (44–68 years)
Gender	Males	02 (20)
	Females	08 (80)
BMI	Normal	01 (10)
	Overweight	07 (70)
	Obese	02 (20)
Site of pain	Bilateral	05 (50)
	Left	02 (20)
	Right	03 (30)
Compartment Involved	Medial	04 (40)
	Patellofemoral	04 (40)
	Unspecified	02 (20)
Duration of pain	<12 months	05 (50)
	>12 months	05 (50)
Use of NSAIDs	Present	10 (100)
Physiotherapy	< 6 months	04 (40)
	> 6 months	02 (20)
Intra-articular steroid injection	Present	01 (10)
Kellgren–Lawrence grade of OA	Grade 1	01 (10)
	Grade 2 and 3	09 (90)
MRI findings	Cartilaginous defect	06 (60)
	Marrow edema	09 (90)
	Meniscal injury	03 (30)
	Joint effusion and abnormal synovial hypervascularity	10 (100)

Abbreviations: BMI, body mass index; MRI, magnetic resonance imaging; NSAIDs, nonsteroidal anti-inflammatory drugs; OA, osteoarthritis; SD, standard deviation.

## Discussion

The findings of the study showed a significant reduction in pain and disability among the study participants. Technical success in 100% and clinical improvement among 80% of the participants at 3 months follow period proves the safety and efficacy of this novel technique of GAE in patients with mild-to-moderate OA who do not respond to conservative treatment. Understanding potential anastomosis pathways, technical details, awareness of the end-point beyond which embolization should be stopped, and most significantly, competence with hardware such as microcatheters by the interventional radiologist is necessary for performing a safe GAE. To the best of the author's knowledge, only a few studies have been published so far with none being reported from India.

Obesity is a well-known risk factor for symptomatic knee OA and weight management is considered important

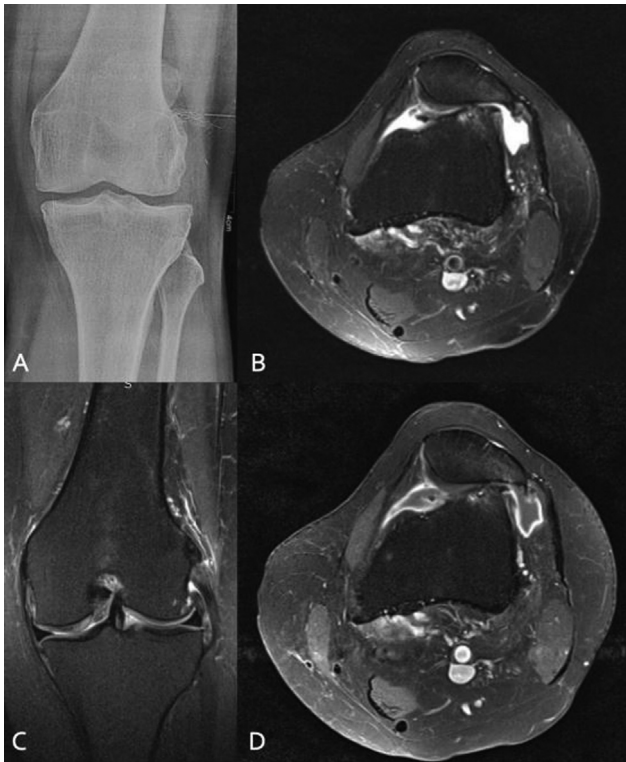

**Fig. 1** A 59-year-old female with right knee pain. (A) X-ray right knee (anteroposterior view) showing reduction of joint space (medial > lateral) with marginal osteophytes. (B) Proton density (PD) fat-saturated coronal image showing cartilage loss and exposure of subchondral bone in the medial femoral condyle and medial tibial plateau. (C) PD fat-saturated sagittal images showing reactive joint effusion, patchy marrow edema in medial femoral condyle (D). Postgadolinium T1-weighted axial image showing synovitis.

while treating patients who have OA.<sup>16</sup> Nearly 90% of patients were overweight or obese. The mean BMI of patients in this study was 28.15 kg/m<sup>2</sup> that is both lower than reported by Bagla et al<sup>15</sup> (35 kg/m<sup>2</sup>) and higher than Okuno et al<sup>12</sup> (25 kg/m<sup>2</sup>). Despite variations in mean BMI, the study found similar reductions in pain and disability. It is generally documented that even patients with unilateral knee OA at baseline eventually advanced to bilateral disease in 80% of the cases in 12 years.<sup>16</sup> Bilateral disease was seen in 50% of patients.

In line with earlier research in the literature,<sup>12,15</sup> abnormal hyperemic synovium in form of abnormal angiographic blush was visualized in the site of maximum knee pain in all subjects (–Figs. 3 and 4). The technical success achieved in all the patients in this study is similar to Okuno et al<sup>12</sup> and Bagla et al.<sup>15</sup> The mean number of arteries successfully embolized per patient in this study was three that is in concordance with the findings of Okuno et al<sup>12</sup> who embolized a mean of 3.2 arteries per patient and Bagla et al<sup>15</sup> who embolized a mean of 2.5 arteries per patient.

The primary and secondary end-point clinical success achieved in eight (80%) patients is consistent with the findings of Okuno et al<sup>12</sup> who first demonstrated the use of transcatheter GAE in a patient with moderate OA. Despite the



**Fig. 2** A 44-year-old female with left knee pain. (A) X-ray left knee (anteroposterior view) showing no significant abnormality. (B) Proton-density (PD) fat-saturated axial image showing mild joint effusion with lateral patellar subluxation with degenerative changes in the lateral femoral condyle and lateral patellar facet with thinning and fraying of the patellar cartilage. (C) PD fat-saturated coronal image showing thickened hyperintense lateral collateral ligament with small subchondral cysts in the lateral femoral condyle. (D) Postgadolinium T1-weighted axial image showing synovitis.

**Table 2** Target arteries in the study population

Target arteries	No. of cases	Percentage
Descending genicular artery	09	90.0
Medial superior genicular arteries	09	90.0
Medial inferior genicular arteries	07	70.0
Lateral inferior genicular arteries	03	30.0
Anterior tibial recurrent artery	01	10.0
Median genicular arteries	01	10.0
Lateral superior genicular arteries	01	10.0

technical success, a significant clinical response could not be achieved in two patients. These patients were obese and had K-L grade 3 on the radiograph. If compounding risk factors are not addressed, GAE may not result in positive long-term benefits. Higher K-L grades, as opposed to those with moderate OA (K-L grades 1 and 2), may also not respond to GAE.<sup>12</sup> Further, MRI revealed full-thickness cartilage defects and meniscal tears in these two patients, factors that are known to be associated with poor response to GAE.<sup>17</sup> However, due to the very small sample size statistical significance could not be

**Table 3** Comparison of median VAS score, pain WOMAC score, and total WOMAC score at different time intervals

Parameters	Time intervals	Mean ± SD	Median (IQR)	p-Value
VAS score	Pre-treatment	7.40 ± 0.69	7.0 (7-18)	0.001 <sup>a</sup>
	Post 1 month	5.20 ± 1.23	5.0 (4-6.23)	
	Post 3 months	4.10 ± 1.28	3.5 (3-5.25)	
Pain WOMAC score	Pre-treatment	14.30 ± 2.05	14 (12-16.25)	0.001 <sup>a</sup>
	Post 1 month	8.30 ± 2.86	08 (06-10)	
	Post 3 months	6.40 ± 3.43	5.50 (3.75-8.50)	
Total WOMAC score	Pre-treatment	54.20 ± 4.39	53.0 (50-57.75)	0.001 <sup>a</sup>
	Post 1 month	36.0 ± 8.71	35.0 (28-43.25)	
	Post 3 months	23.60 ± 7.60	23.50 (18-28)	

Abbreviations: IQR, interquartile range; SD, standard deviation; VAS, visual analog scale; WOMAC, Western Ontario and McMaster Universities Osteoarthritis Index.

<sup>a</sup>Statistically significant.

inferred. One of these patients underwent intra-articular joint injection, whereas the other underwent a total knee replacement.

Okuno et al used imipenem/cilastatin sodium as a temporary embolic agent and the permanent irreversible embolic agent was used in case imipenem/cilastatin was contraindicated. Contrarily, the permanent embolic agent 100 to 300 spherical particles (Embospheres, Merit Medical Systems, Inc. 1600 West Merit Parkway South Jordan, Utah) was used in this study due to a lack of availability and lack of prior experience employing this agent for embolization. Also, these particles are routinely used for prostate artery embolization. Bagla et al<sup>15</sup> used a permanent embolic 75 or 100 µm spherical particles agent.

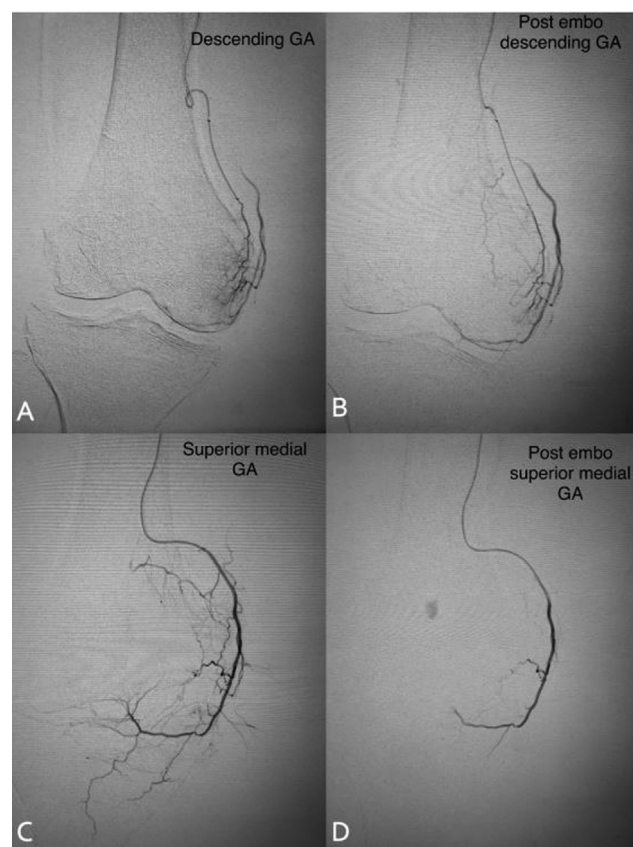
No major adverse events following GAE for endovascular treatment of musculoskeletal joint-related pain are reported to date<sup>12-15</sup> including in this study. Hematoma around the puncture site was seen in 1 patient (10%) that was self-limiting. One patient (10%) developed discoloration of overlying skin likely due to transient cutaneous ischemia that resolved on 1-month follow-up. However, the study by Bagla et al reported skin discoloration in 65%, and plantar sensory paraesthesia was seen in 10% of patients. Plantar sensory paraesthesia was reported in this study. This might be explained by the use of a larger particle size (100-300 µm) as compared with the previous study. Similarly, sized particles were used by Little et al<sup>18</sup> who used cone-beam-computed tomography, did GAE using 100 to 300 µm particles, and applied icepack over the skin to be embolized. Around 12% of subjects experienced nontarget skin tissue embolization in their study. This study did not use icepack in any of the patients and still, there was skin discoloration only

**Table 4** Posthoc comparison of median VAS score, pain WOMAC score, and total WOMAC score

	VAS score Z value; p-Value	Pain WOMAC score Z value; p-Value	Total WOMAC score Z value; p-Value
Post 1 month— Pretreatment	-2.694; 0.007*	-2.81; 0.005*	-2.81; 0.005*
Post 3 months— Pretreatment	-2.82; 0.005*	-2.81; 0.005*	-2.81; 0.005*
Post 3 months— Post 1 month	-2.81; 0.005*	-2.81; 0.006*	-2.81; 0.005*

Abbreviations: VAS, visual analog scale; WOMAC, Western Ontario and McMaster Universities Osteoarthritis Index.

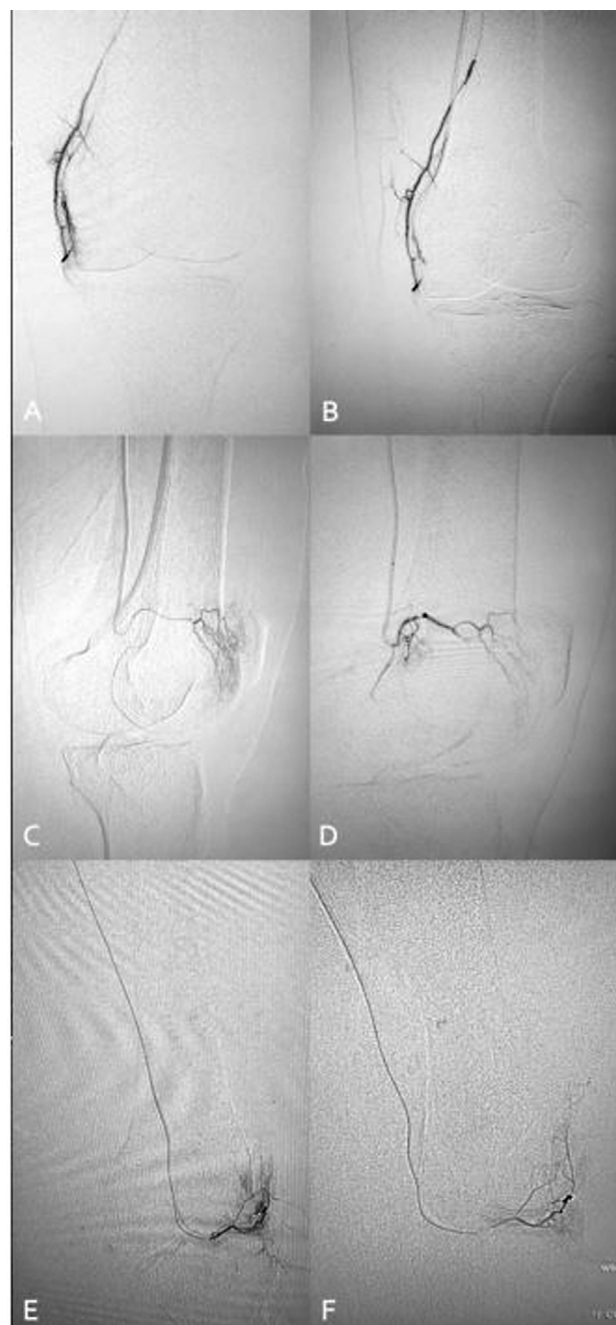
\*Statistically significant.



**Fig. 3** (A) Angiography of the branches of the descending genicular artery (GA) shows hypervascular "blush" over the medial inferior aspect of the knee. (B) Angiography after embolization depicts the end-point of "pruning" of the hypervascular synovium. The parent GA remains patent. (C) Angiography of the branches of the superior medial GA shows hypervascular "blush over the medial inferior aspect of the knee." (D) Angiography after embolization depicts the pruning of the hypervascular synovium with patent parent artery.

in one patient (10%). The use of smaller microcatheters and superselective embolization while avoiding cutaneous branches carefully may be one of the explanations for it.

The need for pain medications also decreased significantly post-GAE. Patients taking oral NSAIDs reduced from 100 to 40% and patients availing physiotherapy reduced from 60 to 20% at



**Fig. 4** (A) Angiography of the branches of the descending genicular artery shows hypervascular "blush" over the medial inferior aspect of the knee. (B) Angiography after embolization depicts the end-point of "pruning" of the hypervascular synovium. The parent genicular artery remains patent. (C) Angiography of the branches of the superolateral genicular artery shows hypervascular "blush" over lateral superior aspect of the knee. (D) Angiography after embolization depicts the end-point of "pruning" of the vessel. The parent genicular artery remains patent. (E) Angiography of the inferior lateral genicular artery shows hypervascular "blush" over the inferolateral aspect of the knee. (F) Angiography after embolization depicts the end-point of "pruning" of the hypervascular synovium with patent parent artery.

3 months follow-up. Reduction in need for pain medication was reported by Okuno et al<sup>12</sup> and Bagla et al<sup>15</sup>.

The study has a few limitations too like the small study population size, short-term follow-up, and the absence of an experimental control arm to analyze the contribution of

placebo to the observed effect. It is vital to consider the effect of a placebo in any interventional procedure that is planned for pain relief. The complexity of analyzing pain outcomes after an interventional procedure should not be underestimated, and it must be given top priority before designing future studies in calculating appropriate responses to GAE. Owing to the small sample size, subanalyses to identify parameters of ideal patient selection could not be performed. Also, the study period was short, and it was not sufficient to identify the permanence of GAE in our study group. Assessment of pain-free period is an important determinant for performing GAE in any patient

In conclusion, GAE in subjects with mild-to-moderate knee OA using permanent spherical microspheres is a safe and interventionally achievable procedure with promising benefits at early post-treatment follow-up. This study corroborates the growing evidence that GAE improves pain, joint function, and overall quality of life in patients with knee OA. Evaluating GAE with more advanced study designs and with randomization is expected to produce higher-quality evidence to support the role of GAE in the nonsurgical management of OA.

#### Informed Consent

Informed consent was taken from the concerned patient.

#### Funding

None.

#### Conflict of Interest

None declared.

#### References

- 1 Peat G, McCarney R, Croft P. Knee pain and osteoarthritis in older adults: a review of community burden and current use of primary health care. *Ann Rheum Dis* 2001;60(02):91–97
- 2 Allen KD, Golightly YM. State of the evidence. *Curr Opin Rheumatol* 2015;27(03):276–283
- 3 Blagojevic M, Jinks C, Jeffery A, Jordan KP. Risk factors for onset of osteoarthritis of the knee in older adults: a systematic review and meta-analysis. *Osteoarthritis Cartilage* 2010;18(01):24–33
- 4 Dominick KL, Ahern FM, Gold CH, Heller DA. Health-related quality of life and health service use among older adults with osteoarthritis. *Arthritis Rheum* 2004;51(03):326–331
- 5 Okuno Y, Korchi AM, Shinjo T, Kato S. Transcatheter arterial embolization as a treatment for medial knee pain in patients with mild to moderate osteoarthritis. *Cardiovasc Intervent Radiol* 2015;38(02):336–343
- 6 McAlindon TE, Bannuru RR, Sullivan MC, et al. OARSI guidelines for the non-surgical management of knee osteoarthritis. *Osteoarthritis Cartilage* 2014;22(03):363–388
- 7 Robinson WH, Lepus CM, Wang Q, et al. Low-grade inflammation as a key mediator of the pathogenesis of osteoarthritis. *Nat Rev Rheumatol* 2016;12(10):580–592
- 8 Bonnet CS, Walsh DA. Osteoarthritis, angiogenesis and inflammation. *Rheumatology (Oxford)* 2005;44(01):7–16
- 9 Mapp PI, Walsh DA. Mechanisms and targets of angiogenesis and nerve growth in osteoarthritis. *Nat Rev Rheumatol* 2012;8(07):390–398
- 10 Ashraf S, Mapp PI, Walsh DA. Contributions of angiogenesis to inflammation, joint damage, and pain in a rat model of osteoarthritis. *Arthritis Rheum* 2011;63(09):2700–2710
- 11 Ashraf S, Wibberley H, Mapp PI, Hill R, Wilson D, Walsh DA. Increased vascular penetration and nerve growth in the meniscus: a potential source of pain in osteoarthritis. *Ann Rheum Dis* 2011;70(03):523–529
- 12 Okuno Y, Korchi AM, Shinjo T, Kato S, Kaneko T. Midterm clinical outcomes and MR imaging changes after transcatheter arterial embolization as a treatment for mild to moderate radiographic knee osteoarthritis resistant to conservative treatment. *J Vasc Interv Radiol* 2017;28(07):995–1002
- 13 Lee SH, Hwang JH, Kim DH, et al. Clinical outcomes of transcatheter arterial embolisation for chronic knee pain: mild-to-moderate versus severe knee osteoarthritis. *Cardiovasc Intervent Radiol* 2019;42(11):1530–1536
- 14 Landers S, Hely R, Page R, et al. Genicular artery embolization to improve pain and function in early-stage knee osteoarthritis—24-month pilot study results. *J Vasc Interv Radiol* 2020;31(09):1453–1458
- 15 Bagla S, Piechowiak R, Hartman T, Orlando J, Del Gaizo D, Isaacson A. Genicular artery embolization for the treatment of knee pain secondary to osteoarthritis. *J Vasc Interv Radiol* 2020;31(07):1096–1102
- 16 Kulkarni K, Karssiens T, Kumar V, Pandit H. Obesity and osteoarthritis. *Maturitas* 2016;89:22–28
- 17 Choi JW, Ro DH, Chae HD, et al. The value of preprocedural MR imaging in genicular artery embolization for patients with osteoarthritic knee pain. *J Vasc Interv Radiol* 2020;31(12):2043–2050
- 18 Little MW, Gibson M, Briggs J, et al. Genicular artery embolization in patients with osteoarthritis of the knee (GENESIS) using permanent microspheres: interim analysis. *Cardiovasc Intervent Radiol* 2021;44(06):931–940