



Do You See What I See? A Case of Alice in Wonderland Syndrome With EEG Correlate

Arya Shah, MD¹, Setty M. Magaña, MD, PhD², and Paul E. Youssef, DO² 

Abstract

Alice in Wonderland syndrome is a disorienting perceptual disorder characterized by discrete episodes of bizarre visual illusions and spatial distortions which has been associated with numerous neurologic and psychiatric conditions. Little is known regarding the electrophysiologic correlates of the visual symptoms described in this syndrome. The authors report the unique case of an 8-year-old boy presenting with visual distortions consistent with Alice in Wonderland syndrome, and an electroencephalogram demonstrating bilateral temporo-occipital slowing which correlated with symptoms of micropsia, teleopsia, and dysmorphopsia. Identification of this clinical syndrome and its electroclinical features are important for establishing a proper diagnosis and subsequent reassurance or appropriate treatment directed toward the underlying etiology.

Keywords

Alice in Wonderland syndrome, EEG, pediatric migraine, epilepsy

Received April 10, 2020. Received revised April 29, 2020. Accepted for publication May 10, 2020.

Alice in Wonderland syndrome (AIWS), first described by the British psychiatrist John Todd in 1955, is a disorienting perceptual disorder characterized by discrete episodes of bizarre visual illusions and spatial distortions, which has been associated with numerous neurologic and psychiatric conditions.^{1,2} The syndrome, named after Lewis Carroll's well-known protagonist in the children's book *Alice's Adventures in Wonderland*,³ involves distorted perceptions of an individual's body size and form or of the objects in the surrounding environment. Such distortions may include micropsia (objects appear smaller), macropsia (objects appear larger), and metamorphopsia (objects appear distorted), among many others.¹ The duration of symptoms tends to be brief, usually minutes to several days, and resolves without sequelae.^{4,5} Patients are seldom frightened or confused by these illusions, and children in particular may relate the experience in exquisite detail without amnesia. The symptoms of Alice in Wonderland syndrome have been attributed to functional and structural aberrations of the perceptual system.⁶ While it has historically been assumed that this syndrome is rare, epidemiologic studies in patients with migraine have reported an Alice in Wonderland syndrome prevalence rate of up to 15% among this population.^{7,8} Previously published etiologies implicated in Alice in

Wonderland syndrome include viral infections (particularly Epstein-Barr virus [EBV]), migraine, epilepsy, central nervous system lesions, and hallucinogenic substances.¹ One pediatric study of Alice in Wonderland syndrome found a family history of migraine or Alice in Wonderland syndrome in nearly 50% of patients, suggesting a possible genetic predisposition to this fascinating syndrome.⁹ No *ICD-10* or *DSM-5* criteria have been established for Alice in Wonderland syndrome; thus, diagnosis is made on clinical grounds, as well as by excluding other diagnoses such as epilepsy, central nervous system lesions, and primary psychiatric disorders.¹ Ancillary tests, including blood tests, brain magnetic resonance imaging, and electroencephalography (EEG), may be indicated when there is diagnostic uncertainty.

¹ Brigham and Women's Hospital, Boston, MA, USA

² Division of Child and Adolescent Neurology, Department of Neurology, Mayo Clinic, Rochester, MN, USA

Corresponding Author:

Paul E. Youssef, DO, Division of Child and Adolescent Neurology, Department of Neurology, Mayo Clinic, 200 1st Street SW, Rochester, MN 55905, USA.
Email: youssef.paul@mayo.edu



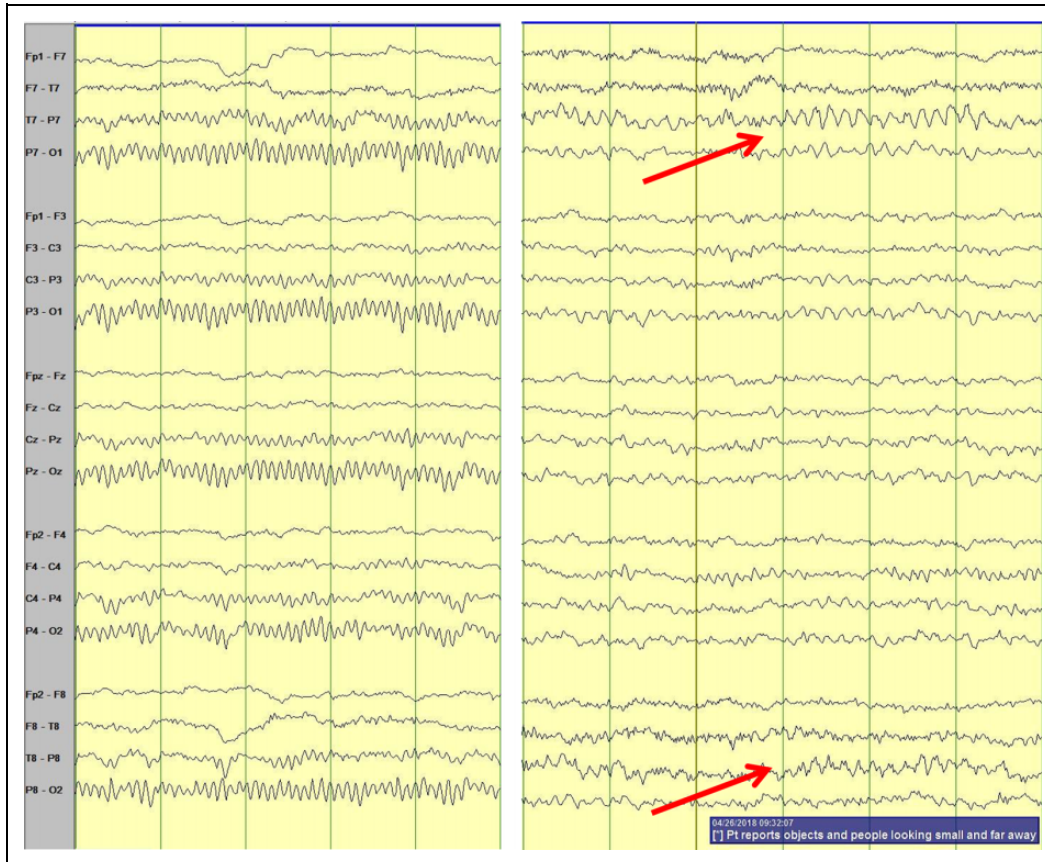


Figure 1. Electroencephalography (EEG) tracings (bipolar montage) in an 8-year old boy with Alice in Wonderland syndrome. The tracing on the left demonstrates symmetric 9 to 10 Hz alpha activity over the posterior head regions. The tracing on the right demonstrates a brief run of 5 to 6 Hz rhythmic theta activity bilaterally in the posterior head regions, maximal over the left posterior temporo-occipital region. This EEG change correlated with the patient's visual symptoms of micropsia, teleopsia, and dysmorphopsia.

The authors present a case of an 8-year-old, neurodevelopmentally normal boy with a history of night terrors, who presented with transient headache and visual disturbance suspicious for Alice in Wonderland syndrome. Subsequent evaluation led to an EEG which demonstrated abnormal EEG correlate with an episode of perceptual disturbance.

Case Description

An 8-year-old, right-hand preference, neurodevelopmentally normal boy presented to the emergency department with symptoms of recurrent perceptual disturbance. His past medical history was unremarkable with the exception of infrequent night terrors. The patient had been seen initially at an outside emergency department for fever and headache. Examination was notable for posterior oropharyngeal erythema. Rapid streptococcal A throat screening test was positive, leading to a diagnosis of streptococcal pharyngitis and treatment with intramuscular penicillin. The patient was not tested for Epstein-Barr virus.

His fever and headache resolved within 12 hours. Less than 24 hours later, the patient presented to our emergency department complaining of 3 episodes of seeing objects being much

smaller (micropsia) and further away (teleopsia) than usual, in addition to seeing wavy or wiggly lines (dysmorphopsia). These symptoms lasted for 5 to 15 minutes and would resolve spontaneously. During the episodes, the child did not have any impairment in consciousness, headache, focal weakness, or abnormal limb movements. The patient did not have a personal history of colic, migraine, cyclic vomiting, or motion sickness. Family history was negative for epilepsy, migraine, neurodevelopmental, or other inherited neurologic conditions. Visual acuity was 20/20 OU, with normal fundoscopic examination. A complete neurologic examination was also normal. The patient's symptoms were suspected to be related to Alice in Wonderland syndrome, and he was discharged from the emergency department with arrangements for an outpatient EEG and neurologic consultation.

To exclude an underlying epileptic condition, the patient underwent a routine awake and sleep EEG 2 days later. The EEG background during wakefulness contained symmetric 9 to 10 Hz alpha activity over the posterior head regions. During the EEG recording, the patient had a recurrence of his typical visual symptoms, characterized by blurred vision with micropsia, teleopsia, and dysmorphopsia. Electrographically, the clinical symptoms were associated with brief (<10 second)

periods of 5 to 6 Hz theta activity over the bilateral posterior head regions and maximal left posterior temporo-occipital region (Figure 1). No potentially epileptogenic activity was present during the clinical symptoms or during the remainder of the awake and sleep recording. Based on the clinical symptoms, normal neurologic and ophthalmologic examinations, and EEG findings, it was felt that the patient's perceptual disturbance was consistent with Alice in Wonderland syndrome. Neuroimaging was not obtained due to the intermittent nature of the nonspecific EEG slowing and the patient's normal neurologic examination with clinical findings suggestive of Alice in Wonderland syndrome. Given the absence of an underlying chronic condition (such as epilepsy or migraine), the family was given reassurance that the symptoms themselves are generally benign and transient. Anticipatory guidance on the association with migraine was reviewed and migraine prophylaxis was discussed if symptoms recurred. Two years since initial presentation, the patient has not experienced further perceptual disturbances nor developed migraine headaches.

Discussion

The above case illustrates unique electroclinical features in a child with distorted visual perceptions consistent with Alice in Wonderland syndrome. Since 1955, no more than 169 case descriptions of Alice in Wonderland syndrome have been published, and very limited EEG data have been reported in these patients.¹ Liaw and Shen¹⁰ in China reported 4 children with metamorphopsia as a presenting symptom of EBV infection where EEG data were obtained. Two patients had normal EEGs, while the 2 others were reported as showing 1 to 4 Hz slow waves either diffusely or over the bilateral parieto-occipital head regions.¹⁰ Kuo and colleagues¹¹ described 4 children with Alice in Wonderland syndrome, with only 1 of the 4 children having an abnormal EEG demonstrating focal slow waves over the occipital and temporal head regions.¹¹ It is unclear whether patients were experiencing visual distortions during the EEG recording in these 2 studies.^{10,11} Technetium-99m hexamethylpropyleneamine tomography (single-photon emission computed tomography) brain scans showed decreased cerebral perfusion in the temporal and occipital lobe in all 4 patients within Kuo's cohort.¹¹ Lahat and colleagues¹² reported significantly higher P₁₀₀-N₁₄₅ amplitude on visual evoked potential in 5 children with Alice in Wonderland syndrome. More recently, functional magnetic resonance imaging showed occipital hypoactivation and parietal hyperactivation in a child with Alice in Wonderland syndrome relative to a matched control participant.¹³ These few studies represent the limited neurophysiologic data within the literature on patients with Alice in Wonderland syndrome.

The EEG abnormalities in individuals with migraine have been well described, and there have been a small number of controlled and blinded studies comparing EEG findings in children with migraine and normal controls.¹⁴⁻¹⁶ In the headache-free period, the EEG is usually normal.¹⁶ Intermittent focal (usually temporal) or generalized slow frequency activity or

an asymmetry of the background activity has also been reported in 0% to 15% of patients, particularly during a migraine with visual aura.¹⁷ While the migrainous symptoms usually improve within hours to days, the EEG abnormalities may persist for as long as 1 to 2 weeks.¹⁸ While the EEG changes in our case of Alice in Wonderland syndrome were similar to those reported in pediatric migraine with aura, our patient was headache-free during the recording and had no personal or family history of migraine, including at last follow-up of 2 years from initial presentation.

This case uniquely demonstrates electroclinical correlate with micropsia, teleopsia, and dysmorphopsia in a child with Alice in Wonderland syndrome and contributes to the limited neurophysiologic data presently available in these patients. To our knowledge, this is the first case in the literature to report nonspecific but definite electrographic correlate with the perceptual symptoms in Alice in Wonderland syndrome. Recognition of the Alice in Wonderland syndrome clinical syndrome and the electrophysiologic manifestations is important for establishing a proper diagnosis and for providing either adequate reassurance or appropriate treatment for the underlying etiology.

Author Contributions

Arya Shah and Setty M. Magaña contributed equally to the manuscript. All authors contributed to conception and design, drafted the manuscript, gave final approval, and agree to be accountable for all aspects of work ensuring integrity and accuracy.


Declaration of Conflicting Interests

The authors declared no potential conflicts of interest with respect to the research, authorship, and/or publication of this article.

Funding

The authors received no financial support for the research, authorship, and/or publication of this article.

ORCID iD

Paul E. Youssef, DO  <https://orcid.org/0000-0001-5765-8573>

Ethical Approval

Not applicable.

References

1. Blom JD. Alice in Wonderland syndrome: a systematic review. *Neurol Clin Pract.* 2016;6(3):259-270.
2. Todd J. The syndrome of Alice in wonderland. *Can Med Assoc J.* 1955;73(9):701-704.
3. Carroll L, Gruyter DE. *Alice's Adventures in Wonderland 150th Anniversary.* Princeton University Press; 2015.
4. Ho CS, Shen EY, Liaw SB, Huang FY. Clinical observation and neurological outcomes in "Alice in Wonderland" syndrome. *Zhonghua Min Guo Xiao Er Ke Yi Xue Hui Za Zhi.* 1992;33(2): 89-95.

5. Lanska JR, Lanska DJ. Alice in Wonderland syndrome: somesthetic vs visual perceptual disturbance. *Neurology*. 2013;80(13):1262-1264.
6. ffytche DH, Howard RJ. The perceptual consequences of visual loss: 'positive' pathologies of vision. *Brain*. 1999;122 (Pt 7):1247-1260.
7. Restak RM. Alice in migraineland. *Headache*. 2006;46(2):306-311.
8. Smith RA, Wright B, Bennett S. Hallucinations and illusions in migraine in children and the Alice in Wonderland syndrome. *Arch Dis Child*. 2015;100(3):296-298.
9. Liu AM, Liu JG, Liu GW, Liu GT. "Alice in Wonderland" syndrome: presenting and follow-up characteristics. *Pediatr Neurol*. 2014;51(3):317-320.
10. Liaw SB, Shen EY. Alice in Wonderland syndrome as a presenting symptom of EBV infection. *Pediatr Neurol*. 1991;7(6):464-466.
11. Kuo YT, Chiu NC, Shen EY, Ho CS, Wu MC. Cerebral perfusion in children with Alice in Wonderland syndrome. *Pediatr Neurol*. 1998;19(2):105-108.
12. Lahat E, Berkovitch M, Barr J, Paret G, Barzilai A. Abnormal visual evoked potentials in children with "Alice in Wonderland" syndrome due to infectious mononucleosis. *J Child Neurol*. 1999;14(11):732-735.
13. Brumm K, Walenski M, Haist F, Robbins SL, Granet DB, Love T. Functional magnetic resonance imaging of a child with Alice in Wonderland syndrome during an episode of micropsia. *J AAPOS*. 2010;14(4):317-322.
14. Bille BS. Migraine in school children. a study of the incidence and short-term prognosis, and a clinical, psychological and electroencephalographic comparison between children with migraine and matched controls. *Acta Paediatr Suppl*. 1962;136:1-151.
15. Whitehouse D, Pappas JA, Escala PH, Livingston S. Electroencephalographic changes in children with migraine. *N Engl J Med*. 1967;276(1):23-27.
16. Sowell MK, Youssef PE. The comorbidity of migraine and epilepsy in children and adolescents. *Semin Pediatr Neurol*. 2016;23(1):83-91.
17. Westmoreland B. EEG in the evaluation of headaches. In: Klass D, Daly D, eds. *Current Practice of Clinical Electroencephalography*. Raven Press; 1979:381-394.
18. Gomez MR, Klass DW. Seizures and other paroxysmal disorders in infants and children. *Curr Probl Pediatr*. 1972;2(6):3-37.