




# Multiple Free Flaps and Second Toe Transfer to Salvage Grasp Function in Bilateral Complete Degloved Hands

R. Srikanth<sup>2</sup> D. Mukunda Reddy<sup>1</sup> K. Muralimohana Reddy<sup>3</sup> N. Rambabu<sup>4</sup> V. Ganga Kishore<sup>5</sup> Sandeep Naidu<sup>2</sup>

<sup>1</sup>Department of Plastic and Reconstructive Surgery, Basavatarakam Smile Train Centre Hyderabad, Telangana, India

<sup>2</sup>Department of Plastic and Reconstructive Surgery, Nizam's Institute of Medical Sciences, Hyderabad, Telangana, India

<sup>3</sup>Department of Plastic Surgery, Yashoda Hospitals Secunderabad, Secunderabad, Telangana, India

<sup>4</sup>Department of Plastic Surgery, Basavatarakam Cancer Hospital, Hyderabad, Telangana, India

<sup>5</sup>Department of Plastic Surgery, Medicare Hospitals, Rajamahendravaram, Andhra Pradesh, India

Address for correspondence Sandeep Naidu, MS, Department of Plastic and Reconstructive Surgery, Nizam's Institute of Medical Sciences, Punjagutta, Hyderabad 500082, Telangana, India (e-mail: sandeepnaidu.63@gmail.com).

Indian J Plast Surg 2024;57(Suppl S1):S100–S105.

## Abstract

A 21-year-old male laborer sustained bilateral degloving injury of the hands with multiple digital amputations and devascularized digits. After X-rays, preliminary debridement was done, when digital amputations were completed, including index ray amputation on both sides. The next day, two anterolateral thigh (ALT) flaps and one second toe transfer were done to restore coverage in the palm and the web and reconstruct the lost thumb. This ensured both coverage and thumb length on the right side, but on the left side the procedure was terminated with flap transfer only. After 3 months, the other second toe was harvested with a dorsalis pedis flap for reconstruction of the left thumb, and a free gracilis flap was done for optimal donor site coverage in the donor left foot. Evaluation after 2 years showed functional hands with reasonable power grasp, pinch grip, and dexterity to manipulate small and large objects that permitted an independent living.

## Keywords

- ▶ hand degloving
- ▶ bilateral
- ▶ ALT flap
- ▶ second toe transfer
- ▶ primary reconstruction

## Introduction

Degloving injuries of the whole hand with amputation of one or more digits are problems that need good planning to not only provide good skin coverage but also restore mobile digits to enable prehension. The condition is even more critical when both hands are injured.

Only flap covers impel a second surgical procedure to make the phalangeal or metacarpal hand functional.

Traditional methods like first web deepening and distraction lengthening of short digital stumps can improve hand function, but a toe transfer is an elegant method to achieve the same objective.

Li et al<sup>1</sup> report combined deep inferior epigastric perforator (DIEP) and second toe transfer in five cases, done either electively or as a delayed emergency; the DIEP flap was joined to the radial vessels end to side proximal to the site of anastomosis of the transferred second toe.

article published online  
August 5, 2024

DOI <https://doi.org/10.1055/s-0044-1788895>.  
ISSN 0970-0358.

© 2024. Association of Plastic Surgeons of India. All rights reserved. This is an open access article published by Thieme under the terms of the Creative Commons Attribution-NonDerivative-NonCommercial-License, permitting copying and reproduction so long as the original work is given appropriate credit. Contents may not be used for commercial purposes, or adapted, remixed, transformed or built upon. (<https://creativecommons.org/licenses/by-nc-nd/4.0/>)  
Thieme Medical and Scientific Publishers Pvt. Ltd., A-12, 2nd Floor, Sector 2, Noida-201301 UP, India

This is a case report of a bilateral circumferential degloving injury of the hands wherein simultaneous free flap cover and second toe transfer were planned for both sides. One of the toe transfers had to be scheduled for second-stage surgery in the interest of patient safety.

## Surgical Technique

### Stage 1

Debridement of both hands was done within 6 hours after the trauma. The degloved skin was distally based at the proximal phalanx level with amputation of the middle and distal phalanges for the fingers. Since the skin was devascularized and crushed, it was removed. The patient underwent transphalangeal amputation of fourth and fifth digits. The middle finger was amputated proximal to the metacarpophalangeal joint (MPJ) on both sides. The thumb amputations left a stump at the base of the proximal phalanx. A ray amputation of both index fingers was done to widen the first webspace. Loss of skin extended up to the wrist crease.

The next day (12 hours after the debridement), a semi-elective reconstruction was planned to transfer two antero-lateral thigh (ALT) flaps and two second toe transfers to cover the degloved hand and to lengthen the amputated thumbs on both sides.

Attention was first directed to reconstructing the right hand. The ALT flap was harvested from the left thigh and simultaneously the second toe from the left foot. Revascularization of the ALT was completed first before the second toe was detached. Anastomosis details are presented in ►Table 1.

Once the left second toe donor site was closed primarily, the second ALT flap was harvested from the right thigh. Since the operative duration now had crossed 6 hours, the harvest of the right second toe for the left hand was deferred and the procedure ended with transfer of the ALT flap only to the left hand (~9 hours of operative time; ►Figs. 1 and 2).

All the microvascular anastomoses were successful in the immediate post-op period. Both the ALT flap donor sites needed split skin grafts.

### Stage 2

Eight weeks later, a second toe transfer from the right foot was done for the thumb reconstruction in the left hand. Since a difficulty was anticipated in the availability of existing ALT flap at the recipient site, the toe was harvested in continuity with a dorsalis pedis flap. Anastomosis was done by harvesting the pedicle of the toe up to the anterior tibial vessels just above the ankle to anastomose to the same radial artery and accompanying veins proximal to the previous anastomotic site in the upper limb (►Figs. 3 and 4).

A gracilis flap was harvested from the left thigh and anastomosed to the stump of the anterior tibial vessels above the left ankle to ensure good wound healing in the foot. Both the transferred flaps survived uneventfully.

K-wires used to fix the second toes that were removed between the fourth and sixth weeks postoperatively and therapy was instituted. One sitting of flap thinning was done on the right side.

## Results

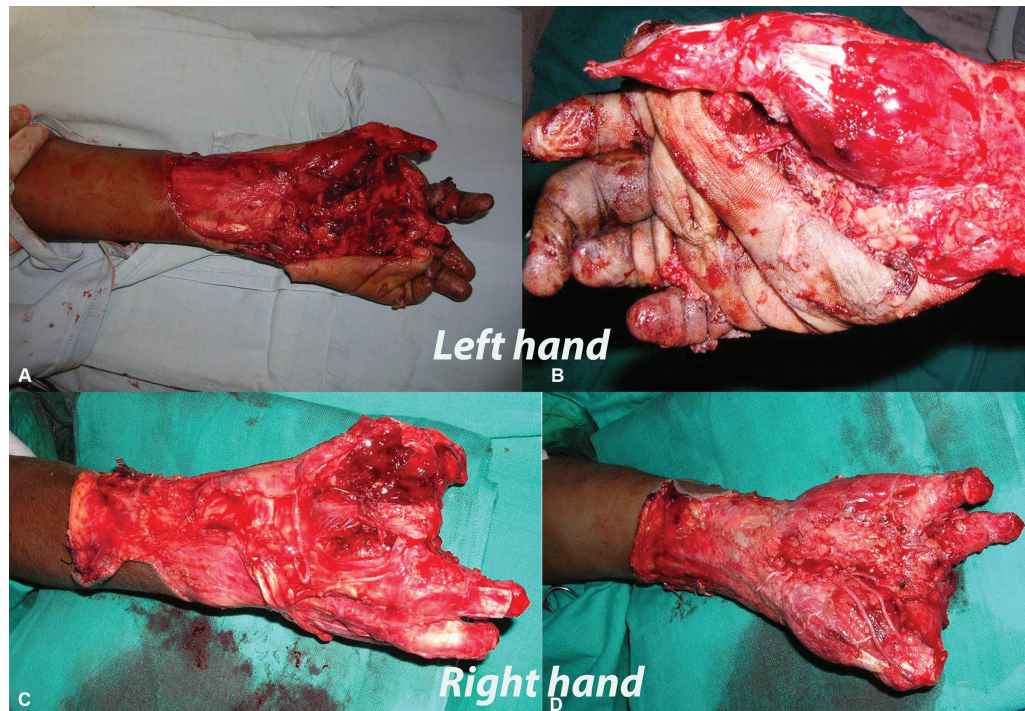The aim was to provide a mobile thumb of reasonable length to oppose the phalangeal ulnar aspect of either hand. The patient was able to grasp using both hands simultaneously. He could use the tip of the reconstructed thumb for fine activities and had a strong adduction of the thumb against the third metacarpal. The available active range of motion (ROM) of the reconstructed thumb was on average 30 degrees at the basal joint, 20 degrees at the MPJ and 20 degrees at the interphalangeal joint (IPJ). He had a moving 2-point discrimination (2PD) of between 7 and 9 mm. There were no trophic ulcerations in spite of activities of daily living. Using an activity board to document the possible

**Table 1** Summary of the flaps transferred in the two stages

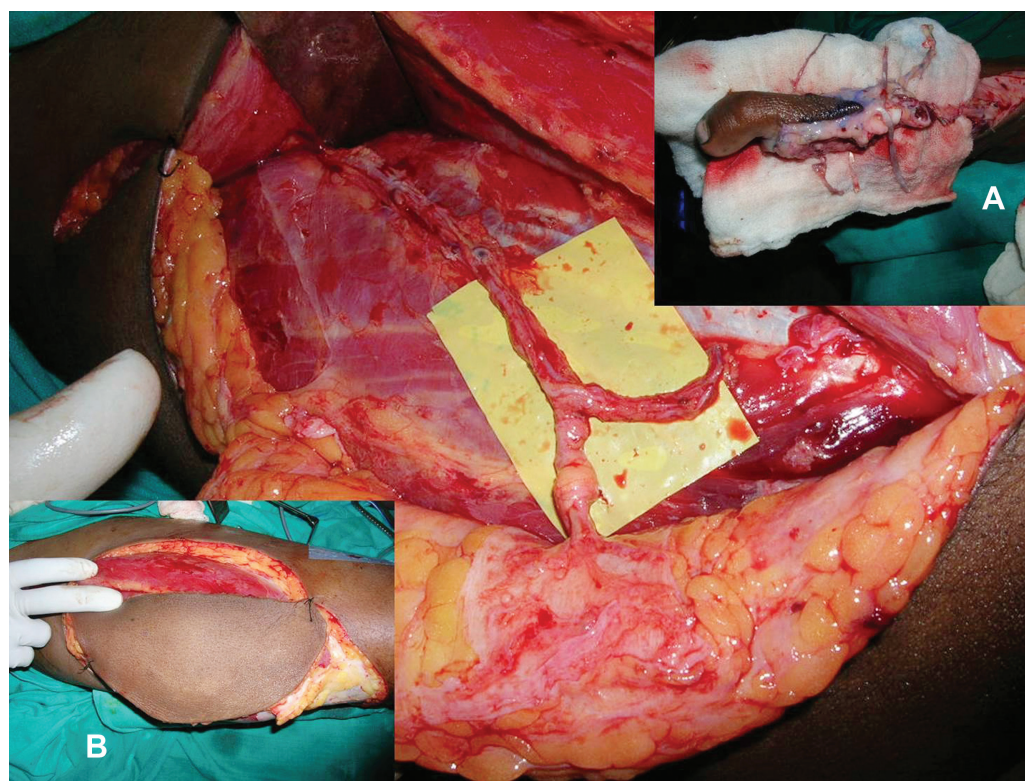
	Right hand		Left hand		Anastomosis artery	Anastomosis vein
	Flap	Toe	Flap			
Stage 1	Left ALT	Left second toe	Right ALT flap <sup>a</sup>		Flap artery: radial artery end to end Toe artery: descending branch of the ALT flap end to end	Flap vein: tributary of the cephalic vein Toe vein: deep vein to the radial venae comitantes Saphenous vein to the cephalic vein
			Flap	Toe		
Stage 2			Gracilis muscle	Right second toe + dorsalis pedis flap	Toe + dorsalis pedis: radial artery end to side proximal to a previous ALT flap anastomosis Gracilis: anterior tibial artery proximal to the site of detachment of the donor toe dorsalis pedis flap	Toe + flap vein: deep vein to the radial venae comitantes Saphenous vein to the rerouted basilic vein Gracilis: 2 venae comitantes of the anterior tibial artery

Abbreviation: ALT, anterolateral thigh.

<sup>a</sup>The second toe transfer was deferred for the left hand on account of increasing operative duration.



**Fig. 1** (A, B) Left hand before debridement. (C, D) Right hand after debridement and amputations.



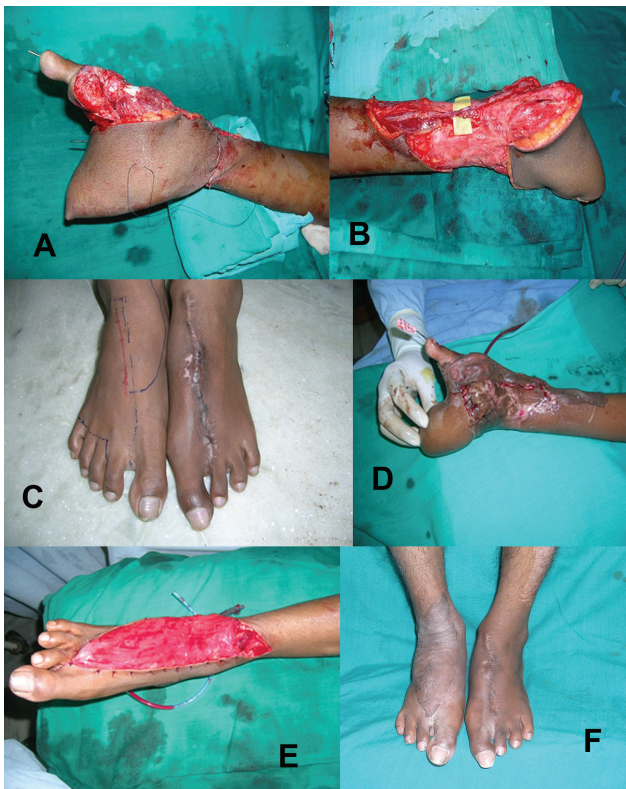**Fig. 2** Donor tissue preparation for the right hand: dissected anterolateral thigh (ALT) flap with perforator entry and long descending branch. (A) Harvested second toe. (B) Harvested ALT flap.

activities of daily living emphasized the functionality of the reconstruction.

In spite of the flap being insensate, there was no evidence of any trophic ulcers in the hand. A thin flap was felt to be more appropriate to give a better appearance (► **Figs. 5 and 6**).

## Discussion

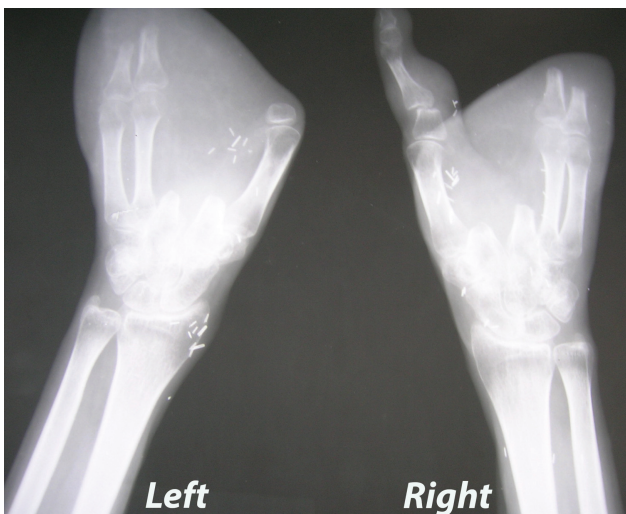
Zelken et al<sup>2</sup> described the successful use of combined ALT and groin pedicle flaps for the total degloved hand. An average of one to four (mean: 1.8) revision procedures



**Fig. 3** (A) Right hand at the completion of second toe transfer and anterolateral thigh (ALT) flap cover. (B) Left hand with only ALT flap transfer. (C) Planning of the second toe with the dorsalis pedis flap from the right foot for the left hand. (D) Completion of second toe transfer to the left hand. (E) Gracilis flap transferred to the donor site of the dorsalis pedis flap in the same stage. (F) Completely healed foot donor sites avoiding the morbidity of great toe harvest.

were needed to improve appearance and function and only one case needed a great toe wraparound subsequently to lengthen the thumb.

Lin<sup>3</sup> further analyzed 15 cases of degloved hands, of which 4 were total degloving covered with pedicle or free groin or



**Fig. 4** X-ray of both hands showing the completed second toe transfer of the right hand and before the second toe transfer for left thumb reconstruction.

ALT flap. Timely division of local flap and syndactyly separation with simultaneous thinning permitted earlier rehabilitation. The amputations were not significant to warrant reconstruction.

Kim et al<sup>4</sup> report a single DIEP flap used for total degloving hand with thumb amputation at the MPJ. Images show all digits with stumps at the level of the proximal phalanx, but no reconstruction was offered.

In the present study, the bilateral nature of the injury and amputations that compromised the number of digits and/or the length made it more imperative to offer primary reconstruction.

Thomas and Tsai<sup>5</sup> describe double toe transfers for reconstructing the middle and ring fingers in combination with a distally based radial forearm flap, using the stump of the radial artery for revascularization of the transferred toes. The thumb was uninjured.

Primary toe transfer makes optimal use of recipient pedicles, enabling earlier rehabilitation to permit good, mobile digits.

Fan et al<sup>6</sup> in 2006 reported the largest series of 11 cases of pure thumb loss with a soft-tissue defect, wherein the scapular or the ALT flap provided coverage and the second or first toe wraparound. The anastomoses used either the radial artery for the toe and the deep plantar branch or the plantar arch for flap perfusion.

We used the descending branch of the ALT flap for toe perfusion in one hand. Since the other toe transfer was done in a second stage, it was done end to side to the radial artery at a higher level.

We planned to provide a mobile radial column (the thumb) of adequate length so that it could oppose the ulnar post consisting of the fourth and fifth digits. These had been amputated distal to the MPJ. Hence, the flexion afforded by the MPJ and the natural mobility of the fourth and fifth carpometacarpal joint was considered enough to provide grasp. The thumb could also be positioned to permit finer activities like manipulating tools including the use of a cellphone.

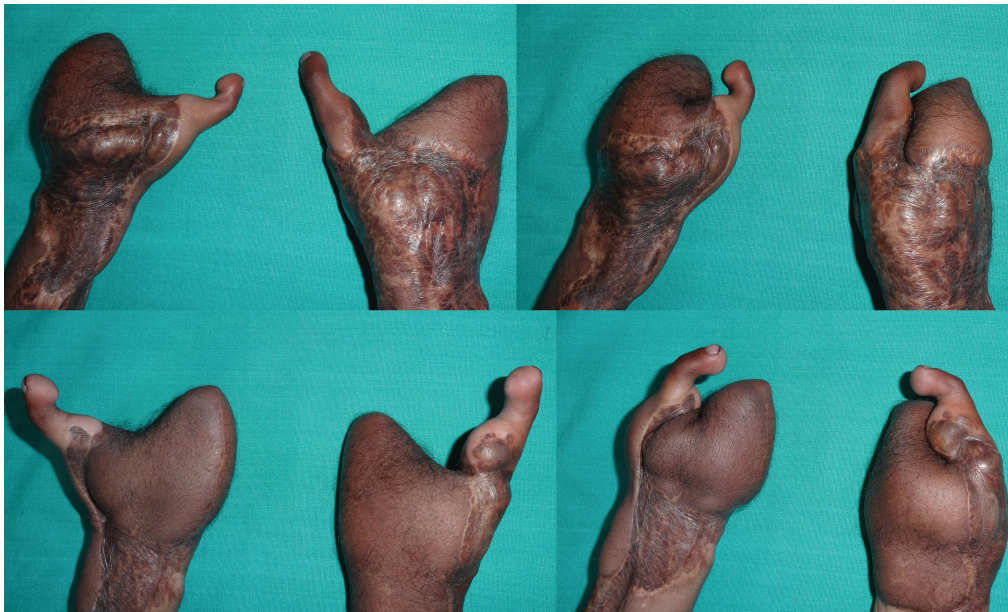One problem that we faced with the reconstruction on the left hand where a simultaneous toe transfer was not done was a relative lack of normal ALT flap skin (on account of contraction) that forced a modification, leading to the elevation of the dorsalis pedis flap in continuity.

To avoid inadequate split skin graft on the foot donor site following flap elevation, a free gracilis flap was transferred simultaneously as a simple option.

In Shen et al,<sup>7</sup> in 3 of 31 cases with degloving and multiple digital losses, they used either two great toes or one great toe and one double toe transfer to the same hand for finger losses, and stressed on the importance of radial digital length for good function.

Combined toe transfers or great toe transfers result in substantial donor defects, which may not be acceptable for Indian patients who rely on open-toed footwear. To minimize donor morbidity, the described method was adopted, and the patient can use Indian-type footwears with ease.

Our intention was to achieve a reasonably functional hand by using a procedure with minimum donor site sequelae. At



**Fig. 5** Sequential images of dorsal and volar views of both hands showing restoration of grasp function.



**Fig. 6** Images showing reasonable achievement of normal daily activities and bimanual tasks at the 2-year follow-up.

the end of follow-up, the patient's Michigan Hand Outcomes Questionnaires (MHQ) score was 63.97 for the right hand, 60.64 for the left hand, and 62.30 for both hands together (► **Videos 1** and **2**).

#### Video 1

This video shows reasonable achievement of normal daily activities and bimanual activities at the 2-year follow-up. Online content including video sequences viewable at: <https://www.thieme-connect.com/products/ejournals/html/10.1055/s-0044-1788895>.

#### Video 2

This video shows reasonable achievement of normal daily activities and bimanual activities at the 2-year follow-up. Online content including video sequences viewable at: <https://www.thieme-connect.com/products/ejournals/html/10.1055/s-0044-1788895>.

## Conclusion

Simultaneous toe transfer and free flap coverage optimize digital mobility and wound closure in degloving hand injuries with digital amputations. When the logistics of operative time do not permit transfer of tissues in a single

stage in a bilateral injury, early planned second-stage reconstruction is crucial to restore activities of daily living.

#### Funding

None.

#### Conflict of Interest

None declared.

## References

- 1 Li XJ, Tong J, Wang Y. Combined free toe and free deep inferior epigastric perforator flap for reconstruction of the thumb and thumb web space. *J Reconstr Microsurg* 2000;16(06):427–436
- 2 Zelken JA, Chang NJ, Wei FC, Lin CH. The combined ALT-groin flap for the mutilated and degloved hand. *Injury* 2015;46(08):1591–1596
- 3 Lin TS. One-stage debulking procedure after flap reconstruction for degloving injury of the hand. *J Plast Reconstr Aesthet Surg* 2016;69(05):646–651
- 4 Kim MJ, Park BY. From mitten hand to five individual fingers: one-stage coverage using a deep inferior epigastric perforator free flap for an extensive degloving hand injury. *Journal of Reconstructive Microsurgery Open* 2018;03:e28–e31
- 5 Thomas BP, Tsai TM. Primary reconstruction of a degloved hand using multiple toe transfers on a single pedicle and a reversed radial artery flap. *J Reconstr Microsurg* 2004;20(01):3–6
- 6 Fan C-Y, Jiang J, Zeng B-F, Jiang P-Z, Cai P-H, Chung KC. Reconstruction of thumb loss complicated by skin defects in the thumb-index web space by combined transplantation of free tissues. *J Hand Surg Am* 2006;31(02):236–241
- 7 Shen XF, Mi JY, Xue MY, et al. Modified great toe wraparound flap with preservation of plantar triangular flap for reconstruction of degloving injuries of the thumb and fingers: long-term follow-up. *Plast Reconstr Surg* 2016;138(01):155–163