



Case report

Organized blood clot masquerading as endobronchial tumor: A review of management and recent advances

Lakshmi Saladi^{a,*}, Dmitry Lvovsky^{a,b}^a Division of Pulmonary and Critical Care Medicine, Department of Medicine, Bronx Care Health System, 1650 Grand Concourse, Bronx, NY 10457, USA^b Icahn School of Medicine at Mount Sinai, USA

ARTICLE INFO

Keywords:

Airway obstruction
Blood clot
Bronchoscopy
Cryoextraction

ABSTRACT

Central airway obstruction, a frequently encountered emergency, is usually associated with blood clots, tumors, foreign bodies or mucus plugs. Airway obstruction due to blood clots can be seen as a complication of lung malignancies, infections, bronchiectasis, arteriovenous malformations or pulmonary infarction. In patients with long standing blood clots, the thrombus gets organized and firmly adherent to the airway. The diagnosis is often misleading as these clots mimic tumors clinically and on imaging. Hemoptysis is the most common presenting symptom though many patients can be asymptomatic. Direct visualization with bronchoscopy is required to establish a diagnosis. Life-threatening respiratory impairment is an indication for emergent clot retrieval. Management of these blood clots, especially when organized, is challenging. Initial attempts at removal should include suctioning, lavage or forceps extraction. When unsuccessful, further management options include balloon catheter dislodgement, use of topical thrombolytics, rigid bronchoscopy and cryoextraction.

1. Introduction

Central airway obstruction is a life-threatening emergency and is associated with various conditions like foreign body aspiration, benign or malignant tumors, mucosal edema, impacted mucus and blood clots. Endobronchial obstruction from an organized blood clot mimicking a tumor is unusual, though not rare [1–5]. In the presence of significant hemoptysis, the diagnosis is obvious. However, hemoptysis is not always a presenting feature in these patients and direct visualization with bronchoscopy is required to exclude other conditions [4–6]. The degree of respiratory impairment varies and, sometimes, patients may be asymptomatic. On the other end of the spectrum are those patients who have significant respiratory compromise requiring mechanical ventilation. Managing such patients is challenging and different bronchoscopic modalities like rigid bronchoscopy, Fogarty catheter dislodgement, forceps, snares and cryoextraction were reported to be successful in the past [1,6,11,12,17–24]. However, these modalities are not always readily available and some require expertise. We present a case of an endobronchial organized blood clot that was successfully removed with flexible fiberoptic bronchoscopy using suction and forceps followed by a detailed discussion on the management of such patients.

2. Case presentation

A 54-year-old woman with chronic pulmonary thromboembolism on warfarin, presented to our emergency department with epistaxis and cough with blood tinged sputum of 4-days duration. She had chronic respiratory failure secondary to COPD requiring home oxygen, deep vein thrombosis, hypertension and history of motor vehicle accident many years ago causing chest wall deformities. She required tracheostomy followed by de-cannulation about 20 years prior to current hospitalization. Her family history was significant for lung cancer in her mother. She was an active smoker with more than 25 pack year smoking history.

Physical examination revealed an obese woman in no apparent distress. Her vital signs were stable and chest auscultation revealed bilateral crackles. Laboratory studies were significant for chronic hypercapnia; her hemoglobin was stable. Chest X-ray is shown in Fig. 1.

Antibiotics were initiated for presumed pneumonia and anticoagulation was held. A CT chest was obtained which showed a 5cm long soft tissue lesion in right bronchus intermedius extending into right middle and lower lobes (Fig. 2A and B).

The patient was admitted to the medical floor for further management. Flexible bronchoscopy was performed that revealed a firm, tan colored lesion obstructing 95% of the proximal right mainstem bronchus (Fig. 3).

* Corresponding author.

E-mail addresses: neeha.viks@gmail.com (L. Saladi), dlvovsky@bronxleb.org (D. Lvovsky).

Abbreviations

Chest X-ray	Chest roentgenogram
COPD	Chronic obstructive pulmonary disease
CT chest	Computed tomography of chest
mL	milliliter
U	units

The lesion was noted to have white laminations and an organized thrombus was suspected. The clot was slowly retrieved using suction and biopsy forceps in a piecemeal fashion. Larger pieces of clot were brought out along with the bronchoscope. The lesion extended into right upper, middle and lower lobe bronchi causing complete occlusion. After removal of the extensive organized clot over a span of few hours, no endobronchial lesions were noted (Fig. 4).

There was mild oozing from right lower lobe anterior basal segment. Pulmonary angiogram was performed followed by embolization of the bronchial artery with clinical improvement. Microscopic pathological examination of the lesion confirmed an organized thrombus. She remained clinically stable without recurrence of hemoptysis.

3. Discussion

Airway obstruction from blood clot is a known complication of trauma to tracheobronchial tree, surgical procedures like tracheostomy, alveolar hemorrhage, pulmonary infections like tuberculosis, bronchiectasis, malignancy, pulmonary infarcts and arteriovenous malformations [1,2]. In 1929, Wilson first reported a case of lung atelectasis secondary to a blood clot following hemoptysis in a patient with

pulmonary tuberculosis. Atelectasis improved with spontaneous expectoration of the blood clot [3].

Hemoptysis is a presenting feature in most cases but the diagnosis can be challenging in up to 30% of the cases where it is absent. This is commonly seen in patients on prolonged mechanical ventilation [4–6]. On physical examination, patients present with clinical evidence of atelectasis with decreased breath sounds on the affected side and sometimes a localized wheeze can be heard. Chest X-ray may be completely normal or may show evidence of lung collapse with mediastinal shift to the affected side. Ipsilateral hyperaeration, sometimes leading to pneumothorax, can be seen if the blood clot acts as a one-way valve [7,8]. Direct visualization with bronchoscopy confirms the diagnosis, a fresh blood clot is dark red in color. However, a long-standing organized blood clot appears white or grey in color mimicking a friable tumor or foreign body.

Management of airway obstruction from blood clots is not standardized and depends on the degree of respiratory impairment, hemodynamic stability, site of obstruction and time since obstruction. In a patient who is hemodynamically stable without major respiratory impairment, observation for spontaneous expectoration of the clot is reasonable [2,3,9]. Attempts to remove such clots may lead to further bleeding or more proximal obstruction which can be catastrophic. Freshly formed clots are usually expectorated within 36–48 hours, but may sometimes progress over days and become organized leading to respiratory failure [10]. Both flexible and rigid bronchoscopy are useful in removal of endobronchial blood clots and initial attempts at removing the clot should involve flexible bronchoscopy with saline lavage and suctioning. If unsuccessful, clot retrieval can be performed in a piecemeal manner using biopsy forceps. Larger pieces of clot can be removed by simultaneously withdrawing the forceps and bronchoscope [6].

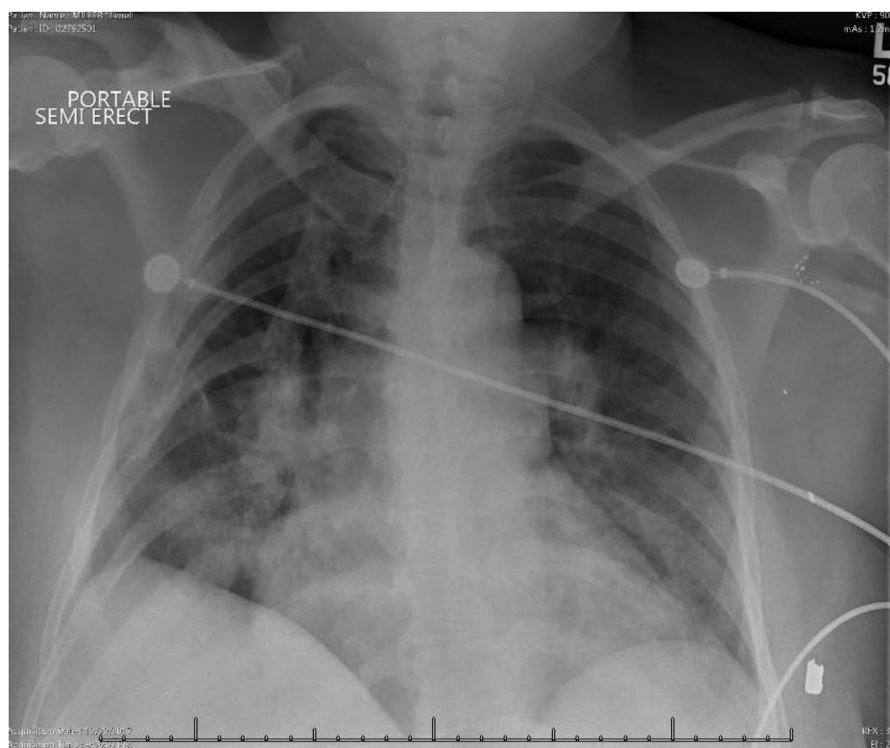


Fig. 1. Chest X-ray with bilateral opacities and chronic right chest wall deformities.

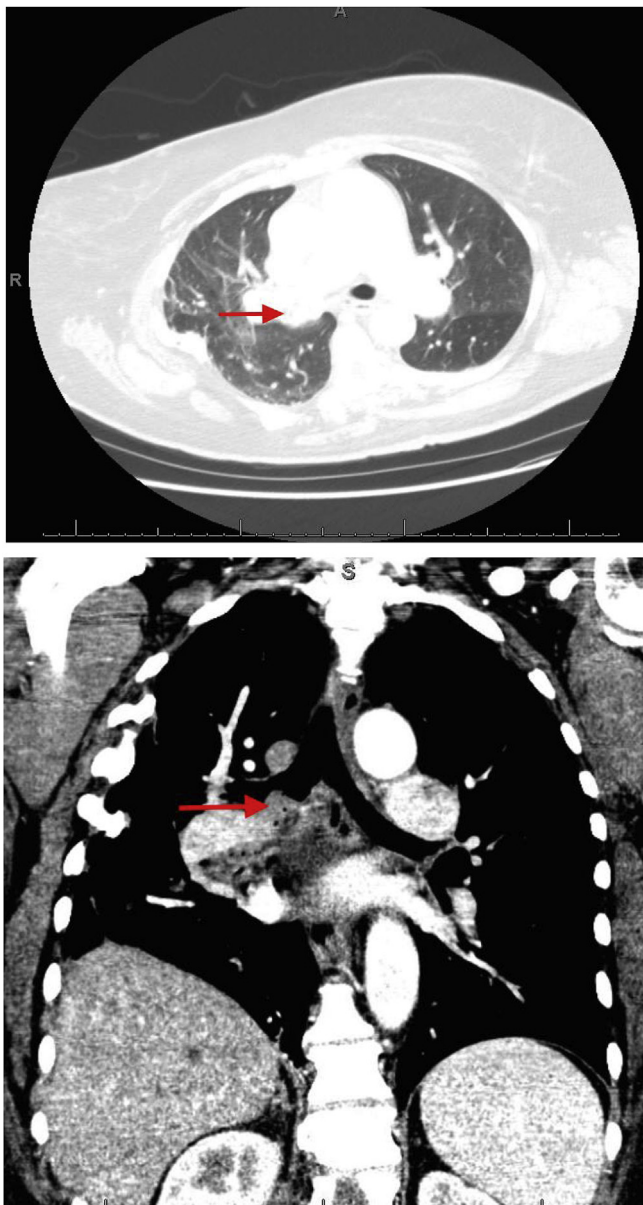


Fig. 2. A: CT chest: Axial view showing right bronchus intermedius obstruction with a soft tissue lesion (red arrow) with right sided atelectatic changes. B: CT chest: Coronal view showing right bronchus intermedius occlusion with soft tissue lesion (red arrow).

Rigid bronchoscopy allows large bore suction catheters and forceps and is superior to flexible bronchoscopy in airway management in case overt bleeding is encountered after clot removal but at the cost of poor ventilation though mechanical ventilation can be performed through a side-port channel [11,12]. Flexible bronchoscopy, on the other hand, can be performed through endotracheal tube allowing for adequate ventilation in a patient with respiratory failure. Fogarty balloon-tip embolectomy catheters have been successfully used to dislodge firm adherent clots followed by suction removal [1]. The balloon catheter

can be used as a bronchial blocker in case of recurrence of bleed after dislodging the clot. However, there is a risk of bronchial disruption and mucosa damage as the catheter is passed blindly and inflated in the distal airway beyond the clot. Direct application of endobronchial thrombolytics under bronchoscopic visualization with successful dissolution of clot was reported in the past [10,13–15]. Streptokinase was used in many case reports and the doses ranged from 30,000 to 120,000 U in 5–20 mL aliquots of saline solutions that were administered for 30–90 minutes. This technique helped with partial clot breakdown followed by suction and removal. Botnick and Brown reported successful use of urokinase at a dose of 15,000 U followed by use of rigid bronchoscopy for clot extraction [16]. Theoretically, there is a risk of re-bleeding with thrombolytics. These techniques are also time consuming and may not always be helpful in a patient with respiratory failure in a critical condition who needs rapid clot removal for better ventilation.

Bronchoscopic cryotherapy, an evolving therapeutic and diagnostic tool, uses nitrous oxide as a cryogen and repeated cycles of rapid freeze-thaw technique causing tissue adherence and tissue necrosis. This technique can be used with rigid and flexible bronchoscopy and is commonly indicated for malignant central airway obstruction and low-grade airway malignancy, cryoextraction of foreign bodies with sufficient water content, endobronchial and transbronchial biopsies [17]. Successful en-bloc removal of large blood clots using cryoextraction was first reported in 2002 by Homasson et al. [18] followed by several case reports [19–22]. In 2014, cryotherapy was successfully applied to remove a large blood clot obstructing the left mainstem bronchus bedside in the intensive care unit [23]. A retrospective review published in 2015 assessed the safety and clinical utility of cryoextraction in patients with airway obstruction. Blood clot extraction was successful in 92% sessions with the failures occurring in the setting of continued and excessive airway bleeding. There was one complication of transient sedation induced hypotension and no evidence of re-bleeding in these patients [24]. The principle of cryoadherence helps in removal of more friable clots due to crystallization of water molecules at the interface whereas organized blood clots can be slowly removed with repeated cycles of cryoablation leading to tissue destruction and cryothrombosis. The main advantages of this technique are rapid removal of clot and safety with less risk of perforation. There is also a beneficial effect of decreased bleeding risk due to vasoconstriction and hemostatic effect of cryotherapy.

4. Conclusion

Organized blood clots mimic endobronchial tumors clinically, radiologically and sometimes under direct visualization with bronchoscopy. Management of these clots that are firmly adherent to the surrounding bronchial mucosa is challenging. The first step in the management involves flexible bronchoscopy and removal using suction and forceps. Several techniques including use of Fogarty balloon catheters and endobronchial thrombolytics were successfully used in the past. Despite the limited literature supporting its use, cryotherapy is increasingly being applied for extraction of friable clots and its use may be extended to organized clots when conventional methods fail. We advocate that cryotherapy as such can minimize procedural and anesthesia time and should be an easily available tool in every bronchoscopy capable institution.

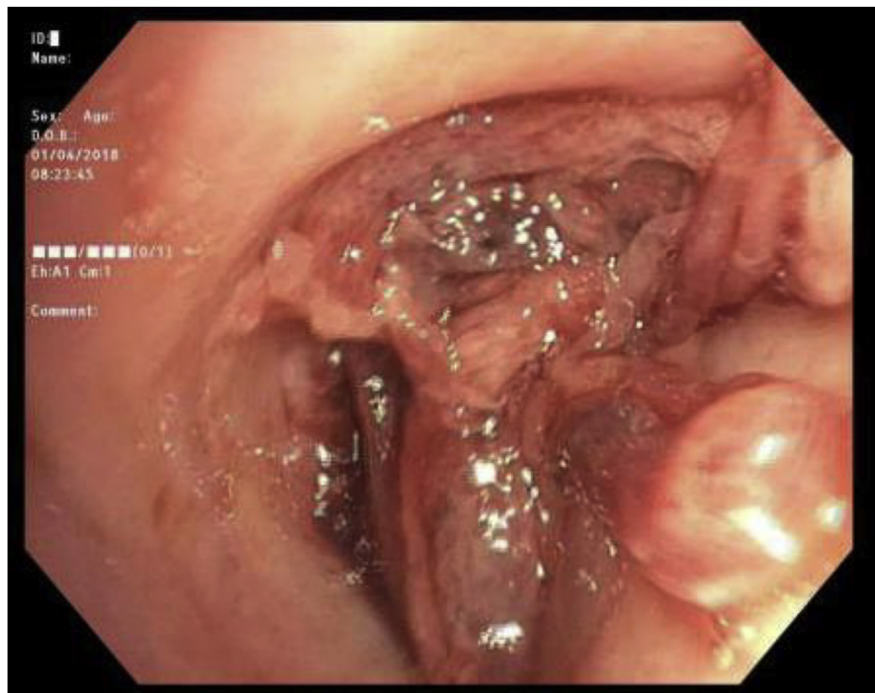
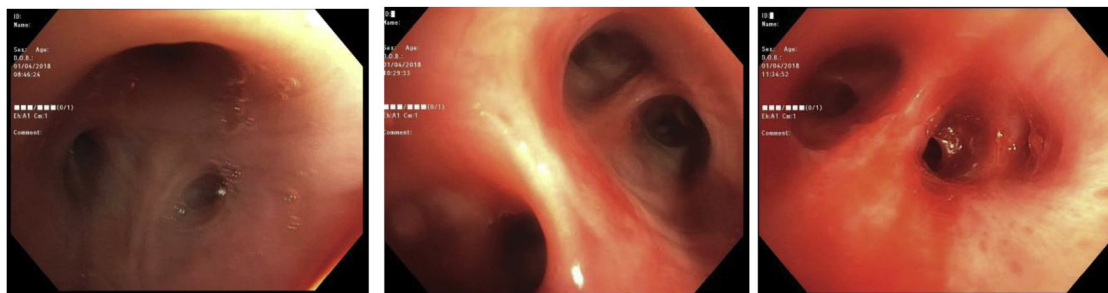


Fig. 3. FOB revealed right proximal mainstem endobronchial soft tissue lesion.



Right upper lobe

Right middle lobe

Right lower lobe

Fig. 4. FOB post clot retrieval showed no endobronchial lesions.

Author disclosure

None of the authors have a financial relationship with a commercial entity that has an interest in the subject of the manuscript. No financial support was used for the study.

Conflict of interest disclosure

The authors declare that there is no conflict of interest regarding the publication of this paper.

References

[1] R.P. Allen, A.D. Siefkin, Emergency airway clot removal in acute hemorrhagic respiratory failure, *Crit. Care Med.* 15 (1987) 985–986.
 [2] J. Mindline, Massive collapse of the lung complicating haemoptysis, *Br. Med. J.* 2 (1935) 1201–40.
 [3] J.L. Wilson, Hemoptysis in tuberculosis followed by massive pulmonary atelectasis, *Am. Rev. Tubercul.* 19 (1929) 310–313.
 [4] K.L. Arney, M.A. Judson, S.A. Sahn, Airway obstruction arising from blood clot: three reports and a review of the literature, *Chest* 115 (1999) 293–300.
 [5] P. Foucher, M. Merati, N. Baudouin, Fatal ball-valve: airway obstruction by an extensive blood clot during mechanical ventilation, *Eur. Respir. J.* 9 (1996) 2181–2182.
 [6] J. Sprung, D.L. Bourke, C. Harrison, et al., Endotracheal tube and tracheobronchial

obstruction as causes of hypoventilation with high inspiratory pressures, *Chest* 105 (1994) 550–552.
 [7] J. Popovich, R. Babcock, Intraluminal blood clot casts causing obstructive emphysema and recurrent pneumothorax, *Crit. Care Med.* 10 (1982) 482–483 .
 [8] J.M. Stanislas, K.M. Porter, G.R. Dickson, et al., Intermittent airway obstruction by a floppy blood clot, *Injury* 27 (1996) 452–453.
 [9] H.J. Isaacs, M.J. Barrash, D.R. Russ, Fatal asphyxia due to massive hemoptysis in a case of mitral stenosis, *J. Am. Med. Assoc.* 151 (1953) 124–127.
 [10] R.P. Cole, G.J. Grossman, Endobronchial streptokinase for bronchial obstruction by blood clots, *N. Engl. J. Med.* 308 (1983) 905–906.
 [11] M.E. Kruczek, B.H. Hoff, B.R. Keszler, et al., Blood clot resulting in ball-valve obstruction in the airway, *Crit. Care Med.* 10 (1982) 122–123.
 [12] B. Duff, B. Gruber, Total tracheobronchial thrombosis due to extracorporeal membrane oxygenation, *Ann. Otol. Rhinol. Laryngol.* 105 (1996) 259–261 .
 [13] Z. Vajo, J.M. Parish, Endobronchial thrombolysis with streptokinase for airway obstruction due to blood clots, *Mayo Clin. Proc.* 71 (1996) 595–596.
 [14] S.L. Maxwell, J.L. Stauffer, Endobronchial streptokinase for relief of tracheobronchial obstruction by blood clots, *Chest* 101 (1992) 1738–1739.
 [15] D.B. Thomson, Endobronchial streptokinase to dissolve a right mainstem clot, *Chest* 89 (1986) 904 .
 [16] W. Botnick, H. Brown, Endobronchial urokinase for dissolution of massive clot following transbronchial biopsy, *Chest* 105 (1994) 953–954.
 [17] S.H. Lee, W.J. Choi, S.W. Sung, Y.K. Kim, C.H. Kim, J.I. Zo, et al., Endoscopic cryotherapy of lung and bronchial tumors: a systematic review, *Kor. J. Intern. Med.* 26 (2011) 137–144.
 [18] J.P. Homasson, J.M. Vergnon, Cryotherapy to extract obstructing blood clots, *J. Bronchol. Interv. Pulmonol.* 9 (2) (2002) 158–159.
 [19] S. De Weerd, M. Noppen, L. Remels, R. Vanherreweghe, M. Meysman, W. Vincken, Successful removal of a massive endobronchial blood clot by means of cryotherapy,

- J. Bronchol. Interv. Pulmonol. 12 (1) (2005) 23–24.
- [20] E.L. Gonzalez, R. Khosla, Cryotherapy in the management of airway clotting in post coronary artery bypass graft complicated with massive hemoptysis, *Am. J. Respir. Crit. Care Med.* 185 (2012) A5967.
- [21] B. Bhardwaj, H. Bhardwaj, H.A. Youness, A. Awab, Bronchoscopic cryoextraction: a novel approach for the removal of massive endobronchial blood clots causing acute airway obstruction, *Southwest J. Pulm. Crit. Care* 7 (2013) 184–189.
- [22] I.S. Sehgal, S. Dhooria, R. Agarwal, D. Behera, Use of a flexible cryoprobe for removal of tracheobronchial blood clots, *Respir. Care* 60 (7) (2015) e128–e131.
- [23] H. Lee, C.S. Leem, J.H. Lee, C.-T. Lee, Y.-J. Cho, Successful removal of endobronchial blood clots using bronchoscopic cryotherapy at bedside in the intensive care unit, *Tuberc. Respir. Dis.* 77 (4) (2014) 193–196.
- [24] N. Sriratanaviriyakul, F. Lam, B.M. Morrissey, et al., Safety and clinical utility of flexible bronchoscopic cryoextraction in patients with non-neoplasm tracheobronchial obstruction: a retrospective chart review, *J. Bronchol. Interv. Pulmonol.* 22 (2015) 288–293.