



# An Upgrade of the International Hip Dysplasia Institute Classification for Developmental Dysplasia of the Hip

Jagar Doski, MD, Laween Mosa, MD, Qaidar Hassawi, MD

*Department of Surgery, College of Medicine, University of Duhok, Duhok, Iraq*

**Background:** The purpose of the current study was to upgrade the International Hip Dysplasia Institute (IHDI) classification of developmental dysplasia of the hip (DDH).

**Methods:** The upgrading was suggested by adding the state of the acetabulum (type A for the normal acetabulum and type B for the dysplastic one). The pelvic radiographic films of 110 children suspected to have DDH were used by three observers to sort out the hips into grades according to the original form and the suggested upgraded one subsequently.

**Results:** The interobserver reliability between the observers improved from a good level (intraclass correlation coefficient [ICC], 0.885; 95% confidence interval [CI], 0.856–0.909) with the original form to an excellent level (ICC, 0.919; 95% CI, 0.898–0.936) with the upgraded form. When the upgraded form was used, only the grade 1 hips were divided into types A and B, while those classified as grades 2, 3, and 4 were all graded as type B only.

**Conclusions:** The IHDI classification of DDH can be upgraded into grade 1A, grade 1B, grade 2, grade 3, and grade 4.

**Keywords:** *Developmental dysplasia of the hip, International Hip Dysplasia Institute classification, Upgrade*

Developmental dysplasia of the hip (DDH) is a common pediatric orthopedic disorder with an incidence of 1.5–2.5 per 1,000 live births.<sup>1)</sup> In early infancy, the physical examination cannot diagnose all cases of DDH; therefore, imaging either by ultrasound or radiography became popular worldwide for screening, confirming clinical suspicion, and classifying the severity of the condition.<sup>2-4)</sup> Ultrasound is the preferred modality for diagnosing DDH in infants less than 6 months old, but the skills to perform a valuable ultrasound may not be available everywhere.<sup>5)</sup> A majority of orthopedic surgeons use pelvic radiographic films to diagnose DDH in children over 3 months of age.<sup>6)</sup>

The International Hip Dysplasia Institute (IHDI)

classification, which uses the midpoint of the proximal femoral metaphysis as a reference landmark to determine the location of the hip, can be applied to children of all ages and is considered more reliable than the Tönnis method, which depends on the relative position of the ossified capital femoral nucleus to Perkin's line and Hilgenreiner's line, even when the capital femoral epiphysis is ossified.<sup>2,7,8)</sup> However, this classification depends mainly on the lateralization and displacement of the proximal femur and neglects the acetabulum. Moreover, grade 1 is a little bit confusing and it may be difficult to decide whether the hip with this grade is normal or abnormal as acetabular dysplasia alone without displacement of the proximal femur is also considered as a type of DDH.

This study aimed to upgrade the IHDI classification by including the state of the acetabulum (normal or dysplastic) to classify the hips. The authors hypothesized that the inclusion of the acetabular state will resolve confusion about the grade 1 hips (whether normal or abnormal).

Received May 11, 2021; Revised October 8, 2021;

Accepted October 8, 2021

Correspondence to: Jagar Doski, MD

Department of Surgery, College of Medicine, University of Duhok, Duhok 42001, Iraq

Tel: +964-075-0459-4137

E-mail: jagaromar@uod.ac

## METHODS

### Approval

This study was approved by the combined Research Ethics Committee of Duhok General Directorate of Health and University of Duhok (No. 11112020-5-8). Informed consent was obtained from patients.

### Type of the Study and Settings

The study is a cross-sectional one. It was done in the Early Detection of Childhood Disability Center in Duhok city, Iraq. Infants and children are referred to this center for detection (i.e., diagnosis) and/or management (i.e., treatment) of pediatric orthopedic disorders.

### Participants

The inclusion criteria were patients who were suspected to have DDH, visited the center for the first time during the period of October 1 till December 30, 2020, and were of either sex. Their age ranged from 3 months to 2 years. The patients were selected consecutively according to their presentation to the center. The exclusion criteria were patients with neuromuscular disorders or arthrogryposis or pelvic radiographic films of poor quality or not taken in the standard position.<sup>9)</sup>

After obtaining permission from parents with a signed form, the data of each patient (name, age, and sex) were reported in a special worksheet. A serial number was assigned to each patient. All identification data related to the patients were hidden from the radiographic films. Only the serial number of each patient was written on his/her film. The films were collected in a box and used by observers later on in the assessment process for this study.

### Templates

For purpose of simplicity, two standardized templates were prepared on transparent papers. These templates were used by the observers on the pelvic radiographic films to

categorize the hips into grades. The first template was prepared to grade the hips according to the original form of the IHDI classification. Three lines for each side (each hip) were drawn on this template according to the description of the creators of this classification: the horizontal Hilgenreiner line (H-line), the vertical Perkin's line (P-line), and the Diagonal line (D-line)<sup>2)</sup> (Fig. 1).

The second template was prepared for the upgraded form. It was a copy of the first one with an added fourth line for each side (each hip) to assess the acetabulum (normal or dysplastic). This line was drawn diagonally from any point of the H-line and inclined upward and outward with an angle of 27.5°. The authors suggested the name acetabular line (A-line) for this added new line. This line was drawn following the acetabular index described classically by Hilgenreiner and clarified by Tönnis, taking into consideration the average lower limit of dysplasia in men and women (Fig. 2).<sup>10-12)</sup>

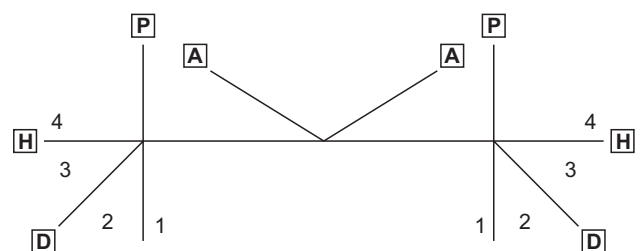
### Observers

The observers were three: two specialized orthopedic surgeons (LM and QH) and one radiologist (AR). They were selected because they had no previous experience in grading the hips with DDH by the IHDI classification. They agreed to participate in the assessment and drafting of the data for this study. They were asked to assess the prepared pelvic radiographic films to categorize the hips with DDH into grades.

In the first session, they were asked to localize three points (but without putting any mark) on the pelvic radiograph film: the lowermost point of the iliac bone at triradiate cartilage (I-point), the most lateral point of the acetabulum (A-point), and the midpoint of the superior margin of the ossified proximal metaphysis of the femoral bone (H-point). Then, they were taught how to use the IHDI classification for grading of DDH and how to use the prepared first template on the pelvic radiographic films for each hip separately. The H-line was to be put on the I-points of both sides and the P-line on the A-point. Then



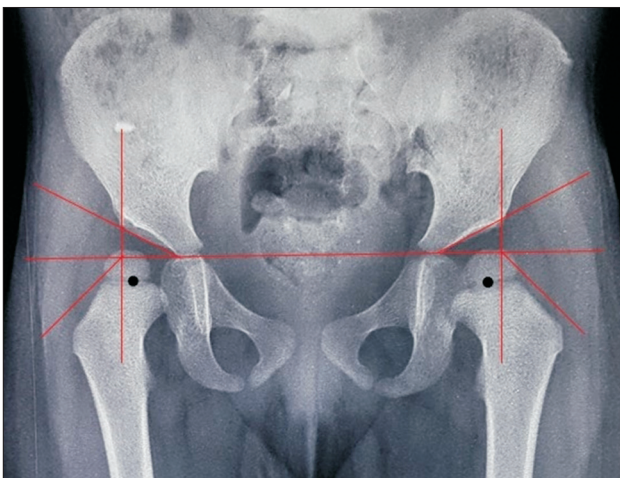
**Fig. 1.** The prepared first template according to the original form of International Hip Dysplasia Institute classification. P: Perkin's line, H: Hilgenreiner's line, D: diagonal line.



**Fig. 2.** The prepared second template for upgrading the International Hip Dysplasia Institute classification. P: Perkin's line, H: Hilgenreiner's line, D: diagonal line, A: acetabular line.

they were asked to determine the position of the H-point in the template sectors of each side to grade the hip into one of the four grades according to the IHDI classification: grade 1 where the H-point is medial to the P-line; grade 2 where the H-point is between P-line and D-line, grade 3 where the H-point is between D-line and H-line, or grade 4 where the H-point is above H-line.<sup>2)</sup>

In the second session, 3 weeks later, they were asked to sort the same collection of pelvic radiograph films by the second template, which included the fourth line (A-line) to determine the quality of the acetabulum by allocating the position and relationship of the A-point to the A-line. The acetabulum was considered normal (type A) when this point was at or below the A-line and considered dysplastic (type B) if it was above the line. Then they were asked to categorize the hips into one of the grades of the suggested upgraded form of the classification: grade 1A when the H-point was medial to the P-line and the acetabulum is normal, grade 1B when the H-point was medial to the P-line and the acetabulum was dysplastic, grade 2A when the H-point was between the P-line and D-line and the acetabulum was normal, grade 2B when the H-point was between P-line and D-line and the acetabulum was dysplastic, grade 3A when the H-point was between the D-line and H-line and the acetabulum was normal, grade 3B when the H-point was between the D-line and the H-line with dysplastic acetabulum, grade 4A when the H-point was above the H-line and the acetabulum was normal, or grade 4B when the H-point was above the H-line with dysplastic acetabulum (Figs. 3-6).



**Fig. 3.** Case example of a pelvic radiograph of an infant with developmental dysplasia of the hip. The right hip was classified according to the upgraded form of the International Hip Dysplasia Institute classification as grade 1B hip where the A-point can be seen above A-line, while the left hip was classified as grade 1A where the A-point is below A-line (black dot, H-point).

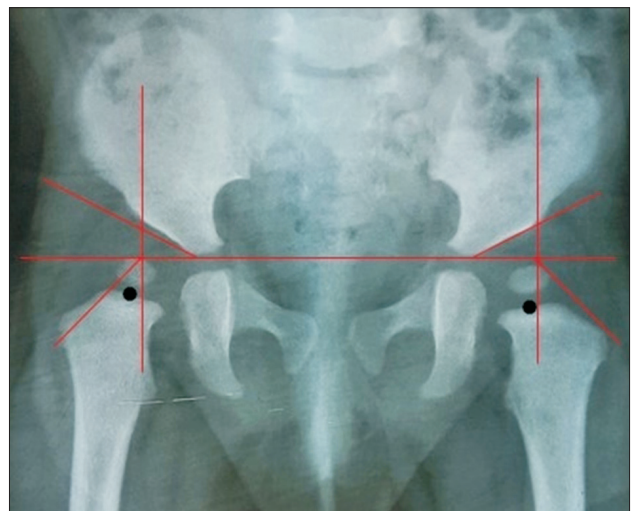
### Data Collection

The observers read the same set of radiograph films twice with an interval of 3 weeks. They did their assessment separately and they were blinded to the data of the patients and to the results of the other observers to prevent bias. They wrote down their assessment on special worksheet papers prepared. For each observer, two worksheet papers were prepared. One paper for grading the hips according to the classic form of the IHDI classification and the second one for the upgraded form. Each paper included the name of the observer, the serial number of the radiographic film, the side of the hip (right or left), and grading of the hip.

### Result Synthesis and Statistical Analysis

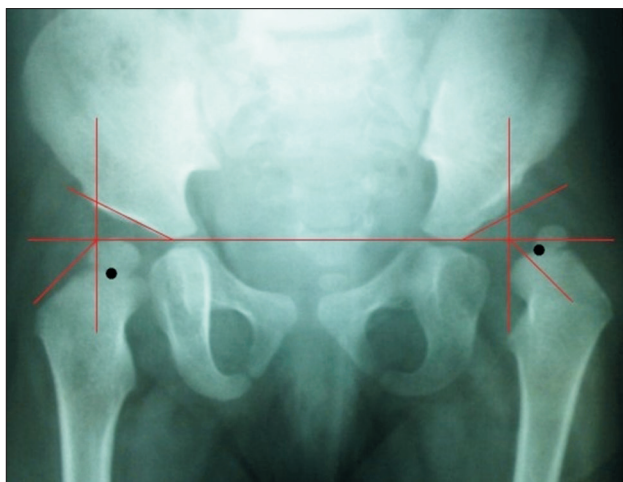
The data in these worksheets were transferred to the computer by using the SPSS IBM ver. 23.0 (IBM Corp., Armonk, NY, USA) for further statistical analysis. The data were imported into the program in form of numeric values. The grading of the hips by the classic form was marked as 1 for grade 1, 2 for grade 2, 3 for grade 3, and 4 for grade 4, while in the upgraded form, 11 for grade 1A, 12 for grade 1B, 21 for grade 2A, 22 for grade 2B, 31 for grade 3A, 32 for grade 3B, 41 for grade 4A, and 42 for grade 4B.

The statistical analysis included the use of intraclass correlation coefficient (ICC) to compute the interobserver reliability of this method because the number of observers (raters) was multiple (more than 2) and the type of variables was of ordinal type. The two-way mixed-effects model was utilized because the study had a fully crossed design (all observers coded the hips in all radiographs that

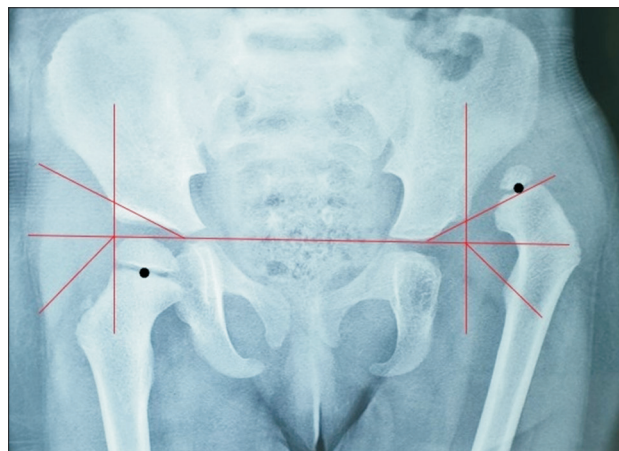


**Fig. 4.** Case example of a pelvic radiograph of another infant with developmental dysplasia of the hip. The right hip was classified as grade 2B according to the upgraded form of the International Hip Dysplasia Institute classification where the A-point is above the A-line (black dot, H-point).





**Fig. 5.** Anteroposterior pelvic radiograph of an infant with unilateral left-sided developmental dysplasia of the hip classified as grade 3B according to the upgraded form of the International Hip Dysplasia Institute classification where the A-point is above the A-line (black dot, H-point).



**Fig. 6.** Pelvic radiograph of an infant with unilateral left-sided developmental dysplasia of the hip classified as grade 4B according to the upgraded form of the International Hip Dysplasia Institute classification where the A-point can be seen above the A-line (black dot, H-point).

had been included in this study) and the observers were not randomly selected. The absolute agreement characteristic type was used because it was important for this study that the scores provided by the observers have similar values.<sup>13)</sup> The average measures of ICC units with a 95% confidence interval (CI) were chosen because they represented the means of the values provided by all observers. This measurement was taken for checking the agreement between the observers for the original and the upgraded forms separately.

For interpretation purposes, the levels of reliability suggested by Koo and Li<sup>14)</sup> were found to be acceptable by the authors: values less than 0.5 are indicative of poor reliability, values between 0.5 and 0.75 indicate moderate reliability, values between 0.75 and 0.9 indicate good reliability, and values greater than 0.9 indicate excellent reliability.

## RESULTS

The patients included in this study were 110, 81 females (73.6%) and 29 males (26.4%). The range of their age was 3–22 months (mean, 6.4 months; standard deviation, 3.8). The number of pelvic radiograph films was 110 and the number of hips assessed was 220,110 for each side (right and left). The interobserver reliability improved from a good level (ICC, 0.885; 95% CI, 0.856–0.909) with the original form to an excellent one (ICC, 0.919; 95% CI, 0.898–0.936) when the upgraded form was used. Most of the hips included in this study (about 91.8%) were of grade 1 or 2 irrespective of the use of the original form or the upgraded one. Sixteen hips (7.3%) were grade 3, and only 2

hips (0.9%) of a single patient were grade 4 (Tables 1 and 2).

On average, when the original form of the classification was used, 110 hips were sorted as grade 1, 92 hips as grade 2, 16 hips as grade 3, and 2 hips as grade 4. When the upgraded form of the classification was used, 58 hips were sorted as grade 1A, 57 hips as grade 1B, 87 hips as grade 2B, 16 hips as grade 3B, and 2 hips as grade 4B. There was some variation in sorting the hips as grade 1 and 2 between the original and the upgrade form, but there was no such variation for the hips sorted as grade 3 and 4. When the upgraded form was used, only the hips of grade 1 were subdivided into the A and B subtypes, while those hips assessed as grade 2, 3, and 4 were all graded as type B only (Table 2).

## DISCUSSION

In general, the interobserver agreement of the present study regarding grading of the hips with the original form of the IHDI classification for DDH was good (ICC, 0.885) and comparable with that of other studies.<sup>2,7,8,15)</sup> This agreement improved to an excellent level (0.919) when the upgraded form was used by the observers. Apparently, the difference seemed to be mild, but it was an improvement from a good level to an excellent one. The interobserver agreement in the present study and other previous studies including the one reported by the creators of the IHDI classification did not reach the value of 1 (which represents the perfect and absolute agreement between the observers). This means that there are weak points in the classification, which are responsible for the imperfect agreement between the observers, causing confusion in

**Table 1.** Number and Percentage of the Hips Sorted by the Observers with the Original Form of the Classification

Grade	Observer 1	Observer 2	Observer 3
1	111 (50.4)	113 (51.4)	106 (48.2)
2	91 (41.4)	88 (40)	97 (44.1)
3	16 (7.3)	17 (7.7)	15 (6.8)
4	2 (0.9)	2 (0.9)	2 (0.9)
Total	220 (100)	220 (100)	220 (100)

Values are presented as number (%).

**Table 2.** Number and Percentage of the Hips Sorted by the Observers with the Upgraded Form

Grade	Observer 1	Observer 2	Observer 3
1A	57 (25.9)	58 (26.4)	58 (26.4)
1B	58 (26.4)	55 (25)	57 (25.9)
2A	0	0	0
2B	86 (39.1)	88 (40)	89 (40.4)
3A	0	0	0
3B	17 (7.7)	17 (7.7)	14 (6.4)
4A	0	0	0
4B	2 (0.9)	2 (0.9)	2 (0.9)
Total	220 (100)	220 (100)	220 (100)

Values are presented as number (%).

deciding to which grade the hip assessed belongs. The reliability between the observers of the present study was better when they used the upgraded form, possibly because it might make the hip view clearer when one looks carefully at both sides of the hip rather than one side as in the original form of the classification.

Most of the hips were graded as grade 1 and 2, and those hips that were sorted as grade 3 and 4 were limited in number with no variance between them whether graded by the original form or the upgraded form. Therefore, the improvement in the agreement between the observers was suspected mainly in those hips sorted as grade 1 and 2. Although the difference between the original form and the upgraded form was mainly in the hips sorted as grade 1 and 2, this does not exclude that such difference might be present in the hips of grade 3 and 4. The authors suspect that the number of these grades, i.e., grade 3 and 4, from the cases included in this study was not enough to clarify this issue, which is a limitation of the study.

When the upgraded form was used, only the hips of grade 1 were subdivided into the A and B subtypes. All hips sorted as grade 2, 3, and 4 in the original form were categorized as type B, i.e., grade 2B, 3B, and 4B, in the upgraded form (Figs. 3-6). No cases of these grades were classified as type A. This might indicate that with the progression of displacement of the femoral head, the acetabulum is almost dysplastic and abnormal. Therefore, it can be concluded that apart from grade 1, the acetabulum will be always dysplastic and abnormal. Thus, it is rational to exclude the subdivision of grades 2, 3, and 4 into type A and B as all hips of these grades are suspected to be of type B only. So, the IHDI classification of DDH can be upgraded into grades 1A, 1B, 2, 3, and 4.

It was not clear in the literature whether the hips sorted as grade 1 by the original form of the classification are normal or not.<sup>2,7,8,15</sup> With use of the upgraded form, they were divided into two subtypes. One subtype had no lateralization of the proximal femur from the joint and

had a normal acetabulum. Ideally, these hips did not need treatment because they were normal. The other subtype was abnormal dysplastic acetabulum. It required treatment and follow-up even if there was no lateralization of the proximal femur at the moment because they were abnormal hips. It could be concluded that there were two types of hips included in grade 1 when assessed by the original form of the classification, and they could not be differentiated from each other. The upgraded form was able to differentiate them into two subtypes.

The limitations of this study are that the number of cases included (especially those of grade 3 and 4) was limited and all cases were from a single center. The authors suggest a new multicenter study with a larger sample, which may aid in deciding the applicability and generalizability (external validity) of the upgraded form of the classification. In conclusion, the IHDI classification can be upgraded into grades 1A, 1B, 2, 3, and 4.

## CONFLICT OF INTEREST

No potential conflict of interest relevant to this article was reported.

## ACKNOWLEDGEMENTS

The authors want to thank the following contributors for their kind help with this study: Dr. Avan Rajab (RA), a specialist of Radiology at Zari-Land Medical Complex, for her help as an observer. Dr. Deldar Morad, community Health Unit, College of Nursing, the University of Duhok, for his help with statistical analysis. The staff of the Early Detection of Childhood Disability Center for their kind help with preparation of the patients and their radiographic films.

## ORCID

Jagar Doski <https://orcid.org/0000-0002-6178-8802>  
Laween Mosa <https://orcid.org/0000-0001-9514-2527>  
Qaidar Hassawi <https://orcid.org/0000-0003-1580-7950>

## REFERENCES

- Gulati V, Eseonu K, Sayani J, et al. Developmental dysplasia of the hip in the newborn: a systematic review. *World J Orthop.* 2013;4(2):32-41.
- Narayanan U, Mulpuri K, Sankar WN, et al. Reliability of a new radiographic classification for developmental dysplasia of the hip. *J Pediatr Orthop.* 2015;35(5):478-84.
- Arti H, Mehdinasab SA, Arti S. Comparing results of clinical versus ultrasonographic examination in developmental dysplasia of hip. *J Res Med Sci.* 2013;18(12):1051-5.
- Dogrueel H, Atalar H, Yavuz OY, Sayli U. Clinical examination versus ultrasonography in detecting developmental dysplasia of the hip. *Int Orthop.* 2008;32(3):415-9.
- Alves C, Truong WH, Thompson MV, et al. Diagnostic and treatment preferences for developmental dysplasia of the hip: a survey of EPOS and POSNA members. *J Child Orthop.* 2018;12(3):236-44.
- Al-Essa RS, Aljahdali FH, Alkhilawi RM, Philip W, Jawadi AH, Khoshhal KI. Diagnosis and treatment of developmental dysplasia of the hip: a current practice of paediatric orthopaedic surgeons. *J Orthop Surg (Hong Kong).* 2017; 25(2):2309499017717197.
- Ramo BA, De La Rocha A, Sucato DJ, Jo CH. A New radiographic classification system for developmental hip dysplasia is reliable and predictive of successful closed reduction and late pelvic osteotomy. *J Pediatr Orthop.* 2018; 38(1):16-21.
- Miao M, Cai H, Hu L, Wang Z. Retrospective observational study comparing the international hip dysplasia institute classification with the Tonnis classification of developmental dysplasia of the hip. *Medicine (Baltimore).* 2017;96(3): e5902.
- Yang Y, Porter D, Zhao L, Zhao X, Yang X, Chen S. How to judge pelvic malposition when assessing acetabular index in children? Three simple parameters can determine acceptability. *J Orthop Surg Res.* 2020;15(1):12.
- Noordin S, Umer M, Hafeez K, Nawaz H. Developmental dysplasia of the hip. *Orthop Rev (Pavia).* 2010;2(2):e19.
- Herring JA. Developmental dysplasia of the hip. In: Herring JA, ed. *Tachdjian's pediatric orthopaedics: from the Texas Scottish Rite Hospital for children.* 5th ed. Philadelphia: Elsevier Saunders; 2014. 483-535.
- Akel I, Songur M, Karahan S, Yilmaz G, Demirkiran HG, Tumer Y. Acetabular index values in healthy Turkish children between 6 months and 8 years of age: a cross-sectional radiological study. *Acta Orthop Traumatol Turc.* 2013;47(1): 38-42.

13. Hallgren KA. Computing inter-rater reliability for observational data: an overview and tutorial. *Tutor Quant Methods Psychol.* 2012;8(1):23-34.
14. Koo TK, Li MY. A guideline of selecting and reporting intraclass correlation coefficients for reliability research. *J Chiropr Med.* 2016;15(2):155-63.
15. Ismiarto YD, Agradi P, Helmi ZN. Comparison of interobserver reliability between junior and senior resident in assessment of developmental dysplasia of the hip severity using Tonnis and international hip dysplasia institute radiological classification. *Malays Orthop J.* 2019;13(3):60-5.