

Fitz-Hugh-Curtis Syndrome Secondary to Postpartum Endometritis: Case Report and Literature Review

Silvia Amodeo^{1*}, Giuseppe Paci¹, Giuseppe Cutaia², Bruno Murmura², Fabio Cannizzaro², Renato Venezia¹

¹Department of Obstetrics and Gynecology, University of Palermo, ²Department of Radiological Sciences, BiND, Paolo Giaccone University Hospital, University of Palermo, Palermo, Italy

Abstract

We report a case of Fitz-Hugh-Curtis syndrome (FHCS) 1 week after an urgent cesarean section. Although its onset in the postpartum period is poorly reported in the literature, we suggest that FHCS can complicate puerperal endometritis; therefore, it should be considered in differential diagnosis in puerpera with right upper quadrant pain. Again, it can be useful to perform a contrast computed tomography that allows early diagnosis and conservative treatment.

Keywords: Endometritis, Fitz-Hugh-Curtis syndrome, hepatitis, pelvic inflammatory disease, peritonitis, puerperal infection

INTRODUCTION

Fitz-Hugh-Curtis syndrome (FHCS) is a rare perihepatitis, in which the microbes responsible for pelvic inflammatory disease (PID) spontaneously ascend from endometrium, Fallopian tubes, and peritoneum and spread to the perihepatic capsule causing its inflammation, without involvement of the hepatic parenchyma.^[1] Due to its rarity and nonspecific clinic, its diagnosis is difficult and mostly surgical. Moreover, the medical literature hardly reported its finding in the postpartum period as the complication of postpartum endometritis.

We describe a case of FHCS secondary to postpartum endometritis caused by *Escherichia coli* in a woman who recently underwent an urgent cesarean section.

CASE REPORT

A 29-year-old puerpera (gravida 1, para 1) presented to our obstetrics and gynecology emergency unit complaining recent appearance of fever, right upper quadrant (RUQ)

pain exacerbated by movement, pelvic pain, and smelly lochiations. She had no remarkable medical history and no previous surgery with the exception of a recent cesarean section. The dichorionic diamniotic pregnancy was obtained by spontaneous conception and proceeded with regular course without complications or symptoms like those referred at the current hospital access. One week previously, she underwent at our unit an urgent cesarean section at 35 weeks and 1 day of gestation for preterm labor with first fetus in breech presentation. Cesarean delivery was performed through Pfannenstiel incision, after preoperative povidone-iodine 10% skin preparation, chlorhexidine vaginal cleansing, and 2 g intravenous dose of cefazolin before skin incision. At the abdomen opening, the pregnant uterus was visualized, the pelvis appeared regular, there was no peritoneal free fluid or adhesions or other signs of pelvic inflammation. Amniotic fluid was clear in both amniotic sacs, and there were no signs of chorioamnionitis. Due to the incision type,

Address for correspondence: Dr. Silvia Amodeo, Department of Obstetrics and Gynecology, University of Palermo, Via Alfonso Giordano 3, 90127, Palermo, PA, Italy. E-mail: silviaamodeo23@gmail.com

Article History:

Submitted: 18 May 2020

Revised: 21 September 2020

Accepted: 29 October 2020

Published: 3 August 2021

Access this article online

Quick Response Code:



Website:
www.e-gmit.com

DOI:
10.4103/GMIT.GMIT_58_20

This is an open access journal, and articles are distributed under the terms of the Creative Commons Attribution-NonCommercial-ShareAlike 4.0 License, which allows others to remix, tweak, and build upon the work non-commercially, as long as appropriate credit is given and the new creations are licensed under the identical terms.

For reprints contact: WKHLRPMedknow_reprints@wolterskluwer.com

How to cite this article: Amodeo S, Paci G, Cutaia G, Murmura B, Cannizzaro F, Venezia R. Fitz-hugh-curtis syndrome secondary to postpartum endometritis: Case Report and literature review. Gynecol Minim Invasive Ther 2021;10:184-6.

the upper abdominal quadrants were not explored. She was discharged after 2 days in good health.

On readmission, 5 days after discharge, body temperature was 38.3°C, blood pressure 105/60 mmHg and pulse rate 93 bpm. Physical examination revealed tenderness in right upper and low quadrants, slight cervical motion tenderness, and green smelly vaginal discharge. Pelvic transvaginal ultrasound showed increased uterine volume as for puerperal period, thickened and heterogeneous endometrium with increased vascularity on Doppler and moderate free fluid in the pouch of Douglas. Laboratory testing showed total leukocyte count of $12 \times 10^3/\text{mm}^3$, with absolutely neutrophils count $11 \times 10^3/\text{mm}^3$ (91%), C-reactive protein level of 15 mg/dl. Liver function test and other hematological and biochemical parameters were within the normal limits. Blood cultures and vaginal and endocervical swabs were performed. Although the context posed for puerperal endometritis, this did not explain the pain in the RUQ. Abdominal ultrasound revealed profuse peritoneal free fluid in perihepatic, perisplenic, and pelvic spaces. Therefore, to investigate the RUQ pain, the day after admission to the hospital, the patient underwent an abdominal contrast-enhanced computed tomography (CECT). The baseline nonenhanced computed tomography (CT) scan confirmed huge abdominal fluid effusion (perihepatic, perisplenic, and pelvic) and showed enlarged uterus compatible with postpartum condition and omental hyperattenuation [Figure 1a]. The arterial phase CECT scan showed abnormal endometrial enhancement, suggestive for endometritis, and contrast enhancement of the Glisson's capsule, mainly on the left hepatic segments and of the gall bladder walls [Figure 1b]. The portal-venous phase confirmed the findings described above [Figure 1c]. The CT findings and the patient's history allowed diagnosing FHCS consequent to postpartum endometritis.

Considering the recent appearance of symptoms, our team opted for conservative treatment and clinical monitoring, by administering clindamycin 600 mg intravenously every

8 h and gentamicin 160 mg intravenously once daily from the 2nd day of hospitalization. On the 4th day (therefore 48 h after starting antibiotic therapy) symptoms were slightly improved, body temperature was 36.6°C, total leukocyte count, and C-reactive protein moderately reduced, therefore, therapy was switched to Ceftriaxone 250 mg IM in a single dose plus Doxycycline 100 mg orally twice a day for 14 days. Clinical monitoring was carried out, complete blood count and polymerase chain reaction were repeated every other day and liver function tests every 2 days resulting within the limits. On the 7th day of hospitalization, blood cultures were negative, endocervical swabs excluded the main organisms responsible for PID such as *Chlamydia trachomatis* and *Neisseria gonorrhoeae* while endocervical cultures identified *E. coli*. The patient was discharged on the 8th day with full resolution of clinical signs, normalization of laboratory values, and thin and regular endometrium on transvaginal ultrasound. At follow-up 3 and 6 months later, the patient reported no further symptoms.

DISCUSSION

FHCS is a rare extra-pelvic complication of PID, first reported by Curtis^[2] in 1930 e Fitz-Hugh^[3] in 1934. It complicates from 4%^[4] to 14%^[5] of PIDs. In order of frequency, *C. trachomatis*, *N. gonorrhoeae*, anaerobic bacteria, various other bacteria as *Mycoplasma genitalium* and some Gram-negative bacteria cause it.^[6] Microorganisms could spread from the pelvis to the hepatic capsule through spontaneous ascent from the right parieto-colic gutter or through lymphatic or hematic system. The extension to the hepatic capsule is responsible for its inflammation and fibrous exudate (perihepatitis), which can lead to adhesions between liver capsule and diaphragm or anterior peritoneal surface,^[7] without involvement of hepatic parenchyma. RUQ pain is the main symptom that patients complain of frequently worsened by movement and breathing. More rarely, the syndrome can be asymptomatic in the acute perihepatitis phase and appears late when the adhesions have

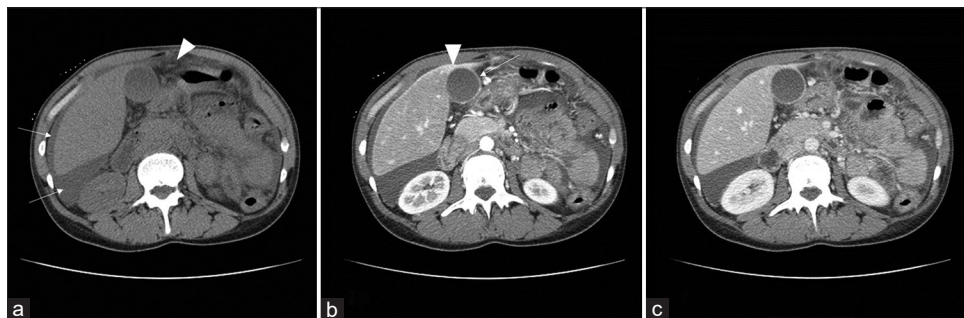


Figure 1: (a) Axial nonenhanced computed tomography scan reveals perihepatic fluid effusion (white arrows) and omental hyperattenuation (arrowhead); (b) Axial arterial phase contrast-enhanced computed tomography scan reveals enhancement of the Glisson's capsule on the left hepatic segments (arrowhead) and of the gall bladder walls (white arrow); (c) Axial portal-venous phase contrast-enhanced computed tomography scan confirmed the findings showed in Figure 1b

already formed. Other associated signs include fever, pelvic pain, vaginal discharge, and vomiting.

In the described case, the association of fever, smelly lochiations, and cervical motion tenderness in the postpartum were suggestive of puerperal endometritis, which occurs after about 1%–3% of vaginal births and up to 27% of cesarean births.^[8] Hassani *et al.*^[9] have described the only case of FHCS in the postpartum period reported in the medical literature. They reported a diagnosis of FHCS 2 weeks after an uncomplicated spontaneous vaginal birth. Although medical literature poorly reports the association between puerperal endometritis and RUQ pain, gynecologists should consider FHCS in the differential diagnoses with other pathological conditions responsible for RUQ pain. Normal liver function tests exclude liver pathologies of pregnancy that could evoke RUQ pain also in the postpartum period, i.e., hypertension-related liver diseases and acute fatty liver. Abdominal ultrasound can show perihepatic fluid effusion and allow excluding acute abdominal pathologies such as cholecystitis, right pyelonephritis, appendicitis, and other form of peritonitis. Although the gold standard diagnosis of FHCS is the laparotomic or laparoscopic finding of “violin string-like” adhesions between hepatic capsule and diaphragm’s dome, CECT can represent a valid support for the noninvasive diagnosis of FHCS. CT scan detects hepatic capsular enhancement on the arterial phase associated with PID’s sign with a sensitivity of 88% and specificity of 95%,^[10] representing an effective tool for noninvasive diagnosis of perihepatitis. It also allows excluding other causes of perihepatitis or RUQ pain.^[1,11,12]

Since it is a benign condition, an early detection allows conservative and noninvasive treatment resolving the underlying infection. Centers for Disease Control and Prevention^[13] suggests empiric broad-spectrum antibiotics, which must cover the most common organisms i.e., *C. trachomatis* and *Neisseria gonorrhoea*, but also Gram-negative organisms, anaerobes, and streptococci.^[1] When adhesions have already formed, it requires surgical adhesion lysis, preferably laparoscopic, to symptom relief. In fact, the main complications are attributable to the development of adhesions. Perihepatic adhesions are responsible for chronic pain in RUQ. Pelvic adhesions and infectious sequelae determine unfavorable reproductive outcomes such as infertility and ectopic pregnancies.

Concluding FHCS secondary to postpartum endometritis is a rare condition. Furthermore, the nonspecificity of RUQ pain can delay the diagnosis, which represents a diagnostic challenge. As in our report, the integration of clinical evaluation, abdominal and gynecological examination, laboratory tests and instrumental investigations, including

transvaginal/abdominal ultrasound and CECT, is crucial for early diagnosis and appropriate treatment.

Once gynecologists detect RUQ pain in a woman with postpartum endometritis, they should suspect FHCS. Performing CT scan enables to diagnose FHCS in the early stages. This allows timely medical treatment, avoiding unnecessary surgical procedures and minimizing the risk of permanent damages.

Declaration of patient consent

The authors certify that they have obtained appropriate patient consent form. In the form, the patient has given her consent for the images and other clinical information to be reported in the journal. The patient understands that name and initial will not be published and due efforts will be made to conceal the identity, but anonymity cannot be guaranteed.

Financial support and sponsorship

Nil.

Conflicts of interest

There are no conflicts of interest.

REFERENCES

1. You JS, Kim MJ, Chung HS, Chung YE, Park I, Chung SP, *et al.* Clinical features of Fitz-Hugh-Curtis Syndrome in the emergency department. *Yonsei Med J* 2012;53:753-8.
2. Curtis AH. A case of adhesion in the right upper quadrant. *J Am Med Assoc* 1930;94:1221-2.
3. Fitz-Hugh T. Acute gonococcal peritonitis of the right upper quadrant in women. *J Am Med Assoc* 1934;102:2094-6.
4. Peter NG, Clark LR, Jaeger JR. Fitz-Hugh-Curtis syndrome: A diagnosis to consider in women with right upper quadrant pain. *Cleve Clin J Med* 2004;71:233-9.
5. Risser WL, Risser JM, Benjamins LJ, Feldmann JM. Incidence of Fitz-Hugh-Curtis syndrome in adolescents who have pelvic inflammatory disease. *J Pediatr Adolesc Gynecol* 2007;20:179-80.
6. Müller-Schoop JW, Wang SP, Munzinger J, Schläpfer HU, Knoblauch M, Tammann RW. Chlamydia trachomatis as possible cause of peritonitis and perihepatitis in young women. *Br Med J* 1978;1:1022-4.
7. Lopez-Zeno JA, Keith LG, Berger GS. The Fitz-Hugh-Curtis syndrome revisited. Changing perspectives after half a century. *J Reprod Med* 1985;30:567-82.
8. Mackeen AD, Packard RE, Ota E, Speer L. Antibiotic regimens for postpartum endometritis. *Cochrane Database Syst Rev*. 2015;2:CD001067.
9. Hassani B, Evans JG, Gibson CB, Gullett JP, Pigott DC. Young woman with postpartum chest and abdominal pain. *Ann Emerg Med* 2018;71:e111-2.
10. Joo SH, Kim MJ, Lim JS, Kim JH, Kim KW. CT diagnosis of Fitz-Hugh and Curtis syndrome: Value of the arterial phase scan. *Korean J Radiol* 2007;8:40-7.
11. Theofanakis CP, Kyriakidis AV. Fitz-Hugh-Curtis syndrome. *Gynecol Surg* 2011;8:129-34.
12. Kim JY, Kim Y, Jeong WK, Song SY, Cho OK. Perihepatitis with pelvic inflammatory disease (PID) on MDCT: Characteristic findings and relevance to PID. *Abdom Imaging* 2009;34:737-42.
13. Centers for Disease Control. Sexually transmitted diseases treatment guidelines. *MMWR Recomm Rep* 2015;64:1-137.