

DIEP Flap Breast Reconstruction in Patients with Breast Ptosis: 2-Stage Reconstruction Using 3-Dimensional Surface Imaging and a Printed Mold

Koichi Tomita, MD, PhD
Kenji Yano, MD, PhD
Mifue Taminato, MD
Michiko Nomori, MD
Ko Hosokawa, MD, PhD

Background: Autologous breast reconstruction can be performed for breasts with ptosis to a certain extent, but if patients desire to correct ptosis, mastopexy of the contralateral breast is indicated. However, accurate prediction of post-mastopexy breast shape is difficult to make, and symmetrical breast reconstruction requires certain experience. We have previously reported the use of three-dimensional (3D) imaging and printing technologies in deep inferior epigastric artery perforator (DIEP) flap breast reconstruction. In the present study, these technologies were applied to the reconstruction of breasts with ptosis.

Methods: Eight breast cancer patients with ptotic breasts underwent two-stage unilateral DIEP flap breast reconstruction. In the initial surgery, tissue expander (TE) placement and contralateral mastopexy are performed simultaneously. Four to six months later, 3D bilateral breast imaging is performed after confirming that the shape of the contralateral breast (post-mastopexy) is somewhat stabilized, and a 3D-printed breast mold is created based on the mirror image of the shape of the contralateral breast acquired using analytical software. Then, DIEP flap surgery is performed, where the breast mold is used to determine the required flap volume and to shape the breast mound.

Results: All flaps were engrafted without any major perioperative complications during both the initial and DIEP flap surgeries. Objective assessment of cosmetic outcome revealed that good breast symmetry was achieved in all cases.

Conclusions: The method described here may allow even inexperienced surgeons to achieve reconstruction of symmetrical, non-ptotic breasts with ease and in a short time. While the requirement of two surgeries is a potential disadvantage, our method will be particularly useful in cases involving TEs, i.e., delayed reconstruction or immediate reconstruction involving significant skin resection. (*Plast Reconstr Surg Glob Open* 2017;5:e1511; doi: 10.1097/GOX.0000000000001511; Published online 5 October 2017.)

INTRODUCTION

Breast reconstruction procedures using autologous tissue, such as deep inferior epigastric artery perforator (DIEP) flaps, can provide high-quality texture and are applicable to patients with some degree of breast ptosis. Although this is certainly advantageous, mastopexy or breast reduction of the contralateral breast may be

indicated if patients desire to correct ptosis. Following these surgeries, however, it takes several months for the breast shape to stabilize, and the final shape is difficult to predict accurately pre- or intraoperatively, especially when the vertical scar technique is used.^{1,2} Moreover, even if mastopexy is performed using the same operative method and design, outcomes vary greatly depending on the quality of the skin and breast parenchyma.

Recent technological innovations such as volumetric planning using computed tomographic angiography enabled us to accurately plan breast reconstruction.^{3,4} In shaping the breast mound, a previous study reported the use of 3-dimensional (3D) imaging and breast replica cast created by wooden block and vacuum-forming device as a method to achieve breast symmetry.⁵ Recently, we used 3D imaging and printing technologies for DIEP

From the Department of Plastic and Reconstructive Surgery, Graduate School of Medicine, Osaka University, Osaka, Japan.

Received for publication June 23, 2017; accepted August 9, 2017.

All procedures conformed to the Declaration of Helsinki, and appropriate informed consent was obtained from the patients.

Copyright © 2017 The Authors. Published by Wolters Kluwer Health, Inc. on behalf of The American Society of Plastic Surgeons. This is an open-access article distributed under the terms of the Creative Commons Attribution-Non Commercial-No Derivatives License 4.0 (CCBY-NC-ND), where it is permissible to download and share the work provided it is properly cited. The work cannot be changed in any way or used commercially without permission from the journal.

DOI: 10.1097/GOX.0000000000001511

Disclosure: *The authors have no financial interest to declare in relation to the content of this article. The Article Processing Charge was paid for by the authors.*

flap breast reconstruction, allowing for easy and quick reconstruction of symmetrical breasts.⁶ In these technologies, breast symmetry is achieved using the image of the contralateral breast. However, in patients who desire to correct breast ptosis, the final image of the contralateral breast is not available at the time of flap surgery. In this article, we report the application of these techniques in unilateral reconstruction of breasts with ptosis, along with favorable outcomes.

PATIENTS AND METHODS

From December 2014 through December 2016, 8 breast cancer patients with ptotic breasts underwent 2-stage unilateral DIEP flap breast reconstruction procedures at Osaka University Medical Hospital. This study was approved by the institutional review board of the hospital, and informed consent was obtained from all patients.

Mean patient age was 52.6 years (range, 39–66 years), and mean follow-up period was 14.6 months (range, 6–27 months). Seven of the 8 patients underwent delayed reconstruction, and 1 underwent immediate reconstruction. Reconstruction procedures were performed after modified radical mastectomy in all cases, except for 1 patient

who underwent immediate reconstruction following skin-sparing mastectomy. No patient underwent postmastectomy radiation therapy (PMRT). Grade of ptosis according to Regnault's classification⁷ was I in 4 patients and II in another 4. Mean time from initial surgery to DIEP flap surgery was 6.4 months (range, 4–10 months).

During the initial surgery, an anatomical tissue expander (TE) with integrated port (Natrele 133, Allergan, Tokyo, Japan) was placed subcutaneously (delayed reconstruction) or subpectorally (immediate reconstruction). Mastopexy of the contralateral breast was performed simultaneously using the vertical scar technique (Fig. 1A). The TE was expanded such that the right and left inframammary folds were equidistant from the clavicular mid-point over the body surface.

Four to 6 months postoperatively, 3D bilateral breast imaging was performed after confirming that the shape of the contralateral breast (postmastopexy) was somewhat stabilized. Before initiating DIEP flap surgery, 3D breast measurements were obtained, the required tissue volume and total flap volume were estimated, and flap type (i.e., unilateral or bilateral deep inferior epigastric vessels) was determined using a David SLS-2 structured light scanner (David Vision Systems GmbH, Koblenz, Germany), as previously described.⁶

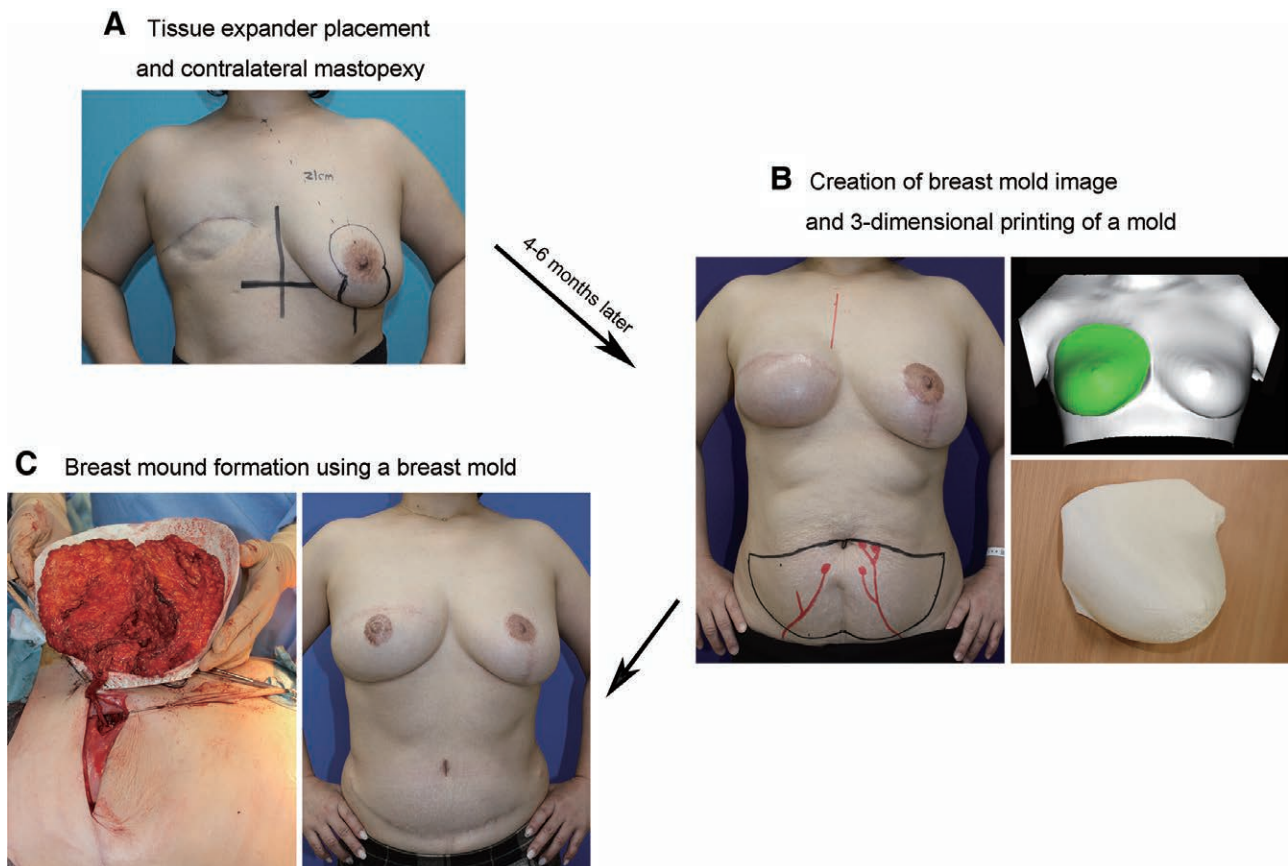


Fig. 1. The flow of 2-stage breast reconstruction procedures is shown. A, In the initial surgery, TE placement in the affected breast, and mastopexy of the contralateral breast using the vertical scar technique, are performed. B, Four to 6 months postoperatively, 3D bilateral breast imaging is performed after confirming that the shape of the contralateral breast is somewhat stabilized, and a 3D-printed breast mold is created based on the mirror image of the shape of the contralateral breast. C, In DIEP flap surgery, the direction of the flap and volume of graft tissue are determined using the breast mold.

Image data were analyzed using Breast-Rugle software, 3D image data-analysis software developed specifically for breast reconstruction procedures (Breast-Rugle, Medic Engineering, Kyoto, Japan), and breast mold data were automatically created based on the horizontally inverted image of the contralateral breast. A 3D polylactic acid breast mold was created using a personal 3D printer (MakerBot Replicator 2x, MakerBot Industries, N.Y.), which was then ethylene oxide gas-sterilized for intraoperative use (Fig. 1B).

The breast mold was used intraoperatively to determine flap direction and graft tissue volume, as previously described,⁶ and the flap was fixed using absorbable sutures (3-0 vicryl) from the back side of the flap (Fig. 1C). After flap deepithelialization, the caudal surface of the flap was tacked with the same absorbable sutures so that the breast mound had a similar shape to that of the contralateral breast, which had been thickened by mastopexy (Fig. 2). Following this, the flap was inserted into the subcutaneous pocket, and an inframammary fold was created according to the method described by Nava et al.^{8,9}

Cosmetic outcomes were evaluated on a 4-point visual analog scale as previously described.¹⁰ Two health professionals assessed cosmetic outcomes as excellent, good, fair, or poor.

RESULTS

Among the 8 flaps, 4 were single-pedicle (unilateral deep inferior epigastric vessel) flaps and 4 were double-pedicle (bilateral deep inferior epigastric vessel) flaps. Mean weight of the transplanted flap was 598 g (range, 447–779 g). In all cases, the flap was engrafted without any major perioperative complications during both the initial and DIEP flap surgeries. One patient had partial necrosis of the flap, 1 developed minor infection of the donor site, and 3 developed donor-site seroma. The patient with partial necrosis of the flap had a history of smoking, and the patients with minor infection and seroma of the donor site had obesity problems (body mass index > 27). Cosmetic outcomes were mostly satisfactory (excellent, 6 cases; good, 2 cases). Of the 2 patients with good outcomes, 1 had softening of the inframammary fold, and the other had insufficient breast thickness due to skin envelope contraction.

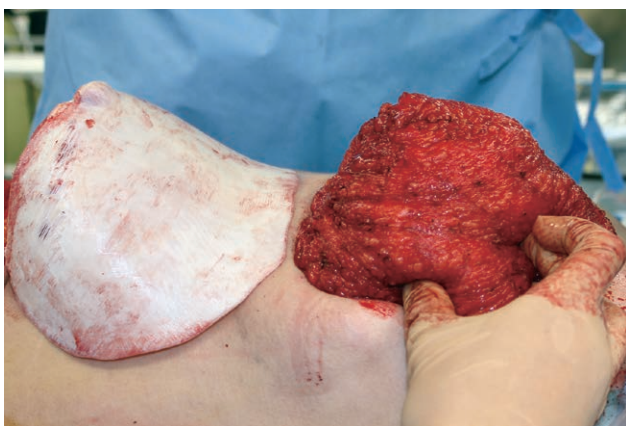

Fig. 2. Using the breast mold as a guide, a thick breast mound is created by tacking the flap surface on the caudal side.

CASE REPORT

A 45-year-old woman underwent modified radical mastectomy and axillary sentinel node biopsy for left breast cancer at another hospital 3 years before making a referral visit to our hospital for delayed reconstruction (Fig. 3A). During the first surgery, subcutaneous TE placement in the left breast area and mastopexy of the right breast were performed. Six months later, 3D bilateral breast imaging was performed, followed by DIEP flap breast reconstruction using a breast mold. The flap was elevated as a double-pedicle flap, and after intraflap anastomosis, 650 g of the 710-g flap was transplanted. Over the course of 6 postoperative months, symmetrical breasts with enough projection were reconstructed successfully (Fig. 3B).

DISCUSSION

Breast reconstruction in patients with ptosis often requires mastopexy or breast reduction of the contralateral breast. In many cases, these procedures are performed as a touch-up surgery following flap transplantation, and it becomes problematic that the desired breast shape cannot be accurately predicted. Breast shape changes postmastopexy, with a reduced breast width/height and increased breast projection. Soft-tissue edema is resolved during the first 3 months, and breast morphological changes are reportedly completed at 3–6 months and 6–9 months after the inverted T-scar and vertical-scar mammoplasty, respectively.² These changes are particularly pronounced and difficult to predict in patients with severe ptosis. Thus, certain experience is needed to achieve a symmetrical reconstruction. Our method is advantageous in that mastopexy is performed before flap surgery, thereby allowing for easier planning for subsequent flap surgery. Moreover, the use of a breast mold, which is created based on the mirror image of the shape of the contralateral breast with postmastopexy changes and alterations, will allow even inexperienced surgeons to achieve reconstruction of symmetrical, nonptotic breasts with ease and in a short time.

One shortcoming of this method is that 2 surgeries are required to complete the reconstruction. In the case of immediate reconstruction following skin-sparing mastectomy, however, bilateral mastopexy could be performed simultaneously, thereby reducing the number of operations to just one.^{11,12} Except when patients have a previous history of postmastectomy radiation therapy, we generally perform 2-stage reconstruction procedures with active use of TEs to avoid a patchwork-like appearance when patients undergo delayed reconstruction or immediate reconstruction involving significant skin resection.¹³ Therefore, our method is likely effective particularly in those cases. Moreover, in nipple-sparing mastectomy, simultaneous bilateral mastopexy poses a risk of nipple-areola complex necrosis; therefore, bilateral mastopexy should be performed secondary to 1-stage or immediate reconstruction.¹⁴ In this scenario, the present method may not be plausible.

CONCLUSIONS

In this small series, we described a new method of symmetrical, nonptotic breast reconstruction using 3D

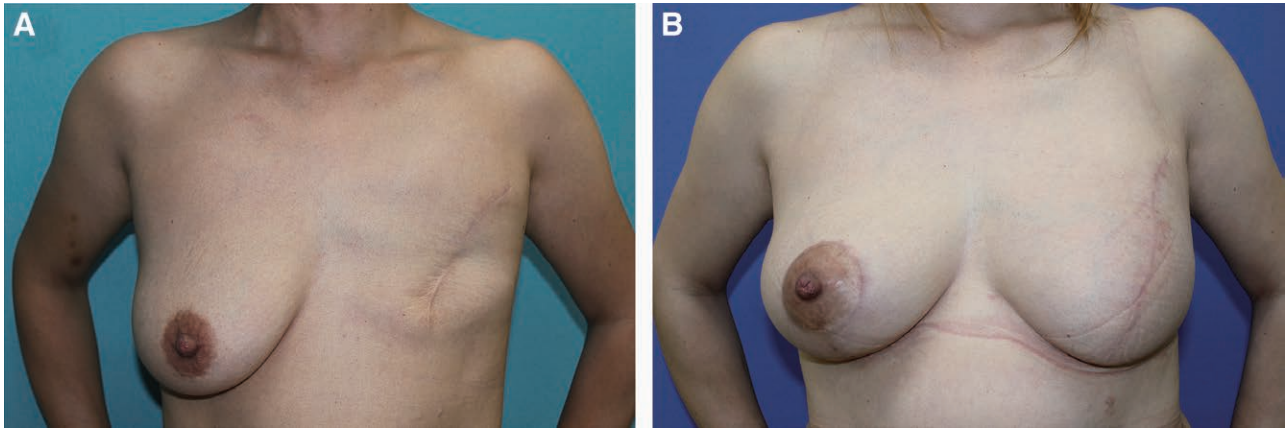


Fig. 3. A 45-year-old woman underwent modified radical mastectomy of the left breast. Three years later, she underwent 2-stage delayed DIEP flap reconstruction. Preoperative view (A) and 6-month postoperative view (B) are shown. We plan to transplant the areola and nipple from the healthy side in the future.

imaging and printing technologies in patients with breast ptosis. From the perspective of reducing the number of operations, the present method will be particularly effective in cases involving TEs, that is, delayed reconstruction or immediate reconstruction requiring significant skin resection.

Koichi Tomita, MD, PhD

Department of Plastic and Reconstructive Surgery
Graduate School of Medicine
Osaka University
2-2 Yamadaoka Suita
Osaka 5650871
Japan
E-mail: ktomita9@hotmail.co.jp

REFERENCES

1. Lejour, M. Vertical mammoplasty: update and appraisal of late results. *Plast Reconstr Surg.* 1999;104:771–781; discussion 782–774.
2. Eder, M, Kloppel, M, Muller, D, et al. 3-D analysis of breast morphology changes after inverted T-scar and vertical-scar reduction mammoplasty over 12 months. *J Plast Reconstr Aesthet Surg.* 2013;66:776–786.
3. Erić M, Anderla A, Stefanović D, et al. Breast volume estimation from systematic series of CT scans using the Cavalieri principle and 3D reconstruction. *Int J Surg.* 2014;12:912–917.
4. Lee KT, Mun GH. Volumetric planning using computed tomographic angiography improves clinical outcomes in DIEP flap breast reconstruction. *Plast Reconstr Surg.* 2016;137:771e–780e.
5. Ahcan U, Bracun D, Zivec K, et al. The use of 3D laser imaging and a new breast replica cast as a method to optimize autologous breast reconstruction after mastectomy. *Breast.* 2012;21:183–189.
6. Tomita K, Yano K, Hata Y, et al. DIEP flap breast reconstruction using 3-dimensional surface imaging and a printed mold. *Plast Reconstr Surg Glob Open.* 2015;3:e316.
7. Regnault P. Breast ptosis. Definition and treatment. *Clin Plast Surg.* 1976;3:193–203.
8. Nava M, Quattrone P, Riggio E. Focus on the breast fascial system: a new approach for inframammary fold reconstruction. *Plast Reconstr Surg.* 1998;102:1034–1045.
9. Tomita K, Yano K, Nishibayashi A, et al. Aesthetic outcomes of inframammary fold recreation in two-stage, implant-based, breast reconstruction. *Springerplus.* 2016;5:1656.
10. Harris JR, Levene MB, Svensson G, et al. Analysis of cosmetic results following primary radiation therapy for stages I and II carcinoma of the breast. *Int J Radiat Oncol Biol Phys.* 1979;5:257–261.
11. Chang EI, Lamaris G, Chang DW. Simultaneous contralateral reduction mammoplasty or mastopexy during unilateral free flap breast reconstruction. *Ann Plast Surg.* 2013;71:144–148.
12. Huang JJ, Wu CW, Leon Lam W, et al. Simultaneous contralateral breast reduction/mastopexy with unilateral breast reconstruction using free abdominal flaps. *Ann Plast Surg.* 2011;67:336–342.
13. Tadiparthi S, Alrawi M, Collis N. Two-stage delayed breast reconstruction with an expander and free abdominal tissue transfer: outcomes of 65 consecutive cases by a single surgeon. *J Plast Reconstr Aesthet Surg.* 2011;64:1608–1612.
14. DellaCroce FJ, Blum CA, Sullivan SK, et al. Nipple-sparing mastectomy and ptosis: perforator flap breast reconstruction allows full secondary mastopexy with complete nipple areolar repositioning. *Plast Reconstr Surg.* 2015;136:1e–9e.