

# Giant axillary tumor resection using ultrasound-guided interscalene brachial plexus block and serratus anterior plane block

Journal of International Medical Research

48(9) 1–5

© The Author(s) 2020

Article reuse guidelines:

[sagepub.com/journals-permissions](https://sagepub.com/journals-permissions)

DOI: 10.1177/0300060520954719

[journals.sagepub.com/home/imr](https://journals.sagepub.com/home/imr)



Ruimin Luo\* , Yu Gu\*, Xu Deng,  
Wenfeng Wu and Yonghua Yao

## Abstract

Herein, we report the combined use of interscalene brachial plexus block and serratus anterior plane block for surgical removal of a large neoplasm that was embedded deep in the axilla and chest wall of a patient with high-risk hypertension. With the combined use of conventional and novel nerve blocks, the large neoplasm was successfully resected without obvious complications.

## Keywords

Interscalene brachial plexus block, serratus anterior plane block, axilla, chest wall, neoplasm, hypertension

Date received: 24 February 2020; accepted: 7 August 2020

## Introduction

Ultrasound-guided nerve block represents an advancement and progress in modern regional anesthesia and aids anesthesiologists in the accurate injection of local anesthetics around the target nerves without damaging them.<sup>1</sup> Usually, general anesthesia is the universal choice for anesthetic management in huge axillary neoplasm resections, especially when the tumor is large and tightly adhered to the deep

---

Department of Anesthesiology, Affiliated Cancer Hospital & Institute of Guangzhou Medical University, Guangzhou, Guangdong, P.R. China

\*These authors contributed equally to this work.

### Corresponding author:

Yonghua Yao, Department of Anesthesiology, Affiliated Cancer Hospital & Institute of Guangzhou Medical University, 78 Hengzhigang Road, Yuexiu, Guangzhou, Guangdong 510000, P.R. China.  
Email: [yaoyonghua01@126.com](mailto:yaoyonghua01@126.com)



Creative Commons Non Commercial CC BY-NC: This article is distributed under the terms of the Creative Commons Attribution-NonCommercial 4.0 License (<https://creativecommons.org/licenses/by-nc/4.0/>) which permits non-commercial use, reproduction and distribution of the work without further permission provided the original work is attributed as specified on the SAGE and Open Access pages (<https://us.sagepub.com/en-us/nam/open-access-at-sage>).

surrounding tissue; however, it may not be optimal for use in patients with severe complications. With the advent and popularity of ultrasound technology, the use of nerve block strategies has increased, but axillary neoplasm resections are rarely performed under nerve block anesthesia alone. However, we successfully performed this operation with a combination of interscalene brachial plexus block (ISBPB) and serratus anterior plane block (SAPB), which eliminated the complications of general anesthesia. Moreover, this combination conferred superior postoperative patient recovery.

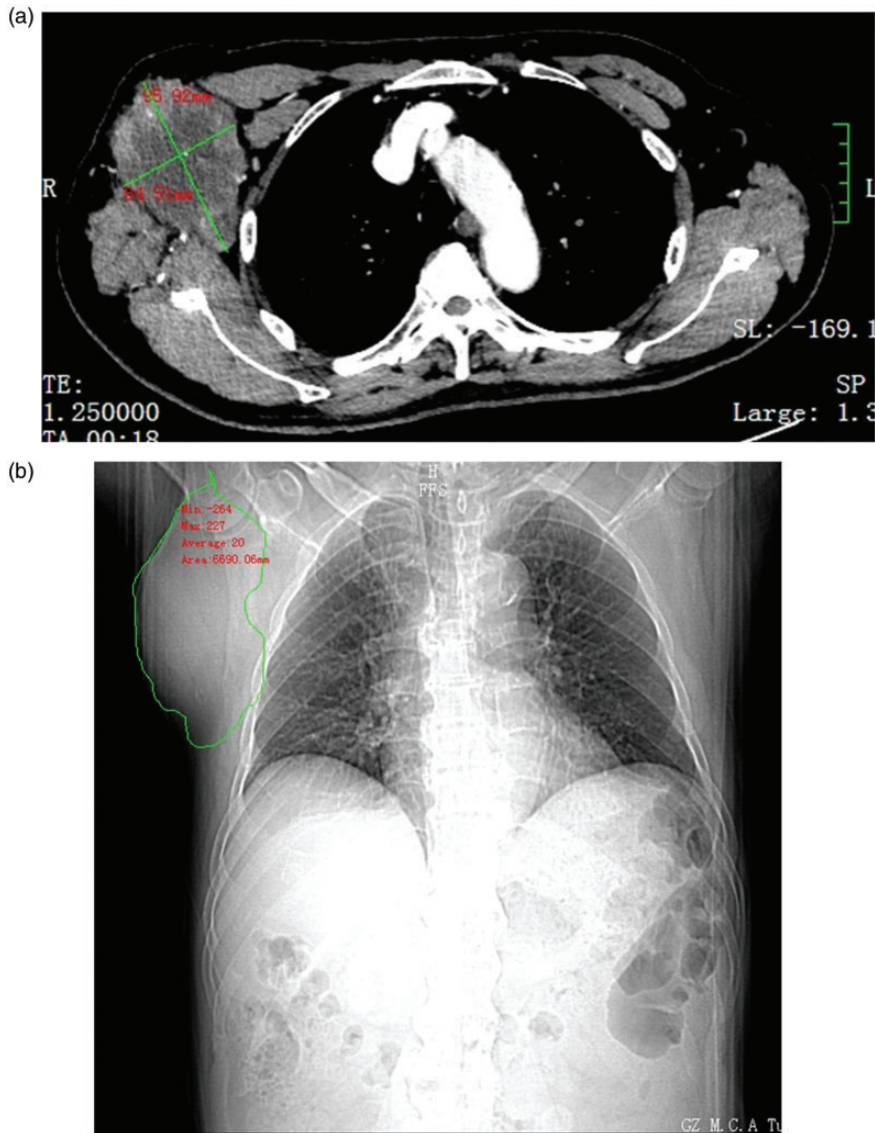
### Case report

A 77-year-old man (160 cm; 65 kg; body mass index [BMI], 25.4 kg/m<sup>2</sup>) required resection of a right axillary neoplasm, which was presumably a squamous cell carcinoma that had metastasized from his upper arm. He was at an advanced age and had a 20-year history of hypertension. His highest blood pressure was about 180/110 mmHg, and he took daily oral valsartan and metoprolol for hypertension. Preoperative echocardiography showed mild mitral and tricuspid valve insufficiency. Preoperative positron emission tomography-computed tomography (PET-CT) indicated sinusitis, right apex pulmonis fibrosis, and aortic calcification. Physical examination found severe sinusitis that adversely affected his sleep, but his preoperative arterial blood gases analysis was normal. A CT scan revealed a 92 × 65-mm irregular right axillary neoplasm (Figure 1a/1b). The anterior margin of the mass extended beyond the anterior axillary line by approximately 2 cm, and the posterior margin reached the posterior axillary line. The tumor extended from the axilla to the fifth rib. On the CT image, it was confined to the subcutaneous area without encroaching on the ribs. For this surgery,

the surgeon planned a 10-cm-long incision from the axilla to the lateral chest wall, followed by complete dissociation of the tumor from the surrounding tissue. The high-risk hypertension, severe sinusitis, and advanced age presented a risk of hemodynamic fluctuation and airway obstruction on general anesthesia, which might greatly impact his prognosis. The patient was assessed to be ASA grade II. Therefore, we attempted combined ISBPB and SAPB.

After establishing venous access and supplementing oxygen, we first performed ISBPB using a 6- to 13-MHz linear ultrasound transducer (Vivid S170N, GE Vingmed Ultrasound AS, Horten, Norway) to trace the brachial plexus root, which appeared as three beads that were approximately vertically aligned between the anterior and middle scalene muscles on the ultrasound image.<sup>2</sup> After skin disinfection and anesthetization, an 80-mm, 22-gauge nerve-stimulating needle (Stimuplex® D, B. Braun, GmbH, Melsungen, Germany) was introduced via the lateral-to-medial approach to target the nerve root. Thereafter, 0.5% ropivacaine (15 mL) was injected evenly around the nerve root. Next, we performed SAPB at the sixth intercostal rib in the right mid-axillary line. Under ultrasound guidance, we identified the latissimus dorsi, serratus anterior, and intercostal muscles; the needle pierced the superficial surface of the serratus anterior and 0.5% ropivacaine (15 mL) was injected above it.

Fifteen minutes postoperatively, the patient's thermoception and pain in the right arm and lateral chest diminished. Midazolam (1 mg), dezocine (10 mg), and continuous intravenous dexmedetomidine infusion (0.3 µg/kg/hour) was provided. His visual analog scale score was <3 and sedation was maintained intraoperatively. Postoperatively, the patient was sent to the ward without any adverse outcomes (Figure 2).

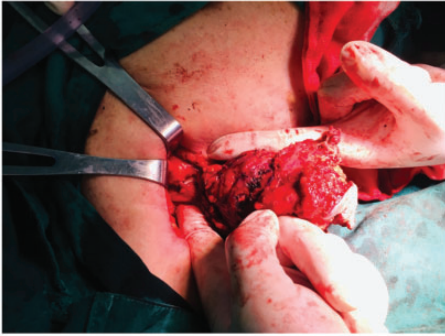

**Figure 1.** (a) Transverse computed tomography image of the axillary neoplasm. (b) Coronal computed tomography image of the axillary neoplasm.

## Discussion

In this patient, the tumor was large and extended from the axilla to the lateral chest wall, and therefore, ISBPB alone was insufficient for tumor resection.<sup>3</sup> Thus, we combined ISBPB with SAPB. The pectoral nerves-2 (PECS2) may be

suitable for the block, but its puncture point is located on the anterior axillary line at the level of the second to fourth intercostal space, which was close to the neoplasm and could have induced its further metastasis.<sup>4</sup> For safety, we performed SAPB at the level of the sixth intercostal



**Figure 2.** Intraoperative separation of the neoplasm.

space instead of the PECS2. The SAPB block method, which is conventionally administered at PECS2, was modified to provide better lateral chest wall analgesia. The serratus anterior extends from the second to the eighth rib, and occasionally, reaches the ninth rib, covering the intercostal muscle.<sup>5</sup> We injected local anesthetic superficially on the serratus anterior surface rather than a deep injection for two reasons. First, consistent with Blanco et al.'s report,<sup>4</sup> superficial SAPB showed wider dermatomal distribution of sensory loss. In a cadaveric study, Biswas et al.<sup>6</sup> reported that superficial SAPB at the level of the fifth rib in the midaxillary line showed dye staining in the axillary region in 18.2% of cases, whereas no staining was observed in the axillary region in any patient with deep SAPB. Second, based on an anatomical document, the mechanism of SAPB appears to be associated with blockade of the lateral cutaneous branch rather than the root of the intercostal nerve.<sup>7</sup> The intercostal nerve is mainly distributed on the thoracic and abdominal walls; it continues from the paravertebral nerve, extends through the intercostal muscles, and then divides into the cutaneous branch and muscular branch before passing the serratus anterior muscle. Its lateral cutaneous branch passes through the lateral chest wall to the surface

of the serratus anterior muscle. Thus, SAPB may depend on the diffusion of local anesthetic on the surface of the serratus anterior or partial passage of local anesthetic through it, rather than directly blocking the nerve root. In addition, they also observed latex expansion after performing SAPB and concluded that the more peripheral intercostal nerve block is unlikely to be the analgesia mechanism of SAPB. Adequate superficial administration of local anesthetics to the serratus anterior ensures efficient anesthetization of the lateral cutaneous branch of intercostal nerve distributed on its surface;<sup>4,8</sup> thus, the afferent pain receptors can be inhibited effectively by blocking the serratus anterior surface.<sup>9</sup>

We combined conventional ISBPB and the modified SAPB, instead of general anesthesia, for a patient at an advanced age and with other high-risk diseases to successfully complete resection of an axillary neoplasm. This approach provided safe and effective anesthesia in our patient, in whom general anesthesia was believed to pose a high risk. Our case provides an alternative to general anesthesia in axillary surgeries.

### Declaration of conflicting interest

The authors declare that there is no conflict of interest.

### Ethics and consent

Written informed consent for the publication of this case report and accompanying images was obtained from the patient prior to surgery.

### Funding

This research received no specific grant from any funding agency in the public, commercial, or not-for-profit sectors.

### ORCID iD

Ruimin Luo  <https://orcid.org/0000-0002-4106-1243>

## References

1. Helen L, O'Donnell BD, and Moore E. Nerve localization techniques for peripheral nerve block and possible future directions. *Acta Anaesth Scand* 2015; 59: 962–974.
2. Franco CD, Williams JM. Ultrasound-guided interscalene block: reevaluation of the “stoplight” sign and clinical implications. *Reg Anesth Pain Med* 2016; 41: 452–459. DOI:10.1097/AAP.0000000000000407.
3. Neuts A, Stessel B, Wouters PF, et al. Selective suprascapular and axillary nerve block versus interscalene plexus block for pain control after arthroscopic shoulder surgery: a noninferiority randomized parallel-controlled clinical trial. *Reg Anesth Pain Med* 2018; 43: 738–744.
4. Blanco R, Parras T, McDonnell JG, et al. Serratus plane block: a novel ultrasound-guided thoracic wall nerve block. *Anaesthesia* 2013; 68: 1107–1113.
5. Didesch JT and Tang P. Anatomy, etiology, and management of scapular winging. *J Hand Surg Am* 2019; 44: 321–330. DOI:10.1016/j.jhsa.2018.08.008.
6. Biswas A, Castanov V, Li Z, et al. Serratus plane block. *Reg Anesth Pain Med* 2018; 43: 854–858.
7. Mayes J, Davison E, Panahi P, et al. An anatomical evaluation of the serratus anterior plane block. *Anaesthesia* 2016; 71: 1064–1069.
8. Piracha MM, Thorp SL, Puttanniah V, et al. “A tale of two planes”: deep versus superficial serratus plane block for postmastectomy pain syndrome. *Reg Anesth Pain Med* 2017; 42: 259–262.
9. Park MH, Kim JA, Ahn HJ, et al. A randomised trial of serratus anterior plane block for analgesia after thoracoscopic surgery. *Anaesthesia* 2018; 73: 1260–1264.