

# Recurrent Anterior Shoulder Dislocation with Coracoid Fracture in an Old Age Male: A Rare Case Report

Kaustubh Sawant<sup>1</sup>, Sagar Bansal<sup>1</sup>

## Learning Point of the Article:

Proper pre-operative planning and thorough investigations would be helpful in diagnosing more such cases and a proper management protocol for such patients.

## Abstract

**Introduction:** Anterior shoulder dislocation is a common pathology in young males with less prevalence in other age groups. Anterior shoulder dislocation being the most common variety of dislocation among the shoulder dislocation can be managed both conservatively and surgically. Recurrent anterior dislocation in middle-aged males with a coracoid fracture is a rare entity and should be managed with proper pre-operative planning including computed tomography (CT) scan, magnetic resonance imaging (MRI), and surgery.

**Case Report:** A 65-year-old male is a known case of recurrent anterior dislocation presented with anterior shoulder dislocation 1½ years back. Closed reduction was done. Radiological evaluations such as CT scan and MRI were done which were suggestive of bony Bankart and coracoid fracture which was managed with open Latarjet procedure.

**Conclusion:** Recurrent anterior shoulder dislocation with a concomitant coracoid fracture is a rare entity in old age, which can be managed with a Latarjet procedure and has a good post-operative outcome.

**Keywords:** Recurrent anterior shoulder dislocation, coracoid fracture, Latarjet procedure.

## Introduction

Shoulder dislocation is the most common joint to dislocate with anterior dislocation accounting for approximately 50% of those [1]. The inherent instability of the joint makes it vulnerable to dislocation with anterior dislocation being the most common type followed by posterior and inferior dislocation, respectively [2-5]. Although these dislocations can occur in any age, 20–29 years is the most common age group. Trauma, seizures, and electrocution injury are the most common mechanisms of shoulder dislocation. Management of shoulder dislocation varies from closed reduction and brace to capsulolabral repair, bony Bankart fixation, Latarjet, and many more depending on the

patient's age, occupation, radiological findings, and recurrent/first episode. Coracoid fractures are a rare occurrence in orthopedics accounting for around 1% of all the fractures and around 5% of fractures about the shoulder joint [6, 7]. Literature describing the occurrence of coracoid fracture with recurrent anterior shoulder dislocation is rare. In this case report, we discuss a case of recurrent anterior instability with coracoid fracture in a 65-year-old male.

## Case Report

A 65-year-old male presented to us 1½ years back with right-sided anterior shoulder dislocation in an emergency (Fig. 1).

Access this article online

Website:  
www.jocr.co.in

DOI:  
<https://doi.org/10.13107/jocr.2024.v14.i10.4846>

## Author's Photo Gallery



Dr. Kaustubh Sawant



Dr. Sagar Bansal

<sup>1</sup>Department of Orthopaedics, Pt. Madan Mohan Malviya Hospital, Mumbai, Maharashtra, India.

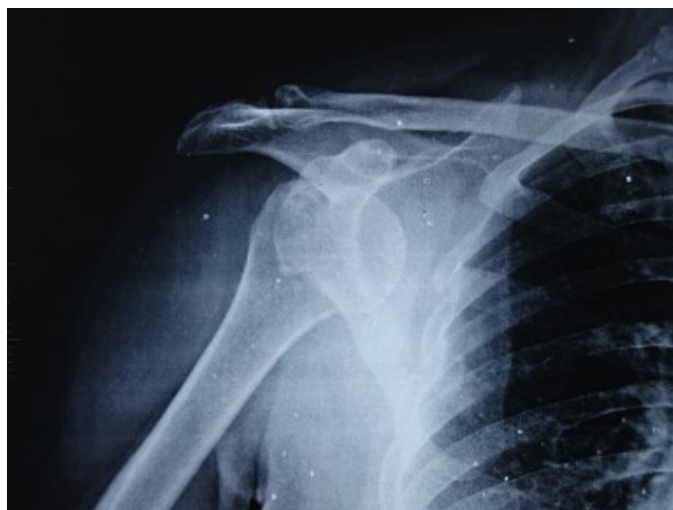### Address of Correspondence:

Dr. Sagar Bansal,  
Department of Orthopaedics, Pt. Madan Mohan Malviya Hospital, Mumbai, Maharashtra, India.  
E-mail: sagarbansal59@gmail.com

Submitted: 25/07/2024; Review: 13/08/2024; Accepted: September 2024; Published: October 2024

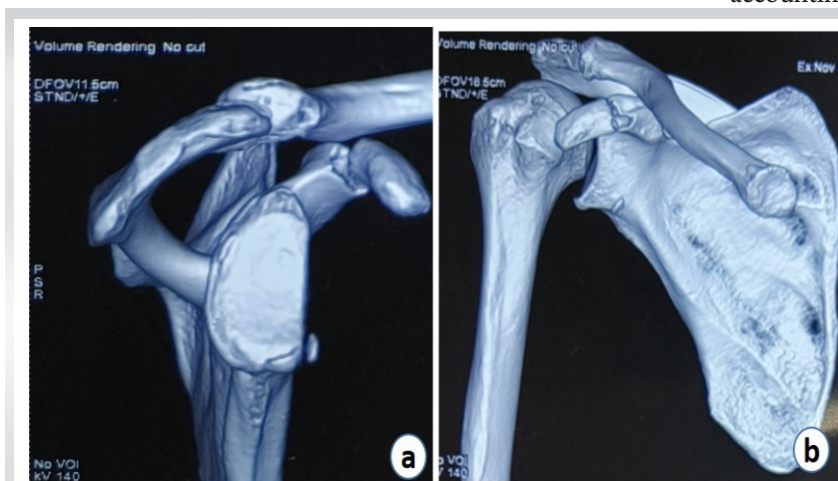
DOI: <https://doi.org/10.13107/jocr.2024.v14.i10.4846>

This is an open access journal, and articles are distributed under the terms of the Creative Commons Attribution-NonCommercial-ShareAlike 4.0 License <https://creativecommons.org/licenses/by-nc-sa/4.0/>, which allows others to remix, tweak, and build upon the work non-commercially, as long as appropriate credit is given and the new creations are licensed under the identical terms



**Figure 1:** X-ray suggestive of right shoulder dislocation.

After doing closed reduction and confirming the reduction on X-ray, the patient was admitted for further management. History was suggestive of the first episode of dislocation in 2006 following trauma after which the patient had recurrent episodes every year. There was no hypermobility at joints as well as no neurovascular defect. He had a known case of hypertension and diabetes mellitus and was on medications for the same. Computed tomography (CT) scan of right shoulder was suggestive of coracoid process fracture, bony defect in the postero-superior aspect of the right humerus, and bony fragment seen in the antero-inferior aspect of the glenoid region (Fig. 2a and b). Bone loss was calculated with the best-fit circle method and was approximately 35%. Magnetic resonance imaging (MRI) is suggestive of minimally displaced coracoid fracture. Hills Sach lesion and bony Bankart lesion. After proper pre-operative workup, the patient was planned for open



**Figure 2:** (a and b) Computed tomography cuts show glenoid bone loss and coracoid fracture.

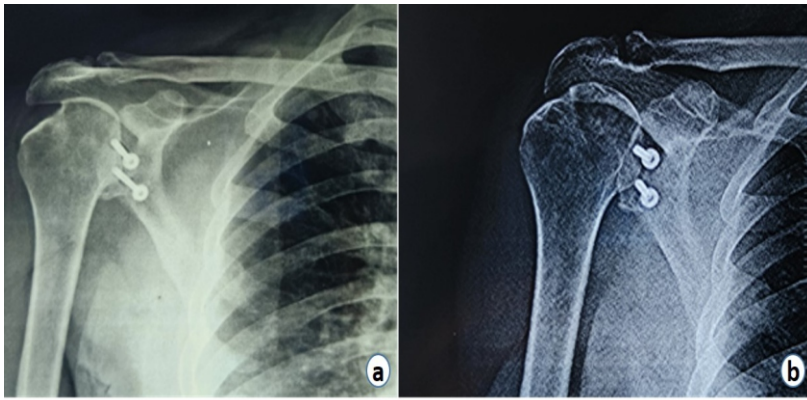
congruent-arc Latarjet. The deltopectoral approach was taken. After incising the clavipectoral fascia, a fractured coracoid was identified. The inferior edge of the coracoid and glenoid anterior surface was prepared for fixation. Fragment was passed through the inferior one-third of the subscapularis and was fixed to the glenoid with a 4-mm cannulated cancellous screw (Fig. 3a and b). Extra-articulation of the graft was done using a suture anchor. Post-operative physiotherapy was started from day 1. At 1½-year follow-up, the patient is back to performing his job as well as easily performing activities of daily living without any pain. The patient had 10° forward elevation and external rotation lag in contrast to the opposite side and internal rotation possible up to the postero-superior iliac spine (Fig. 4a-c). He had no further dislocation episode post-surgery.

### Discussion

The shoulder joint is a complex joint which is stabilized by various structures during its range of motion. Glenohumeral articulation, glenoid labrum, glenohumeral ligaments, rotator cuff, and deltoid muscle play an important role in stabilizing shoulder joints. The shoulder joint is an inherently unstable joint because of the limited osseous contact between the humeral head and glenoid, hence predisposing the joint to subluxation and dislocation making it the most commonly dislocated synovial joint of the body [8]. The glenoid labrum plays an important role in providing stability by deepening the glenoid cavity by around 50% [9].

A Bankart lesion, which is defined as the anteroinferior detachment of the glenoid labrum, is present in about 87–100% of 1st-time dislocations because this portion of the labrum is the weakest part of the glenohumeral complex [10, 11, 12]. Coracoid fractures are a rare occurrence in orthopedics accounting for around 1% of all the fractures and around 5% of

fractures about the shoulder joint [6, 7]. Coracoid fractures can occur through various mechanisms such as avulsion injuries, fatigue fractures, direct contact injuries, and glenohumeral dislocation events [13, 14, 15]. Coracoid fractures are often missed in cases of shoulder dislocation which leads to persistent pain post-dislocation. Its diagnosis is important due to its implications in deciding the management for the patient. While the axillary view and Stryker notch view might help in diagnosing coracoid fracture, in our case, CT and MRI done for the management of recurrent dislocation revealed the minimally displaced coracoid process fracture. It is our hypothesis that the coracoid fracture in our case was due to a direct blow of the humeral head on



**Figure 3:** (a and b) X-rays: Immediate post-operative and after 1-year post-operative.

the coracoid. CT scan was suggestive of 35% glenoid bone loss. After necessary pre-operative workup, the patient was taken for an open Latarjet procedure in which the fractured coracoid was used to augment the anterior glenoid and was fixed with 2 metal screws. With proper post-operative rehabilitation, the patient is presently able to do all activities of daily living and has returned to work. Few cases of anterior shoulder dislocation have been described in the literature. Bishai et al. published a publication of 3 cases with anterior dislocation and coracoid fracture, in which one was managed with arthroscopic Latarjet, the second one with open Latarjet, and the last one with open reduction and internal fixation of coracoid fracture and glenoid augmentation with distal tibial allograft [16]. Verma et al. presented a similar case in a 28-year-old male who was managed with an iliac crest graft because the fracture segment was too small [7]. Lal et al. reported a case of 48 years whose coracoid fracture was diagnosed intraoperatively while doing an open Bankart procedure, signifying the possibility of missing a coracoid preoperatively in many cases [15]. Saragaglia et al. in 1994 published three cases of anterior shoulder instability with

coracoid fracture which were managed with the Latarjet procedure using the coracoid fracture [17]. Out of the 3 cases, 1 was diagnosed with coracoid fracture intraoperatively. Robinson et al. reported 5 cases of coracoid non-union in 5 cases of anterior glenohumeral instability in known cases of seizure disorder. Boytchev B in 1951 managed the cases of recurrent anterior dislocation by rerouting the tendon of coracobrachialis, the short head of biceps, pectoralis minor, and the detached tip of coracoid underneath the subscapularis and fixing them with a screw [18]. Boytchev procedure led to high redislocation rates and hence was not practised.

Apart from Latarjet, other procedures such as augmentation with scapular spine bone graft, iliac crest bone graft, and distal tibia allograft can be used for the management of recurrent shoulder dislocation patients. With recurrent anterior shoulder instability being a common pathology managed by an orthopedic surgeon, one should be mindful to rule out other concomitant pathology, especially coracoid fracture preoperatively itself with imaging studies. Not only it is commonly missed out preoperatively in many cases as the data published show but if left undiagnosed and not managed, it might lead to constant post-operative pain even if the glenoid pathology is managed leading to poor prognosis.

In our case, anterior shoulder instability in a 65-year-old male Latarjet was done using the fractured coracoid as a graft, underlining the importance of good pre-operative planning to avoid missing such rare but possible injury patterns.

### Conclusion

With limited data published on cases of anterior shoulder



**Figure 4:** (a-c) Range of motion: Internal rotation, forward elevation, and external rotation at 1-year post-operative.

instability and coracoid fracture, and a portion of those fractures being missed preoperatively, we are of the view that thorough radiological investigations done preoperatively can help in diagnosing more such cases so that more studies can be done as currently the data are too small to make any conclusions regarding the management of such cases.

### Clinical Message

With only limited cases being reported of coracoid fracture in recurrent shoulder dislocation, we feel that many of such fractures are missed pre-operatively, we hope that by proper case discussions and planning pre-operatively, more such cases will be reported in the near future.

**Declaration of patient consent:** The authors certify that they have obtained all appropriate patient consent forms. In the form, the patient has given the consent for his/ her images and other clinical information to be reported in the journal. The patient understands that his/ her names and initials will not be published and due efforts will be made to conceal their identity, but anonymity cannot be guaranteed.

**Conflict of interest:** Nil    **Source of support:** None

### References

- Abrams R, Akbarnia H. Shoulder dislocations overview. In: StatPearls. Treasure Island, FL: StatPearls Publishing; 2023. Available from: <https://www.ncbi.nlm.nih.gov/books/NBK459125> [Last accessed on 2023 Aug 08].
- Farrar NG, Malal JJ, Fischer J, Waseem M. An overview of shoulder instability and its management. *Open Orthop J* 2013;7:338-46.
- Vasiliadis AV, Kalitsis C, Biniaris G, Saridis A. Anterior shoulder dislocation during breaststroke swimming technique: A case report and review of the literature. *Case Rep Orthop* 2019;2019:9320569.
- Phadke A, Bakti N, Bawale R, Singh B. Current concepts in management of ACJ injuries. *J Clin Orthop Trauma* 2019;10:480-5.
- Carr JB, Chicklo B, Altchek DW, Dines JS. On-field management of shoulder and elbow injuries in baseball athletes. *Curr Rev Musculoskelet Med* 2019;12:67-71.
- Daggett M, Busch K, Sonnery-Cottet B. Surgical dissection of the anterolateral ligament. *Arthrosc Tech* 2016;5:e185-8.
- Verma N, Chahar D, Chawla A, Sreenivasan R, Pankaj A. Recurrent anterior instability of the shoulder associated with coracoid fracture - An unusual presentation. *J Clin Orthop Trauma* 2016;7:99-102.
- Dodson CC, Cordasco FA. Anterior glenohumeral joint dislocations. *Orthop Clin North Am* 2008;39:507-18, vii.
- Howell SM, Galinat BJ. The glenoid-labral socket. A constrained articular surface. *Clin Orthop Relat Res* 1989;243:122-5.
- Taylor DC, Arciero RA. Pathologic changes associated with shoulder dislocations. Arthroscopic and physical examination findings in first-time, traumatic anterior dislocations. *Am J Sports Med* 1997;25:306-11.
- Baker CL, Uribe JW, Whitman C. Arthroscopic evaluation of acute initial anterior shoulder dislocations. *Am J Sports Med* 1990;18:25-8.
- Norlin R. Intraarticular pathology in acute, first-time anterior shoulder dislocation: An arthroscopic study. *Arthroscopy* 1993;9:546-9.
- Archik S, Nanda SN, Tripathi S, Choudhari A, Rajadhyaksha H. An isolated displaced fracture of the coracoid process treated with open reduction and internal fixation - a case report and review of literature. *J Orthop Case Rep* 2016;6:37-9.
- Kennedy NI, Ferrari MB, Godin JA, Sanchez G, Provencher MT. Repair of an isolated coracoid fracture with suture anchor fixation. *Arthrosc Tech* 2017;6:e1715-9.
- Lal H, Bansal P, Sabharwal VK, Mawia L, Mittal D. Recurrent shoulder dislocations secondary to coracoid process fracture: A case report. *J Orthop Surg (Hong Kong)* 2012;20:121-5.
- Bishai SK, Maceroni M, King CN, Martinez MM. A case report presenting 3 cases of anterior shoulder dislocations with coracoid fractures each with similar glenoid bone loss patterns. *JSES Rev Rep Tech* 2021;1:430-7.
- Saragaglia D, Picard F, Gérard P, Tourne Y, Leroy JM. L'instabilité antérieure de l'épaule associée à la fracture du processus coracoïde. A propos de trois cas [Anterior instability of the shoulder associated with fracture of the coracoid process. A propos of 3 cases]. *Rev Chir Orthop Reparatrice Appar Mot* 1994;80:651-5.
- Robinson CM, Al-Hourani K, Malley TS, Murray IR. Anterior shoulder instability associated with coracoid



nonunion in patients with a seizure disorder. J Bone Joint Surg Am 2012;94:e40.

**Conflict of Interest:** Nil  
**Source of Support:** Nil

**Consent:** The authors confirm that informed consent was obtained from the patient for publication of this case report

#### How to Cite this Article

Sawant K, Bansal S. Recurrent Anterior Shoulder Dislocation with Coracoid Fracture in an Old Age Male: A Rare Case Report. Journal of Orthopaedic Case Reports 2024 October;14(10): 158-162.

